

Journal Pre-proof

Mitotane: new facts for an old drug

A. Calabrese, S. Puglisi, V. Basile, P. Perotti, M. Terzolo

PII: S2451-9650(19)30067-5

DOI: <https://doi.org/10.1016/j.coemr.2019.08.010>

Reference: COEMR 110

To appear in: *Current Opinion in Endocrine and Metabolic Research*

Received Date: 11 July 2019


Revised Date: 15 August 2019

Accepted Date: 19 August 2019

Please cite this article as: Calabrese A, Puglisi S, Basile V, Perotti P, Terzolo M, Mitotane: new facts for an old drug, *Current Opinion in Endocrine and Metabolic Research*, <https://doi.org/10.1016/j.coemr.2019.08.010>.

This is a PDF file of an article that has undergone enhancements after acceptance, such as the addition of a cover page and metadata, and formatting for readability, but it is not yet the definitive version of record. This version will undergo additional copyediting, typesetting and review before it is published in its final form, but we are providing this version to give early visibility of the article. Please note that, during the production process, errors may be discovered which could affect the content, and all legal disclaimers that apply to the journal pertain.

© 2019 Elsevier Ltd. All rights reserved.



MITOTANE: NEW FACTS FOR AN OLD DRUG. (FULL TITLE)

NOVEL EVIDENCE ON MITOTANE. (SHORT TITLE)

A. Calabrese¹, S. Puglisi¹, V. Basile, P. Perotti, M. Terzolo.

Internal Medicine, Dept. of Clinical and Biological Sciences, S. Luigi Gonzaga Hospital,
University of Turin, Orbassano, Italy

¹The two authors contributed equally.

Corresponding author:

Prof. Massimo Terzolo

Internal Medicine, Dept. of Clinical and Biological Sciences, University of Turin

S. Luigi Gonzaga Hospital, Regione Gonzole 10, Orbassano (TO) 10043, Italy

(+39) 320 8527961, terzolo@usa.net

DISCLOSURE STATEMENT

AC, VB and PP have nothing to declare. SP has received a grant for scientific writing from HRA Pharma; MT has received research grants from HRA Pharma and Novartis, and advisory board honoraria from HRA Pharma.

ABSTRACT

Adrenocortical carcinoma (ACC) is an aggressive cancer with poor long-term survival.

Apart from radical surgery, there is a reduced range of therapeutic possibilities and mitotane remains the cornerstone of the treatment in adjuvant and palliative setting.

Even though many decades after its introduction in clinical practice, there are still many uncertainties surrounding the applied use and the actual benefit of this old drug.

Recent ACC guidelines suggest adjuvant mitotane for patients at high risk of recurrence, and chemotherapy plus mitotane in metastatic disease, moreover the use of mitotane monotherapy has been proposed in a subset of patients.

When using mitotane, physicians have to consider and manage its potential toxicity and endocrine effects that need a complex supporting therapy.

BACKGROUND

Adrenocortical cancer (ACC) is a rare and aggressive cancer, with an overall 5-year survival rate of 16% - 47% (1). Patient outcome is mainly influenced by completeness of surgical removal and tumor stage at diagnosis (2). However, prognosis is not uniform and survival at any stage may vary depending on clinical, pathological and molecular factors that have been partially elucidated (3).

Development of treatment options beyond surgery has been limited. Surgery, however, may cure only a few patients, while most of them will suffer recurrence and tumor progression leading to death. Therefore, there is an urgent need to develop effective medical treatments to improve patient outcome. Up to now, no personalized approach has been developed, and no simple targetable molecular event has been identified from preclinical studies (1) (4) (5).

To underline the low level of evidence on medical treatment of ACC it is enough to remember that only two randomized controlled trials on advanced ACC have been conducted (6) (7), while no randomized study is available on adjuvant treatments.

In this unpleasant scenario, mitotane remains the cornerstone of ACC treatment being currently used both in adjuvant and palliative setting. However, more than 50 years after its introduction in clinical practice, there are still many uncertainties surrounding the use of this old drug.

The scope of this work is to present a concise review of recent advances in the use of mitotane.

MITOTANE FOR ADJUVANT TREATMENT

Given that ACC has a strong propensity to recur after surgery (8) and that tumor recurrence is also frequently observed after microscopically radical (R0) operations done by skilled surgeons (9), implementation of adjuvant treatments in clinical practice appears as a sound strategy (10). The adjuvant treatment mostly employed in clinics has been the administration of mitotane, although there is an ongoing debate on its actual efficacy. Lacking results from randomized controlled trials, the best evidence in favor of adjuvant mitotane in ACC patients following radical surgery comes from a large retrospective case-control study by our group. The study showed that patients treated with adjuvant mitotane had a significantly survival advantage compared with that of patients left untreated following surgery (11). Strengths of the study are its statistical power and that treatment assignment was center-specific (i.e. all patients of a given center were treated or not) and not based on patient characteristics, thus resulting in the inclusion of well-matched control groups. The retrospective nature of the study, however, does not allow concluding definitively that adjuvant mitotane treatment is beneficial. An uneven patient selection confounds the interpretation of the study outcomes, as exemplified by a retrospective analysis of 207 ACC patients claiming that adjuvant mitotane treatment was associated with reduced recurrence-free survival (RFS). In that study, however, 28% of patients treated with adjuvant mitotane had metastatic ACC at presentation compared to 9% of untreated patients. Therefore, the study suffers from a confounding by indication since the mitotane-treated patients had a far higher risk of recurrence at baseline than untreated patients, a difference that cannot be fully adjusted for in multivariate analysis (12).

Our group has updated the follow-up of the cohorts of patients included in the 2007 study

(11) with almost 10 years of additional observation, confirming that adjuvant mitotane treatment is associated with a significant benefit in terms of RFS regardless of the hormone secretory status (13). Median RFS was 42 months in the adjuvant group compared with 17 months in control group 1 ($p < 0.001$) and 26 months control group 2 ($p < 0.005$) (13). Mitotane-treated patients had a significant benefit in overall survival (OS) in comparison with the control group 1, while the difference in OS just failed to reach statistical significance with the control group 2 (13). In this study, landmark analysis was employed to circumvent the immortal-time bias that is a common confounder of this type of studies.

Efficacy of adjuvant mitotane treatment has been the subject of two recent meta-analyses that were able to retrieve only 6 and 5 studies, respectively, fulfilling the quality criteria of sufficient patient number, presence of a concomitant control group of untreated patients and reporting of baseline patient characteristics. Due to the variable inclusion criteria and different study procedures, a remarkable heterogeneity between studies was apparent in both meta-analyses that were not able to identify predictors of response to adjuvant mitotane (14) (15). Both meta-analyses, however, concluded that adjuvant mitotane was associated with a significant prolongation of OS, while the increment in RFS resulted statistically significant only in one (15).

The European Society of Endocrinology - ENSAT guidelines on the management of ACC suggest adjuvant mitotane treatment for patients at high risk of recurrence following complete tumor extirpation, although recognizing the low level of evidence of this recommendation (Figure 1). Adjuvant mitotane remains an option to be discussed on individual basis for patients at low risk of recurrence (14). This subset of patients is the target of the randomized controlled study ADIUVO (www.epiclin.it/adiuvo) whose

results are expected in the next year.

We have recently reviewed our experience with adjuvant mitotane treatment in non-metastatic ACC patients following complete tumor resection (16). We did a retrospective analysis of 152 patients who have not been included in previous studies. Of those, 100 patients underwent adjuvant mitotane therapy after initial surgery (mitotane group) and 52 were not treated with any adjuvant treatment following surgery (control group). The median RFS was 36.5 months (4-199) in the mitotane group and 21 months (4-180) in the control group ($p < 0.001$). The difference in OS was not significantly different between treated and untreated patients; however, in the group of patients with either stage III ACC or ki67 index $> 10\%$ adjuvant mitotane was associated with a significant prolongation of RFS ($p = 0.014$) (Figure 2). Interestingly, hormone-secreting ACC showed a higher ki67 index and this may explain why hormone secretion was a worse prognostic factor, confirming previous observations (17). In our experience, a low-dose mitotane regimen had acceptable toxicity and most patients were able to tolerate long-term treatment. Therefore, this study is the first to support, although on a retrospective basis, the current recommendation of adjuvant mitotane therapy in ACC patients at high risk of recurrence following radical surgery.

MITOTANE FOR TREATMENT OF ADVANCED DISEASE

The management of ACC patients with metastatic disease is challenging and the prognosis is generally poor, since most patients are doomed to die of disease progression within 1-2 years. However, ACC is a heterogeneous disease and a subset of patients bearing less aggressive tumors may experience quite prolonged survival. Several prognostic factors such as time since initial surgery, presence of distant metastases, number of metastatic lesions and number of organs involved, and high tumor grade have been found to predict survival in patients with metastatic ACC (18) (19). Moreover, studies indicated that overt cortisol excess is associated with a detrimental prognosis due to the associated morbidity (20) (21).

Treatment of advanced/metastatic patients may include as therapeutic tools loco-regional approaches, such as surgery, radiofrequency ablation and chemoembolization, in patients with slowly progressive disease and low metastatic burden (22) (23) (24). Loco-regional measures may synergize with systemic therapies to attain long-lasting tumor control in patients with less aggressive ACC. In presence of low-grade tumors with limited metastatic burden, therefore, it is reasonable to offer single-agent mitotane as a systemic option (14). Early studies assessing the efficacy of single-agent mitotane reported a rate of objective tumor responses between 13% and 31% (25) (26) (27). However, most of the responses were of limited duration and complete responses were rarely observed. The outcome of these studies raised the concept of a “therapeutic range” of plasma mitotane concentrations that should be targeted in any patient with advanced/metastatic ACC. As a matter of fact, disease responses were mainly confined in patients attaining plasma mitotane concentration between 14 and 20 mg/L (25) (26) (27).

This concept has been validated more recently in a retrospective series of 127 patients receiving mitotane monotherapy for advanced ACC (28). In this study, the patients who reached a peak mitotane concentration >14 mg/L had longer RFS and OS than patients who did not. Interestingly, also the rate of objective responses was higher in patients with mitotane concentrations at target, even if some responses were observed with lower levels. Overall, a complete response was observed in 2.3% of patients, a partial response in 18.1%, and disease stabilization in 25.2%, respectively. Interestingly, objective tumor responses were as high as 30% in patients with either low tumor burden (<10 tumour lesions) or longer RFS after primary surgery (≥ 360 days) (Figure 3). Although the OS was quite limited, being 18.5 months, mitotane monotherapy was able to attain long-lasting tumor control in a number of patients (28). Therefore, the study supports the concept that mitotane is a slow-acting drug, and that mitotane monotherapy is indicated in the management of patients with a low tumor burden and/or more indolent disease. Conversely, chemotherapy plus mitotane are currently recommended for patients with aggressive disease and multiple metastases (14).

Very recently, the outcome of single-agent monotherapy has been reported in 36 patients with metastatic ACC treated at a single center. In this retrospective series, most patients progressed under treatment but a remarkable 8% complete response rate was observed. The responding patients had non-functioning tumors with a low-volume disease (29). Although on a limited patient cohort, the study confirms that mitotane monotherapy may be effective in selected ACC patients.

Owing to the latency of action of mitotane associated to the time needed to reach the therapeutic target, it is unclear how long clinicians should wait to assess the efficacy, or the lack of, of mitotane therapy. As a consequence, mitotane is continued almost

indefinitely in many patients with advanced ACC lacking clear rules for its discontinuation. A recent study aimed to clarify this issue, evaluating the time until a partial response was attained in patients with metastatic ACC (30). A cohort of 68 patients who survived more than 24 months after diagnosis of stage IV ACC was retrospectively analyzed, including 57 patients treated with mitotane monotherapy and the remainders with mitotane associated to chemotherapy. In this selected cohort of long-term survivors, almost all objective responses were observed within 12 months from start of mitotane and this finding suggests that mitotane may be discontinued after that time if ACC continues to progress. The value of the therapeutic range was reaffirmed, since responses were more frequently and rapidly observed in patients attaining mitotane concentrations >14 mg/L. The association between response and target mitotane concentrations was less apparent when mitotane was used with chemotherapy (30).

ENDOCRINE EFFECTS OF MITOTANE

It is held that mitotane has a plethora of effects on the endocrine system; thus, the drug can be regarded as an endocrine disruptor (31). In addition to its inhibitory effect on adrenal steroidogenesis, mitotane affects also testosterone synthesis, pituitary function (32) (33) (34) (35) and has an inherent estrogenic effect that has been recently demonstrated *in vivo*, in a mitotane-treated child who developed a peripheral precocious puberty (31).

The effects of mitotane on the hypothalamic-pituitary-adrenal axis were thoroughly investigated in a prospective cohort of 16 ACC patients treated following radical tumor resection (36). The study showed that chronic mitotane treatment led to adrenal insufficiency in most but not all patients, despite that therapeutic concentrations were reached in 50% of cases. Interestingly, ACTH levels were elevated in most but not all patients, and the ACTH response to CRH was lower than in a cohort of patients with Addison's disease (36). This finding may result from an inhibitory effect of mitotane on pituitary ACTH, as previously demonstrated *in vitro* (33).

The study was unable to find biomarkers that may help to guide hormone replacement in mitotane-treated patients, which is not an easy task due to the increased metabolic clearance of exogenous steroids on mitotane treatment (37). This implies that doses of cortisone acetate as high as 50-100 mg daily (36), or hydrocortisone 40-80 mg daily (38), are needed in ACC patients on mitotane. In an attempt to simplify glucocorticoid replacement, ACC patients on mitotane were switched from immediate to modified release hydrocortisone. However, the use of equivalent doses of modified release hydrocortisone resulted in insufficient hydrocortisone coverage; thus, the new formulation of hydrocortisone cannot be recommended for mitotane-induced adrenal

insufficiency (38).

Mitotane is able to alter testosterone levels through a complex effect including a sharp rise in the levels of sex hormone binding protein (SHBP) and a delayed inhibition of testosterone synthesis and secretion by the testis. As a consequence, levels of total testosterone may actually rise in a first phase, or remain normal, but free testosterone (the bioactive fraction) is reduced causing sexual dysfunction in about 30% of men on longstanding treatment. Sex steroid replacement may become necessary to treat male hypogonadism but can worsen gynecomastia, to which concurs the intrinsic estrogenic effect of mitotane (32).

Mitotane interferes with thyroid function and hypothyroidism becomes apparent early in the course of treatment in about half of treated patients. Mitotane administration is associated with low FT4 levels without a compensatory rise in TSH, a finding that recalls central hypothyroidism due to the inhibitory effect of mitotane on the synthesis and secretion of TSH (32,35).

Mitotane treatment is also associated with increasing levels of LDL, HDL cholesterol, and triglycerides (32). However, the value of introducing statins remains uncertain and the decision to use anti-lipid drugs should be carefully thought considering the cardiovascular risk and life expectancy of the treated patients (10, 14). Clinicians should avoid in mitotane-treated patients drugs metabolized by cytochrome P450 subtype 3A4, such as some statins, anti-hypertensive drugs, hormones, benzodiazepines, because of the expected reduction in drug concentration and effect due to this pharmacologic interaction (14).

CONCLUSION

Novel data on the efficacy of single-agent mitotane treatment, either as adjuvant or palliative measure, have been published that may help in selecting patients who may benefit from treatment. However, the level of evidence remains low in the absence of prospective studies that are urgently needed to make significant advances in the treatment of ACC patients.

Journal Pre-proof

REFERENCES

1. Stigliano A, Chiodini I, Giordano R, Faggiano A, Canu L, Della Casa S, et al. Management of adrenocortical carcinoma: a consensus statement of the Italian Society of Endocrinology (SIE). *J Endocrinol Invest*. 2016;39(1):103–21.
2. Fassnacht M, Johanssen S, Quinkler M, Bucsky P, Willenberg HS, Beuschlein F, et al. Limited prognostic value of the 2004 International Union Against Cancer staging classification for adrenocortical carcinoma. *Cancer*. 2009;115(2):243–50.
3. Terzolo M, Daffara F, Ardito A, Zaggia B, Basile V, Ferrari L, et al. Management of adrenal cancer: A 2013 update. *J Endocrinol Invest*. 2014;37(3):207–17.
4. Fassnacht M, Libé R, Kroiss M, Allolio B. Adrenocortical carcinoma: a clinician's update. *Nat Rev Endocrinol*. 2011;7(6):323–35.
5. Bourdeau I, MacKenzie-Feder J, Lacroix A. Recent advances in adrenocortical carcinoma in adults. *Curr Opin Endocrinol Diabetes Obes*. 2013;20(3):192–7.
6. Fassnacht M, Terzolo M, Allolio B, Baudin E, Haak H, Berruti A, et al. Combination Chemotherapy in Advanced Adrenocortical Carcinoma. *N Engl J Med*. 2012 Jun 7;366(23):2189–97.
7. Fassnacht M, Berruti A, Baudin E, Demeure MJ, Gilbert J, Haak H, et al. Linsitinib (OSI-906) versus placebo for patients with locally advanced or metastatic adrenocortical carcinoma: a double-blind, randomised, phase 3 study. *Lancet Oncol*. 2015 Apr;16(4):426–35.
8. Amini N, Margonis GA, Kim Y, Tran TB, Postlewait LM, Maithel SK, et al. Curative Resection of Adrenocortical Carcinoma: Rates and Patterns of Postoperative Recurrence. *Ann Surg Oncol*. 2016;23(1):126–33.

9. Lombardi CP, Raffaelli M, Boniardi M, De Toma G, Marzano LA, Miccoli P, et al. Adrenocortical carcinoma: Effect of hospital volume on patient outcome. *Langenbeck's Arch Surg.* 2012;397(2):201–7.
10. Puglisi S, Perotti P, Cosentini D, Roca E, Basile V, Berruti A, et al. Decision-making for adrenocortical carcinoma: surgical, systemic, and endocrine management options. *Expert Rev Anticancer Ther.* 2018;18(11):1125–33.
11. Terzolo M, Angeli A, Fassnacht M, Daffara F, Tauchmanova L, Conton PA, et al. Adjuvant Mitotane Treatment for Adrenocortical Carcinoma. *N Engl J Med.* 2007;356(23):2372–80.
12. Postlewait LM, Ethun CG, Tran TB, Prescott JD, Pawlik TM, Wang TS, et al. Outcomes of Adjuvant Mitotane after Resection of Adrenocortical Carcinoma: A 13-Institution Study by the US Adrenocortical Carcinoma Group. In: *Journal of the American College of Surgeons.* NIH Public Access; 2016. p. 480–90.
13. Berruti A, Grisanti S, Pulzer A, Claps M, Daffara F, Loli P, et al. Long-term outcomes of adjuvant mitotane therapy in patients with radically resected adrenocortical carcinoma. *J Clin Endocrinol Metab.* 2017;102(4):1358–65.
14. Fassnacht M, Dekkers O, Else T, Baudin E, Berruti A, de Krijger RR, et al. European Society of Endocrinology Clinical Practice Guidelines on the Management of Adrenocortical Carcinoma in Adults, in collaboration with the European Network for the Study of Adrenal Tumors. *Eur J Endocrinol.* 2018;179(4):G1–46.
15. Tang Y, Liu Z, Zou Z, Liang J, Lu Y, Zhu Y. Benefits of Adjuvant Mitotane after Resection of Adrenocortical Carcinoma: A Systematic Review and Meta-Analysis. *Biomed Res Int.* 2018;2018:1–8.

16. Calabrese A, Basile V, Puglisi S, Perotti P, Pia A, Saba L, et al. Adjuvant mitotane therapy is beneficial in non-metastatic adrenocortical carcinoma at high risk of recurrence. *Eur J Endocrinol*. 2019;180(6):389–98.
17. Berruti A, Fassnacht M, Haak H, Else T, Baudin E, Sperone P, et al. Prognostic Role of Overt Hypercortisolism in Completely Operated Patients with Adrenocortical Cancer. *Eur Urol*. 2014 Apr;65(4):832–8.
18. Volante M, Terzolo M, Fassnacht M, Rapa I, Germano A, Sbiera S, et al. Ribonucleotide reductase large subunit (RRM1) gene expression may predict efficacy of adjuvant mitotane in adrenocortical cancer. *Clin Cancer Res*. 2012;18(12):3452–61.
19. Malandrino P, Al Ghuzlan A, Castaing M, Young J, Caillou B, Travagli J-P, et al. Prognostic markers of survival after combined mitotane- and platinum-based chemotherapy in metastatic adrenocortical carcinoma. *Endocr Relat Cancer*. 2010;17(3):797–807.
20. Puglisi S, Perotti P, Pia A, Reimondo G, Terzolo M. Adrenocortical Carcinoma with Hypercortisolism. *Endocrinol Metab Clin North Am*. 2018;47(2):395–407.
21. Libé R, Borget I, Ronchi CL, Zaggia B, Kroiss M, Kerkhofs T, et al. Prognostic factors in stage III-IV adrenocortical carcinomas (ACC): an European Network for the Study of Adrenal Tumor (ENSAT) study. *Ann Oncol*. 2015 Oct 21;26(10):2119–25.
22. Bellantone R, Ferrante A, Boscherini M, Lombardi CP, Crucitti P, Crucitti F, et al. Role of reoperation in recurrence of adrenal cortical carcinoma: results from 188 cases collected in the Italian National Registry for Adrenal Cortical Carcinoma. *Surgery*. 1997 Dec;122(6):1212–8.

23. Wood BJ, Abraham J, Hvizda JL, Alexander HR, Fojo T. Radiofrequency ablation of adrenal tumors and adrenocortical carcinoma metastases. *Cancer*. 2003 Feb 1;97(3):554–60.
24. Cazejust J, De Baère T, Auperin A, Deschamps F, Hechelhammer L, Abdel-Rehim M, et al. Transcatheter arterial chemoembolization for liver metastases in patients with adrenocortical carcinoma. *J Vasc Interv Radiol*. 2010 Oct;21(10):1527–32.
25. Baudin E, Pellegriti G, Bonnay M, Penfornis A, Laplanche A, Vassal G, et al. Impact of monitoring plasma 1,1-dichlorodiphenildichloroethane (o,p'DDD) levels on the treatment of patients with adrenocortical carcinoma. *Cancer*. 2001 Sep 15;92(6):1385–92.
26. Haak HR, Hermans J, van de Velde CJ, Lentjes EG, Goslings BM, Fleuren GJ, et al. Optimal treatment of adrenocortical carcinoma with mitotane: results in a consecutive series of 96 patients. *Br J Cancer*. 1994;69(5):947–51.
27. Hermsen IG, Fassnacht M, Terzolo M, Houterman S, Den Hartigh J, Leboulleux S, et al. Plasma concentrations of o,p'DDD, o,p'DDA, and o,p'DDE as predictors of tumor response to mitotane in adrenocortical carcinoma: Results of a retrospective ENS@T multicenter study. *J Clin Endocrinol Metab*. 2011;96(6):1844–51.
28. Megerle F, Herrmann W, Schloetelburg W, Ronchi CL, Pulzer A, Quinkler M, et al. Mitotane Monotherapy in Patients With Advanced Adrenocortical Carcinoma. *J Clin Endocrinol Metab*. 2018 Apr;103(4):1686–95.
29. Reidy Lagunes DL, Lung B, Untch BR, Raj N, Hrabovsky A, Kelly C, et al. Complete Responses to Mitotane in Metastatic Adrenocortical Carcinoma—A

- New Look at an Old Drug. *Oncologist*. 2017;22(9):1102–6.
30. Vezzosi D, Do Cao C, Hescot S, Bertherat J, Haissaguerre M, Bongard V, et al. Time Until Partial Response in Metastatic Adrenocortical Carcinoma Long-Term Survivors. *Horm Cancer*. 2018;9(1):62–9.
31. Oddie PD, Albert BB, Hofman PL, Jefferies C, Laughton S, Carter PJ. Mitotane in the treatment of childhood adrenocortical carcinoma: a potent endocrine disruptor. *Endocrinol Diabetes Metab Case Reports*. 2018;
32. Daffara F, de Francia S, Reimondo G, Zaggia B, Aroasio E, Porpiglia F, et al. Prospective evaluation of mitotane toxicity in adrenocortical cancer patients treated adjuvantly. *Endocr Relat Cancer*. 2008;15(4):1043–53.
33. Gentilin E, Tagliati F, Terzolo M, Zoli M, Lapparelli M, Minoia M, et al. Mitotane reduces human and mouse ACTH-secreting pituitary cell viability and function. *J Endocrinol*. 2013;218(3):275–85.
34. Gentilin E, Molè D, Gagliano T, Minoia M, Ambrosio MR, degli Uberti EC, et al. Inhibitory effects of mitotane on viability and secretory activity in mouse gonadotroph cell lines. *Reprod Toxicol*. 2014;45:71–6.
35. Zatelli MC, Gentilin E, Daffara F, Tagliati F, Reimondo G, Carandina G, et al. Therapeutic concentrations of mitotane (o,p α -DDD) inhibit thyrotroph cell viability and TSH expression and secretion in a mouse cell line model. *Endocrinology*. 2010;151(6):2453–61.
36. Reimondo G, Puglisi S, Zaggia B, Basile V, Saba L, Perotti P, et al. Effects of mitotane on the hypothalamic-pituitary-adrenal axis in patients with adrenocortical carcinoma. *Eur J Endocrinol*. 2017;177(4):361–7.
37. Chortis V, Taylor AE, Schneider P, Tomlinson JW, Hughes BA, O'Neil DM, et

- a1. Mitotane therapy in adrenocortical cancer induces CYP3A4 and inhibits 5 α -reductase, explaining the need for personalized glucocorticoid and androgen replacement. *J Clin Endocrinol Metab.* 2013;98(1):161–71.
38. Weigel M, Hahner S, Sherlock M, Agha A, Behan LA, Stewart PM, et al. Immediate versus modified release hydrocortisone in mitotane-treated patients with adrenocortical cancer. *Clin Endocrinol (Oxf).* 2017;86(4):499–505.

ANNOTATIONS TO REFERENCES

13. ** An updated follow-up of the 3 patient cohorts (1 mitotane-treated and 2 concomitant untreated groups) reported in 2007, now with 9 additional years of observation and better statistics (landmark analysis) confirming the benefit of adjuvant mitotane treatment on RFS.
14. ** The first comprehensive guidelines on the management of ACC patients providing clinically useful guidance for treatment of this rare tumor.
15. * A meta-analysis of the available evidence on adjuvant mitotane therapy.
16. ** The first evidence, still retrospective, that adjuvant mitotane is beneficial in patients at high risk of recurrence (i.e. patients with stage III ACC and/or ki67 index >10%).
27. ** The largest study on mitotane monotherapy for advanced ACC showing the efficacy of treatment and identifying predictive factors of response.
28. * A small sized study on mitotane monotherapy for advanced ACC showing the efficacy of treatment.
29. * A study aiming to assess the correct timing of mitotane discontinuation and the relation between activity and target plasma concentrations of the drug.
30. * A case-report of a child with ACC treated with mitotane that illustrates the multiple effects of the drug on the endocrine system.
35. * A detailed assessment of the multiple effects of mitotane on the HPA axis of ACC patients on chronic adjuvant treatment. Mitotane affects also pituitary ACTH secretion.
37. * Modified release hydrocortisone does not work as well as immediate release hydrocortisone as replacement in mitotane-treated patients.

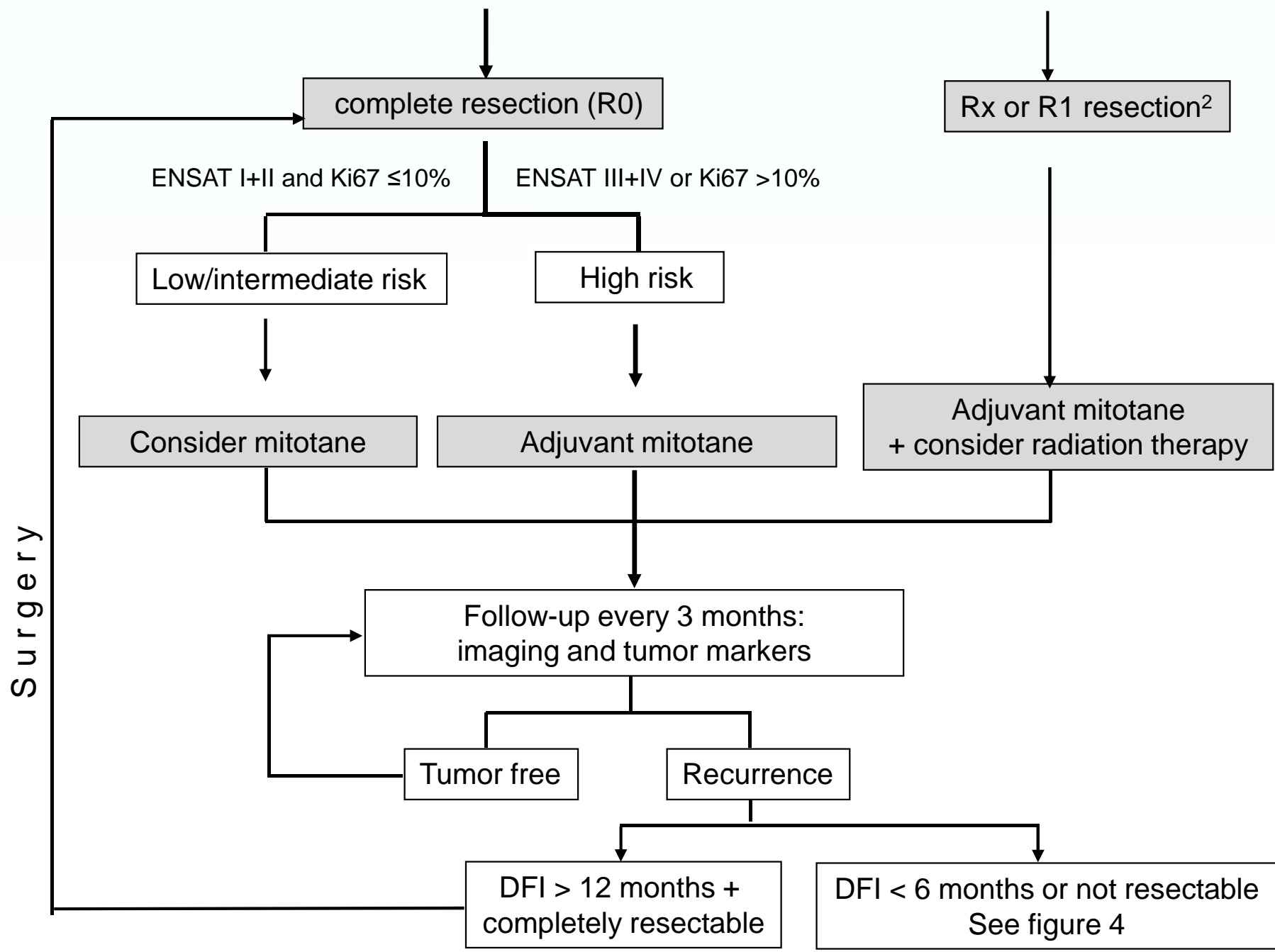
LEGENDS TO FIGURES

Figure 1. Treatment flow-chart of localized adrenocortical carcinoma (Modified from Fig. 3 of Fassnacht et al., 2018).

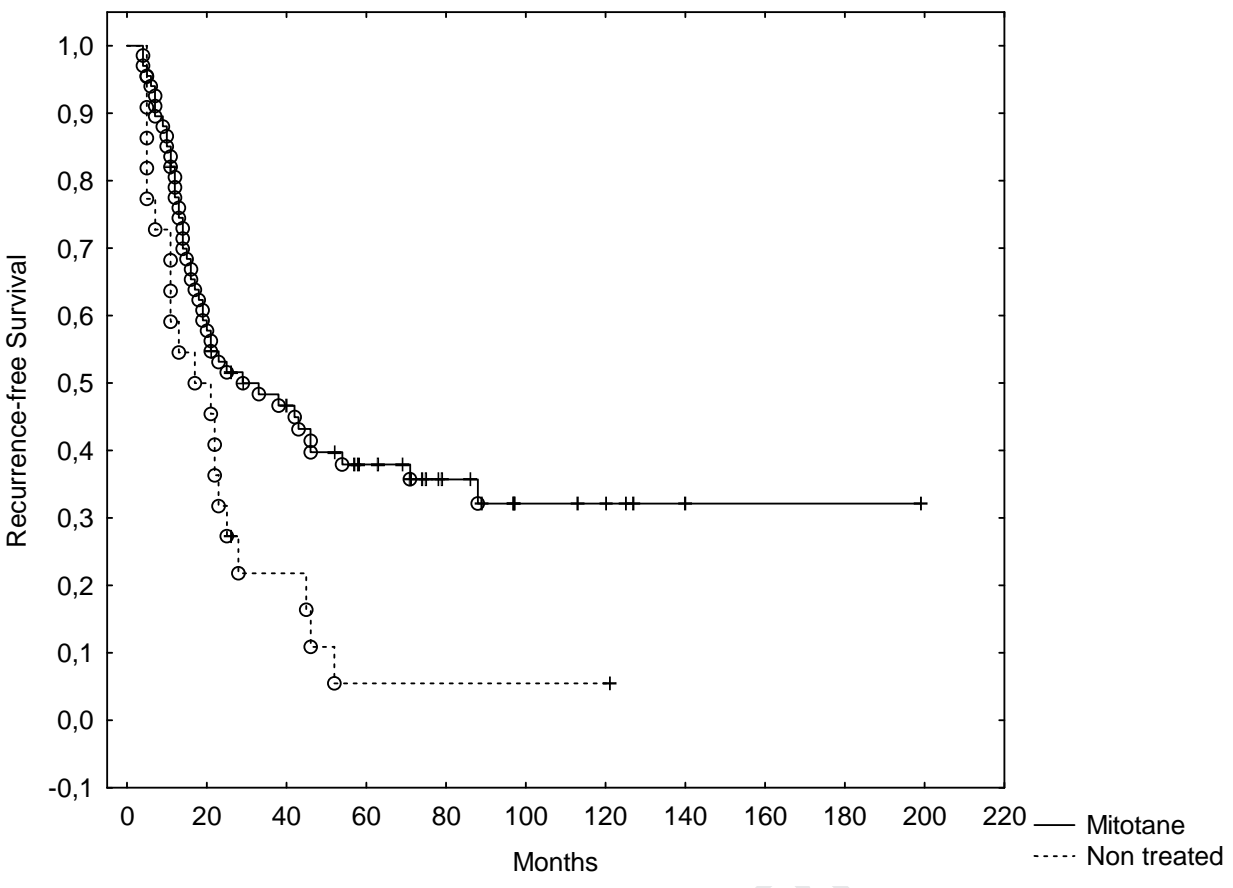
Figure 2. Recurrence-free survival of patients at high risk of recurrence (stage III ACC or $ki67 > 10\%$) treated with mitotane (solid line) or non-treated (dotted-line) following radical surgery.

Figure 3. Influence of the timing of mitotane initiation and tumour burden on overall survival (Modified from Fig. 2 of Megerle et al., 2018)

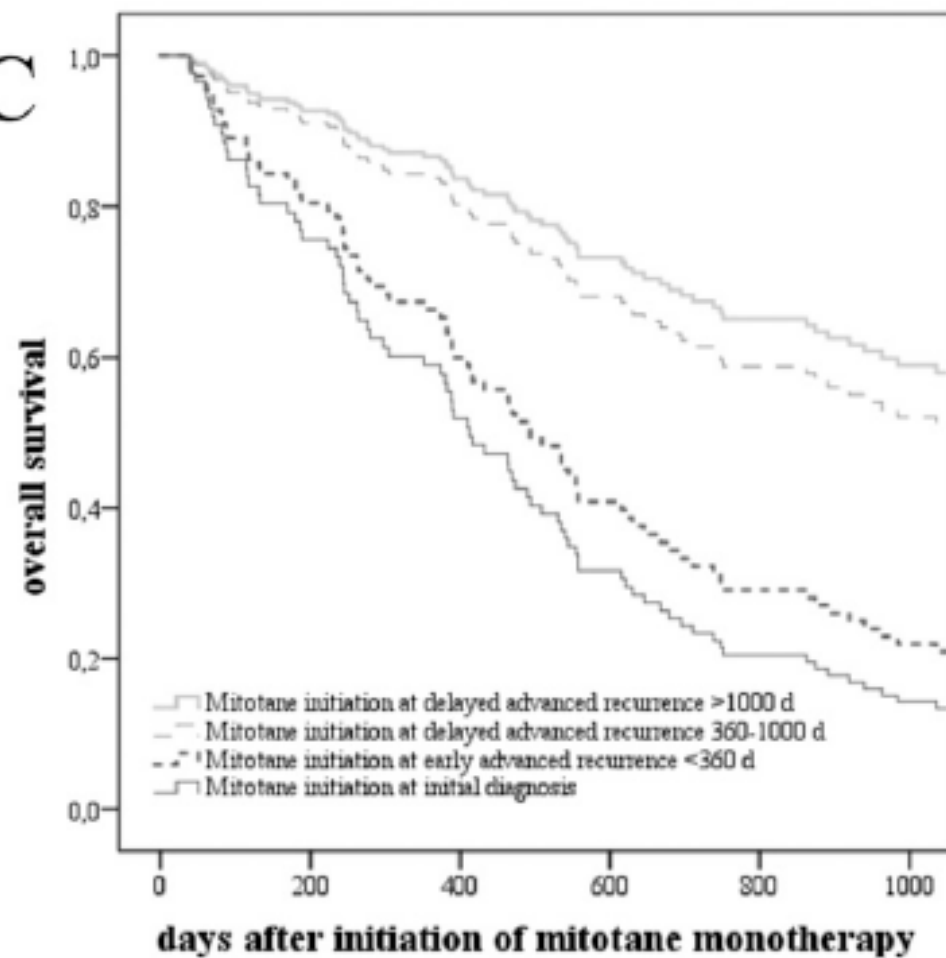
ACC amenable to complete resection



○ Completed + Censored



Journal P, I

C**D**