

The amnion muscle combined graft (AMCG) conduits in nerves repair: an anatomical and experimental study on a rat model

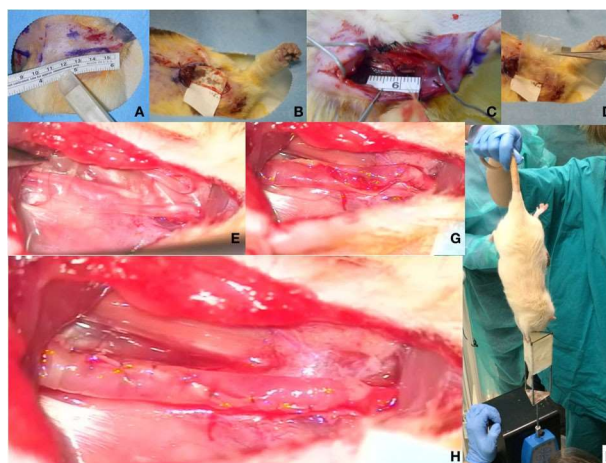
Andrea Marchesini¹ · Stefania Raimondo² · Nicola Zingaretti³ · Valentina Riccio⁴ · Bruno Battiston⁵ · Mauro Provinciali⁶ · Stefano Geuna² · Michele Riccio¹

- 1 Department of Reconstructive Plastic Surgery - Hand Surgery, Azienda Ospedaliero - Universitaria Ospedali Riuniti di Ancona, Ancona, (AN), Italy
- 2 Department of Clinical and Biological Sciences, Neuroscience Institute Cavalieri Ottolenghi, University of Torino, Orbassano, (TO), Italy
- 3 Department of Plastic and Reconstructive Surgery, University of Udine, Ospedale "S. Maria della Misericordia", Udine, (UD), Italy⁴
- 4 Department of Veterinary Medicine, School of Veterinary Surgery, Ospedale Veterinario Didattico San Sollecito, University of Camerino, Matelica, Italy
- 5 Department of Orthopedics and Traumatology - Hand surgery Unit, C.T.O. Hospital, Torino, (TO), Italy
- 6 Advanced Technology Center for Aging Research, Scientific Technological Area, IRCCS-INRCA, Experimental Animal Models for Aging Unit, Scientific Technological Area, IRCCS- INRCA, Via Birarelli 8, Ancona 60121, Italy

Abstract

The amnion muscle combined graft (AMCG) conduits showed good clinical results in peripheral nerves gap repair. It combines the human amniotic membrane with autologous skeletal muscle fibres. These results seem attributable to the biological characteristics of human amniotic membrane: Pluripotency, anti-inflammatory and low immunogenicity. We here evaluate the final outcome of nerve regeneration morphologically and functionally, across the AMCG compared to nerve autograft. Fourteen Wistar rats were divided into two groups: In Group A, including 6 rats, the left forelimb was treated performing a 1.5 cm length gap on median nerve that was then reconstructed with a reverse autograft. In Group B, including 8 rats, the gap was reconstructed with AMCG. Functional results were evaluated at 30, 60 and 90 days performing grasping tests. Morphological and stereological analyses were performed at T90 using high-resolution light microscopy and design-based stereology. The AMCG conduits revealed nerve fibres regeneration and functional recovery. Functional recovery was observed in both groups with AMCG conduits group showing lower values and a regeneration of median nerves with more myelinated fibres with the same axon size, but thinner myelin than the autograft group. Though the autograft remains the gold standard to restore wide nerve gaps, the AMCG conduit has proved to be effective in enabling nerve regeneration through a critical rat's nerve gap of 15 mm. These findings empirically support the great clinical results obtained using AMCG conduit to restore traumatic nerve's gap from 3 to 6 cm of mixed forearm nerves.

Graphical Abstract



1 Introduction

Peripheral nerve injury remains a significant clinical challenge in reconstructive microsurgery because it is a relatively common consequence of trauma, diseases, or tumour surgery. Several million people suffer from serious, traumatic, peripheral nerve injuries each year and, despite more than a century of research, the outcome of peripheral nerve repair is often poor especially in the patients where a nerve gap was done [1]. We described for the first time, in a previous article, the good clinical results of the use of Amnion Muscle Combined Graft (AMCG) conduits in peripheral nerves gap repair. It consists in the combination of the human amniotic membrane (HAM) conduit with autologous skeletal muscle fibres harvested in the site of the nerve lesion [2].

The great results obtained using AMCG have to be due to the following biological characteristics of human amniotic membrane: Pluripotency of amnion-derived cells, anti-inflammatory and low immunogenic characteristics of amniotic membrane / amnion-derived cells, non-tumorigenicity and no ethical problems with usage [3]. In addition the amnion is rich with collagen, laminin, fibronectin, and other basement membrane components that, as Davis et al. in 1987 showed, could promote the regeneration of neurons both in vitro and in vivo [4, 5].

The purpose of this report is to evaluate the final outcome of nerve regeneration, both morphologically and functionally, across the AMCG in comparison with nerve autograft that still is the gold standard of nerve gap reconstruction [6–9].

2 Materials and methods

The in vivo study was performed under European and Italian Law on animal experimentation. The used policies and procedures were in agreement with those detailed by 86/609/CEE directive. Fourteen male Wistar rats, aged from 12–14 months, (340 ± 60 g/BW) were used (Experimental Animal Models for Aging Units Research Department, I.N.R.C.A. / I.R.R.C.S., Ancona, Italy). The rats were inbred, therefore they could be considered genetically identical. The animals were divided into two groups.

In Group A, that included 6 rats, the left forelimb was treated performing a 1.5 cm length gap on median nerve that was reconstructed by means of a reverse autograft of median nerve meanwhile the right forelimb was treated by resecting the median nerve and polling the proximal stump inside the pectoralis major muscle.

In Group B, that included 8 rats, the left forelimb was treated performing a 1.5 cm length gap on the median nerve that was then reconstructed by means of AMCG; meanwhile the right forelimb was treated resecting the median nerve and polling the proximal stump inside the pectoralis major muscle as in group A.

Each animal was kept in a single cage at controlled temperature and humidity, with water and food ad libitum.

2.1 Surgical procedure and sample preparation

The animals were anesthetized with a ketamine (40 mg/ Kg) and xylazine (5 mg/kg) intramuscular injection and placed prone on a warm pad. After trichotomy, under clean condition, a bilateral cutaneous longitudinal skin incision from axilla to the elbow was performed, on both forelimbs to approach the median nerve (Figs. 1 and 2). The median nerve of the left forelimb of the rat was approached from the axillary region to the elbow and under operative microscope (at 40× magnification), the median nerve was then carefully exposed from its origin at brachial plexus to the elbow (Fig. 3). Then we performed a 1.5 cm gap on the median nerve thus resecting the median nerve 3 mm proximal to the elbow end 1.5 cm proximal to the first cut, at the level of the pectoralis major muscle (Fig. 4). Distal edge of the resected nerve's segment was marked before resection.

In group A the nerve's gap was immediately repaired by using the same resected nerve segment up side down as a nerve graft. It was sutured by means of two epineurial stitches of 9-0 monofilament nylon, with its distal edge, marked, on the proximal stump of the median nerve and by means of other two epineurial stitches of 9-0 monofilament nylon (Sharp Point AA-0105 HRM4n1/2 circle 150° M.E.T. 100 micron) between proximal stump of the nerve's fragment and the distal edge of the median nerve.

In group B the nerve's gap was reconstructed using AMCG technique. It consists of a dry amnion tube containing a muscle strip. The Human Tissue Bank of Treviso ONLUS, supplied us with the freeze dried Amniotic Membrane Patch with the approval of its ethical committee.

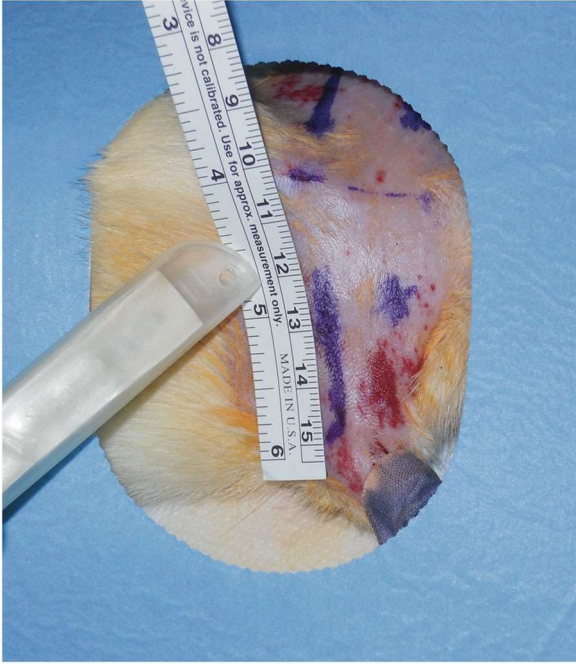

Fig. 1 Pre operative planning and surgical sterile prep

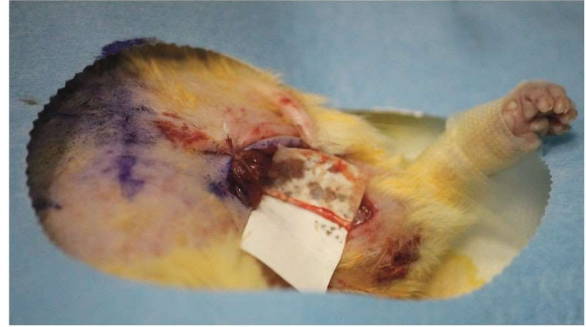

Fig. 2 Rat's median nerve dissection from axilla to elbow

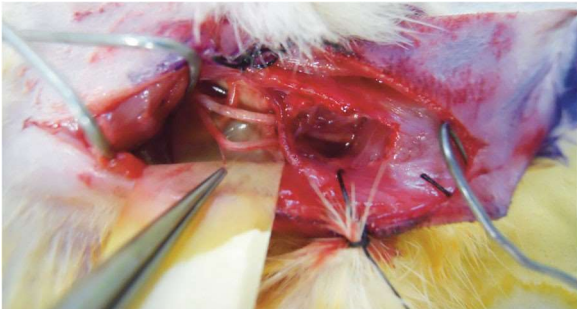

Fig. 3 Rat's median nerve isolation from axilla to elbow

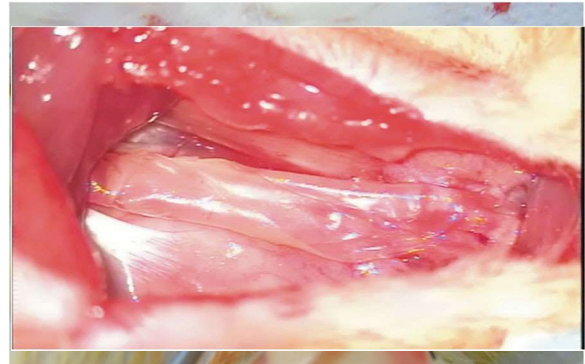


Fig. 4 Creation of 1.5 cm gap on the left median nerve

Fig. 5 Amniotic membrane bridging the nerve's gap

To obtain this conduit after rehydrating with sterile saline solution a rectangular piece of dry amnion, long 1.5 cm and width enough to create a tube of the same section of the proximal stump of the median nerve (Fig. 5), we rolled up the amnion sheet around a strip of skeletal muscle that was taken from the pectoralis major muscle taking care to respect the longitudinal course of the muscle's fibres (Fig. 6). The fragments of muscle were previously washed with saline solution to carefully remove the residues of blood. The amnion sheets are oriented with the fetal shiny surface that would be directed toward the inner surface of the finished tube. The AMCG conduit was carefully secured to the distal and proximal stumps of the nerve with two 9/0 monofilament nylon epineurial stiches and sealed with 9/0 monofilament nylon stiches (Sharpoint AA-0105HRM4n1/ 2 circle 150° M.E.T. 100 micron) between longitudinal edge of the tube (Fig. 7).

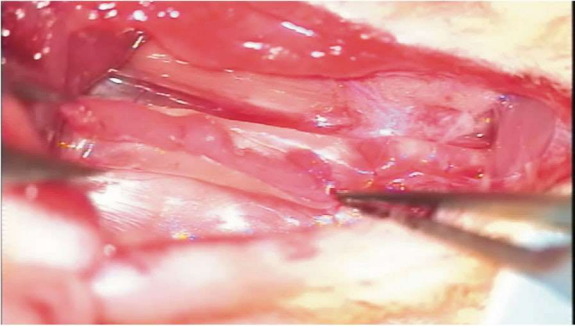


Fig. 6 Amniotic membrane conduit filled with a longitudinal strip of pectoralis m

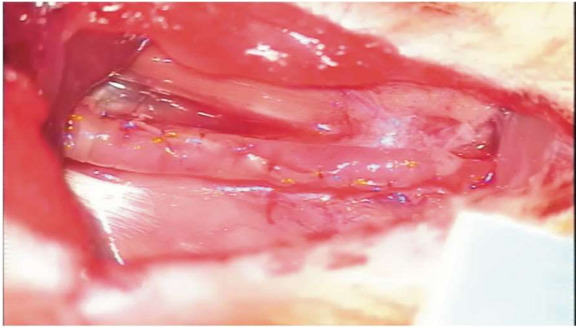
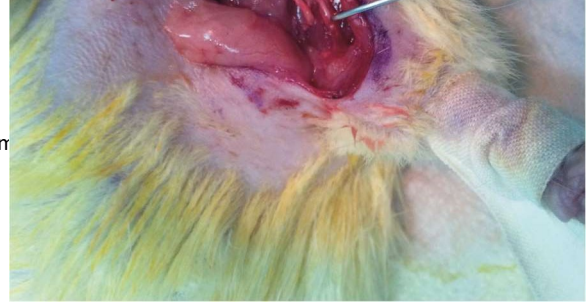

Fig. 7 Viewed of the AMCG conduit done at the end of its wrapping

In both the two groups, to prevent interferences with the grasping test device due to the use of the contralateral forelimb, the median nerve of the right forelimb was dissected for 2 cm and transected at the distal third of the brachium, 3 mm proximal to the elbow; its proximal stump was then pulled inside the pectoralis major muscle, without stretching the nerve, and sutured in the pectoralis major muscle to avoid spontaneous reinnervation by means of one stitch of 9-0 monofilament nylon (SharpPoint AA-0105 HRM4n1/2 circle 150° M.E.T. 100 micron) (Figs. 8 and 9). An antibiotic therapy with 75 mg/Kg of oxytetracycline per day for 6 days and Carprofen 0.4 mg/kg every 12 h for the first day was administered starting immediately after surgery.

2.2 Functional evaluation

Functional results were evaluated at 30, 60 and 90 days post-operatively, performing grasping test (GT) sessions according to the technique described by Bertelli JA and Mira JC in 1995 [10] and modified by Papalia et al. in 2003 [11].

2.3 Morphological and stereological analysis

At the end of the follow-up period, after 90 days, animals were sacrificed by anesthetic surplus and median nerves harvested. During the collection of the sample any scar formation around the nerve graft and AMCG conduit was clinically evaluated and scored by using a scale ranging from 0 (no scar) to 4 (extensive scarring) (Fig. 10).

The experimental sites were dissected and full thickness sample of the median nerve was collected including 3 mm of the median nerve proximal and distal to the graft (Figs. 11 and 12). The proximal edge of the sample was then marked with a single stitch before the specimen was fixed in 2.5% glutaraldehyde in 0.1M phosphate buffer (pH 7.4) for 5–6 h at 4 °C. The samples were then post-fixed in 2% osmium tetroxide for 2 h and dehydrated in passages in ethanol from 30 to 100%. After two passages of 7 min in

propylene oxide and 1 h in a 1:1 mixture of propylene oxide and Glauerts' mixture of resins, the samples were embedded in Glauerts' mixture of resins (made of equal parts of Araldite M and the Araldite Harter, HY 964). In the resin mixture, 0.5% of the plasticizer dibutylphthalate was added. For the final step, 2% of accelerator 964 was added to the resin in order to promote the polymerization of the embedding mixture.

Fig. 8 Rat's right forelimb, distal median nerve stump isolated and ready to be pulled inside pectoralis major muscle

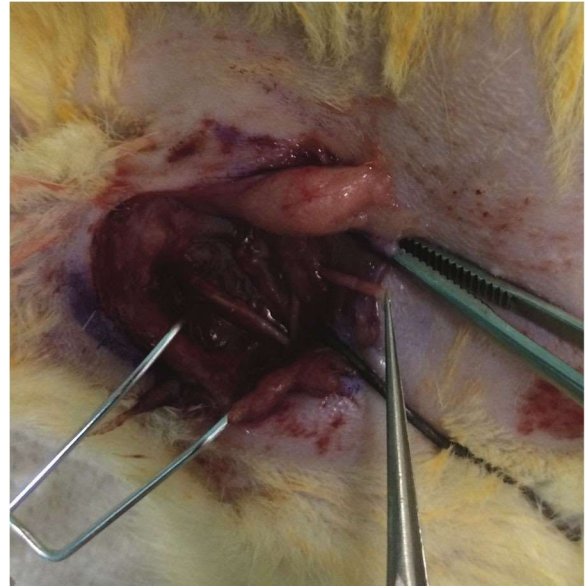


Fig. 9 Rat's right forelimb median nerve pulled and sutured inside the pectoralis major muscle to avoid contralateral regeneration

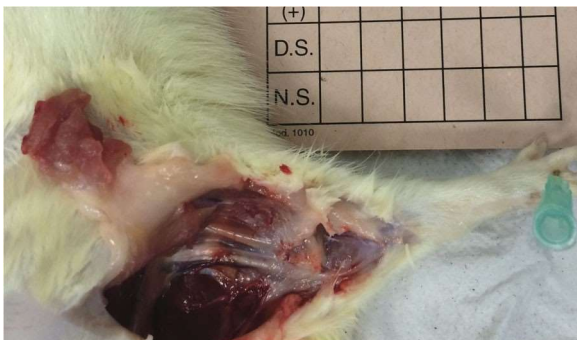

Fig. 10 Surgical dissection, 90 days after primary surgery, of the left median nerve. The image show little scarring around AMCG conduit

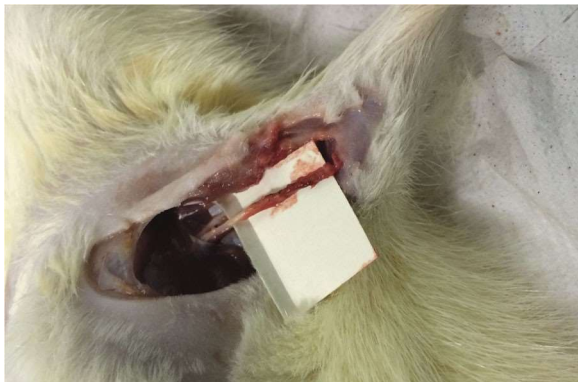

Fig. 11 Surgical dissection, 90 days after primary surgery, of the left median nerve. The image shows the appearance of the AMCG conduit that presents a homogeneous calibre

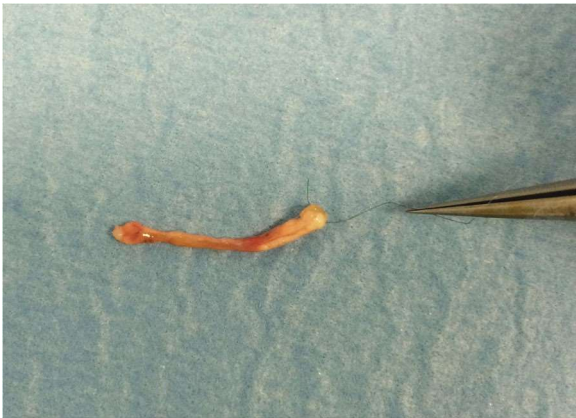

Fig. 12 AMCG conduit dissected and collected before fixation with proximal edge marked by a stitch

Semi-thin sections (2.5 μm thick) were cut using an Ultracut UCT ultramicrotome (Leica Microsystems, Wetzlar, Germany) and stained with 1% Toluidine blue for high resolution light microscopy examination and design-based stereology. A DM4000B microscope equipped with a DFC320 digital camera and an IM50 image manager system (Leica Microsystems, Wetzlar, Germany) was used for section analysis.

In order to quantify myelinated nerve fibres with high resolution light microscopy, one toluidine blue stained semi-thin section was selected and the total cross-sectional area of the whole nerve was measured. 13-15 sampling fields were selected using a systematic random sampling protocol, as previously described [12, 13]. In each sampling field, a two dimensional dissector procedure was adopted [13]. The mean total fibre number, fibre and axon diameter, myelin thickness and g-ratio were then estimated.

2.4 Statistical analysis

Statistical analysis was performed using SPSS software (New York, NY, USA). All data (functional and stereological analysis) were statistically analysed using the t-test.

3 Results

All rats survived up to the final follow-up assessment, no sign of auto mutilations was observed. The mean value of the scar evaluation was 2 in both group B and C, ranging from 1 to 3. Figures 13a–d shows representative images of regenerating nerves 90 days after surgery. Both the distal part of the median nerve repaired with the autograft technique (Figs. 13a, b) and the distal part of the median nerve repaired with AMCG (Figs. 13c, d) presented vessels and myelinated regenerating fibres with the classical fasciculate organization.

Figure 14 shows graphs representing functional and stereological analysis. Functional recovery, evaluated using grasping test 30, 60 and 90 days after surgery, was observed in both groups (Fig. 14a), even if AMCG group showed significantly ($p \leq 0.05$) lower values (T30 = 4 ± 7.7 ; T60 = 92 ± 12.6 ; T90 = 113 ± 24) than autograft group (T30 = 122 ± 81.4 ; T60 = 208 ± 62.57 ; T90 = 233 ± 47.3)

throughout the post-operative period. Moreover, the stereological analysis showed that, in AMCG group, regenerating median nerves have significantly ($p \leq 0.05$) more myelinated fibres (Fig. 14b) (24977 ± 5324) with the same axon size (Fig. 14c) ($2.32 \pm 0.12 \mu\text{m}$), but significantly ($p \leq 0.05$) thinner myelin (Fig. 14d) ($0.37 \pm 0.02 \mu\text{m}$) than autograft group (number of fibers: 10160 ± 8013 ; axon size:

$2.58 \pm 0.26 \mu\text{m}$; myelin thickness: $0.58 \pm 0.07 \mu\text{m}$). These values lead to have significantly ($p \leq 0.05$) smaller myelinated nerve fibres (Fig. 14e) ($3.07 \pm 0.15 \mu\text{m}$ vs. $3.74 \pm$

$0.31 \mu\text{m}$ of autograft group) and a significantly ($p \leq 0.05$) higher g-ratio (Fig. 14f) in the AMCG group (0.75 ± 0.01 vs. 0.66 ± 0.04 of autograft group).

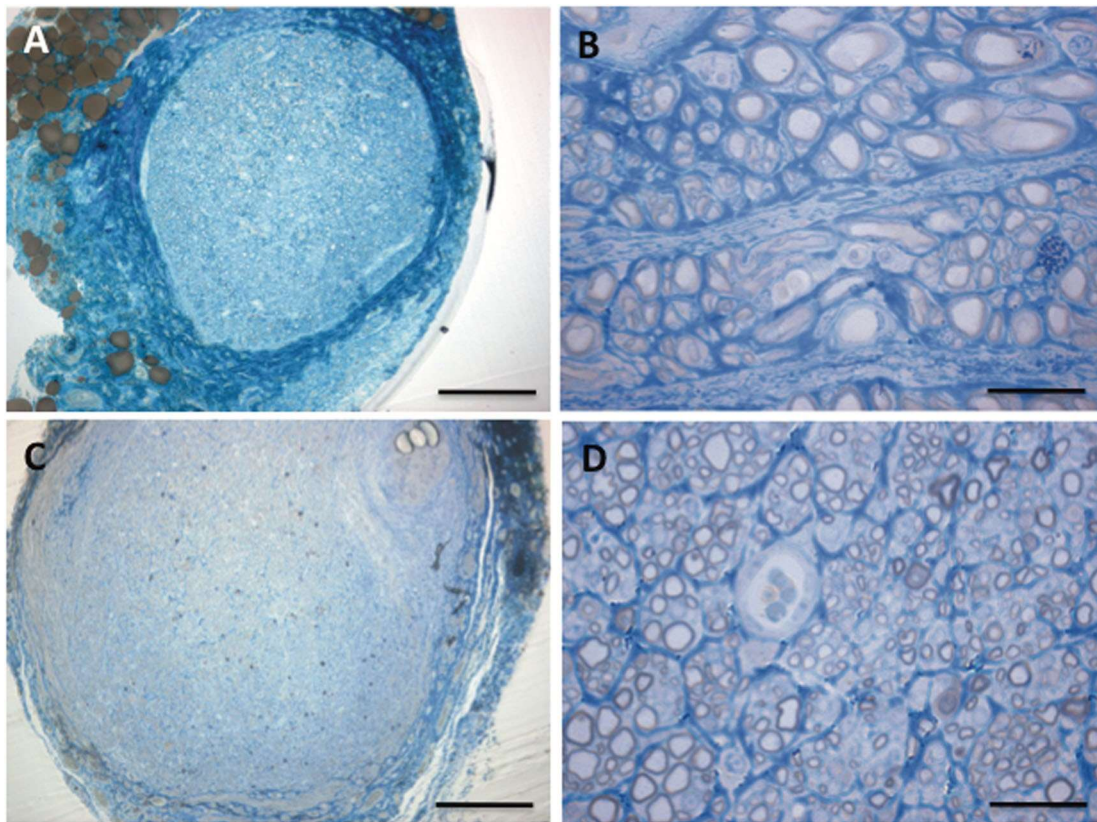


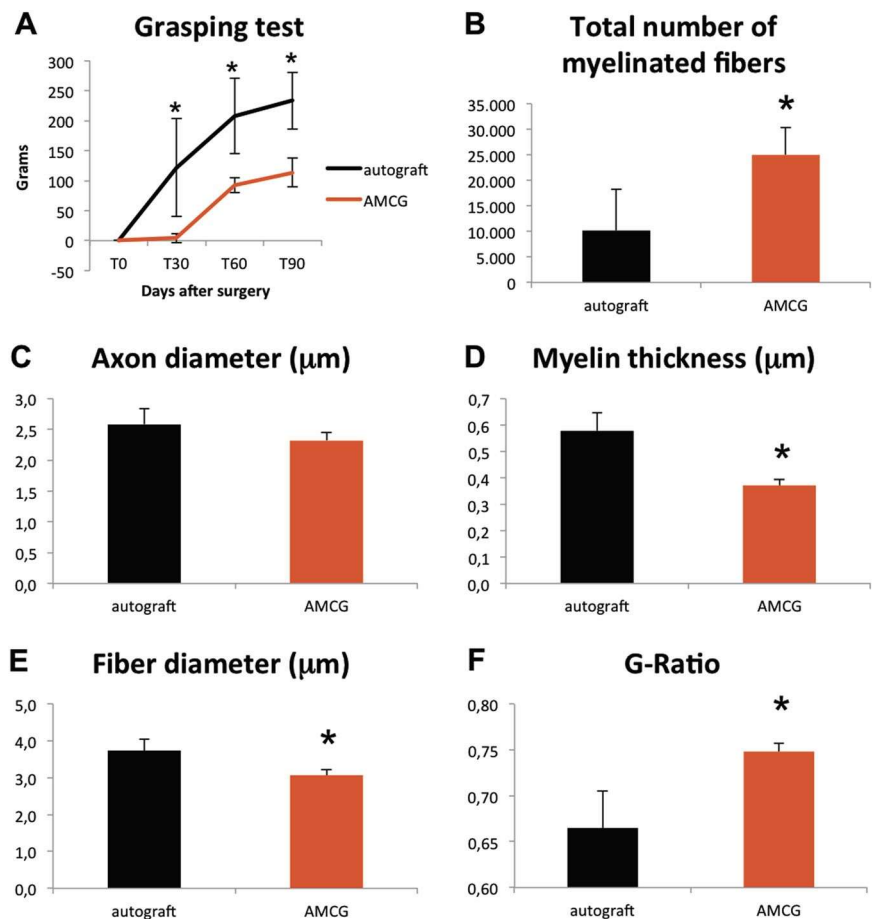
Fig. 13 Morphological analysis: Light microscope images of transversal sections of the distal part of median nerves stained with Toluidine Blue. Regenerating fibres can be observed 90 days after median nerve repair with autograft (a–b) and AMCG (c–d). Scale bars: a, c 200 μ m; b, d 20 μ m

4 Discussion

Several techniques for repairing peripheral nerves after severe injuries have been developed and different types of conduits have been experimentally examined for reconstruction of peripheral nerve defects and extensive research continues to focus on the conduit enrichment to support axonal regeneration [2, 4, 6, 8, 9, 14–20]. Literature suggest that the ideal nerve conduit, for successful nerve regeneration, should be biocompatible with the surrounding nerve tissues, causing minimal tissue inflammatory reaction; they should stimulate axonal regeneration through its entire length and they should biodegrade as the nerve regenerates. In addition to its biochemical role, each nerve conduit would also benefit from certain mechanical features: that it should be easily manufactured, readily available, semi-flexible, and easily manipulated in the surgical setting [4, 16, 17, 20–23]. But also if the conduit responds to all these features, like muscle vein combined conduit [24, 25], the main limitation of nerve regeneration inside conduits remains the distance between the stumps that may be bridged. As the distance increases, exceeding 3 cm length, regeneration and functional outcome decrease and eventually fail [9, 14, 26]. For this reason still now the autologous nerve graft is considered the gold standard technique to reconstruct nerve's gap longer than 3 cm.

In rats, the limiting distance, at which an empty conduit cannot sustain regeneration is considered 15 mm. For example with silicon tubes it was demonstrated that no axons reached the distal segment in a 15 mm defect, whereas axons readily crossed a gap up to 10 mm. Then, the success of regeneration when using empty artificial nerves conduits is limited by the length of the gap (less than 15 mm in the rat) [8, 27].

Fig. 14 a Functional results: Evaluation was performed at 30, 60 and 90 days post-operatively performing grasping test (GT). The black line show the mean results of group A (autograft) and red line show the mean results of group B (AMCG conduit). Stereological analysis: b Mean total fibre number, c axon diameter, d myelin thickness, e fiber diameter and f g-ratio were then estimated



In this study, we have investigated the capability of AMCG to sustain axonal regeneration when used to repair a critical 15 mm gap resection of the median nerve in rats, compared with autograft.

AMCG is a conduit that consists in the combination of the human amniotic membrane conduit filled with auto- logous skeletal muscle fibers with a longitudinal course inside the tube.

Our results showed that AMCG used for repairing a rat median nerve enables nerve fibres regeneration and func- tional recovery. Despite the recovery is significantly dif- ferent from autograft technique, it could be considered a great result considering that we are using a long conduit (1.5 cm). In fact despite the autograft group showed less myelinated fibers than AMCG group, the functional test results showed a better and faster recovery in this group. This statement confirms the superiority of autologous nerve graft in the reconstruction of wide mixed nerve's gap compared to all type of nerve tube showed in literature; this is due to a more specific and selective guide to the muscle reinnervation offered by the autologous nerve's graft. Nonetheless, unlike the other types of nerve conduits, the AMCG—thanks to its regenerative capacity—is able to offer a functional recovery in case of wide mixed nerve's gap, differently from other conduits which fail to restore functions. This ability of the AMCG conduit could be explained by a rapid and more specific axons regeneration due to the stimulatory effects of the important unique bio- chemical components of the amnion (i.e., collagen, laminin, and fibronectin). They not only perform as powerful neurite-promoting factors, they also provide directional guidance to the growing axons by offering an adhesive substrate to outgrowing nerve sprouts [2, 4, 5, 28–30].

In addition, the amnion tube can become fully vascu- larized and consequently supply oxygen and other nutrients to nerve cells within the conduit, whereas nerve autograft involves disconnecting the graft from its blood supply, and the silicone tube failed to produce an adequate vascular- ization [4].

This technique shares with the muscle in vein technique the important biological advantages given by muscle fibres that it avoids conduit's collapse, promotes axonal regen- eration and Schwann cell migration by means of basal lamina scaffolds and that muscle fibres and Schwann cells share a common autotrophic loop based on the neuregulin/ ErbB receptor signaling

pathway [14, 31–33]. But in addition to these three important biological elements our techniques add the regenerative role of the amnion membrane.

Conclusions

Though the autograft remains the gold standard treatment to restore wide nerve gap, the AMCG conduit has proved to be effective in allowing nerve regeneration through a critical rat's nerve gap of 15 mm. These findings support, with an experimental observation, the great clinical results obtained using AMCG conduit to restore traumatic nerve's gap wide from 3 to 6 cm of mixed, motor and sensitive, forearm nerves that we previously published [2] confirming the great regenerative value of amniotic membrane.

Compliance with ethical standards

Conflict of interest The authors declare that they have no conflict of interest.

References

1. Henry FP, Goyal NA, et al. Improving electrophysiologic and histologic outcomes by photochemically sealing amnion to the peripheral nerve repair site. *Surgery*. 2009;145:313–21. <https://doi.org/10.1016/j.surg.2008.11.005>
2. Riccio M, Pangrazi PP, Parodi PC, et al. The amnion muscle combined graft (AMCG) conduits: a new alternative in the repair of wide substance loss of peripheral nerves. *Microsurgery*. 2014;34:616–22. <https://doi.org/10.1002/micr.22306>
3. Toda A, Okabe M, Yoshida T, Nikaido T. The potential of amniotic membrane/amnion-derived cells for regeneration of various tissues. *J Pharmacol Sci*. 2007;105:215–28. <https://doi.org/10.1254/jphs.CR0070034>
4. Mohammad J, Shenaq J, Rabinovsky E, Shenaq S. Modulation of peripheral nerve regeneration: a tissue-engineering approach. The role of amnion tube nerve conduit across a 1-centimeter nerve gap. *Plast Reconstr Surg*. 2000;105:660–6.
5. Davis GE, Blaker SN, Engvall E, Varon S, Manthorpe M, Gage FH. Human amnion membrane serves as a substratum for growing axons in vitro and in vivo. *Science*. 1987;236:1106–9.
6. Siemionow M, Uygur S, Ozturk C, Siemionow K. Techniques and materials for enhancement of peripheral nerve regeneration: a literature review. *Microsurgery*. 2013;33:318–28. <https://doi.org/10.1002/micr.22104>
7. Millesi H, Meissl G, Berger A. The interfascicular nerve-grafting of the median and ulnar nerves. *J Bone Jt Surg Am*. 1972;54:727–50.
8. Deumens R, Bozkurt A, Meek MF, et al. Repairing injured peripheral nerves: bridging the gap. *Prog Neurobiol*. 2010;92:245–76. <https://doi.org/10.1016/j.pneurobio.2010.10.002>
9. Geuna S, Tos P, Titolo P, Ciclamini D, Beningo T, Battiston B. Update on nerve repair by biological tubulization. *J Brachial Plex Peripher Nerve Inj*. 2014;9:3 <https://doi.org/10.1186/1749-7221-9-3>
10. Bertelli JA, Mira JC. The grasping test: a simple behavioral method for objective quantitative assessment of peripheral nerve regeneration in the rat. *J Neurosci Methods*. 1995;58:151–5.
11. Papalia I, Tos P, Stagno d'Alcontres F, Battiston B, Geuna S. On the use of the grasping test in the rat median nerve model: a re-appraisal of its efficacy for quantitative assessment of motor function recovery. *J Neurosci Methods*. 2003;127:43–47. [https://doi.org/10.1016/S0165-0270\(03\)00098-0](https://doi.org/10.1016/S0165-0270(03)00098-0)
12. Geuna S. Appreciating the difference between design-based and model-based sampling strategies in quantitative morphology of the nervous system. *J Comp Neurol*. 2000;427:333–9.
13. Geuna S, Tos P, Battiston B, Guglielmone R, Giacobini-Robecchi MG. Morphological analysis of peripheral nerve regenerated by means of vein grafts filled with fresh skeletal muscle. *Anat Embryol*. 2000;201:475–82.
14. Tos P, Battiston B, Ciclamini D, Geuna S, Artiaco S. Primary repair of crush nerve injuries by means of biological tubulization with muscle-vein-combined grafts. *Microsurgery*. 2012;32:358–63. <https://doi.org/10.1002/micr.21957>
15. Merolli A, Rocchi L, Wang XM, Cui FZ. Peripheral nerve regeneration inside collagen-based artificial nerve guides in humans. *J Appl Biomater Funct Mater*. 2015;13(1):61–5. <https://doi.org/10.5301/jabfm.5000188>.
16. Seckel BR, Chiu TH, Nyilas E, Sidman RL. Nerve regeneration through synthetic biodegradable nerve guides: regulation by the target organ. *Plast Reconstr Surg*. 1984;74:173–81.
17. Fields RD, Le Beau JM, Longo FM, Ellisman MH. Nerve regeneration through artificial tubular implants. *Prog Neurobiol*. 1989;33:87–134.
18. Valentini RF, Aebischer P, Winn SR, Galletti PM. Collagen- and laminin-containing gels impede peripheral nerve regeneration through semipermeable nerve guidance channels. *Exp Neurol*. 1987;98:350–6.
19. Valentini RF, Sabatini AM, Dario P, Aebischer P. Polymer electret guidance channels enhance peripheral nerve regeneration in mice. *Brain Res*. 1989;480:300–4.
20. Heath CA, Rutkowski GE. The development of bioartificial nerve grafts for peripheral-nerve regeneration. *Trends Biotechnol*. 1998;16:163–8.
21. Mackinnon SE, Hudson AR, Falk RE, Hunter DA. The nerve allograft response—an experimental model in the rat. *Ann Plast Surg*. 1985;14:334–9.
22. Bora FW Jr, Bednar JM, Osterman AL, Brown MJ, Sumner AJ. Prosthetic nerve grafts: a resorbable tube as an alternative to autogenous nerve grafting. *J Hand Surg Am*. 1987;12(5 Part1):685–92.
23. Chiu DT, Janecka I, Krizek TJ, Wolff M, Lovelace RE. Auto-genous vein graft as a conduit for nerve regeneration. *Surgery*. 1982;91:226–33.

24. Battiston B, Tos P, Cushway TR, Geuna S. Nerve repair by means of vein filled with muscle grafts I. Clinical results. *Microsurgery*. 2000;20:32–36.
25. Battiston B, Tos P, Geuna S, Giacobini-Robecchi MG, Gugliel-mone R. Nerve repair by means of vein filled with muscle grafts. II. *Morphol Anal Regen Microsurg*. 2000;20:37–41.
26. Yannas IV, Hill BJ. Selection of biomaterials for peripheral nerve regeneration using data from the nerve chamber model. *Biomaterials*. 2004;25:1593–1600. [https://doi.org/10.1016/S0142-9612\(03\)00505-2](https://doi.org/10.1016/S0142-9612(03)00505-2)
27. Lundborg G, Dahlin LB, Danielsen N, et al. Nerve regeneration in silicone chambers: influence of gap length and of distal stump components. *Exp Neurol*. 1982;76:361–75.
28. Akle CA, Adinolfi M, Welsh KI, Leibowitz S, McColl I. Immunogenicity of human amniotic epithelial cells after transplantation into volunteers. *Lancet*. 1981;2:1003–5.
29. Banerjee A, Nürnberger S, Hennerbichler S, et al. In toto differentiation of human amniotic membrane towards the Schwann cell lineage. *Cell Tissue Bank*. 2013;15:227–39. <https://doi.org/10.1007/s10561-013-9401-1>
30. Venkatachalam S, Palaniappan T, Jayapal PK, Neelamegan S, Rajan SS, Muthiah VP. Novel neurotrophic factor secreted by amniotic epithelial cells. *Biocell*. 2009;33(2):81–9. Aug.
31. Raimondo S, Nicolino S, Tos P, et al. Schwann cell behavior after nerve repair by means of tissue-engineered muscle-vein combined guides. *J Comp Neurol*. 2005;489:249–59. <https://doi.org/10.1002/cne.20625>
32. Tos P, Battiston B, Nicolino S, et al. Comparison of fresh and predegenerated muscle-vein-combined guides for the repair of rat median nerve. *Microsurgery*. 2007;27:48–55. <https://doi.org/10.1002/micr.20306>
33. Geuna S, Raimondo S, Nicolino S, et al. Schwann-cell proliferation in muscle-vein combined conduits for bridging rat sciatic nerve defects. *J Reconstr Microsurg*. 2003;19:119–23. <https://doi.org/10.1055/s-2003-37818>. discussion124