



Published in final edited form as:

*Am J Hematol.* 2015 November ; 90(11): E211–E212. doi:10.1002/ajh.24143.

## **t(9;22) as secondary alteration in core-binding factor *de novo* acute myeloid leukemia**

**Candida Vitale<sup>1</sup>, Xinyan Lu<sup>2</sup>, Balkees Abderrahman<sup>1</sup>, Koichi Takahashi<sup>1</sup>, Farhad Ravandi<sup>1</sup>, and Elias Jabbour<sup>1</sup>**

1

2

The presence of specific recurrent karyotype abnormalities is one of the most powerful prognostic predictors in acute myeloid leukemia (AML). AML with inv(16) is categorized by the World Health Organization in the group of core-binding factors (CBF) AML, and it is associated with a favorable prognosis. From the molecular standpoint, the inv(16) leads to the formation of the *CBFB-MYH11* fusion gene, which has a role in the disruption of normal hematopoiesis and in the inactivation of tumor suppressor genes needed for neoplastic transformation. Clonal evolution is generally considered a sign of disease progression in AML, but additional chromosomal aberrations seems not to impact on prognosis in CBF AML.

Translocation (9;22) and its derivative *BCR-ABL1* fusion protein are the hallmark of chronic myeloid leukemia (CML), they are often found in acute lymphoblastic leukemia, but they are uncommon in AML. The concomitant occurrence of inv(16) and t(9;22) is an extremely rare event, and it has been described mainly in the setting of chronic myeloid leukemia in blastic phase (BP-CML). AML with a co-presence of inv(16) and t(9;22) in all aberrant metaphases are traditionally categorized as BP-CML, whereas it is conceivable that cases in which the t(9;22) is present in only a fraction on the inv(16) positive metaphases are *de novo* AML.

To date, there are only 11 cases described in the literature in which the t(9;22) definitely represents a secondary event in an inv(16) AML [1-10]. The reported FAB subtype is always M4/M4Eo, except for one case, which was M1 [5], and all patients presented with characteristic inv(16)(p13.1q22) and t(9;22)(q34;q11.2). Additional cytogenetic abnormalities were reported in four of the patients [4, 8-10]. The produced *BCR-ABL1* chimeric protein was the p190 variant in all cases except one, which was positive for the p210 variant [8].

Here we report the case of a 70-year-old male with a history of hypertension and atrial fibrillation, who presented with fatigability and shortness of breath. A complete blood count showed anemia (Hemoglobin 8.5 g/dL) and thrombocytopenia (platelets  $12 \times 10^9/L$ ), with a white blood cell count of  $90 \times 10^9/L$ . A peripheral blood smear showed 26% blasts with

monocytic appearance. A bone marrow smear showed approximately 20% blasts, intermediate to large in size with moderately abundant cytoplasm, no Auer rods, unfolded nuclei, and occasional prominent nucleoli. Eosinophils were increased at 10%. Stains on bone marrow aspirate showed myeloperoxidase positivity. Bone marrow biopsy confirmed the diagnosis of AML. The immunophenotype by flow cytometry showed that blasts were positive for CD4, CD13, CD33 dim, CD34, CD38, CD45 dim, CD64, CD117, CD123, HLA-DR, TdT dim, and negative for CD2, CD3, CD5, CD7, CD10, CD19, CD22, CD36, CD41 and CD56. Cytogenetic analysis revealed 46,XY,inv(16)(p13.1q22)[3]/46,idem,t(9;22)(q34;q11.2)[17] (Figure 1 A and B). FISH showed a consistent result: *CBFB* rearrangement was detected in 89% interphases and *BCR-ABL1* rearrangement in 78% interphases (Figure 1 C and D). Quantitative RT-PCR confirmed the presence of a *CBFB-MYH11* fusion transcript (ratio to *ABL1* >100), and an e1a2 *BCR-ABL1* fusion transcript coding for the 190 kDa *BCR-ABL1* fusion protein (ratio to *ABL1* >94.95). These results strongly suggest that in our case inv(16) is the primary event, whereas the inv(16) t(9;22) clone should be considered the secondary clone. A next generation sequencing-based analysis for the detection of somatic mutations in the coding sequence of a total of 28 genes considered relevant in leukemia was also performed and detected no mutations. Genes analyzed were: *ABL1*, *ASXL1*, *BRAF*, *DNMT3A*, *EGFR*, *EZH2*, *FLT3*, *GATA1*, *GATA2*, *HRAS*, *IDH1*, *IDH2*, *IKZF2*, *JAK2*, *KIT*, *KRAS*, *MDM2*, *MLL*, *MPL*, *MYD88*, *NOTCH1*, *NPM1*, *NRAS*, *PTPN11*, *RUNX1*, *TET2*, *TP53*, *WT1*.

The patient was treated with a high-dose cytarabine-based regimen (FLAG-Ida) including fludarabine (30 mg/m<sup>2</sup> IV daily, Days 1-5), cytarabine (2 g/m<sup>2</sup> IV daily, Days 1-5), idarubicin (6 mg/m<sup>2</sup> IV daily, Days 3-4), and filgrastim (5 mcg/kg IV daily, Days 2-5), in combination with dasatinib (70 mg PO daily, days 1-14). Treatment was overall well tolerated. After the induction treatment, he achieved a complete remission with incomplete platelet recovery (CRp), with a bone marrow aspirate done at day 21 showing a cellular bone marrow with granulocytic predominance and 2% blasts. Minimal residual disease evaluated by flow cytometry was negative. FISH was negative for *CBFB* and *BCR-ABL1* rearrangements. A low level e1a2 *BCR-ABL1* fusion transcript was detected (ratio to *ABL1*: <0.01) and *CBFB-MYH11* fusion transcript was considerably decreased, but still detectable (ratio to *ABL1*: 0.74). Since the patient was not considered a candidate for allogeneic stem cell transplantation, it was decided to pursue consolidation cycles at lower doses, in combination with dasatinib 70 mg daily concomitantly with the consolidation and thereafter infinitely as monotherapy. The patient received a total of four consolidation cycles, which were overall rather well tolerated besides recurrent episodes of rectal bleeding. The patient maintained the CRp, and at the last bone marrow evaluation, performed at 5 months from the initial diagnosis. The *BCR-ABL1* fusion transcript study showed a complete molecular remission, and *CBFB-MYH11* ratio to *ABL1* was further reduced to 0.06.

It has been shown that in patients with CBF AML additional chromosomal abnormalities do not affect the patient outcome. However, that may not be the case when the additional abnormality is the t(9;22), an event which has been estimated to characterize <1% of CBF AML. Moreover, the clinical behavior of *de novo* CBF AML acquiring the Philadelphia chromosome as an additional subsequent clonal alteration may be different compared to the

cases in which the t(9;22) is a driving mutation and the inv(16) is the manifestation of clonal evolution.

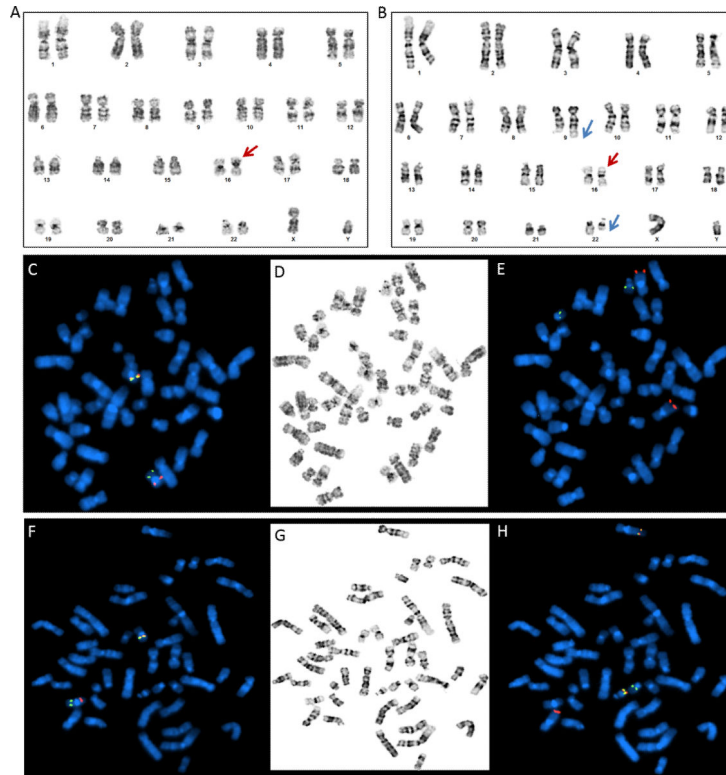
The availability of tyrosine kinase inhibitors (TKI) specifically targeting *BCR-ABL1* could potentially have an impact on the outcome of patients with CBF AML and secondary t(9;22), as suggested by anecdotal published cases [3, 6, 7, 9, 10]. The choice of a second or third generation TKI should balance the toxicity profile, the availability of the drug, and the efficacy data extrapolated from *in vitro* studies and from other disease settings. Undoubtedly, the small number of patients presenting with t(9;22) as a secondary alteration in inv(16) AML does not allow to draw a definitive conclusion on the impact of this molecular alteration on patients' prognosis and on the efficacy of different treatment approaches.

## Acknowledgements

The University of Texas MD Anderson Cancer Center is supported in part by the National Institutes of Health through a Cancer Center Support Grant (P30 CA16672).

## REFERENCES

1. Secker-Walker LM, Morgan GJ, Min T, et al. Inversion of chromosome 16 with the Philadelphia chromosome in acute myelomonocytic leukemia with eosinophilia. Report of two cases. *Cancer genetics and cytogenetics*. 1992; 58:29–34. [PubMed: 1728947]
2. Miura I, Takatsu H, Yamaguchi A, et al. Standard Ph chromosome, t(9;22)(q34;q11), as an additional change in a patient with acute myelomonocytic leukemia (M4Eo) associated with inv(16)(p13q22). *American journal of hematology*. 1994; 45:94–96. [PubMed: 8250017]
3. Cividin M, Brizard F, Sorel N, et al. p190(BCR-ABL) rearrangement as a secondary change in a case of acute myelo-monocytic leukemia with inv(16)(p13q22). *Leukemia research*. 2004; 28:97–99. [PubMed: 14630086]
4. Tirado CA, Valdez F, Klesse L, et al. Acute myeloid leukemia with inv(16) with CBFβ-MYH11, 3'CBFβ deletion, variant t(9;22) with BCR-ABL1, and del(7)(q22q32) in a pediatric patient: case report and literature review. *Cancer genetics and cytogenetics*. 2010; 200:54–59. [PubMed: 20513535]
5. Svaldi M, Lanthaler A, Venturi R, et al. Simultaneous occurrence of bcr-abl and inv16 in a case of M1 acute myeloid leukemia. *Leukemia*. 2001; 15:695. [PubMed: 11368385]
6. Bacher U, Haferlach T, Alpermann T, et al. Subclones with the t(9;22)/BCR-ABL1 rearrangement occur in AML and seem to cooperate with distinct genetic alterations. *British journal of haematology*. 2011; 152:713–720. [PubMed: 21275954]
7. Roth CG, Contis L, Gupta S, et al. De novo acute myeloid leukemia with Philadelphia chromosome (BCR-ABL) and inversion 16 (CBFβ-MYH11): report of two cases and review of the literature. *Leuk Lymphoma*. 2011; 52:531–535. [PubMed: 21281226]
8. Dai HP, Xue YQ, Wu LL, et al. p210 BCR/ABL1 as a secondary change in a patient with acute myelomonocytic leukemia (M4Eo) with inv(16). *International journal of hematology*. 2012; 96:814–817. [PubMed: 23054652]
9. Han E, Lee H, Kim M, et al. Characteristics of hematologic malignancies with coexisting t(9;22) and inv(16) chromosomal abnormalities. *Blood research*. 2014; 49:22–28. [PubMed: 24724063]
10. Kim M, Lim J, Kim Y, et al. A case of therapy-related acute myeloid leukemia associated with inv(16), with subsequent development of t(9;22). *Leukemia*. 2006; 20:746–748. [PubMed: 16437154]



**Figure 1.**

Karyotype of bone marrow blasts at diagnosis showed a clone with  $inv(16)(p13.1q22)$  only (A), and a clone with both  $inv(16)(p13.1q22)$  and  $t(9;22)(q34;q11.2)$  (B). Red arrows indicate the  $inv(16)$  and blue arrows indicate  $t(9;22)$ . Panels C-E and F-H represent FISH analysis on metaphases corresponding to the karyotypes in panels A and B, respectively. C: Metaphase FISH using dual color break apart probe showing  $inv(16)$  with CBF $\beta$  rearrangement (split red/green signal). D: Corresponding G-banded metaphase. E: Sequential FISH using BCR-ABL1 dual color extra signal probe on the same metaphase showing no evidence of BCR-ABL1 fusion (ABL1: red; BCR: green). F: Metaphase FISH using dual color break apart probe showing  $inv(16)$  with CBF $\beta$  rearrangement (split red/green signal). G: Corresponding G-banded metaphase. H: Sequential FISH using BCR-ABL1 dual color extra signal probe on the same metaphase showing BCR-ABL1 fusion (ABL1: red; BCR: green).