

# Eltrombopag for the Treatment of Refractory Pure RBC Aplasia after Major ABO Incompatible Hematopoietic Stem Cell Transplantation

Alessandro Busca<sup>1,\*</sup>, Chiara Dellacasa<sup>1</sup>, Luisa Giaccone<sup>1</sup>, Sara Manetta<sup>1</sup>, Lucia Biale<sup>2</sup>, Laura Godio<sup>3</sup>, Semra Aydin<sup>4</sup>, Moreno Festuccia<sup>1</sup>, Lucia Brunello<sup>1</sup>, Benedetto Bruno<sup>1</sup>

<sup>1</sup> A.O.U. Città della Salute e della Scienza, Dipartimento di Oncologia, SSD Trapianto allogenico di cellule staminali, Turin, Italy

<sup>2</sup> Banca del Sangue, Servizio di Immunoematologia, A.O.U. Città della Salute e della Scienza Turin, Italy

<sup>3</sup> Anatomia Patologica, A.O.U. Città della Salute e della Scienza and University of Turin, Italy

<sup>4</sup> A.O.U. Città della Salute e della Scienza, Dipartimento di Oncologia, Ematologia, Turin, Italy

## ABSTRACT

Pure RBC aplasia (PRCS) is a well-recognized complication after allogeneic hematopoietic stem cell transplantation (HSCT). Many therapeutic options are available to treat this condition, including erythropoietin, rituximab, bortezomib, plasma exchange, immunoadsorption, donor lymphocyte infusion, mesenchymal stem cells, antithymocyte globulin, and high-dose steroids; however, treatment outcomes are often variable and can sometimes lead to disappointing results. In this brief article we report our experience with 2 patients with PRCA after major ABO-incompatible HSCT who were resistant to multiple therapeutic interventions and who eventually benefited from treatment with eltrombopag, a thrombopoietin mimetic approved by the US Food and Drug Administration for the treatment of patients with immune thrombocytopenic purpura or severe aplastic anemia refractory to immunosuppressive agents or not eligible for HSCT. Data from these 2 patients show that eltrombopag was effective in treating erythroid aplasia and transfusion dependence after HSCT in patients who did not benefit from multiple previous treatments. Moreover, eltrombopag was well tolerated, with only a transient thrombocytosis requiring dose adjustment and no evidence of clonal evolution. Based on the positive results obtained in these 2 patients, we suggest that eltrombopag may have a favorable effect on unilineage cytopenias such as PRCA. Further studies in a large proportion of patients are mandatory to confirm these preliminary results.

## INTRODUCTION

Pure RBC aplasia (PRCA) is an uncommon complication of ABO major mismatched allogeneic hematopoietic stem cell transplantation (HSCT), occurring in 7.5% to 16% of patients [1-4]. PRCA has been considered as the result of B lymphocytes of recipient origin producing isohemoagglutinins, which can interfere with the engraftment of donor erythroid cells, and is characterized by delayed RBC recovery after transplantation, anemia, and reticulocytopenia [5].

The diagnosis is confirmed by the absence of erythroblasts from otherwise morphologically normal bone marrow, once other causes, for instance viral infections and drug toxicity, have been excluded. A number of risk factors have been associated with the development of PRCA, including anti-A isoagglutinins, the use of reduced-intensity conditioning,

cyclosporine-based graft-versus-host disease (GVHD) prophylaxis, the absence of GVHD, and grafts from matched sibling donors [3-5].

Although several patients may recover spontaneously, others need more aggressive treatment strategies to avoid extensive RBC transfusions and related iron overload [6]. Rapid tapering of immunosuppressive agents, erythropoietin (recombinant human erythropoietin [rHuEPO]), rituximab, bortezomib, plasma exchange (PEX), immunoadsorption, donor lymphocyte infusion, mesenchymal stem cells, antithymocyte globulin, and high-dose steroids have been used for treatment of PRCA; however, results reported in the literature with these therapeutic options are largely variable or even disappointing in many cases [3,6-18].

Eltrombopag is an oral thrombopoietic receptor agonist that is approved by the US Food and Drug Administration for the treatment of patients with immune thrombocytopenic purpura [19,20] and severe aplastic anemia (SAA) refractory to immunosuppressive treatments or not eligible for HSCT [21-23]. We hypothesized that eltrombopag might have activity in patients with PRCA based on the favorable multilineage responses observed in patients with SAA, particularly with extended therapy [22]. Here we report our experience with the use of eltrombopag for the treatment

of 2 patients with PRCA after major ABO-incompatible HSCT.

## RESULTS

Between January 2012 and July 2017, 321 patients with hematologic disorders underwent an allogeneic HSCT at the Stem Cell Transplant Center of the AOU Citta' della Salute e della Scienza of Turin. Eight of 97 (8%) assessable patients receiving major ( $n = 76$ ) or bidirectional ( $n = 21$ ) ABO-incompatible grafts developed a PRCA. In 2 patients a prompt erythroid response was observed after 3 and 5 cycles of PEX, respectively, in 1 case associated with rHuEPO; 3 patients responded to rHuEPO alone. One patient failed to demonstrate a response to PEX and rHuEPO, and eventually PRCA resolved after 4 doses of rituximab. Two patients who developed PRCA resistant to multiple therapeutic interventions are herein described.

### Patient 1

A 48-year-old man with high-risk acute myeloid leukemia (*FLT3* positive with *NPM1* mutation and extramedullary involvement) in first complete remission received a peripheral blood HSCT from an HLA matched unrelated donor in January 2016. The conditioning regimen was myeloablative, and GVHD prophylaxis consisted of antithymocyte globulin, cyclosporine, and short-course methotrexate. Donor and recipient blood groups were A negative and O positive, respectively. Pretransplant anti-A isohemoagglutinin titer was 1:512. RBC reduction of the apheresic product was not performed because of the low hematocrit value.

Neutrophil and platelet engraftment occurred on days +16 and +17 post-HSCT, respectively. The patient received the last RBC unit on day +13. However, since day +37 the patient developed a transfusion-dependent anemia, with remarkable reticulocytopenia (.09% absolute value) and a transfusion need of about 2 RBC units every week; however, anti-A isohemoagglutinin titer was still 1:512.

On day +47 the patient started treatment with theta-erythropoietin (EPO) 40,000 U/wk, with any appreciable response after 6 weeks of treatment. On day +90 the bone marrow biopsy documented the presence of a PRCA, with a global cellularity of about 50%, whereas WBC and platelet precursors were well represented. Viral infections (cytomegalovirus; Epstein-Barr virus; human herpesvirus-6, -7, and -8; herpes simplex virus 1 and 2; and parvovirus B19) were excluded. Neither signs of hemolysis nor iron or vitamin deficiencies were detected. On day +120 reticulocytopenia was still present, and anti-A isohemoagglutinin titer was 1:256; neutrophils were at the lower normal value, whereas the number of platelets dropped to  $24,000/\text{mm}^3$ . No clinical signs of acute GVHD were present.

Because of a persistent lack of erythroid response, the patient received 5 PEX procedures from day +124 every other day. Theta-EPO 40,000 U was administered after each PEX and then continued weekly for 3 weeks. PEX procedures were rather well tolerated, except for an episode of hypofibrinogenemia treated with plasma replacement. After PEX procedures the anti-A isohemoagglutinin titer dropped to 1:64; however, no erythroid response was observed.

At 6 months post-HSCT iron chelation therapy (ICT) with deferasirox (DFX) was started with a ferritin value of 4437 ng/mL. On day +234, rituximab 375 mg/m<sup>2</sup>/wk was administered for 4 consecutive weeks, together with theta-EPO 40,000 U once a week. However, the treatment did not result in any beneficial effect in terms of transfusion dependence,

reticulocytopenia, or thrombocytopenia. DFX was temporarily withheld because of a high creatinine value and grade 3 neutropenia requiring granulocyte colony-stimulating factor administration, and the patient was eventually switched to deferoxamine (DFO) after 100 days of treatment. Eleven months post-HSCT, rHuEPO was definitively stopped due to lack of response.

At 1 year post-transplant bone marrow biopsy showed a dishomogeneous representation of myeloid and erythroid lineage with mild megakaryocytic hyperplasia; global cellularity ranged from 10% to 60%, and chimerism was 100% full donor, because of the presence of a pancytopenia, we decided to start the thrombopoietin (TPO) mimetic eltrombopag at the dose of 75 mg/day for the first 2 weeks and then increase to 150 mg/day. After 1 month of treatment the patient showed a significant increase of neutrophils and platelets and a reduction of transfusion support to 1 RBC unit per week. After 2 months of treatment the patient was independent from transfusions, with a hemoglobin value of 11.3 g/dL and normal neutrophils and platelets counts. After 4 months of treatment eltrombopag was discontinued with a hemoglobin value of 15.4 gr/dL; thrombocytosis has never been observed.

At the present, the patient has been off eltrombopag treatment for 8 months by now with normal hemoglobin levels and neutrophil counts. The bone marrow biopsy showed a normal cellularity (80%) with good trilinear representation. No cytogenetic abnormalities have been detected. Figure 1A shows the time course of patient 1.

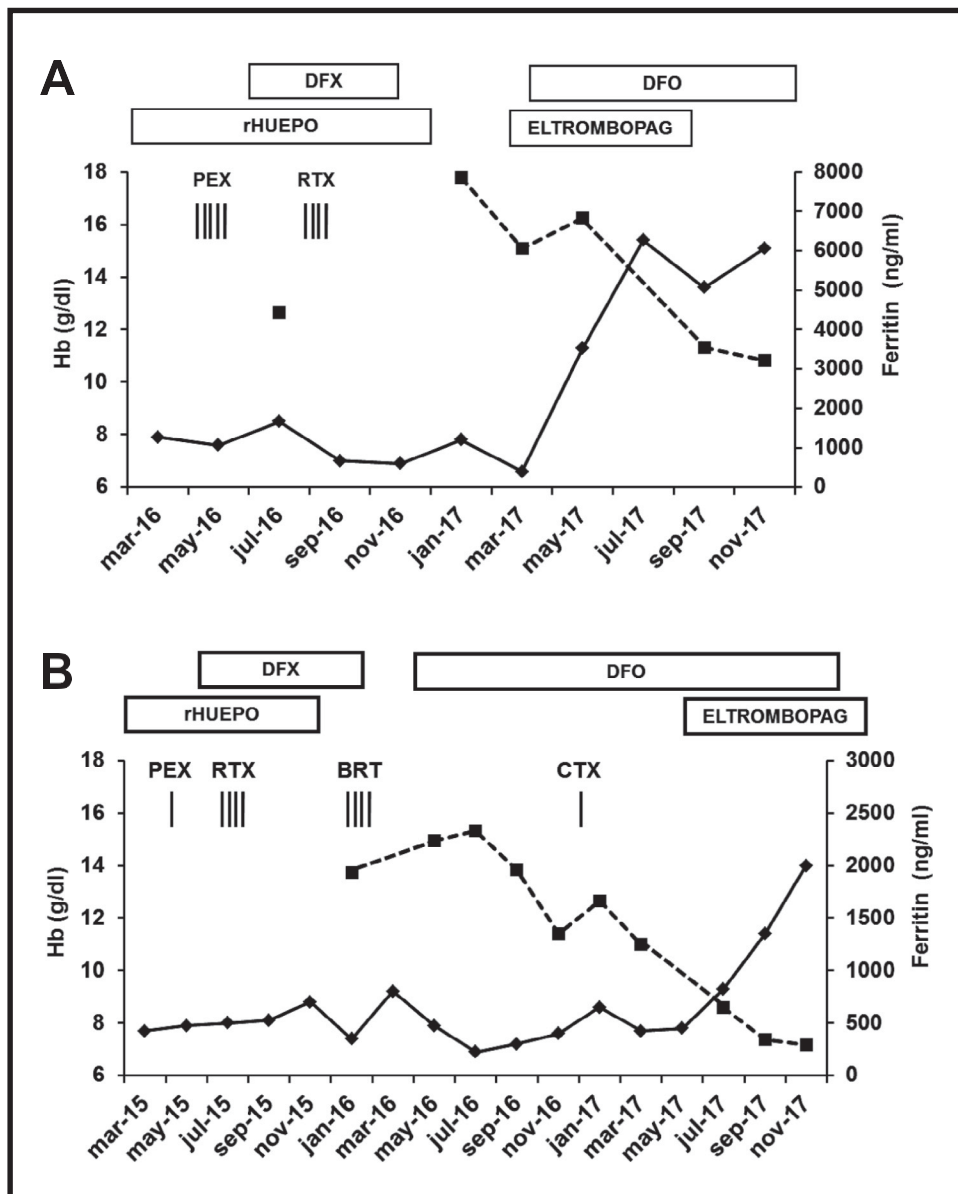
### Patient 2

A 47-year-old woman with biphenotypic acute leukemia in first complete remission received an allogeneic peripheral SCT from an HLA matched unrelated donor in January 2015. Myeloablative conditioning regimen consisted of cyclophosphamide and total body irradiation 12 Gy, and GVHD prophylaxis was based on antithymocyte globulin, cyclosporine, and short-course methotrexate. The blood groups of the patient and the donor were O positive and A positive, respectively.

The patient's anti-A isohemoagglutinin pretransplant titer was 1:256. RBC reduction of the apheresis stem cell product was not performed because of the low hematocrit value.

The patient reached neutrophil and platelet engraftment on days +24 and +18 post-HSCT, respectively. The last RBC unit was transfused on day +14. Since day +37 hemoglobin values gradually decreased, and the patient became transfusion dependent (2 RBC units every 2 weeks). On day +47 treatment with theta-EPO (rHuEPO) 40,000 U per week was started; WBC and platelet values were normal, reticulocyte count was  $5700 \times 10^9/\text{L}$ , neither iron or vitamin deficiency nor hemolysis was detected, and EPO value was 25 U/L. No remarkable response was seen after 6 weeks of treatment with rHuEPO.

A bone marrow biopsy on day 100 was consistent with the diagnosis of PRCA with a normal representation of myeloid and platelet precursors and a global cellularity of 70% (Figure 2A). Full donor chimerism was detected, and the bone marrow aspirate demonstrated a complete remission of her underlying disease. Based on these findings, together with the persistence of an anti-A isohemoagglutinin titer of 1:64, on day +112 a course of PEX was started. Unfortunately, the patient developed a severe anaphylactic reaction to plasma proteins that led to the immediate discontinuation of the PEX program.



**Figure 1.** Evolution of hemoglobin level (solid line) and ferritin levels (dotted line). The treatments with their influence on hematologic parameters are illustrated in patient 1 (A) and patient 2 (B). RTX indicates rituximab; BRT, bortezomib; CTX, cyclophosphamide.

At 5 months post-HSCT ICT with DFX was started, with a ferritin value of 1907 ng/mL. The patient never experienced acute or chronic GVHD.

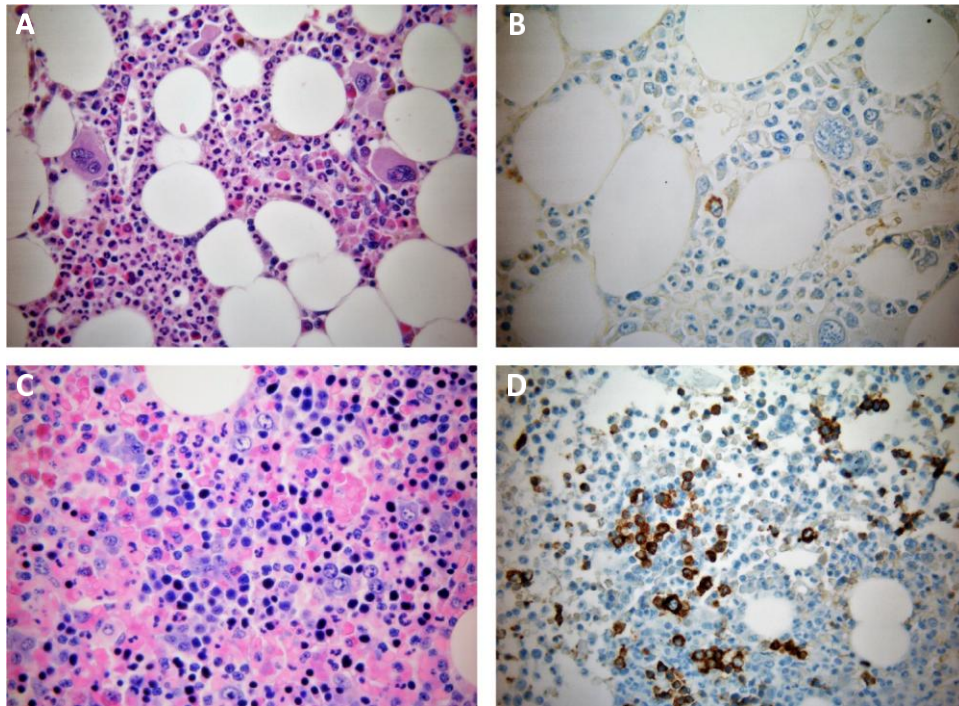
Rituximab (375 mg/m<sup>2</sup>/wk for 4 weeks) and rHuEPO 40,000 U twice a week were subsequently administered without any significant response. The bone marrow biopsy performed 8 months after transplant confirmed a PRCA and full donor chimerism. Ten months after transplant rHuEPO was withdrawn because of a lack of efficacy. Viral infections (cytomegalovirus; Epstein-Barr virus; human herpesvirus-6, -7, and -8; herpes simplex virus 1 and 2; and parvovirus B19) were excluded.

Eleven months after the transplant the patient received a total of 4 doses of bortezomib (1.4 g/m<sup>2</sup> once a week), however, any modification of the transfusion support and isohemagglutinin titer was observed. Ferrochelation with DFX was withheld in February 2016 because of the pres-

ence of neutropenia, and DFO was started. In December 2016 1 dose of cyclophosphamide (1 g) was administered, without any relevant response.

Based on the favorable results obtained in our previous patient, in June 2017 we decided to start the TPO mimetic eltrombopag at the dose of 75 mg/day for the first week and then increased to 150 mg/day. After 3 weeks of treatment eltrombopag was discontinued because of increased platelets up to 500,000 × 10<sup>9</sup>/L and then was resumed at a dose ranging between 50 and 75 mg/day to maintain the platelet value within the normal range.

Overall, after 5 weeks of treatment with eltrombopag the patient became transfusion independent, with progressive improvement of hemoglobin values until normal values. After 5 months of treatment with eltrombopag the bone marrow biopsy showed a moderate trilinear hyperplasia (Figure 2B). In December 2017 patient 2 discontinued eltrombopag after



**Figure 2.** (A) Bone marrow biopsy shows intact granulocytic and megakaryocytic lineages. Erythroid colonies are absent. (B) Immunostaining for CD71 highlights rare erythroid precursors. (C) After eltrombopag treatment, bone marrow biopsy shows a good trilinear representation with normoblastic erythropoiesis. (D) Immunohistochemical stain for CD71 highlights erythroid colonies.

6 months of treatment. Levels of both hemoglobin and platelets remained within the normal range since then. Figure 1B shows the time course of the patient.

## DISCUSSION

Eltrombopag has been proven to be an effective treatment for patients with SAA refractory to immunosuppressive agents [21-23]. Our preliminary data seem to indicate that eltrombopag is a promising drug even in unilineage cytopenias. PRCA is a well-recognized complication after allogeneic HSCT and may be associated to severe pancytopenia in 16% of the cases [24]. However, no standard of care for the treatment of this condition has been established. Table 1 summarizes the clinical characteristics and treatment modalities adopted for patients with post-HSCT PRCA reported in literature since 2000.

Roughly 70 patients with post-HSCT PRCA have been described, and nearly all patients were blood group O and received grafts from donors of blood group A [3,6-18]. Donors were equally balanced between unrelated and matched sibling, whereas conditioning regimens were mainly myeloablative and GVHD prophylaxis cyclosporine-based in most patients. A large number of treatment modalities have been reported with variable degree of success. A complete and partial responses have been reported in 66% of patients who were treated with PEX (7/14) or EPO (7/7), in 36% of patients who received rituximab (5/14), and in 58% of patients treated with high-dose steroids alone or combined with tapering of calcineurin inhibitors (11/19). Donor lymphocyte infusion, bortezomib, and mesenchymal stem cells have been reported in sporadic cases. Undoubtedly, these data may overestimate the real need for aggressive treatments of patients with post-HSCT PRCA because of the propensity of investigators to report difficult cases and especially those who fail

primary therapy such as rHuEPO. Nevertheless, erythroid aplasia and transfusion dependence after HSCT is a compelling problem that justifies therapeutic efforts for a timely solution. In this respect eltrombopag has a high curative potential with a good safety profile.

The mechanism through which eltrombopag may have induced erythroid reconstitution in our patients remains speculative. Several lines of evidence suggest that eltrombopag is able to stimulate directly human hematopoietic stem cells [22,23,25]. Desmond et al. [22] showed that in patients with SAA, 7 of 17 responders achieved trilineage responses and 11 patients became RBC transfusion independent. Moreover, in vitro studies showed that TPO may affect proliferation and differentiation of erythroid progenitors and of late-stage erythroid precursors, respectively [26]. Alternatively, or additionally, the pathway that involves IFN- $\gamma$  (a proinflammatory cytokine often increased after HSCT and potentially implicated in the damage of hematopoietic stem and progenitor to cells), may also be affected. Recent findings showed that eltrombopag was capable of evading the IFN- $\gamma$  induced inhibition on human hematopoietic stem and progenitor cells through the impairment of the TPO/c-MPL pathway [27]. Whether eltrombopag may affect immune cell functions is still a matter of investigation.

Emerging data suggesting that ICT is able to induce an erythroid response [28-32]. Messa et al. [31] reported that 42% of patients with hematologic malignancies and aplastic anemia achieved a transfusion independency after treatment with DFX or DFO. Similarly, Gattermann et al. [32] showed that DFX treatment for up to 1 year led to erythroid improvement in 21% of 247 patients with myelodysplastic syndrome. According to these observations, a potential synergistic effect between ICT and eltrombopag may be hypothesized in our patients. In particular, patient 2 showed

**Table 1**

Summary of PRCA post-HSCT Reported in the Literature from 2000 to 2017

Reference	Patients with PRCA	Diagnosis	HSCT	Source	Conditioning	GVHD Prophylaxis	D/R ABO	Treatment and Outcome (no. of patients)	CR/PR Failure
Sackett K. J Clin Apher 2016	1	SCN	MUD	BM	MAC	CSA	A→0	PEX	RTX, bortezomib, darbopoietin
Helbig G. Ann Hematol 2007	6	AL 5/6	MSD (5) MUD (1)	BM (3) PBSC (2)	MAC	CSA-MTX (5) CSA (1)	A→0 (4) Bi-D (1)	RTX + rHuEPO (1) rHuEPO+second HSCT+RTX (1) PEX (1) second HSCT (1) PEX+rHuEPO+second HSCT (1)	DLI (1) PDN + rHuEPO + TaperCI (1) PDN + rHuEPO + TaperCI + AZA (1) RTX (1) PEX (1)
Fang B. Ann Hematol 2009	2	AL	MSD (1) MUD (1)	BM (1) PBSC (1)	MAC	CSA-MTX (1) CSA-MTX-MMF (1)	A→0	MSC (2)	PEX ± steroids (2) RTX + rHuEPO + CS + taperCI (1)
Hirokawa M. BBMT 2013	46	AL (36)	MSD (24) MUD (22)	BM (33) PBSC (13)	MAC (21)		A→0 (28) Bi-D (6)	CS (8/14), taperCI (2/8), RTX (1)	RTX (2), rHuEPO (3), CS (1), DLI (2),
Poon L-M. BMT 2012	1	AML	MSD	PBSC	MAC	Tac-MTX	Bi-D	Bortezomib	RTX, taperCI, DLI
Benson DM. BMT 2008	1	NHL	MUD	PBSC	MAC	NR	A→0	RTX	—
Verholen F. Eur J Hematol 2004	1	AML	PMRD	PBSC	MAC	CSA-MTX	A→0	DLI	PEX, RTX
Yang M-H. Ann Hematol 2001	1	SAA	MSD	BM	MAC	CSA-MTX	A→0	CS	—
Yang X. Transf Med 2014	1	AML	MSD	PBSC	MAC	Tac-MMF	A→0	CS	—
Deotare U. BMT 2006	1	SAA	MSD	PBSC	RIC	CSA-MTX	Bi-D	CS	RTX, rHuEPO, taper CI
Worel N. Transf 2000	7	AL,SAA, CML	MSD	BM (6) PBSC (1)	MAC	NR	A→0 B→0	PEX (4) IA + rHuEPO (2)	rHuEPO (5)
Khan F Transf Med 2014	1	MDS	MSD	NR	RIC	Tac-MTX	A→0	Bortezmib	CS + RTX
Maschan AA, BMT 2002	1	SAA	MSD		MAC	CSA-MTX	A→0	RTX	—
Rabitsch W. BMT 2003	5	ALL (2) CML(2) NHL(1)	MSD	NR	NR	CSA-MTX	A→0 (4) B→0 (1)	IA (5)	RHuEPO (5) PEX (3)

NR indicates no response; CR, complete response; PR, partial remission; SCN, severe congenital neutropenia; MSD, matched sibling donor; MUD, matched unrelated donor; PMRD, partially matched related donor; PBSC, peripheral blood stem cell; BM, bone marrow; MAC, myeloablative conditioning; CSA, cyclosporine; MTX, methotrexate; MMF mycophenolate mofetil; Tac, tacrolimus; RTX, rituximab; AL, acute leukemia; AML, acute myeloid leukemia; NHL, non-Hodgkin lymphoma; CML, chronic myeloid leukemia; MDS, myelodysplastic syndrome; ALL, acute lymphoblastic leukemia; taperCI, taper calcineurin inhibitor; IA, immunoadsorption; AZA, azathioprine; Bi-D, Bidirectional; MSC, mesenchymal stem cells; DLI, donor lymphocyte transfusion; CS, corticosteroids; NR, not reported.



an erythroid response after 2 months of treatment with eltrombopag and 16 months after the start of ICT with DFO, which led to a significant reduction of ferritin levels. In patient 1 the adjunctive effect of ICT to eltrombopag is questionable because DFX was administered for 3 months only and discontinued 6 months before the erythroid response was observed.

Of note, eltrombopag was well tolerated by our patients, with only a transient thrombocytosis requiring dose adjustment. Neither patient had evidence of clonal evolution, although prolonged follow-up is still needed.

In conclusion, although we cannot completely exclude a spontaneous improvement, our findings, albeit observed in a small patient subset, may be considered indicative of a favorable effect of eltrombopag on unilineage cytopenias such as PRCA. Additional studies that include a large proportion of patients are mandatory to confirm our preliminary data.

#### ACKNOWLEDGMENTS

*Financial disclosure:* The authors have nothing to disclose.

*Conflict of interest statement:* There are no conflicts of interest to report.

#### REFERENCES

1. Sniecinski IJ, Oien L, Petz LD, Blume KG. Immunohematologic consequences of major ABO-mismatched bone marrow transplantation. *Transplantation*. 1988;45:530-533.
2. Gmür JP, Burger J, Schaffner A, et al. Pure red cell aplasia of long duration complicating major ABO-incompatible bone marrow transplantation. *Blood*. 1990;75:290-295.
3. Worel N, Greinix HT, Schneider B, et al. Regeneration of erythropoiesis after related- and unrelated-donor BMT or peripheral blood HPC transplantation: a major ABO mismatch means problems. *Transfusion*. 2000;40:543-550.
4. Aung FM, Lichtiger B, Bassett R, et al. Incidence and natural history of pure red cell aplasia in major ABO-mismatched haematopoietic cell transplantation. *Br J Haematol*. 2013;160:798-805.
5. Griffith LM, McCoy JP Jr, Bolan CD, et al. Persistence of recipient plasma cells and anti-donor isohaemagglutinins in patients with delayed donor erythropoiesis after major ABO incompatible non-myeloablative haematopoietic cell transplantation. *Br J Haematol*. 2005;128:668-675.
6. Hirokawa M, Fukuda T, Ohashi K, PRCA Collaborative Study Group, et al. Efficacy and long-term outcome of treatment for pure red cell aplasia after allogeneic stem cell transplantation from major ABO-incompatible donors. *Biol Blood Marrow Transplant*. 2013;19:1026-1032.
7. Sackett K, Cohn CS, Fahey-Ahrndt K, Smith AR, Johnson AD. Successful treatment of pure red cell aplasia because of ABO major mismatched stem cell transplant. *J Clin Apher*. 2017;57:2216-2219.
8. Helbig G, Stella-Holowiecka B, Wojnar J, et al. Pure red-cell aplasia following major and bi-directional ABO-incompatible allogeneic stem-cell transplantation: recovery of donor-derived erythropoiesis after long-term treatment using different therapeutic strategies. *Ann Hematol*. 2007;86:677-683.
9. Fang B, Song Y, Li N, Li J, Han Q, Zhao RC. Mesenchymal stem cells for the treatment of refractory pure red cell aplasia after major ABO-incompatible hematopoietic stem cell transplantation. *Ann Hematol*. 2009;88:261-266.
10. Poon LM, Koh LP. Successful treatment of isohaemagglutinin-mediated pure red cell aplasia after ABO-mismatched allogeneic hematopoietic cell transplant using bortezomib. *Bone Marrow Transplant*. 2012;47(6):870-871.
11. Benson DM Jr, Smith MK, Krugh D, Devine SM. Successful therapy of chronic graft-versus-host disease manifesting as pure red cell aplasia with single-agent rituximab. *Bone Marrow Transplant*. 2008;41:595-596.
12. Verhopen F, Stalder M, Helg C, et al. Resistant pure red cell aplasia after allogeneic stem cell transplantation with major ABO mismatch treated by escalating dose donor leukocyte infusion. *Eur J Haematol*. 2004;73:441-446.
13. Yang MH, Hsu HC. Pure red cell aplasia after ABO-incompatible allogeneic stem cell transplantation in severe aplastic anemia with response to steroids: a case report and literature review. *Ann Hematol*. 2001;80:299-301.
14. Yang X, Levis M. Pulsed-high-dose dexamethasone as a treatment for pure red cell aplasia following ABO-incompatible allogeneic stem cell transplantation. *Transfus Med*. 2014;24:246-248.
15. Deotare UR, Vishwabandya A, Mathews V, George B, Srivastava A, Chandy M. Response to high-dose dexamethasone for acquired pure red cell aplasia following ABO-mismatched allogeneic stem cell transplantation. *Bone Marrow Transplant*. 2006;37:1149-1150.
16. Khan F, Linden MA, Zantek ND, Vercellotti GM. Subcutaneous bortezomib is highly effective for pure red cell aplasia after ABO-incompatible haematopoietic stem cell transplantation. *Transfus Med*. 2014;24:187-188.
17. Maschan AA, Skorobogatova EV, Balashov DN, et al. Successful treatment of pure red cell aplasia with a single dose of rituximab in a child after major ABO incompatible peripheral blood allogeneic stem cell transplantation for acquired aplastic anemia. *Bone Marrow Transplant*. 2002;30:405-407.
18. Rabitsch W, Knöbl P, Prinz E, et al. Prolonged red cell aplasia after major ABO-incompatible allogeneic hematopoietic stem cell transplantation: removal of persisting isohaemagglutinins with Ig-Therasorb immunoadsorption. *Bone Marrow Transplant*. 2003;32:1015-1019.
19. Bussel JB, Cheng G, Saleh MN, et al. Eltrombopag for the treatment of chronic idiopathic thrombocytopenic purpura. *N Engl J Med*. 2007;357:2237-2247.
20. Saleh MN, Bussel JB, Cheng G, et al. Safety and efficacy of eltrombopag for treatment of chronic immune thrombocytopenia: results of the long-term, open-label EXTEND study. *Blood*. 2013;121:537-545.
21. Olnes MJ, Scheinberg P, Calvo KR, et al. Eltrombopag and improved hematopoiesis in refractory aplastic anemia. *N Engl J Med*. 2012;367:11-19.
22. Desmond R, Townsley DM, Dumitriu B, et al. Eltrombopag restores trilineage hematopoiesis in refractory severe aplastic anemia that can be sustained on discontinuation of drug. *Blood*. 2014;123:1818-1825.
23. Townsley DM, Scheinberg P, Winkler T, et al. Eltrombopag added to standard immunosuppression for aplastic anemia. *N Engl J Med*. 2017;376:1540-1550.
24. Aung FM, Lichtiger B, Rondon G, et al. Pure red cell aplasia in major ABO-mismatched allogeneic hematopoietic stem cell transplantation is associated with severe pancytopenia. *Biol Blood Marrow Transplant*. 2016;22:961-965.
25. Sun H, Tsai Y, Nowak I, Liesveld J, Chen Y. Eltrombopag, a thrombopoietin receptor agonist, enhances human umbilical cord blood hematopoietic stem/primitive progenitor cell expansion and promotes multi-lineage hematopoiesis. *Stem Cell Res*. 2012;9:77-86.
26. Liu W, Wang M, Tang DC, et al. Thrombopoietin has a differentiative effect on late-stage human erythropoiesis. *Br J Haematol*. 1999;105:459-469.
27. Alvarado LJ, Andreoni A, Huntsman HD, et al. Heterodimerization of TPO and IFN- $\gamma$  impairs human hematopoietic stem/progenitor cell signalling and survival in chronic inflammation, ASH Meeting. *Blood* 2017;130(suppl 1):4.
28. Vreugdenhil G, Smeets M, Feelders RA, Van Eijk HG. Iron chelators may enhance erythropoiesis by increasing iron delivery to haematopoietic tissue and erythropoietin response in iron-loading anaemia. *Acta Haematol*. 1993;89:57-60.
29. Oliva EN, Ronco F, Marino A, Alati C, Praticò G, Nobile F. Iron chelation therapy associated with improvement of hematopoiesis in transfusion-dependent patients. *Transfusion*. 2010;50:1568-1570.
30. Park SJ, Han CW. Complete hematopoietic recovery after continuous iron chelation therapy in a patient with severe aplastic anemia with secondary hemochromatosis. *J Korean Med Sci*. 2008;23:320-323.
31. Messa E, Cilloni D, Messa F, Arruga F, Roetto A, Saglio G. Deferasirox treatment improved the hemoglobin level and decreased transfusion requirements in four patients with the myelodysplastic syndrome and primary myelofibrosis. *Acta Haematol*. 2008;120:70-74.
32. Gattermann N, Finelli C, Della Porta M, et al. Hematologic responses to deferasirox therapy in transfusion-dependent patients with myelodysplastic syndromes. *Haematologica*. 2012;97:1364-1371.