

CASE REPORT

Bilateral multifocal synchronous intra- and extra-parotid Warthin tumors: case report and review of literature

Beatrice FABIANO, Giuseppe RIVA *, Vittorio FERRERO

ENT Department, Gradenigo Hospital, Turin, Italy

*Corresponding author: Giuseppe Riva, ENT Department, Gradenigo Hospital, Corso Regina Margherita 10, 10153 Turin, Italy.
E-mail: giuseppe.riva84@gmail.com

ABSTRACT

Warthin tumor is the second most frequent benign tumor of the parotid gland. Multifocal Warthin tumors are rarely bilateral synchronous. Six synchronous bilateral cases with more than two nodules of Warthin tumor have been described in the literature; only three cases had 4 or 5 tumor nodules. None of these had also extra-parotid localizations. We report a rare case of a patient with four bilateral synchronous Warthin tumors of parotid glands and we present a complete review of the literature. A 72-year-old woman presented at our division with a 12 months history of bilateral parotid swelling. Magnetic resonance imaging revealed four bilateral nodular lesions of the parotid glands. Fine-needle aspiration biopsy was indicative of Warthin tumors. The patient underwent surgical treatment. Multifocality should be kept in mind when a Warthin tumor is diagnosed. Therefore, magnetic resonance imaging represent an important tool in the diagnostic algorithm, and an adequate follow-up is mandatory.

(Cite this article as: Fabiano B, Riva G, Ferrero V. Bilateral multifocal synchronous intra- and extra-parotid Warthin tumors: case report and review of literature. *Otorinolaringol* 2017;67:120-2. DOI: 10.23736/S0392-6621.17.02123-3)

Key words: Adenolymphoma - Parotid gland - Salivary gland neoplasms.

Warthin tumor, also known as papillary cystadenoma lymphomatosum, is the second most frequent benign tumor of the parotid gland after pleomorphic adenoma.¹ The tumor accounts for 2-15% of all parotid tumors.^{2, 3}

Salivary gland neoplasms are usually solitary while multiple tumors occurring simultaneously in an individual are uncommon. Most of the multifocal Warthin tumors are unilateral, whereas bilateral Warthin tumors are much more uncommon. Most of the bilateral tumors are metachronous, with a very few cases of synchronous bilateral tumors reported in the literature.^{2, 4-7} Only one previous case had simultaneous bilateral parotid and neck localizations.⁵

We present a rare case of a patient with four bilateral synchronous intra- and extra-parotid Warthin tumors. Written informed consent was obtained.

Case report

A 72-year-old woman presented at our division with a 12 months history of bilateral parotid swelling. Apart from the habit of smoking, her medical history was normal. Clinical examinations confirmed bilateral mobile, painless swelling, without intra-oral lesions. Facial nerves function was normal. Ultrasonography (US) showed multifocal bilateral parotid nodules, so magnetic resonance imaging (MRI) was programmed.

MRI revealed four bilateral nodular lesions of the parotid glands: three nodules in the right parotid gland and one nodule in the left gland. They were well defined and rounded in appearance, with mild enhancement after administration of intravenous contrast medium (Figure 1). The left nodule measured 2 cm in diameter and it was in the superficial lobe. In the right parotid gland, the bigger nodules measured 2.2 cm and 2.1 cm in maximum dimension, while a minor nodule had a 1 cm diameter. The 2.1 cm nodule was in the deep lobe of right parotid gland.

Fine-needle aspiration biopsy (FNAB), under ultrasonography guidance, was carried out on the bigger right nodule and on the left nodule. It was indicative of Warthin tumors.

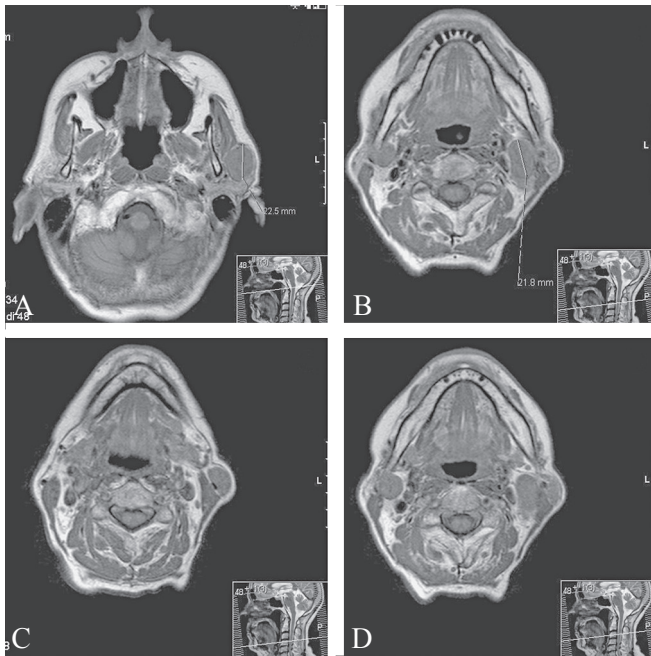


Figure 1.—Imaging findings. Axial T1-weighted magnetic resonance imaging. A) 2.2 cm right nodule in the superficial lobe; B) 2.1 cm right nodule in the deep lobe; C) 1.0 cm right nodule in the superficial lobe, which was actually an extra-parotid localization; D) 2.0 cm left nodule in the superficial lobe.

On the basis of these data, the patient underwent right total parotidectomy with preservation of facial nerve branches (Figure 2). Meticulous intraoperative inspection and palpation of the

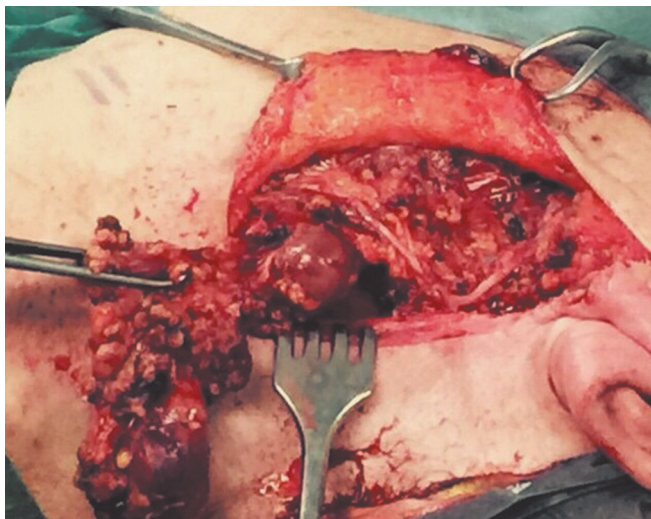


Figure 2.—Intraoperative images. Right parotidectomy showing two Warthin tumors (intra- and extra-parotid nodules) with preservation of facial nerve.

glandular tissues and peri-glandular lymph nodes were performed in order to exclude the presence of other small neoplasms undetected at MRI. One of the right nodules was actually extra-parotid at Robins neck level 2. Histopathological examination of the specimen revealed three distinct nodes of Warthin tumor, with complete excision and without evidence of malignancy. No post-operative complications occurred.

The patient chose a waiting and see approach for the left parotid Warthin tumor. Six months after surgery, ultrasonography showed no right parotid recurrence and no dimension increase of the left parotid mass.

Discussion

Warthin tumor is the second most common salivary gland tumor and accounts for 2-15% of all epithelial tumors of the parotid.^{1, 3, 4} Evidence for the etiology and pathogenesis of the disease is still lacking.¹ However, smoking seems to be a significant risk factor for development of Warthin tumors.⁸

About 12% of patients develop multiple Warthin tumors. They may occur unilaterally or bilaterally, metachronously or synchronously. Most of them are unilateral and metachronous. In 4-7% of the cases bilateral tumor development has been reported.⁸ To our knowledge, six synchronous bilateral cases with more than two nodules of Warthin tumor have been described in the literature. Only three cases had 4 or 5 tumor nodules.² None of these had also extra-parotid localizations. Only one previous case had simultaneous bilateral parotid and neck localizations.⁵ So far, no risk factors for the presence of bilateral Warthin tumor have been detected.⁸

The majority of patients present with a slowly growing asymptomatic parotid mass. The average size of the tumor at presentation varies from a few millimeters to centimeters.⁴ The range of dimension for multifocal Warthin tumor is 0.2-4.8 cm, with a greater number of nodules generally in the right parotid gland.² In our case, the dimensions of lesions ranged 1.0-2.2 cm.

Ultrasound scanning (US) demonstrates hypoechoic ovoid lesions with anechoic areas that are often hypervascularised.³ Computer tomography (CT) or magnetic resonance imaging (MRI) demonstrates an enhancing, well circumscribed lesion.³ Fine needle aspiration cytology shows focal collections of oncocytic epithelial cells surrounded by lymphocytes.^{1, 9} Warthin tumor is a benign lesion; however a very low rate of malignant transformation to squamous cell carcinoma or low

grade lymphoma is recognized. Moreover, an extra-parotid neck localization can mimic a tumor metastatic to a lymph node.

Diagnosis is based on histological examination, so ultrasound-guided fine needle aspiration cytology or biopsy (FNAC or FNAB) is mandatory in the diagnostic algorithm. Moreover, in multifocal tumors, complete bilateral screening of the parotid glands by MRI is needed to program surgery.

The treatment recommended for Warthin tumor is superficial parotidectomy, when the tumor occurs in a superficial lobe, or total parotidectomy, when the tumor is in a deep lobe, with preservation of the facial nerve. The recurrence rate is low, most likely due to multifocality.¹ For this reason, a meticulous macroscopic examination of the parotid is indicated. Moreover, a meticulous intra-operative inspection and palpation of periglandular lymph nodes is mandatory in order to exclude the presence of extra-parotid Warthin tumors. Our patient underwent right total parotidectomy, in order to first treat the parotid gland with the majority of tumor nodules. The patient have chosen a waiting and see approach for the left Warthin tumor. Therefore, it is mandatory to discuss the therapeutic path with the patient.

Long-term follow-up is mandatory, due to the possible occurrence of metachronous salivary and extrasalivary tumors, even after prolonged time intervals. US should be used in follow-up. Concerning multifocal bilateral Warthin tumors, literature studies report a disease free follow-up between 3 months and 5 years.^{4, 10} No recurrence on the operated side was observed at 6 months after surgery in our case.¹⁰

Conclusions

Multiple Warthin tumors, synchronously involving both parotid glands, are exceptionally rare. However, multifocality and extra-parotid localizations should be kept in mind when a Warthin tumor is diagnosed. Therefore, MRI examination represents an important tool in the diagnostic algorithm, an intra-operative macroscopic examination of the parotid is indicated, and an adequate follow-up is mandatory.

References

1. Simpson RHW, Eveson JW. Warthin tumor. In: Barnes L, Eveson JW, Reichart P, Sidransky D (ed) World Health Organization classification of tumors: pathology and genetics of head and neck tumors. Lyon, France: IARC Press, 2005:263-5.
2. Maiorano E, Lo Muzio L, Favia G, Piattelli A. Warthin's tumor: a study of 78 cases with emphasis on bilaterality, multifocality and association with other malignancies. *Oral Oncology* 2002;38:35-40
3. Hilton JM, Phillips JS, Hellquist HB, Premachandra DJ. Multifocal multi-site Warthin tumor. *Eur Arch Otorhinolaryngol.* 2008;265:1573-5
4. Ascani G, Pieramici T, Rubini C, Messi M, Balercia P. Synchronous bilateral Warthin's tumors of the parotid glands: a case report. *Acta Otorhinolaryngol Ital* 2010;30:310-2.
5. Shah N, Tighe JV, Barrett AW, Kumar S, Allen JP. Bilateral intraparotid and extraparotid Warthin's tumors. *Br J Oral Maxillofac Surg* 2007;45:238-9.
6. Kremp AN, Nelson BL. Bilateral Warthin tumors of the parotid gland. *Head and Neck Pathol* 2008;2:175-6.
7. Nascimento LA, Santos Ferreira JA, Pio RB, Soares Takano GH, Miziara HL. Synchronous bilateral Warthin tumors: a case report. *Int Arch Otorhinolaryngol* 2014;18:217-20.
8. Klusmann JP, Wittekindt C, Preuss SF, Al Attab A, Schroeder U, Guntinas-Lichius O. High risk for bilateral Warthin tumor in heavy smokers – review of 185 cases. *Acta Oto-Laryngologica* 2006;126:1213-7.
9. Yu GY, Ma DQ, Zhang Y, Peng X, Cai ZG, Gao Y, *et al.* Multiple primary tumors of the parotid gland. *Int J Oral Maxillofac Surg* 2004;33:531-4.
10. Deveer M, Sahan M, Sivrioglu AK, Celik OI. Bilateral multifocal Warthin tumors. *BMJ Case Rep* 2013;2013.

Conflicts of interest.—The authors certify that there is no conflict of interest with any financial organization regarding the material discussed in the manuscript. Manuscript accepted: July 24, 2017. - Manuscript received: July 15, 2017.