

Research Article

Open Access

Alessia Ferrarese*, Marco Bindi, Matteo Rivelli, Mario Solej, Stefano Enrico, Valter Martino

Self-gripping mesh versus fibrin glue fixation in laparoscopic inguinal hernia repair: a randomized prospective clinical trial in young and elderly patients

DOI 10.1515/med-2016-0087

received August 12, 2016; accepted August 19, 2016

Abstract: Laparoscopic transabdominal preperitoneal inguinal hernia repair is a safe and effective technique. In this study we tested the hypothesis that self-gripping mesh used with the laparoscopic approach is comparable to polypropylene mesh in terms of perioperative complications, against a lower overall cost of the procedure.

We carried out a prospective randomized trial comparing a group of 30 patients who underwent laparoscopic inguinal hernia repair with self-gripping mesh versus a group of 30 patients who received polypropylene mesh with fibrin glue fixation.

There were no statistically significant differences between the two groups with regard to intraoperative variables, early or late intraoperative complications, chronic pain or recurrence.

Self-gripping mesh in transabdominal hernia repair was found to be a valid alternative to polypropylene mesh in terms of complications, recurrence and postoperative pain. The cost analysis and comparability of outcomes support the preferential use of self-gripping mesh.

Keywords: Inguinal hernia; Laparoscopic repair; Transabdominal hernia repair

*Corresponding author: **Alessia Ferrarese**, University of Turin, Section of General Surgery, San Luigi Gonzaga Teaching Hospital, Regione Gonzole 10, 10043 Orbassano, Turin, Italy, E-mail: alessia.ferrarese@gmail.com

Marco Bindi, Matteo Rivelli, Mario Solej, Stefano Enrico, Valter Martino, University of Turin, Department of Oncology, School of Medicine, Teaching Hospital "San Luigi Gonzaga", Section of General Surgery, Orbassano, Turin, Italy

Abbreviations and acronyms: TAPP = Transabdominal Pre-Peritoneal, ASA = American Society of Anesthesiology, BMI= Body Mass Index, PM Group = Polypropylene-Mesh Group, SGM Group = Self-Gripping Mesh Group, SD = Standard Deviation

1 Introduction

Inguinal hernia is one of the most common diseases, with an incidence of 700,000 cases each year in the United States and a male-to-female preponderance of 9 to 1 [1,2].

Hernia repair is one of the most frequently performed general surgical procedures in the world [1].

Laparoscopic transabdominal hernia repair was first performed in the early 1990s by F. Ger, in Germany [3-6], and consisted of nickel clips to close the defect through an intra-abdominal approach. The first laparoscopic transabdominal pre-peritoneal hernia repair (TAPP) was performed in 1992 in France by Arregui and Doin, who fixed a mesh in the peritoneal space after making an incision through the parietal peritoneum [7,8].

The advantages of laparoscopic over open mesh repair in terms of improved intraoperative diagnosis, better aesthetic result and reduced postoperative pain have been demonstrated in literature [9-13].

Laparoscopic inguinal hernia repair through a transabdominal preperitoneal approach has been described in literature as a difficult procedure; this difficulty is linked to the intrinsic complexity of the anatomical area to be dissected and also to the patient's habitus and the characteristics of the abdominal wall defect [14].

Laparoscopy is always performed under general anesthesia and, according to some authors, carries a higher risk of intraoperative complications.

Current indications for laparoscopic repair are bilateral inguinal hernias and recurrent hernias following a previous anterior repair (grade B of recommendation) [15-22].

Despite developments in prosthetic materials and improvements to methods of fixation, polypropylene mesh with fibrin glue fixation still sets the standard for laparoscopic repair [21,23-38].

The use of fibrin glue to fix the mesh in hernia repair was first described in 2001 by Katkhouda *et al.* using a pig model [39].

Numerous new meshes have been developed in recent years; however, none of these have been able to match polypropylene mesh for ease of handling and efficacy, nor can they replace it as the new gold standard [40-42].

One of the most recent meshes to have come onto the market features a self-gripping technology. According to the literature, these self-gripping meshes have excellent properties of fixation and efficacy [43]; self-gripping mesh is composed of a layer of large-pore polyester coated with a layer of polylactic acid self-gripping micro hooks. The mesh exhibits intrinsic and atraumatic fixation so to close the hernia safely and effectively, considerably reducing the level of chronic pain.

In 2006 Chastan was the first to describe a new hernia repair procedure through the inguinal approach using a Velcro®-like self-gripping mesh without tacking systems [44].

Inadequate mesh fixation has been reported to be the main cause of recurrences following laparoscopic hernia repair.

Chronic pain is an infrequent, but serious, potential complication of mesh fixation with tacks [49-51].

Tekit *et al.* described two instances in which further surgery was required due to debilitating pain following TAPP repair [46].

The International Endohernia Society (IEHS) guidelines of 2011 and European Hernia Society guidelines of 2009 defined endoscopic inguinal hernia techniques as safe, providing specific technical steps are followed [21,22]; in 2012 a randomized prospective study comparing TAPP versus totally extraperitoneal laparoscopic hernia repair defined the two methods as similar in terms of overall perioperative outcome and found the totally extraperitoneal approach to be significantly advantageous in terms of postoperative pain.

At the time of preparing the guidelines and conducting the study cited above, there was no standardized tech-

nique for applying self-gripping mesh in laparoscopic procedures [52].

In 2012, Fumagalli *et al.* conducted a study to compare the TAPP approach with self-gripping mesh versus fixation with clips, and the authors concluded, within the limits of a retrospective study, that the use of self-gripping mesh could be a valid alternative to the other techniques [53].

In a retrospective study of 2012, Birk *et al.* concluded that laparoscopic hernia repair using self-gripping mesh was a rapid, effective and safe technique, with fewer cases of recurrence and reduced incidence of chronic pain; they reported that the costs of fixation systems required with other non-self-gripping meshes were superfluous [54].

The aim of this study was to compare laparoscopic surgical procedure using self-gripping mesh versus the procedure using polypropylene mesh with fibrin glue fixation.

The end point of the trial was to test the hypothesis that self-gripping mesh is comparable to polypropylene mesh in terms of perioperative complications against a lower overall cost of the procedure in young and elderly (> 65 years old).

2 Methods

2.1 Study design

This non-stratified, monocentric study with balanced randomization (1:1) used a parallel group design to compare the TAPP approach with self-gripping mesh to the TAPP repair with polypropylene mesh with biological fibrin glue fixation.

2.2 Eligibility criteria

Patients eligible for inclusion were men with primary or recurrent unilateral inguinal hernia, aged 25 to 70 years, with a BMI (body mass index) of < 18 and ASA (American Society of Anesthesiology) class ≤ 3. The purpose of recruiting a male-only cohort was to standardize the surgical setting as far as possible in terms of anatomy and technical problems encountered in performing the inguinal dissection.

Exclusion criteria were glaucoma, previous retinal detachment or relevant cardiovascular co-morbidity.

2.3 Setting

The study was conducted at the General Surgery Unit, Department of Oncology, San Luigi Gonzaga School of Medicine, University of Turin in Orbassano, Italy, between 1 January 2014 and 1 January 2015.

2.4 Surgical procedures

Patients were randomized to receive laparoscopic inguinal hernia repair with either self-gripping mesh or polypropylene mesh with glue fixation.

Self-gripping mesh was a lightweight, monofilament, two-dimensional mesh with an upper layer of resorbable polylactic acid micro hooks on the adhesive side. This was compared with a medium-weight, large-pore polypropylene mesh fixed by means of 1-2 cc of biological fibrin glue.

The procedures were performed by two surgeons, both of whom were specialists in laparoscopy, having performed at least 500 cholecystectomies and a further 300 laparoscopic surgical procedures (including at least 70 TAPP procedures).

The mean at follow-up is currently 11 months. Eligible patients were recruited between March 2013 and December 2013. All participants underwent a surgical and anesthesiological evaluation at the time of randomization into the study. They also underwent a postoperative evaluation at one day, seven days and three months after surgical procedure.

All the operations were performed as day surgery procedures: patients were admitted to hospital on the morning of the operation and discharged the first or second day after surgery, following a physical examination of the abdomen and monitoring of gas canalization.

Ethical approval: The research related to human use has been complied with all the relevant national regulations, institutional policies and in accordance the tenets of the Helsinki Declaration, and has been approved by the authors' institutional review board or equivalent committee.

Informed consent: Informed consent has been obtained from all individuals included in this study.

2.5 Details of the surgical technique

The same laparoscopic technique was used for both groups, with access by umbilical incision, Veress assisted,

and two operating trocars. A preperitoneal pocket was created by performing medial, lateral and midline dissection with reduction of the hernial sac. In all cases, the funicular elements were parietalized, and hemostasis was secured.

In all cases the mesh was cut to a size of 10 x 12 x 8 cm with incision of the funicular portion. Self-gripping mesh was inserted rolled up, and the polypropylene mesh was inserted flat; the latter was fixed using 1-2 cc of biological fibrin glue prepared by diluting the thrombin component in a ratio of 1:10 with respect to the fibrin after appropriate thawing.

2.6 Variables evaluated

For both groups, we evaluated perioperative variables (operating time and postoperative length of hospital stay), intraoperative complications (vascular lesions, deferential lesions), early postoperative complications (hematoma, seroma, orchitis, wound infection, neuralgia, difficulty with urination), and late postoperative complications (testicular phlogosis, testicular atrophy, deferential lesions, chronic local pain, mesh infection, recurrence).

Post-operative pain was evaluated with a visual analogue scale (VAS) one-dimensional numerical rating scale (NRS) graded from 0 to 10 [55]. The evaluation was performed at one day, seven days and three months in both groups (Table 4); we used the definition coined by other authors and proposed in the guidelines for the prevention of chronic postoperative pain [56]. These authors defined chronic pain as pain that persists for more than six months after the operation and that is due to synthetic material used to repair the defect [57,58].

2.7 Outcomes

The primary end point of this study was a comparison of the two techniques based on analysis of the previously defined parameters, given the known reduction in the overall cost of the implantable systems (reduction in the total cost of the operation).

For the equivalence study, to establish the similarity of the perioperative complications of recurrence and chronic pain associated with two surgical procedures, we calculated a sample size of 30 patients per group, given an incidence of recurrence of approximately 5% with a TAPP procedure [59], a fixed chronic pain rate of 28.7% [10] and a formal estimated power of the study of 80%. After that,

we studied surgery-related variables in the subgroup of elderly patients, and we commented on its incidence.

2.8 Method of randomization

Participants were assigned to one of the two treatment groups by simple randomization generated with the on-line software available at www.randomization.com.

After we obtained patients' informed consent, they were allocated to the groups by a researcher who was not clinically involved in the trial, and randomization was concealed by use of sealed envelopes held in a specific part of the Department. The researcher informed the surgeon which prosthesis was to be used only when the envelope was opened. The patients were told which mesh had been used at the end of the study.

2.9 Statistical methodology

Statistical proportions of dichotomic variables (classification and type of hernia, number of complications) were compared with the Chi-square test and Fisher's exact test.

Continuous variables (age distribution, BMI distribution, mean operative time, postoperative length of hospital stay, operating time, American Society of Anesthesiologists [ASA] evaluation) were expressed as the average (range) and analyzed with the Mann-Whitney U test. Patient distribution according to the two teams was verified. All statistical analyses were performed with R software (vers. 2.6.2); a *P* value of <0.01 was considered statistically significant.

3 Results

During the study period, hernioplasty was indicated for 142 patients. Eighty-two patients were excluded from the study: 65 because they did not meet eligibility criteria, 13 because they did not give their consent to take part in the trial and 4 for other reasons (refusal of general anesthesia) (Figure 1).

Sixty patients were randomized: 30 were assigned to surgical treatment with polypropylene mesh with fibrin glue fixation (PM group) and 30 to surgical treatment with self-gripping mesh (SGM group).

None of the patients recruited into the study was excluded, withdrew from or died during the course of the trial, and thus all patients were included in the analysis.

Table 1 summarizes the participants' basic characteristics; study groups were compared on demographic and clinical characteristics. Primary outcome variables are shown in Tables 2a and 2b in the total group and in the elderly.

Intention-to-treat analysis revealed an average operating time of 74.4 minutes for the PM group and 74.9 minutes for SGM group. Analysis of surgery-related variables revealed no statistically significant differences between the two groups (Table 2a) and in the elderly (Table 2b).

In terms of complications, Table 3 shows the data of intention-to-treat analysis. No surgical wound infection, mesh superinfection, urogenital or other complications occurred.

The assessment of chronic pain, using the VAS, showed no statistically significant differences at one day, seven days and three months in either group (Table 3a) (Figure 2); there were no differences in the elderly (Table 3b).

The comparison between complications did not reveal any statistically significant differences between two groups.

Cost analysis of the implantable systems found that the total cost of hernia repair with self-gripping mesh was € 123 (the cost of the mesh alone), whereas the cost of hernioplasty with polypropylene mesh was € 272 (€ 22 for mesh and € 259 for 5 cc of glue).

4 Discussion

We believe that laparoscopic transabdominal hernia repair is an effective procedure that can achieve excellent results in terms of aesthetics, morbidity and postoperative pain [9-13,60-61].

These are fundamental aspects, since the incidence of chronic pain and disability following inguinal hernia repair through open or laparoscopic procedures is not negligible [62-66].

In agreement with Bittner *et al.*, we are convinced that the application of a strictly standardized technique is an essential precondition for reducing the risk of intraoperative complications to a minimum [14].

The procedure must be performed by a laparoscopic surgeon with extensive experience of open abdominal-wall surgery and an excellent knowledge of abdominal-wall anatomy.

The results achieved with the self-gripping mesh and the polypropylene mesh were comparable, as both are

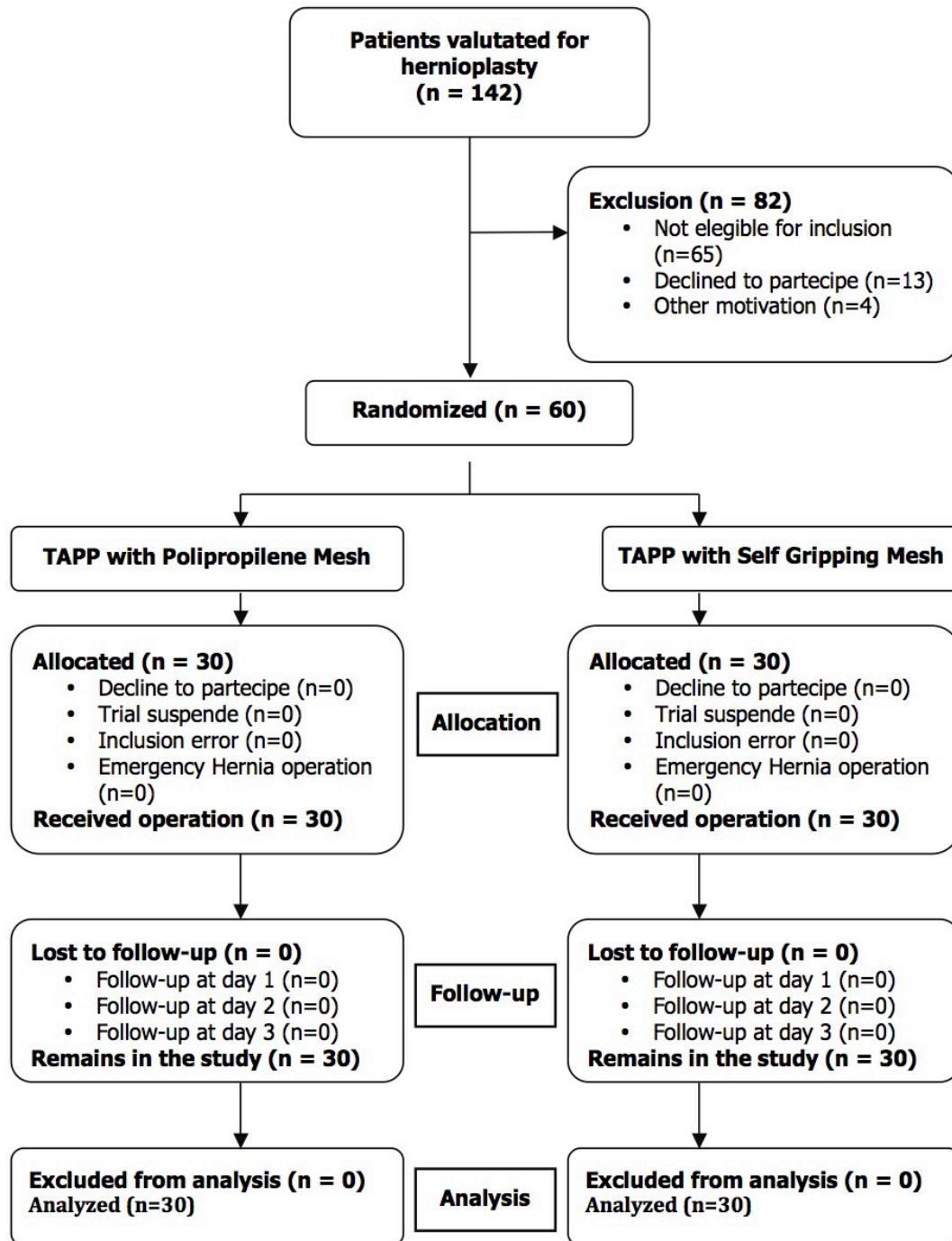


Figure 1: Flowchart

working prostheses and both methods of fixation are valid and effective.

Operating times were comparable, despite the surgeons initially finding it more difficult to position the self-gripping mesh; however, both surgeons confirmed that they found the mesh easy to handle after first ten procedures. Moreover, for the SGM group, there was no

need to consider the time required to prepare and apply the fibrin glue.

The postoperative length of hospital stay was comparable for both procedures; both were performed as day surgery with one night in hospital and only a very small number of patients (3 in the PM group, 2 in the SGM group) had to stay two nights. Analytical comparison of post-operative length of hospital stay revealed no statistically sig-

Table 1: Patient Baseline Characteristics

Patient Baseline Characteristics	PM Group	SGM Group	P
Total			
Male [no. (%)]	30	30	-
Female [no. (%)]	0	0	-
Mean age (yr), mean (\pm SD)	53,3 (\pm 10,9)	53 (\pm 11,0)	0,906
Hernia type			
Indirect [no. (%)]	27 (90%)	26 (86,6%)	0,687
Direct [no. (%)]	3 (10%)	4 (13,3%)	0,687
Recurrence			
Recurrence [no. (%)]	4 (13.3%)	5 (16.6%)	0,717
Primitive [no. (%)]	28 (86.6%)	25 (83.3%)	0,717
ASA			
I [no. (%)]	5 (16,6%)	5 (16,6%)	1
II [no. (%)]	24 (80%)	23 (76,6%)	0,754
III [no. (%)]	1 (3,3%)	2 (6,6%)	0,553
BMI (Kg/m ²), mean (\pm SD)	24,5 (\pm 1,2)	24,1 (\pm 1,6)	0,315

PM Group: Polypropylene Mesh Group

SGM Group: Self-Gripping Mesh Group

ASA: American Society of Anesthesiologists' physical status score

BMI: Body Mass Index

Table 2a: Surgery-Related Variables

Surgery-Related Variables	PM Group	SGM Group	P
Operative time (min), mean (\pm SD)	74,4 (\pm 12,8)	74,9 (\pm 14,8)	0,882
Mean Postoperative Hospitalisation Stay (day), mean (\pm SD)	1,1 (\pm 0,2)	1,0 (\pm 0,2)	0,647

PM Group: Polypropylene Mesh Group

SGM Group: Self Gripping Mesh Group

Table 2b: Surgery-Related Variables in elderly

Surgery-Related Variables	PM Group	SGM Group	P
Operative time (min), mean (\pm SD)	72,4 (\pm 10,8)	77,9 (\pm 13)	0,782
Mean Postoperative Hospitalisation Stay (day), mean (\pm SD)	1,0 (\pm 0,2)	1,0 (\pm 0,2)	0,777

PM Group: Polypropylene Mesh Group

SGM Group: Self-Gripping Mesh Group

nificant differences between two groups. The analysis of elderly group showed no significant difference.

A review of the Food and Drug Administration sets the incidence of hematoma after laparoscopic repair of inguinal hernia at < 1%, seroma at 4% and infection at 42%.

Table 3: Complications

Complications	PM Group	SGM Group	P	RR (95% CI)
Intraoperative complications				
Vascular lesions	0	1	0,313	0 (nv)
Deferential lesions	0	0	-	-
Early postoperative complications				
Hematoma	1	0	0,313	0 (nv)
Seroma	0	0	-	-
Orchitis	0	0	-	-
Wound infections	0	0	-	-
Neuralgia	0	0	-	-
Urinary problems	0	0	-	-
Late postoperative complications				
Testicular problems	0	0	-	-
Chronic pain	0	0	-	-
Mesh infection	0	0	-	-
Recurrence	1	0	0,313	0 (Nv)
Totale	2	1		

PM Group: Polypropylene Mesh Group

SGM Group: Self-Gripping Mesh Group

Nv: not evaluable

Table 4a: VAS Scale evaluation

Timing of valutation [Vas scale (cm)]	PM Group	SGM Group	P
Day 1 mean (\pm SD)	2,5 (\pm 0,8)	2,4 (\pm 0,8)	0,881
Day 2 mean (\pm SD)	1,1 (\pm 0,9)	1,0 (\pm 1,0)	0,701
Day 3 mean (\pm SD)	0,2 (\pm 0,6)	0,6 (\pm 0,9)	0,121

PM Group: Polypropylene Mesh Group

SGM Group: Self-Gripping Mesh Group

SD: standard deviation

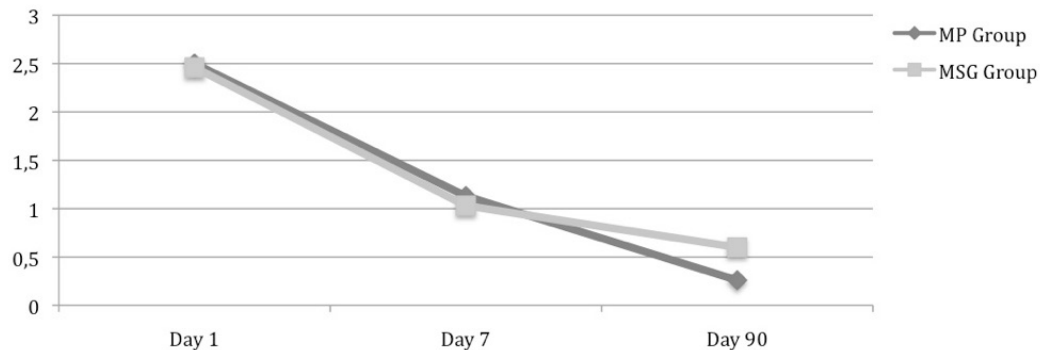
Table 4b: VAS Scale evaluation in elderly

Timing of valutation [Vas scale (cm)]	PM Group	SGM Group	P
Day 1 mean (\pm SD)	2,2 (\pm 0,7)	2,5 (\pm 0,6)	0,671
Day 2 mean (\pm SD)	1,1 (\pm 0,6)	1,0 (\pm 0,9)	0,698
Day 3 mean (\pm SD)	0,1 (\pm 0,6)	0,3 (\pm 0,9)	0,211

PM Group: Polypropylene Mesh Group

SGM Group: Self-Gripping Mesh Group

SD: standard deviation



MP Group: Mesh Polypropilene Group
 MSG Group: Mesh Self Gripping Group

Figure 2: VAS Scale valuation

The incidence of intraoperative complications reported in our study was in line with those reported in the literature (Table 3).

The most worrying complication is infection of the mesh. In some cases treatment with antibiotics is not sufficient to solve the problem and another operation may be needed to remove the mesh; this complication is made worse by a high rate of sepsis and mortality [72-76].

In our study there were no cases of mesh superinfection in either group.

Another serious complication that has been reported in the literature associated, above all, with open inguinal hernia repair is erectile dysfunction and subsequent inability to procreate [77-78].

None of the patients in either of our two groups reported sexual dysfunction or urological complications.

One typical complication of inguinal hernia repair is recurrence. In the literature, the recurrence rate following hernia repair has been reported from 8 to 17% of cases [17,79].

A meta-analysis to compare inguinal hernia repair with open and laparoscopic techniques revealed an incidence of recurrence of 2.7% with an open approach versus 5.5% with laparoscopy (transabdominal or totally extraperitoneal approach) with an average follow-up of 28 months [61].

In our study, there was one case of recurrence in the PM group; this occurred on the fifteenth day after surgery and was thus attributable to an erroneous technique with incorrect positioning of the mesh or inaccurate dilution of the glue.

Chronic postoperative pain was measured according to the modified definition of the International Association for the Study of Pain (IASP) [56].

Comparison of postoperative pain in the two study groups (assessed on the VAS) did not reveal any statistically significant differences during the hospital stay or at follow-up after seven days and three months; we believe this reflects the atraumatic nature of both fixation methods.

Cost analysis found the polypropylene mesh to be less cost-effective, owing to the high cost of the biological glue used for fixation. The cost of this system could be reduced by using smaller quantities of fibrin glue or alternative products such as cyanoacrylate [41], which has been found to guarantee good fixation even when only very small amounts are used; however, further prospective studies are needed to compare the different methods of fixation to test their actual efficacy and benefits.

This study has some limitations. First, the sample includes only male patients within a given age range.

Since it is reasonable to assume that hernia defects in females are similar, and possibly also easier to repair, women might also benefit from this type of procedure. Provided there are no co-pathologies that are contraindications for laparoscopic surgery, this technique could also be used equally effectively on patients aged more than 75 years.

Moreover, our sample included patients with just one primary or recurring defect; these findings cannot thus be applied with certainty to patients with a bilateral defect.

The study was limited to a small sample with an average follow-up of just 11 months. An average time of 11 months is reasonable for detecting early recurrences but prevents us from evaluating late recurrences.

Another limitation regards the use of two different surgeons, albeit from the same school and with similar experience; both surgeons used the same verified standard technique, although the evaluation of their similarity was based on their own self-assessment and was therefore not objective. Hopefully, the presence of specialized surgical tutors will make it possible for this operation to be performed by a large number of surgeons in different surgical settings, even during training [14,80-84].

Surgery seems to be more difficult in elderly patients [85], but we consider laparoscopy as feasible in emergency [86-89]. It is a secure technique in both young and elderly patients [90-96] and in repair of wound defects. The constant improvement of open and laparoscopic surgical procedures [97-104] and diagnostic techniques [105-118] have allowed a significant development in the field of wall defects.

In conclusion, the laparoscopic approach for inguinal hernia repair is a safe and effective procedure. The TAPP technique with self-gripping mesh has been found to be a valid alternative to TAPP repair with polypropylene mesh with fibrin glue fixation in terms of the incidence of recurrence, complications and chronic pain.

The lower cost of the procedure using self-gripping mesh also weighs in favor of this type of mesh.

Conflict of interest statement: Authors state no conflict of interest.

References

- [1] Bax T, Sheppard BC, Crass RA. Surgical Options in the Management of Groin Hernias, Oregon Health Sciences University, Portland, Oregon. *Am Fam Physician* 1999; 59:143-156
- [2] Rutkow IM, Robbins AW. Demographic, classificatory, and socioeconomic aspects of hernia repair in the United States. *Surg Clin North Am* 1993; 73:413-426
- [3] Ger R. The laparoscopic management of groin hernias. *Contemp Surg* 1991; 39: 15-19
- [4] Schultz L, Graber J, Pietrafitta J et al. Laser laparoscopic herniorrhaphy: a clinical trial, preliminary results. *J Laparoendosc Surg* 1990; 1:41-45
- [5] Corbitt J. Laparoscopic herniorrhaphy. *Surg Laparosc Endosc* 1991; 1:23-25
- [6] Filipi C, Fitzgibbons RJ, Salerno GM et al. Laparoscopic herniorrhaphy. *Surg Clin North Am* 1992; 72:1109-1124
- [7] Arregui ME, Davis CJ, Yucel O, Nagan RF. Laparoscopic mesh repair of inguinal hernia using a preperitoneal approach: a preliminary report. *Surg Laparosc Endosc* 1992; 2:53-58
- [8] Dion JM, Morin J. Laparoscopic inguinal herniorrhaphy. *Can J Surg* 1992; 35:209-212
- [9] Liem MSL, Van Der Graaf Y, Van Steensel CJ et al. Comparison of conventional anterior surgery and laparoscopic surgery for inguinal-hernia repair. *N Engl J Med* 1997; 336:1541-1547
- [10] The MRC Laparoscopic Groin Hernia Trial Group. Laparoscopic versus open repair of groin hernia: a randomised comparison. *Lancet* 1999; 354:185-190
- [11] Mc Cormack K, Scott NW, Go PM et al. Laparoscopic techniques versus open techniques for inguinal hernia repair. *Cochrane Database Syst Rev* 2003; 1:CD001785
- [12] Dulucq JL. Traitement des hernies de l'aïne par mise en place d'un patch prothétique sous-péritonéal en rétropéritonéoscopie. *Cahiers de Chir* 1991; 79:15-16
- [13] Moreno-Egea A, Torralba Martínez JA, Morales Cuenca G, Aguayo Albasini JK. Randomized clinical trial of fixation vs nonfixation of mesh in total extraperitoneal inguinal hernioplasty. *Arch Surg* 2004; 139:1376-1379
- [14] Bittner R, Leibl BJ, Jäger C et al. TAPP - Stuttgart technique and result of a large single center series. *J Minim Access Surg* 2006; 2:155-159
- [15] Bloor K, Freemantle N, Khadjesari Z et al. Impact of NICE guidance on laparoscopic surgery for inguinal hernias: analysis of interrupted time series. *BMJ* 2003; 326:578
- [16] De Lange DH, Kreeft M, Van Ramshorst GH et al. Inguinal hernia surgery in The Netherlands: are patients treated according to the guidelines? *Hernia* 2010; 14:143-148
- [17] Rosenberg J, Bisgaard T, Kehlet H et al. Danish Hernia Database recommendations for the management of inguinal and femoral hernia in adults. *Dan Med Bull* 2011; 58:C4243
- [18] Shaikh I, Olabi B, Wong VM et al. NICE guidance and current practise of recurrent and bilateral groin hernia repair by Scottish surgeons. *Hernia* 2011; 15:387-391
- [19] Karthikesalingam A, Markar SR, Holt PJ, Praseedom RK. Meta-analysis of randomized controlled trials comparing laparoscopic with open mesh repair of recurrent inguinal hernia. *Br J Surg* 2010; 97:4-11
- [20] Wauschkuhn CA, Schwarz J, Boekeler U, Bittner R. Laparoscopic inguinal hernia repair: gold standard in bilateral hernia repair? Results of more than 2,800 patients in comparison to literature. *Surg Endosc* 2010; 24:3026-3030
- [21] Bittner R, Arregui ME, Bisgaard T et al. Guidelines for laparoscopic (TAPP) and endoscopic (TEP) treatment of inguinal Hernia [International Endohernia Society (IEHS)]. *Surg Endosc* 2011; 25:2773-2843
- [22] Simons MP, Aufenacker T, Bay-Nielsen M et al. European Hernia Society guidelines on the treatment of inguinal hernia in adult patients. *Hernia* 2009; 13:343-403
- [23] Horstmann R, Hellwig M, Classen C et al. Impact of polypropylene amount on functional outcome and quality of life after inguinal hernia repair by the TAPP procedure using pure, mixed and titanium coated meshes. *World J Surg* 2006; 30:1742-1749
- [24] Langenbach MR, Schmidt J, Zirngibl H. Comparison of biomaterials: three meshes and TAPP for inguinal hernia. *Surg Endosc* 2006; 20:1511-1117

- [25] Langenbach MR, Schmidt J, Ubrig B, Zirngibl H. Sixty-month follow-up after endoscopic inguinal hernia repair with three types of mesh: a prospective randomized trial. *Surg Endosc* 2008; 22:1790-1797
- [26] Bringmann S, Wollert S, Osterberg J, Heikkinen T. Early results of a randomized multicenter trial comparing Prolene and Vypro II mesh in bilateral endoscopic extraperitoneal hernioplast (TEP). *Surg Endosc* 2005; 19:536-540
- [27] Katkhouda N. A new technique for laparoscopic hernia repair using fibrin sealant. *Surg Technol Int* 2004, 12:120-126
- [28] Lau H. Fibrin sealant versus mechanical stapling for mesh fixation during endoscopic extraperitoneal inguinal hernioplasty: a randomized prospective trial. *Ann Surg* 2005; 242:670-675
- [29] Lovisetto F, Zonta S, Rota E *et al.* Use of human fibrin glue (Tissucol) versus staples for mesh fixation in laparoscopic transabdominal preperitoneal hernioplasty: a prospective, randomized study. *Ann Surg* 2007; 245:222-231
- [30] Petter-Puchner AH, Fortelny R, Mittermayr R *et al.* Fibrin sealing versus stapling of hernia meshes in an onlay model in the rat. *Hernia* 2005; 9:322-329
- [31] Fortelny RH, Schwab R, Glaser KS *et al.* The assessment of quality of life in a trial on lightweight mesh fixation with fibrin sealant in transabdominal preperitoneal hernia repair. *Hernia* 2008; 12:499-505
- [32] Olmi S, Erba L, Bertolini A *et al.* Fibrin glue for mesh fixation in laparoscopic transabdominal preperitoneal (TAPP) hernia repair: indications, technique, and outcomes. *Surg Endosc* 2006; 20:1846-1850
- [33] Schwab R, Schumacher O, Junge K *et al.* Fibrin sealant for mesh fixation in Lichtenstein repair: biomechanical analysis of different techniques. *Hernia* 2007; 11:139-145
- [34] Schwab R, Schumacher O, Junge K *et al.* Biomechanical analyses of mesh fixation in TAPP and TEP hernia repair. *Surg Endosc* 2008; 22:731-738
- [35] Novik B, Hagedorn S, Mork UB *et al.* Fibrin glue for securing the mesh in laparoscopic totally extraperitoneal inguinal hernia repair: a study with a 40-month prospective follow-up period. *Surg Endosc* 2006; 20:462-467
- [36] Ten Hallers EJ, Jansen JA, Marres HA *et al.* Histological assessment of titanium and polypropylene fiber mesh implantation with and without fibrin tissue glue. *J Biomed Mater Res A* 2007; 80:372-380
- [37] Fortelny RH, Petter-Puchner AH, Khakpour Z *et al.* Spray application of fibrin sealant with an angled spray tip device in laparoscopic inguinal hernia repair. *Eur Surg* 2010; 42:171-176
- [38] Fortelny RH, Petter-Puchner AH, Ferguson J *et al.* A comparative biomechanical evaluation of hernia mesh fixation by fibrin sealant. *J Surg Res* 2011; 171:576-581
- [39] Katkhouda N, Mavor E, Friedlander MH *et al.* Use of fibrin sealant for prosthetic mesh fixation in laparoscopic extraperitoneal inguinal hernia repair. *Ann Surg* 2001; 233:18-25
- [40] Kulacoglu H. Current options in inguinal hernia repair in adult patients. *Hippokratia* 2011; 15:223-231
- [41] Kukleta JF, Freytag C, Weber M. Efficiency and safety of mesh fixation in laparoscopic inguinal hernia repair using n-butyl cyanoacrylate: long-term biocompatibility in over 1,300 mesh fixations. *Hernia* 2012; 16:153-162
- [42] Fortelny RH, Petter-Puchner AH, May C *et al.* The impact of atraumatic fibrin sealant vs. staple mesh fixation in TAPP hernia repair on chronic pain and quality of life: results of a randomized controlled study. *Surg Endosc* 2012; 26:249-254
- [43] Kingsnorth A, Gingell-Littlejohn M, Nienhuijs S *et al.* Randomized controlled multicenter international clinical trial of self-gripping Parietex™ ProGrip™ polyester mesh versus lightweight polypropylene mesh in open inguinal hernia repair: interim results at 3 months. *Hernia* 2012; 16:287-294
- [44] Chastan P. Tension-free open inguinal hernia repair using an innovative self-gripping mesh. *J Min Access Surg* 2006; 2:139-143
- [45] Lowham AS, Filipi CJ, Fitzgibbons RJ Jr *et al.* Mechanism of hernia recurrence after preperitoneal mesh repair: traditional and laparoscopic. *Ann Surg* 1997; 225:422-431
- [46] Tetik C, Arregui ME, Dulucq JL *et al.* Complications and recurrences associated with laparoscopic repair of groin hernias: a multi-institutional retrospective analysis. *Ann Surg* 1994; 8:1316-1323
- [47] Felix E, Scott S, Crafton B *et al.* Causes of recurrence after laparoscopic hernioplasty: a multicenter study. *Surg Endosc* 1998; 12:226-231
- [48] Phillips EH, Rosenthal R, Fallas M *et al.* Reasons for recurrence following laparoscopic hernioplasty. *Surg Endosc* 1995; 9:140-145
- [49] Eubanks S, Newman L 3rd, Goehring L *et al.* Meralgia paresthetica: a complication of laparoscopic herniorrhaphy. *Surg Laparosc Endosc* 1993; 3:381-385
- [50] Broin EO, Horner C, Mealy K *et al.* Meralgia paresthetica following laparoscopic inguinal hernia repair: an anatomical analysis. *Surg Endosc* 1995; 9:76-78
- [51] Felix EL, Harbertson N, Vartanian S. Laparoscopic hernioplasty: significant complications. *Surg Endosc* 1999; 13:328-331
- [52] Krishna A, Misra MC, Bansal VK *et al.* Laparoscopic inguinal hernia repair: transabdominal preperitoneal (TAPP) versus totally extraperitoneal (TEP) approach: a prospective randomized controlled trial. *Surg Endosc* 2012; 26:639-649
- [53] Fumagalli UR, Puccetti F, Elmore U *et al.* Self-gripping mesh versus staple fixation in laparoscopic inguinal hernia repair: a prospective comparison. *Surg Endosc* 2013; 27:1798-1802
- [54] Birk D, Pardo CG. Self gripping Parietex ProGrip™ Mesh in Laparoscopic Hernia Repair. Have we found the ideal implant? *Surg Technol Int* 2012; 22:93-100
- [55] Huskisson EC. Measurement of pain. *Lancet* 1974; 2:1127-1131
- [56] Alfieri S, Amid PK, Campanelli G *et al.* International guidelines for prevention and management of postoperative chronic pain following inguinal hernia surgery. *Hernia* 2011; 15:239-249
- [57] Page B, Paterson C, Young D *et al.* Pain from primary inguinal hernia and the effect of repair on pain. *Br J Surg* 2002; 89:1315-1318
- [58] Aasvang E, Kehlet H. Chronic postoperative pain: the case of inguinal herniorrhaphy. *Br J Anaesth* 2005; 95:69-76
- [59] Sato H, Shimada M, Kurita N *et al.* The safety and usefulness of the single incision, transabdominal pre-peritoneal (TAPP) laparoscopic technique for inguinal hernia. *Med Invest* 2012; 59:235-240
- [60] Bittner R, Sauerland S, Schmedt CG. Comparison of endoscopic techniques vs Shouldice and other open nonmesh

- techniques for inguinal hernia repair: a meta-analysis of randomized controlled trials. *Surg Endosc* 2005; 19:605-615
- [61] Stylopoulos N, Gazelle GS, Rattner DW. A cost–utility analysis of treatment options for inguinal hernia in 1,513,008 adult patients. *Surg Endosc* 2003; 17:180-189
- [62] French Associations for Surgical Research, Oberlin P, Boudet MJ et al. Recurrence after inguinal hernia repair: prognostic facts in a prospective study of 1706 hernias. *Br J Surg* 1995; 82: Suppl 1:65
- [63] Friis E, Lindahl F. The tension-free hernioplasty in a randomized trial. *Am J Surg* 1996; 172:315-319
- [64] Cunningham J, Temple WJ, Mitchell P et al. Cooperative hernia study: pain in the postrepair patient. *Ann Surg* 1996; 224:598-602
- [65] Kumar S, Wilson RG, Nixon SJ, Macintyre IM. Chronic pain after laparoscopic and open mesh repair of groin hernia. *Br J Surg* 2002; 89:1476-1479
- [66] Rowntree LG. National program for physical fitness: revealed and developed on the basis of 13,000,000 physical examinations of Selective Service registrants. *JAMA* 1944; 125:821-827
- [67] Robinson TN, Clarke JH, Schoen J, Walsh MD. Major mesh-related complications following hernia repair. Events reported to the Food and Drug Administration. *Surg Endosc* 2005; 19:1556-1560
- [68] Taylor SG, O'Dwyer PJ. Chronic groin sepsis following tension-free inguinal hernioplasty. *Br J Surg* 1999; 86:562-565
- [69] Ismail W, Agrawal A, Zia MI. Fate of chronically infected onlay mesh in groin wound. *Hernia* 2002; 6:79-81
- [70] Avtan L, Avci C, Bulut T, Fourtanier G. Mesh infections after laparoscopic inguinal hernia repair. *Surg Laparosc Endosc* 1997; 7:192-195
- [71] Tolino MJ, Tripoloni DE, Ratto R, Garcia MI. Infections associated with prosthetic repairs of abdominal wall hernias: pathology, management and results. *Hernia* 2009; 13:631-637
- [72] Gilbert AI, Felton LL. Infection in inguinal hernia repair considering biomaterials and antibiotics. *Surg Gynecol Obstet* 1993; 177:126-130
- [73] Shulman AG, Amid PK, Lichtenstein IL. The safety of mesh repair for primary inguinal hernias: results of 3,019 operations from five diverse surgical sources. *Am Surg* 1992; 58:255-257
- [74] McRoy LL. Plugoma and the prolene hernia system. *J Am Coll Surg* 2010; 212:424
- [75] Miller JP, Acar F, Kaimaktchiev VB et al. Pathology of ilioinguinal neuropathy produced by mesh entrapment: case report and literature review. *Hernia* 2008; 12:213-216
- [76] Fawole AS, Chaparala RPC, Ambrose NS. Fate of the inguinal hernia following removal of infected prosthetic mesh. *Hernia* 2006; 10:58-61
- [77] Ott V, Groebli Y, Schneider R. Late intestinal fistula formation after incisional hernia using intraperitoneal mesh. *Hernia* 2005; 9:103-104
- [78] Uzzo RG, Lemack GE, Morrissey KP et al. The effects of mesh bioprosthesis on the spermatic cord structures: a preliminary report in a canine model. *J Urol* 1999; 161:1344-1349
- [79] Bisgaard T, Bay-Nielsen M, Kehlet H. Re-recurrence after operation for recurrent inguinal hernia. A nationwide 8-year follow-up study on the role of type of repair. *Ann Surg* 2008; 247:707-711
- [80] Bokeler U, Schwarz J, Bittner R et al. Teaching and training in laparoscopic inguinal hernia repair (TAPP): impact of the learning curve on patient outcome. *Surg Endosc* 2013; 27:2886-2893
- [81] Bittner R, Schmedt CG, Schwarz J et al. Laparoscopic transperitoneal procedure for routine repair of groin hernia. *Br J Surg* 2002; 89:1062-1066
- [82] Wright D, O'Dwyer PJ. The learning curve for laparoscopic hernia repair. *Semin Laparosc Surg* 1998; 5:227-232
- [83] Liem MSL, Van Steensel CJ, Boelhouwer RU et al. The learning curve for totally extra-peritoneal laparoscopic inguinal hernia repair. *Am J Surg* 1996; 171:281-285
- [84] Neumayer L, Giobbie-Hurder A, Jonasson O et al. Open mesh versus laparoscopic mesh repair of inguinal hernia. *N Engl J Med* 2004; 350:1819-1827
- [85] Ferrarese A, Martino V, Falcone A, Solej M, Destefano I. Perforated Duodenal Diverticulum: Case Report and Short Review of the Literature. *Chirurgia* 2014; 27:129-131
- [86] Solej M, Martino V, Mao P, Enrico S, Rosa R, Fornari M, Destefano I, Ferrarese AG, Gibin E, Bindi F, Falcone A, Ala U, Nano M. Early versus delayed laparoscopic cholecystectomy for acute cholecystitis. *Minerva Chir* 2012; 67:381-387
- [87] Gentile V, Ferrarese AG, Marola S, Surace A, Borello A, Ferrara Y, Enrico S, Martino V, Nano M, Solej M. Perioperative and postoperative outcomes of perforated diverticulitis Hinchey II and III: Open Hartmann's procedure vs. laparoscopic lavage and drainage in the elderly *International Journal of Surgery* 2014; 12 suppl 2:86-89
- [88] Surace A, Marola S, Benvenga S, Borello A, Gentile V, Ferrarese AG, Enrico S, Martino V, Nano M, Solej M. Difficult abdominal access in laparoscopic cholecystectomy in elderly patients: Our experience and literature review. *International Journal of Surgery* 2014; 12 suppl 2:1-3
- [89] Berti S, Ferrarese AG, Feleppa C, Francone E, Martino V, Bianchi C, Falco E. Laparoscopic perspectives for distal biliary obstruction. *International Journal of Surgery* 2015; 21 suppl 1:64-67
- [90] Ferrarese AG, Martino V, Nano M. Elective and emergency laparoscopic cholecystectomy in the elderly: early or delayed approach, *BMC Geriatr* 2011; 11suppl 1:A14
- [91] Ferrarese AG, Martino V, Nano M. Wound defects in the elderly: our experience, *BMC Geriatr* 2011; 11: suppl 1:A15
- [92] Ferrarese AG, Solej M, Enrico S, Falcone A, Catalano S, Pozzi G, Marola S, Martino V. Elective and emergency laparoscopic cholecystectomy in the elderly: our experience, *BMC Surg* 2013; 13: suppl 2:21
- [93] Ferrarese AG, Martino V, Enrico S, Falcone A, Catalano S, Gibin E, Marola S, Surace A, Solej M. Laparoscopic repair of wound defects in the elderly: our experience of 5 years, *BMC Surg* 2013; 13: suppl 2:23
- [94] Ferrarese AG, Martino V, Enrico S, Falcone A, Catalano S, Pozzi G, Marola S, Solej M. Laparoscopic appendectomy in the elderly: our experience, *BMC Surg* 2013; 13: suppl 2:22
- [95] Ferrarese AG, Marola S, Surace A, Borello A, Bindi M, Cumbo J, Solej M, Enrico S, Nano M, Martino V. Fibrin glue versus stapler fixation in laparoscopic transabdominal inguinal hernia repair: A single center 5-year experience and analysis of the results in the elderly. *International Journal of Surgery* 2014; 12: suppl 1:94-98
- [96] Ferrarese AG, Enrico S, Solej M, Falcone A, Catalano S, Gibin E, Marola S, Surace A, Martino V. Transabdominal pre-peritoneal

- mesh in inguinal herniarepair in elderly: end point of our experience. *BMC Surg* 2013; 13: suppl 2:24
- [97] Allaix ME, Giraudo G, Ferrarese A et al. 10-Year Oncologic Outcomes After Laparoscopic or Open Total Mesorectal Excision for Rectal Cancer. *World J Surg* 2016; 14; in press
- [98] Eretta C, Ferrarese A, Olcese S et al. Celiac axis compression syndrome: laparoscopic approach in a strange case of Chronic abdominal pain in 71 years old man. *Open Med* 2016; 11: In press
- [99] Nano M, Martino V, Ferrarese A, Falcone A. A brief history of laparoscopy. *G Chir* 2012; (33); 3:53-57
- [100] Martino V, Ferrarese A, Bindi M et al. Abnormal right hepatic artery injury resulting in right hepatic atrophy: diagnosed by laparoscopic cholecystectomy. *Open Med* 2015; 10:535-537
- [101] Ferrarese A, Pozzi G, Borghi F et al. Malfunctions of robotic system in surgery: role and responsibility of surgeon in legal point of view. *Open Med* 2016; 11: In press
- [102] Ferrarese A, Pozzi G, Borghi F, Pellegrino L, Di Lorenzo P, Amato B, Santangelo M, Niola M, Martino V. Informed consent in robotic surgery: quality of information and patient perception. *Open Med* 2016; 11: In press
- [103] Ferrarese A, Solej M, Enrico S et al. Diagnosis of incidental gallbladder cancer after laparoscopic cholecystectomy: our experience. *BMC Surg* 2013; 13 Suppl 2:S20
- [104] Azoulay D, Castaing D, Dennison A et al. Transjugular intrahepatic portosystemic shunt worsens the hyperdynamic circulatory state of the cirrhotic patient: preliminary report of a prospective study. *Hepatology* 1994 Jan; 19(1):129-132
- [105] Pozzi G, Ferrarese A, Busso M et al. Percutaneous drainage and sclerosis of mesenteric cysts: literature overview and report of an innovative approach. *Int J Surg* 2014; 12 Suppl 2:S90-93
- [106] Martino V, Ferrarese A, Borello A et al. An unusual evolution of a case of Klippel-Trenaunay Syndrome. *Open Med* 2015; 10:498-501
- [107] Sandrucci S, Garrone C, Mobiglia A et al. Evaluation of the toxicity induced in rat by the intra-arterial cytostatic infusion and by hepatic dearterialization associated with systemic cytostatic therapy. *Bollettino e Memorie della Societa Piemontese di Chirurgia* 1989; 59(2):65-77
- [108] Muzio S, Cassini P, Martino V et al. Transcystic videolaparoscopy for choledocholithiasis with holmium: YAG laser lithotripsy. A case report. *Chir Ital* 2008; 60(1):119-123
- [109] Serra R, Grande R, Butrico L et al. Effects of a new nutraceutical substance on clinical and molecular parameters in patients with chronic venous ulceration. *Int Wound J* 2016; 13(1):88-96
- [110] Surace A, Ferrarese A, Benvenga R et al. ACTH-secreting neuroendocrine pancreatic tumor: a case report. *Int J Surg* 2014; 12 Suppl 1:222-224
- [111] Ferrarese A, Borello A, Gentile V et al. Meso-pancreatectomy for pancreatic neuroendocrine tumor. *Int J Surg* 2014; 12 Suppl 1:123-125
- [112] Serra R, Gallelli L, Conti A et al. The effects of sulodexide on both clinical and molecular parameters in patients with mixed arterial and venous ulcers of lower limbs. *Drug Des Devel Ther* 2014; 13;8:519-527
- [113] Priola AM, Priola SM, Volpicelli G et al. Accuracy of 64-row multidetector CT in the diagnosis of surgically treated acute abdomen. *Clin Imaging* 2013; 37(5):902-907
- [114] Ferrarese A, Enrico S, Solej M et al. Laparoscopic management of non-midline incisional hernia: A multicentric study. *Int J Surg* 2016 21; pii: S1743-9191(16)30181-9. doi: 0.1016/j.ijisu.2016.06.023. [Epub ahead of print]
- [115] Surace A, Ferrarese A, Marola S et al. Endorectal ultrasound in the diagnosis of rectal cancer: accuracy and criticisms. *Int J Surg* 2014; 12 Suppl 2:99-102
- [116] Surace A, Ferrarese A, Marola S et al. Abdominal compartment syndrome and open abdomen management with negative pressure devices. *Ann Ital Chir.* 2015; 86(1):46-50
- [117] Ferrarese A, Falcone A, Solej M et al. Surgeon's clinical valuation and accuracy of ultrasound in the diagnosis of acute appendicitis: A comparison with intraoperative evaluation. Five years experience. *Int J Surg* 2016;33 Suppl 1:45-50
- [118] Marola S, Ferrarese A, Solej M et al. Management of venous ulcers: State of the art. *Int J Surg* 2016 Jun 21; in press