

Annamaria Iagnocco · Angela Cerioni  
Giulio Coari · Alejandra Ossandon  
Raffaele Masciangelo · Guido Valesini

## Intra-articular methotrexate in the treatment of rheumatoid arthritis and psoriatic arthritis: a clinical and sonographic study

Received: 29 October 2004 / Revised: 25 March 2005 / Accepted: 25 March 2005 / Published online: 10 June 2005  
© Clinical Rheumatology 2005

**Abstract** The aim of our study was to evaluate the effects of intra-articular methotrexate (MTX) in patients with rheumatoid arthritis (RA) and psoriatic arthritis (PsA). Twenty-three consecutive patients, 10 with RA and 13 with PsA, with prevalent or unique arthritic involvement of one knee, were treated with intra-articular injections of MTX 10 mg every 7 days for 8 weeks. Before the beginning of the treatment and after 9 and 17 weeks, the patients underwent a clinical evaluation measuring maximal knee flexion angle, visual analog scale (VAS) and erythrocyte sedimentation rate (ESR). On the same days, an ultrasonographic examination of the involved knee was performed by two independent experienced operators. Synovial thickness in the suprapatellar bursa and the presence of joint effusion and Baker's cyst were assessed. An increase of the mean value of maximal knee flexion angle and a reduction of the mean values of ESR and VAS between T0, T9 and T17 were demonstrated. Ultrasonographic evaluation showed significant reduction of synovial thickness and joint effusion. No differences were detected for the presence of Baker's cyst. We may conclude that repeated intra-articular injections of MTX resulted in a decrease of local as well as systemic inflammatory signs. As far as we know, this is the first study that explores the effects of intra-articular MTX in RA and PsA both clinically and by ultrasonography.

**Keywords** Intra-articular methotrexate · Joint sonography · Psoriatic arthritis · Rheumatoid arthritis

**Abbreviations** ERS: Erythrocyte sedimentation rate · MTX: Methotrexate · PsA: Psoriatic arthritis · RA: Rheumatoid arthritis · US: Ultrasonography · VAS: Visual analog scale

### Introduction

Intra-articular therapy is an often-used procedure in the treatment of mono-oligoarthritis, especially because it has the advantage of conveying the drug directly to the inflamed joint area, thus avoiding major systemic side effects. This kind of therapeutic approach requires specialised knowledge of anatomy and physiology of the musculoskeletal system as well as understanding of the pathology of rheumatic disorders. When properly indicated and performed, it carries minimal risk for the patient. Many different compounds may be injected; among them, corticosteroids are the most commonly used [1–4].

The modern treatment of inflammatory arthritides includes the early administration of disease-modifying antirheumatic drugs (DMARDs), which are considered to be effective in inhibiting the progression of joint damage. Methotrexate (MTX) is one of the most frequently used, since it has been proved to influence the outcome of these diseases by reducing the incidence of erosions. MTX acts by inhibiting dihydrofolate reductase, an essential enzyme for the biosynthesis of purinic, thymidylic and inosinic acids [5, 6]. Therapeutic effects are also thought to be due to the inhibition of methylation reactions and the promotion of adenosine release [7, 8] with final inhibition of toxic oxygen metabolite release, lymphocyte proliferation and production of tumour necrosis factor alpha (TNF- $\alpha$ ), interleukin (IL)-6 and IL-8. MTX is also able to induce suppressor lymphocyte phenotype and function and to increase IL-10 production

A. Iagnocco (✉) · A. Cerioni · G. Coari  
A. Ossandon · G. Valesini  
Department of Clinical and Applied Medical Therapy,  
Rheumatology Unit, University of Rome "La Sapienza",  
Viale del Policlinico 155, Rome, 00161, Italy  
E-mail: annamaria.iagnocco@uniroma1.it  
Tel.: +39-6-490676  
Fax: +39-6-490676

R. Masciangelo  
Department of Experimental Medicine and Pathology,  
University of Rome "La Sapienza",  
Viale del Policlinico 155, Rome, 00161 Italy

[9–12]. MTX is usually administered weekly, with oral or parenteral low doses of 7.5–15 mg/week. Intra-articular administration has been reported, with possibly favourable results [13–15] and rare negative side effects [16]. The local use of the compound is supported by the aim of achieving maximal anti-inflammatory and immunosuppressive effects on the synovial membrane [17, 18].

The present study was undertaken to evaluate the effects of intra-articular MTX in patients with knee joint synovitis, due to rheumatoid arthritis (RA) or psoriatic arthritis (PsA). Patients' serial assessment was based on the evaluation of clinical and laboratory parameters and on an ultrasonographic examination of the affected knee. Ultrasonography (US) was chosen as the imaging modality of reference, since it has been successfully applied, in recent years, to the examination of joint alterations in many rheumatic disorders. In particular, US is currently considered a reliable imaging technique for the detection of joint effusion and synovial proliferation [19, 20], which represent two of the main consequences of synovitis [21, 22]. Moreover, due to the frequent communication between the gastrocnemiosemimembranous bursa and knee joint cavity, Baker's cysts can be frequently detected by US in the popliteal fossa when effusion is present.

As far as we know, this is the first study that evaluates the effects of intra-articular MTX in RA and PsA by US.

---

## Methods

### Patients

Twenty-three consecutive patients, 10 with RA and 13 with PsA, with prevalent or unique arthritic involvement of one knee, who attended the outpatient Rheumatology Unit of the "La Sapienza" University, Policlinico Umberto I of Rome, Italy, were recruited for the study. The PsA and RA patients satisfied the validated classification criteria for the correspondent disease [23, 24].

On the basis of the potential organ toxicity of MTX, patients with hepatic or pulmonary pathology were excluded from the study. Subjects with signs of any other rheumatic disease were also excluded. Knee involvement was confirmed by clinical evaluation.

All patients were under stable treatment with methylprednisolone 4 mg/day and diclofenac 100 mg/day for 2 months prior to the beginning of the study and carried on with this medication till the last follow-up. No other drug was added, no other intra-articular injection was performed and no topical application was used.

The involved knee was injected with 10 mg sodium salt MTX once a week for 8 weeks. The drug was diluted in a 3 ml saline solution. From the 9th week, MTX was administered orally at a dose of 7.5 mg/week. The patients were evaluated, both clinically and by US, before the beginning of the treatment (T0) and after 9 (T9) and 17 (T17) weeks.

### Clinical evaluation

Maximal knee flexion angle was measured using a goniometer, the visual analog scale (VAS) was calculated using a 10-cm horizontal scale with ten possible scores and a venous blood sample was taken to determine erythrocyte sedimentation rate (ESR) values.

### Sonography

US of the inflamed knee was performed with a 7.5-MHz linear probe (HP, Image Point HX System) by two different operators experienced in musculoskeletal US and blinded to the patient's diagnosis as well as clinical and laboratory data. The exams were carried out separately. The suprapatellar bursa was scanned for the measurement of synovial thickness and the detection of effusion, while the posterior calf was explored for the presence of Baker's cyst.

Synovial thickness was measured with the patient supine and the knee in neutral position as previously described [19, 25]. Measurements were done on the posterior wall of the synovial membrane, as it is better defined than the anterior wall, 2 cm above the superior pole of the patella, both in the transverse and longitudinal scans. The mean values of each couple of results were calculated. Measurements were repeated twice by both operators. According to previous studies [19], thickness of the synovial membrane was considered abnormal when higher than 3 mm. Joint effusion, secondary to synovitis, was diagnosed when hypoanechoic fluid collection was shown within the articular space [19, 25]. Finally, the presence of Baker's cyst was ascertained when fluid distension of the gastrocnemiosemimembranous bursa was demonstrated.

### Statistical analysis

Student's *t*-test, the general linear model (GLM) repeated measures procedure and McNemar's test were chosen to compare results. Findings were expressed by average and standard deviation parameters. Values of  $p < 0.05$  were considered to be statistically significant.

---

## Results

The ten RA subjects had polyarthritis with prevalent involvement of one knee. The group was formed by eight women and two men, with a mean age of 35.5 years (range: 24–45) and a mean disease duration of 6.3 years (range: 3–11). Among the 13 PsA patients, 5 had monoarthritis involving one knee (1 woman and 4 men, mean age: 32.4 years, range: 25–39, mean disease duration: 1.9 years, range: 1–3) and 8 had oligoarthritis with prevalent involvement of one knee (4 women and 4 men, mean age: 31.5 years, range: 20–42, mean disease

duration: 1.1 years, range: 1–3). Clinical and US findings are reported in Table 1.

Considering the total number of patients, maximal knee flexion angle (mean value) increased significantly between T0 (57.6°) and T9 (69.4°,  $p < 0.000$ ), between T9 and T17 (73.3°,  $p < 0.000$ ) and between T0 and T17 ( $p < 0.000$ ). Analysing the single diseases, significant differences were found in RA between T0 and T9 ( $p < 0.02$ ), T9 and T17 ( $p < 0.000$ ) and T0 and T17 ( $p < 0.002$ ); in PsA, differences were significant between T0 and T9 ( $p < 0.000$ ), T9 and T17 ( $p < 0.003$ ) and T0 and T17 ( $p < 0.000$ ).

A significant reduction was demonstrated in the mean values of the VAS between T0 (RA: 6.60, PsA: 6.41, total: 6.59) and T9 (RA: 4.31, PsA: 3.58, total: 3.89), between T9 and T17 (RA: 3.96, PsA: 3.23, total: 3.55) and between T0 and T17 ( $p < 0.000$ ) both in the single RA and PsA cohorts than in the group taken as a whole.

In the whole cohort of patients the mean values of ESR appeared significantly reduced between T0 (44.4 mm/h) and T9 (38.3 mm/h,  $p < 0.000$ ), between T9 and T17 (35.7 mm/h,  $p < 0.000$ ) and between T0 and T17 ( $p < 0.000$ ). Analysing the single diseases, significant differences were found in RA between T0 and T9 ( $p < 0.015$ ), T9 and T17 ( $p < 0.008$ ) and T0 and T17 ( $p < 0.001$ ); in PsA, differences were significant between T0 and T9 ( $p < 0.000$ ), T9 and T17 ( $p < 0.003$ ) and T0 and T17 ( $p < 0.000$ ).

The US examinations did not show a significant intraobserver (intraclass correlation coefficient 0.82–0.93,  $p < 0.0001$ ) and interobserver (intraclass correlation coefficient 0.85,  $p < 0.0001$ ) variability.

A significant reduction of the mean thickness of the synovial membrane (Fig. 1) was found in both groups of RA and PsA patients, as well as in the whole cohort examined, between T0 (RA: 5.72 mm, PsA: 5.34 mm, total: 5.50 mm) and T9 (RA: 5.05 mm, PsA: 4.69 mm, total: 4.83 mm), between T9 and T17 (RA: 4.80 mm, PsA: 4.54 mm, total: 4.65 mm) and between T0 and T17 with a  $p < 0.000$ .

When examining the whole cohort of patients, significant differences were present in the incidence of joint effusion between T0 (12 cases) and T9 (four joints,  $p < 0.027$ ) and between T0 and T17 (three knees,  $p < 0.008$ ). No significant difference was found within the single groups of RA and PsA patients, due to the low number of positive cases.

Since Baker's cyst was found only in a limited number of patients (T0: five cases, T9: two knees, T17: one joint), statistical analysis did not show significant differences during the follow-up.

## Discussion

One of the main characteristics of RA and PsA is the presence of synovitis, which provokes the appearance of joint effusion and synovial proliferation, due to synovial hyperplasia and hypertrophic changes [20–22, 26]. The

Table 1 Results for sonographic and clinical parameters

Mean value	RA (T0)	RA (T9)	RA (T17)	PsA (T0)	PsA (T9)	PsA (T17)	Total <sup>a</sup> (T0)	Total <sup>a</sup> (T9)	Total <sup>a</sup> (T17)
Synovial membrane (mm)	5.72 (SD 0.78)	5.05 (SD 0.87)	4.80 (SD 0.68)	5.34 (SD 0.55)	4.69 (SD 0.53)	4.54 (SD 0.57)	5.50 (SD 0.67)	4.83 (SD 0.68)	4.65 (SD 0.62)
ESR (mm/h)	47.1 (SD 10.50)	42.5 (SD 9.83)	40.7 (SD 9.73)	42.3 (SD 11.81)	35.2 (SD 9.71)	31.8 (SD 7.95)	44.4 (SD 11.34)	38.3 (SD 10.24)	35.7 (SD 9.68)
VAS	6.60 (SD 0.96)	4.31 (SD 0.66)	3.96 (SD 0.49)	6.41 (SD 0.91)	3.58 (SD 0.70)	3.23 (SD 0.54)	6.59 (SD 0.93)	3.89 (SD 0.69)	3.55 (SD 0.63)
Knee flexion angle	47.5° (SD 14.5)	55.2° (SD 10.3)	60.3° (SD 11.4)	65.3° (SD 16.7)	80.3° (SD 14.8)	84.1° (SD 16.4)	57.6° (SD 17.9)	69.4° (SD 18.2)	73.7° (SD 18.6)
Joint effusion (number of joints)	5	2	1	7	2	2	12	4	3
Baker's cysts (number of joints)	2	1	0	3	1	1	5	2	1

<sup>a</sup>Total patients (RA + PsA)

entity of these alterations is strictly correlated to the activity and severity of the inflammatory process [20, 25, 26]. The US analysis reliably detects both abnormalities and it is thus considered an accurate imaging method for the study of synovitis [19, 27–29]. Previous studies demonstrated that magnetic resonance analysis of a single sagittal slice and US measurements of synovial thickness in the suprapatellar bursa are reliable and accurate methods for the quantification of the severity of the inflammatory process in RA and in Sjögren's syndrome patients [19, 30, 31].

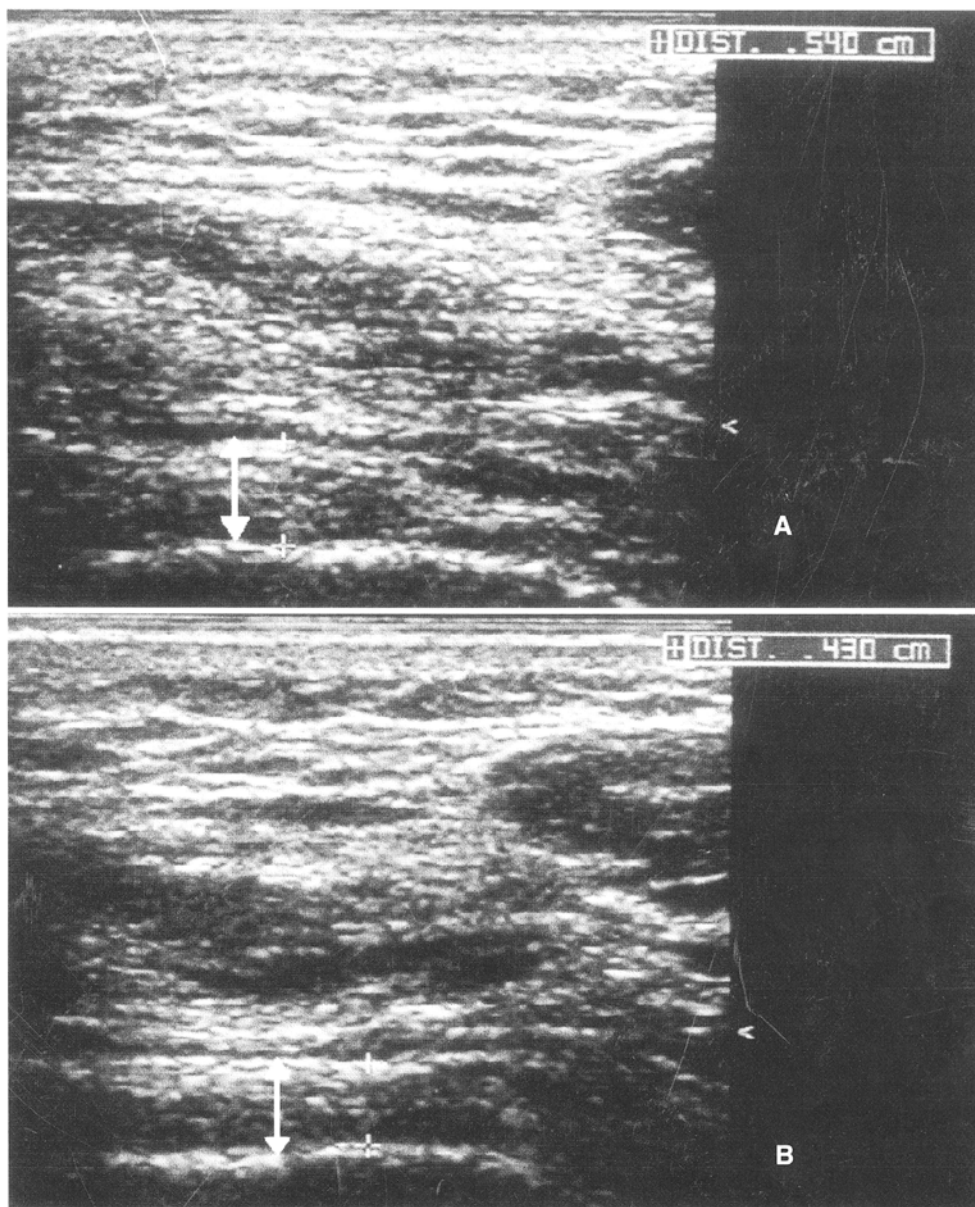
The use of colour and power Doppler has recently made the application of US in the evaluation of synovitis possible. Unfortunately, due to the lack of standardization of different parameters, these techniques are still considered very user dependent [20] and often present difficulties in the quantification of alterations.

The effects of intra-articular MTX have been previously evaluated with controversy and inconstantly favourable results [16–18, 32–37]. As far as we know, this is the first study that investigates the effects of intra-articular MTX in RA and PsA both clinically and by ultrasound.

Our findings suggest a local anti-inflammatory action of MTX, demonstrated by the reduction of the signs of synovitis (joint effusion and synovial thickness) in the serial US examinations of the treated knees in both RA and PsA patients. The positive effect of the drug is also supported by the increase of the mean maximal knee flexion angle, the decrease of the mean VAS values and the significant reduction of the mean ESR values.

In conclusion, the present report confirms the important role played by US in the depiction of knee

**Fig. 1** Sonography of the knee in a patient with PsA. The thickness of the synovial membrane (↓) is measured in the suprapatellar bursa (transverse scan). **a** Thickness of the synovial membrane before the beginning of the intra-articular MTX treatment. **b** Thickness of the synovial membrane 17 weeks after the beginning of the intra-articular MTX treatment



joint synovitis in chronic arthritides. The use of intra-articular MTX appeared to be effective in reducing local inflammatory activity. Further studies are warranted to confirm this result and to demonstrate the possible systemic effects of this local treatment.

The non-invasiveness, low cost, reproducibility and quickness of US represent relevant advantages in respect to other more expensive and scarcely available imaging methods. These characteristics render ultrasound an important and manageable tool in the assessment of synovitis in arthritic patients as well as in the evaluation of the effects of treatment.

## References

- Canoso JJ (1998) Aspiration and injection of joints and periarthicular tissues. In: Klippel JH, Dieppe PA (eds) *Rheumatology*. Mosby, London, pp 2.12.1–2.12.12
- Altman RD, Moskowitz R (1998) Intra-articular sodium hyaluronate (Hyalgan) in the treatment of patients with osteoarthritis of the knee: a randomized clinical trial. *Hyalgan Study Group. J Rheumatol* 25:2203–2212
- Listrat V, Ayrat X, Patarnello F et al (1997) Arthroscopic evaluation of potential structure modifying activity of hyaluronan (Hyalgan) in osteoarthritis of the knee. *Osteoarthritis Cartilage* 5:153–160
- Frizziero L, Govoni E, Bacchini P (1998) Intra-articular hyaluronic acid in the treatment of osteoarthritis of the knee: clinical and morphological study. *Clin Exp Rheumatol* 16:441–449
- Songsiridej N, Furst DE (1990) Methotrexate: the rapidly acting drug. *Baillieres Clin Rheumatol* 4:575–593
- Segal R, Yaron M, Tartakovsky B (1990) Methotrexate: mechanism of action in rheumatoid arthritis. *Semin Arthritis Rheum* 20:190–199
- Davis JC, Klippel JH (1999) Antimalarials and immunosuppressive drugs. In: Lahita RG (ed) *Systemic lupus erythematosus*. Academic Press, San Diego, pp 976–977
- Seitz M (1999) Molecular and cellular effects of methotrexate. *Curr Opin Rheumatol* 11:226–232
- Gruber HE, Hoffer ME, McAllister DR et al (1989) Increased adenosine concentration in blood from ischemic myocardium by AICA-riboside: effects on flow, granulocytes and injury. *Circulation* 80:1400–1411
- Barankiewicz J, Ranlov G, Jimenez R, Gruber HE (1990) Selective adenosine release from human B but not T lymphoid cell line. *J Biol Chem* 265:15738–15743
- Kremer JM (1994) The mechanism of action of methotrexate in rheumatoid arthritis: the search continues. *J Rheumatol* 21:1–5
- Genestier L, Paillot R, Fournel S, Ferraro C, Miossec P, Revillard JP (1998) Immunosuppressive properties of methotrexate: apoptosis and clonal deletion of activated peripheral T cells. *J Clin Invest* 102:322–328
- Hall GH, Head AC (1975) Intraarticular methotrexate. *Lancet* 2:409
- Marks JS, Stewart IM, Hunter JA (1976) Intra-articular methotrexate in rheumatoid arthritis. *Lancet* 2:857–858
- Mussini C, Manzini E, Curci G, Zaniol P, Fiochi R (1978) Intraarticular use of 4-amino-N10-methyl-pteroyl-glutamic acid (methotrexate) for the treatment of rheumatoid synovitis. *Chir Organi Mov* 64:193–198
- Alamo M, Grisanti M (1991) Methotrexate in rheumatoid arthritis. *Rev Med Chil* 119:691–700
- Hall GH, Jones BJ, Head AC, Jones VE (1978) Intra-articular methotrexate. Clinical and laboratory study in rheumatoid and psoriatic arthritis. *Ann Rheum Dis* 37:351–356
- Franchi F, Seminara P, Codacci-Pisanelli G, Aronne T, Avella A, Bonomo L (1989) Intra-articular methotrexate in the therapy of rheumatoid arthritis. *Recenti Prog Med* 80:261–262
- Iagnocco A, Coari G, Palombi G, Valesini G (2002) Knee joint synovitis in Sjögren's syndrome. Sonographic study. *Scand J Rheumatol* 31:291–295
- Giovagnorio F, Martinoli C, Coari G (2001) Power Doppler sonography in knee arthritis—a pilot study. *Rheumatol Int* 20:101–104
- Rubaltelli L, Fiocco U, Cozzi L et al (1994) Prospective sonographic and arthroscopic evaluation of proliferative knee joint synovitis. *J Ultrasound Med* 13:855–862
- Henderson B, Hedwards JCW (1987) Structural and microscope changes. In: Henderson B, Hedwards JCW (eds) *The synovial lining in health and disease*. Chapman & Hall, London, pp 233–237
- Moll JM, Wright V (1973) Psoriatic arthritis. *Semin Arthritis Rheum* 3:55–78
- Arnett FC, Edworthy SM, Bloch DA et al (1988) The American Rheumatism Association 1987 revised criteria for the classification of rheumatoid arthritis. *Arthritis Rheum* 31:315–324
- Coari G, Iagnocco A, Maggi S et al (1996) Sonographic findings in haemodialysis-related chronic arthropathy. *Eur Radiol* 6:890–894
- Østergaard M, Gideon P, Henriksen O, Lorensen I (1994) Synovial volume—a marker of disease severity in rheumatoid arthritis? Quantification by MRI. *Scand J Rheumatol* 23:197–202
- Hammer M, Mielke H, Wagener P, Schwarzrock R, Giebel G (1986) Sonography and NMR imaging in rheumatoid gonarthrosis. *Scand J Rheumatol* 15:157–164
- Wyld PJ, Dawson KP, Chisholm RJ (1984) Ultrasound in the assessment of synovial thickening in the hemophilic knee. *Aust N Z J Med* 14:678–680
- Van Holsbeeck M, Van Holsbeeck K, Gevers G et al (1988) Staging and follow-up of rheumatoid arthritis of the knee. Comparison of sonography, thermography and clinical assessment. *J Ultrasound Med* 7:561–566
- Østergaard M, Stoltenberg M, Lovgreen-Nielsen P, Volck B, Jensen CH, Lorensen I (1997) Magnetic resonance imaging-determined synovial membrane and joint effusion volumes in rheumatoid arthritis and osteoarthritis: comparison with the macroscopic and microscopic appearance of the synovium. *Arthritis Rheum* 40:1856–1867
- Clunie G, Hall-Craggs MA, Paley MN et al (1997) Measurement of synovial lining volume by magnetic resonance imaging of the knee in chronic synovitis. *Ann Rheum Dis* 56:526–534
- Bird HA, Ring EF, Daniel R, Bacon PA (1977) Comparison of intra-articular methotrexate with intra-articular triamcinolone hexacetonide by thermography. *Curr Med Res Opin* 5:141–146
- Foong WC, Green KL (1993) Treatment of antigen-induced arthritis in rabbits with liposome-entrapped methotrexate injected intra-articularly. *J Pharm Pharmacol* 45:204–209
- Williams AS, Camilleri JP, Goodfellow RM, Williams BD (1996) A single intra-articular injection liposomally conjugated methotrexate suppresses joint inflammation in rat antigen-induced arthritis. *Br J Rheumatol* 35:719–724
- Gao IK, Leins C, Bohlen H, Heilig B, Lemmel EM (1988) Inhibition of interleukin-8 synthesis by intraarticular methotrexate therapy in patients with rheumatoid arthritis. *Z Rheumatol* 57:95–100
- Blyth T, Stirling A, Coote J, Land D, Hunter JA (1998) Injection of the rheumatoid knee: does intra-articular methotrexate or rifampicin add to the benefits of triamcinolone hexacetonide? *Br J Rheumatol* 37:770–772
- Williams AS, Topley N, Dojcinov S, Richards PJ, Williams BD (2001) Amelioration of rat antigen-induced arthritis by liposomally conjugated methotrexate is accompanied by down-regulation of cytokine mRNA expression. *Rheumatology* 40:375–383