

# Power Doppler ultrasound of the hand and wrist joints in systemic sclerosis

A. Iagnocco, C. Vavala, M. Vasile, K. Stefanantoni, G. Valesini, V. Ricciari

Dipartimento di Medicina Interna  
e Specialità Mediche, Reumatologia,  
Sapienza Università di Roma, Rome, Italy.

Annamaria Iagnocco, MD, Assist. Prof.

Caterina Vavala, MD

Massimiliano Vasile, MD

Katia Stefanantoni, MD

Guido Valesini, Prof.

Valeria Ricciari, Assist. Prof.

Please address correspondence to:

Annamaria Iagnocco, MD,

Dipartimento di Medicina Interna  
e Specialità Mediche, Reumatologia,

Sapienza Università di Roma,

Policlinico Umberto I,

Viale del Policlinico 155,

00161 Roma, Italy.

E-mail: [annamaria.iagnocco@uniroma1.it](mailto:annamaria.iagnocco@uniroma1.it)

Received on December 30, 2011; accepted  
in revised form on July 5, 2012.

*Clin Exp Rheumatol* 2013; 31 (Suppl. 76):  
S89-S95.

© Copyright CLINICAL AND  
EXPERIMENTAL RHEUMATOLOGY 2013.

**Key words:** systemic sclerosis,  
ultrasound, power Doppler, hand,  
wrist

## ABSTRACT

**Objectives.** This paper aims to investigate the prevalence and severity of hand and wrist joints power Doppler (PD) ultrasound (US) detected abnormalities in systemic sclerosis (SSc).

**Methods.** Hand and wrist joints of 46 consecutive SSc patients and 15 healthy controls were studied by using PDUS. Each joint was evaluated for the presence of effusion, synovial hypertrophy, hyperaemia, bone erosions and cortical irregularities; in addition, local tendons for tenosynovitis and hyperaemia, and median nerve for entrapment neuropathy were examined.

**Results.** Synovial hypertrophy was detected in 3% hand joints and in 46% wrists of SSc patients, with significant differences respect to controls ( $p=0.000004$  and  $0.000001$ , respectively). The prevalence of PD positivity was significantly higher in patients' hand joints (1.7%,  $p=0.001527$ ) and wrists (43%,  $p=0.000001$ ) than in healthy individuals. Seven percent of hand and 54% of wrist joints resulted to be positive for joint effusion with significant differences from controls ( $p=0.000001$  and  $p=0.000013$ , respectively). The prevalence of cortical irregularities was significantly higher ( $p=0.006$ ) than healthy subjects only at hand joints level. No significant difference was found for bone erosions. Tenosynovitis was found in 6% out of the 1.196 synovial tendon sites examined of SSc patients with significant differences compared to healthy subjects ( $p=0.000001$ ); PD resulted to be positive in 29% of them, with significant differences compared to controls ( $p=0.0038$ ).

**Conclusion.** This study, focused on hand and wrist joints PDUS assessment of inflammatory and structural abnormalities in SSc, demonstrated a varied and complex involvement both at joint and periarticular tissues level, showing that wrists were more frequently the site of inflammatory findings.

## Introduction

Systemic sclerosis (SSc) is a chronic connective tissue disease characterised by microvascular damage and deposition of collagen in the skin and internal organs. Its etiology and pathogenesis have not been clearly identified, yet. Patients with SSc are usually young or middle-age women (female-to-male ratio approximately 8:2), and often develop joint involvement, especially at the level of the hands and feet, with arthralgia and/or arthritis and/or flexion contractures (1-5). Articular involvement constitutes a determinant of disability and is usually evaluated by clinical examination and conventional radiography. The main hand radiologic features are represented by erosions, joint space narrowing, demineralisation, acro-osteolysis, flexion contracture and calcinosis (3, 4, 6, 7).

Musculoskeletal ultrasound (US) is a useful imaging tool to assess joint and soft tissue involvement in connective tissue diseases (8); it is a harmless, non-invasive and relatively low-cost technique that can give useful information about a wide range of abnormalities appearing at joint and soft tissue levels in rheumatic patients. Particularly in recent years, US has proved to have a relevant role in the assessment of joint inflammation and structural alterations in patients with different rheumatic disorders. Using US, it is possible to study synovial joints and periarticular soft tissues for the occurrence of inflammatory lesions (such as synovitis, tenosynovitis and bursitis), bone changes and cartilaginous abnormalities (9-17). Moreover, the use of power Doppler (PD) modality allows to study local vascularisation and to detect the presence of pathological hyperaemia, which is considered as an index of active inflammation (18). The role of US in the assessment of musculoskeletal abnormalities in SSc patients is yet to be defined and only limited focus on the evaluation of

Competing interests: none declared.

hand and wrist joint changes has been developed so far, even though this often represents a serious concern in that disease (8). Thus, by using US combined with PD and including both assessment of inflammatory changes and structural alterations, the aims of the present study were to investigate the prevalence and severity of hand and wrist joints abnormalities in SSc patients and to compare PD-US-detected findings with clinical and laboratory data.

### Patients and methods

Forty-six patients with SSc consecutively admitted to the outpatient clinic of the Rheumatology Unit of Sapienza Università di Roma and fulfilling the preliminary American College of Rheumatology (ACR) criteria for the classification of SSc were investigated (19). The presence of any other rheumatic disease or of an overlap syndrome was an exclusion criterion for the patients enrolment. In addition, 15 healthy subjects, selected among the staff of our Rheumatology unit on the basis of a voluntary enrolment, were examined as controls. Informed consent was obtained from all participants according to the declaration of Helsinki. The study was approved by local ethic committee.

All patients and controls underwent clinical evaluation, laboratory tests and PD-US assessment in the same day.

#### *Clinical and laboratory assessment*

An expert rheumatologist, blinded to ultrasonographic findings, performed a detailed clinical assessment including evaluation of different organs and systems (lung, esophagus, heart, cutis), hand and wrist joints involvement (pain, swelling, functional limitation and tendon friction rubs), nailfold capillaroscopy, and laboratory investigations (blood cell count, erythrocyte sedimentation rate [ESR], C-reactive protein [CRP], complement fractions C3 and C4, renal function evaluation, antinuclear antibodies, including anti-centromere antibodies [ACA], antibodies against topoisomerase I [Scl-70]).

#### *US examination*

After clinical assessment and on the same day, US examination was per-

formed by an expert rheumatologist, blinded to clinical and laboratory features either if the subjects were SSc patients or healthy controls, who assessed, bilaterally, wrist and hand joints (radio-ulno-carpal [RUC], inter-carpal [IC], carpo-metacarpal [CMC], metacarpophalangeal [MCP], proximal interphalangeal [PIP], distal interphalangeal joints [DIP]), flexor and extensor tendons at hand and wrist level (1°-6° extensor compartments, flexor carpi radialis, flexor digitorum superficialis and profundus, flexor pollicis longus, 2° digitorum flexor tendons, 3° digitorum flexors, 4° digitorum flexors, 5° digitorum flexors), and the median nerve. The US examination was conducted by using a multiplanar scanning technique, according to published guidelines (12-17, 20). A Logiq9 machine (General Electric, Medical Systems, Milwaukee, WI, USA) equipped with a 9-15 linear probe was used (gain 50%) and PD (7.5MHz; gain 50%; PRF 0.5kHz, low filter) was applied to assess local synovial vascularisation. Each joint was evaluated for the presence of effusion, synovial hypertrophy, hyperaemia, bone erosions and cortical irregularities; in addition, local tendons for the occurrence of tenosynovitis and hyperaemia, and median nerve for assessment of cross sectional area were examined. All abnormalities were registered according to the reported definitions of the literature, as follows (21-23): joint effusion as an abnormal hypoechoic or anechoic intra-articular material that is displaceable and compressible, but does not exhibit Doppler signal; synovial hypertrophy as an abnormal hypoechoic intra-articular tissue non-displaceable and poorly compressible and which may exhibit Doppler signal; bone erosions as an intra-articular discontinuity of the bone surface that is visible in 2 perpendicular planes; cortical irregularities as loss of continuity of cortical bone without any clear evidence of erosion/osteophyte/fracture; tenosynovitis as hypoechoic or anechoic thickened tissue with or without fluid within the tendon sheath, which is seen in 2 perpendicular planes and which may exhibit Doppler signal; increased median nerve cross sectional area (>12 mm<sup>2</sup>).

A 4-point-semi-quantitative-scale (0-3: 0=absent; 1=mild; 2=moderate; 3=severe) was used to indicate the degree of effusion, synovial hypertrophy and PD signal at joint level (24). A similar scoring system was used to determine the grade of tenosynovitis. Bone erosions and abnormal median nerve were assessed on a dichotomous scale (present/absent).

#### *Statistical analysis*

Data were presented as mean±SD. Categorical data were analysed using Fisher's exact two-tailed test. Differences between groups were analysed using the Mann-Whitney U-test. A value of  $p < 0.05$  was considered as statistically significant.

### Results

Demographic, clinical and laboratory findings in SSc patients and in healthy subjects are reported in Tables I and II. We investigated 46 patients (42 women and 4 men; median age 62 years, range 38-77) with SSc, consecutively referring to our Rheumatology Unit; mean disease duration was 136 months (range 7-528); 28 patients had a limited (lcSSc) form (2 men and 26 women; median age 64 [range 39-77]; mean disease duration 128 months [range 7-328]) and 18 a diffuse (dcSSc) (2 women and 16 men; median age 56 [range 39-76]; mean disease duration 149 months [range 24-528]) form of disease. Treatment included low dose of prednisone (4/5 mg/day) (15 dcSSc and 10 lcSSc), DMARDs therapy (5 dcSSc and 5 lcSSc), vasodilators (16 dcSSc and 19 lcSSc), antiplatelet (8 dcSSc and 25 lcSSc) and NSAIDs (4 dcSSc and 6 lcSSc) drugs. In addition, 15 healthy subjects, selected among the staff of our Rheumatology unit on the basis of a voluntary enrolment, were examined as controls (10 women and 5 men; median age 51 years, range 30-59).

Clinical evaluation of hand and wrist joints revealed the following findings: painful joints in 29 out of 92 (31.5%) wrists, 56 out of 460 (12%) MCP, 68 out of 460 (14.7%) PIP, 46 out of 368 DIP (12.5%) and in 4 out of 92 (4.3%) CMC joints. Swollen joints were de-

**Table I.** Demographic, organs and laboratory features in patients and healthy subjects.

Demographic, organs and laboratory features	SSc (n=46)	lcSSc (n=28)	dcSSc (n=18)	HS (n=15)
Gender: men/women (ratio)	4/42 (0.095)	2/26	2/16	5/10 (0.5)
Age: mean (range), years	62 (38–77)	64 (39–77)	56 (39–76)	51 (30–59)
Disease duration: mean (range), months	136 (7–528)	128 (7–384)	149 (24–528)	–
Pulmonary hypertension: yes/no	15/31	9/19	6/12	–
Lung fibrosis: yes/no	25/21	12/16	13/5	–
Esophageal involvement: yes/no	31/15	15/13	16/2	–
Ulcers: yes/no	19/27	8/20	11/7	–
Skin score: $\geq 14$ / $<14$	15/31	2/26	13/5	–
Videocapillaroscopy: late/early or active	16/30	6/22	10/8	–
ESR: mean	21.8 mm/h	24.2 mm/h	17.7 mm/h	–
CRP: positive/negative	6/40	4/24	2/16	–
ACA positive	25	21	4	–
Scl-70 positive	14	3	11	–
Hypocomplementaemia: yes/no	3/43	1/27	2/16	–

SSc: total patients with systemic sclerosis; lcSSc: patients with limited form of systemic sclerosis; dcSSc: patients with diffuse form of systemic sclerosis; HS: healthy subjects; ESR: erythrocyte sedimentation rate; CRP: C-reactive protein; ACA: anti-centromere antibodies; Scl-70: antibodies against topoisomerase I.

**Table II.** Hand and wrist involvement in patients and healthy subjects.

Findings	SSc (n=46)	lcSSc (n=28)	dcSSc (n=18)	HS (n=15)
Wrist pain: yes/no	17/29	7/21	10/8	–
Hand pain: yes/no	18/28	12/16	6/12	–
Wrist swelling: yes/no	4/42	1/27	3/13	–
Hand swelling: yes/no	14/32	10/18	4/14	–
Functional limitation wrist: yes/no	13/33	3/25	10/8	–
Functional limitation hand: yes/no	28/18	12/16	16/2	–
Tendon friction rubs: yes/no	10/36	2/26	8/10	–

SSc: total patients with systemic sclerosis; lcSSc: patients with limited form of systemic sclerosis; dcSSc: patients with diffuse form of systemic sclerosis; HS: healthy subjects.

**Table III.** Ultrasonographic findings in hand and wrist joints of SSc patients and healthy subjects: numbers of involved joints.

US findings	Synovial hypertrophy	Power Doppler	Joint effusion	Erosions SSc/HS	Cortical irregularities
	SSc/HS <i>p</i> -value	SSc/HS <i>p</i> -value	SSc/HS <i>p</i> -value	<i>p</i> -value	SSc/HS <i>p</i> -value
MCP	21 (4.6%)/0 <i>p</i> =0.003560	13 (2.8%)/0 <i>p</i> =0.045447	49 (10.6%)/1(3.3%) <i>p</i> =0.000010	3 (0.6%)/0 n.s.	1 (0.2%)/0 n.s.
PIP	20 (4.3%)/0 <i>p</i> =0.006121	8 (1.8%)/0 n.s.	42 (9.9%)/0 <i>p</i> =0.000007	0/0 n.s.	9 (1.9%)/0 n.s.
DIP	3 (0.8%)/0 n.s.	3 (0.8%)/0 n.s.	14 (3.8%)/0 <i>p</i> =0.026434	0/0 n.s.	9 (2.4%)/0 n.s.
IC	1 (1.1%)/0 n.s.	1(1.1%)/0 n.s.	1 (1.1%)/0 n.s.	0/0 n.s.	0/0 n.s.
CMC	0/0 n.s.	0/0 n.s.	0/0 n.s.	0/0 n.s.	0/0 n.s.
Total hand joints involvement	45 (3%)/0 <i>p</i> =0.000004	25 (1.7%)/0 <i>p</i> =0.001527	106 (7%)/0 <i>p</i> =0.000001	3 (0.2%)/0 n.s.	19 (1.3%)/0 <i>p</i> =0.006
RUC	44 (46%)/0 <i>p</i> =0.000001	40 (43%)/0 <i>p</i> =0.000001	50 (54%)/3(10%) <i>p</i> =0.000013	2 (2%)/0 n.s.	2 (2%)/0 n.s.

MCP: metacarpophalangeal; PIP: proximal interphalangeal; DIP: distal interphalangeal; IC: intercarpal; CMC: carpo-metacarpal; RUC: radio-ulno-carpal; SSc: numbers of involved joints in total patients (n=46) with systemic sclerosis; HS: numbers of involved joints in healthy subjects. n.s.: non significant *p*-value.

tected in 8 out of 92 (8.7%) wrists, 23 out of 460 (5%) MCP, 61 out of 460 (13.2%) PIP and in 45 out of 368 (12.2%) DIP joints. Limited motion was found in 17 out of 92 (18.4%) wrists, 65 out of 460 (14.1%) MCP, 94 out of 460 (20.4%) PIP and in 106 out of 368 (28.8%) DIP joints. Globally, at wrist level pain was found in 17 patients (7 lcSSc and 10 dcSSc), swelling in 4 (1 lcSSc and 3 dcSSc) and functional limitation in 13 patients (3 lcSSc and 10 dcSSc); at hand level pain was present in 18 patients (12 lcSSc and 6 dcSSc), swelling in 14 (10 lcSSc and 4 dcSSc) and functional limitation in 28 patients (12 lcSSc and 16 dcSSc); 10 patients (2 lcSSc and 8 dcSSc) presented tendon friction rubs (TFR) (Table II).

Serological parameters showed ESR median as 21.8 mm/h (range 4–62); CRP was positive in 6 patients; 25 and 14 resulted positive for ACA and Scl70 antibodies, respectively; hypocomplementaemia was present in only 3 patients. All differences regarding clinical and laboratory assessment between lcSSc and dcSSc subgroups are reported in Table I. Ultrasonographic features at hand and wrist joints and tendons level are reported in Tables III, IV, V, VI and VII and in Figure 1.

In particular, synovial hypertrophy was detected in 3% of hand and in 46% wrist joints of SSc patients (Fig. 1A), of with significant differences compared to controls (*p*=0.000004 and 0.000001, respectively). The prevalence of PD positivity was significantly higher in patients' hand joints (1.7%, *p*=0.001527) and wrist joints (43%, *p*=0.000001) than in healthy individuals. Regarding the finding of joint effusion, 7% of hand and 54% of wrist joints resulted to be positive for that abnormality with significant differences compared to controls (*p*=0.000001 and *p*=0.000013, respectively) (Table III).

No significant difference was found for the evidence of bone erosions both at hand and wrist level. The prevalence of cortical irregularities was significantly higher (*p*=0.006) than in healthy subjects only at hand joint level.

The US analysis of the degree of single abnormalities at different joint sites (Table IV) demonstrated that signifi-

**Table IV.** Grade of synovial hypertrophy, power Doppler and effusion in hand and wrist joints of SSc patients and healthy subjects.

US findings	Synovial hypertrophy SSc/HS <i>p</i> -value			Power Doppler SSc/HS <i>p</i> -value			Joint effusion SSc/HS <i>p</i> -value		
	mild	moderate	severe	mild	moderate	severe	mild	moderate	severe
1° MCP	0/0	1/0	1/0	1/0	1/0	1/0	9/0	1/0	0/0
2° MCP	7/0	1/0	0/0	2/0	0/0	2/0	12/1	1/0	1/0
3° MCP	4/0	1/0	0/0	1/0	0/0	1/0	9/0	1/0	1/0
4° MCP	2/0	0/0	1/0	0/0	0/0	2/0	6/0	0/0	2/0
5° MCP	2/0	0/0	1/0	0/0	0/0	2/0	4/0	0/0	2/0
1° IP	2/0	1/0	0/0	2/0	0/0	0/0	3/0	3/0	0/0
2° PIP	4/0	1/0	0/0	0/0	1/0	1/0	10/0	1/0	1/0
3° PIP	2/0	1/0	0/0	0/0	0/0	1/0	7/0	1/0	1/0
4° PIP	4/0	0/0	1/0	1/0	0/0	1/0	9/0	0/0	1/0
5° PIP	2/0	0/0	1/0	0/0	0/0	1/0	4/0	0/0	1/0
2° DIP	0/0	0/0	0/0	0/0	0/0	0/0	5/0	1/0	0/0
3° DIP	1/0	1/0	1/0	1/0	0/0	2/0	4/0	0/0	1/0
4° DIP	0/0	0/0	0/0	0/0	0/0	0/0	1/0	0/0	0/0
5° DIP	0/0	0/0	0/0	0/0	0/0	0/0	2/0	0/0	0/0
IC	1/0	0/0	0/0	1/0	0/0	0/0	1/0	0/0	0/0
CMC	0/0	0/0	0/0	0/0	0/0	0/0	0/0	0/0	0/0
Total hand joints involvement	31/0	7/0	6/0	9/0	2/0	14/0	86/1	9/0	11/0
	<i>p</i> =0.000211	n.s.	n.s.	n.s.	n.s.	<i>p</i> =0.027	<i>p</i> =0.000001	n.s.	n.s.
RUC	27/0	14/0	3/0	22/0	14/0	4/0	34/3	6/0	10/0
	<i>p</i> =0.000971	<i>p</i> =0.027	n.s.	<i>p</i> =0.0042	<i>p</i> =0.027	n.s.	<i>p</i> =0.019068	n.s.	n.s.

MCP: metacarpophalangeal; IP: interphalangeal; PIP: proximal interphalangeal; DIP: distal interphalangeal; IC: intercarpal; CMC: carpo-metacarpal; RUC: radio-ulno-carpal; SSc: numbers of involved joints in total patients (n=46) with systemic sclerosis; HS: numbers of involved joints in healthy subjects. n.s.: non significant *p*-value.

cant differences between SSc patients' joints and controls were present, at hand level, for the findings of mild synovial hypertrophy (*p*=0.000211), severe PD positivity (*p*=0.027) and mild effusion (*p*=0.000001); at wrist level, for mild (*p*=0.000971) and moderate (*p*=0.027) synovial hypertrophy, mild (*p*=0.0042) and moderate (*p*=0.027) PD positivity and mild effusion (*p*=0.019068).

Regarding tendon involvement (Table V), B-mode ultrasonographic signs of tenosynovitis (Fig. 1B) were found in 6% out of the 1196 synovial tendon sites examined with significant differences compared to healthy subjects (*p*=0.000001); PD resulted to be positive in 29% of them, a value that resulted to be significantly different from controls (*p*=0.0038).

Considering findings at patient level (Tables VI and VII), US correlations were performed comparing lcSSc (n=28) to dcSSc (n=18) patients, total SSc patients (n=46) to controls (n=15), and also comparing separately lcSSc and dcSSc subgroup to controls. No significant US differences were found between lcSSc and dcSSc subgroups (*p*=n.s.).

Regarding relation between total SSc and controls (Table VI), joint effu-

sion was present in the hand joints of 50% of the patients and in 6.7% of the controls (*p*=0.002533); the wrist had a significantly higher and more complex involvement, with evidence of synovial hypertrophy in 63% (*p*=0.000009), PD positivity in 61% (*p*=0.000015) and effusion in 69.5% (*p*=0.000196) of cases. The prevalence of bone erosions and

cortical irregularities was not significantly higher in patients than in healthy controls.

Tenosynovitis was found in 43.5% of patients with SSc and only in 6.7% of controls (*p*=0.01), without any significant differences regarding the finding of local PD positivity (Table VII).

Increased cross-sectional area of me-

**Table V.** Ultrasonographic findings in extensor and flexor tendons in SSc patients and healthy subjects.

Number of synovial tendon sites totally examined in SSc: 1.196, and in healthy subjects: 390.

Tendons	B-mode tenosynovitis SSc/HS <i>p</i> -value	Positive power Doppler SSc/HS <i>p</i> -value
1° extensor compartment	3/0	1/0
2° extensor compartment	4/0	2/0
3° extensor compartment	4/0	0/0
4° extensor compartment	14/0	4/0
5° extensor compartment	1/0	0/0
6° extensor compartment	5/0	1/0
Flexor carpi radialis	1/0	1/0
Flexor digitorum superficialis and profundus	1/0	1/0
Flexor pollicis longus	3/0	2/0
2° digitorum flexor tendons	8/1	3/0
3° digitorum flexors	13/0	2/0
4° digitorum flexors	9/0	2/0
5° digitorum flexors	6/0	2/0
Total tendons involvement	72 (6%)/1 (0.26%) <i>p</i> =0.000001	21 (29%)/0 <i>p</i> =0.0038

SSc: numbers of involved tendons in total patients (n=46) with systemic sclerosis; HS: numbers of involved joints in healthy subjects.

**Table VI.** US findings in hand and wrist, numbers of involved subjects.

		Synovial hypertrophy	Power Doppler	Joint effusion	Erosions	Cortical irregularities
lcSSc/dcSSc <i>p</i> -value	Hand involvement	9/2 n.s.	5/2 n.s.	16/7 n.s.	3/0 n.s.	2/0 n.s.
	Wrist involvement	16/13 n.s.	16/12 n.s.	19/13 n.s.	1/0 n.s.	0/1 n.s.
SSc/HS <i>p</i> -value	Hand involvement	11/0 n.s.	7/0 n.s.	23/1 <i>p</i> =0.002533	3/0 n.s.	2/0 n.s.
	Wrist involvement	29/9 <i>p</i> =0.000009	28/0 <i>p</i> =0.000015	32/2 <i>p</i> =0.000196	1/0 n.s.	1/0 n.s.
lcSSc/HS <i>p</i> -value	Hand involvement	9/0 <i>p</i> =0.016890	5/0 n.s.	16/1 <i>p</i> =0.001246	3/0 n.s.	2/0 n.s.
	Wrist involvement	16/0 <i>p</i> =0.000151	16/0 <i>p</i> =0.000151	19/2 <i>p</i> =0.001062	1/0 n.s.	0/0 n.s.
dcSSc/HS <i>p</i> -value	Hand involvement	2/0 n.s.	2/0 n.s.	7/1 <i>p</i> =0.046339	0/0 n.s.	0/0 n.s.
	Wrist involvement	13/0 <i>p</i> =0.000029	12/0 <i>p</i> =0.000054	13/2 <i>p</i> =0.001286	0/0 n.s.	1/0 n.s.

SSc: total patients with systemic sclerosis (n=46); lcSSc: patients with limited form (n=28); dcSSc: patients with diffuse form (n=18); HS: healthy subjects (n=15); n.s.: non significant *p*-value.

dian nerve at carpal tunnel was found in 2 SSc cases and in none of the controls (n.s.).

Comparing lcSSc subgroup to controls, significant correlation were present at hand for the occurrence of joint effusion (16 lcSSc vs. 1 controls; *p*=0.001246) and synovial hypertrophy (9 lcSSc vs. 0 controls; *p*=0.000151); at wrist joint effusion was found in 19 lcSSc vs. 2 controls (*p*=0.0001062), both synovial hypertrophy and PD positivity in 16 lcSSc vs. 0 controls (*p*=0.000151) (Table VI); US signs of tenosynovitis (Table VII) were present in 11 lcSSc and only in 1 control (*p*=0.032719), without any significant differences regarding local PD positivity. No others differences were present.

Results between dcSSc subgroup and controls showed the following findings: at hand level joint effusion was present in 7 dcSSc and in 1 controls (*p*=0.046339), while at wrist a more complex involvement was evident with joint effusion in 13 dcSSc vs. 2 controls (*p*=0.001286), synovial hypertrophy in 13 dcSSc (*p*=0.000029) and PD positivity in 12 dcSSc (*p*=0.000054) (Table VI); tenosynovitis was present in 9 dcSSc (*p*=0.001390), without differences for local PD positivity (Table VII). No other differences were found.

*Correlation between US features and clinical/serological findings*

Statistical correlations between US findings and clinical/serological assessment

were performed for total patients (46), and also separately for lcSSc (28) and dcSSc (18) subgroups.

A statistically significant correlation was found between joint effusion and pain at hand level considering total (46) SSc patients (*p*=0.033108), and between PD positivity and swelling at wrist level in lcSSc subgroup (*p*=0.0401026); no other significant correlations were found between US findings and clinical articular assessment (pain, swelling, functional limitation) in total SSc and in 2 subgroups. The occurrence of TFR was not statistically related to US signs of tenosynovitis.

No significant correlations were present between US features and following findings: ulcers (present/absent), skin involvement (skin score, cut off ≥14), disease duration (cut off ≥120 months), nailfold capillaroscopy (pattern late vs. early or active).

CRP positive was not related to PD positivity on wrist and hand joints, and on tendon level.

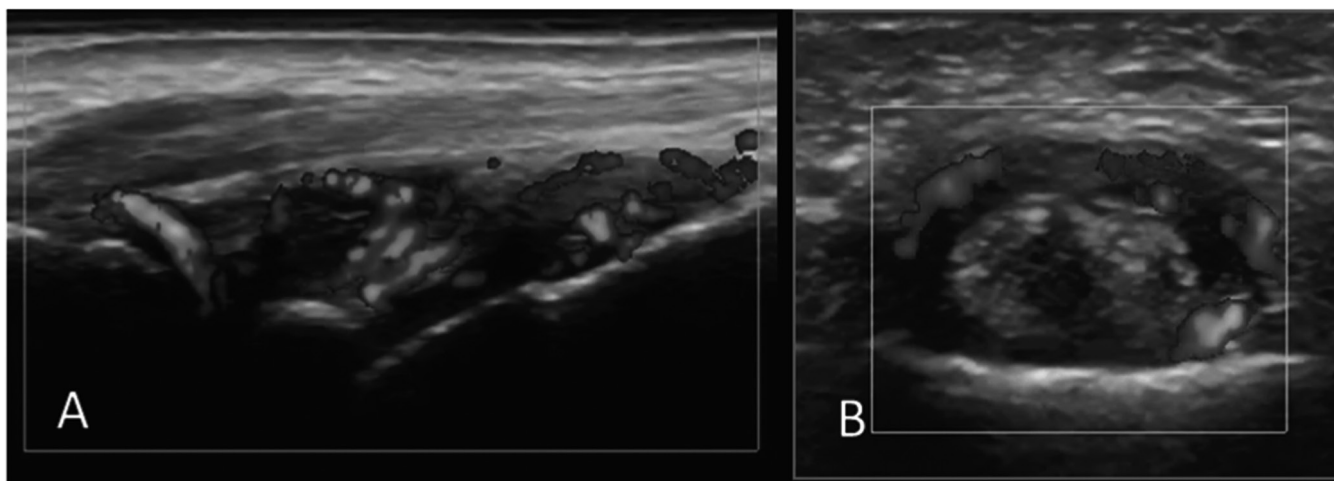
**Discussion and conclusions**

The present US study, performed at hand and wrist level in patients with SSc, investigated the abnormalities of both joints and periarticular structures, and showed a diffuse involvement in all synovial structures examined, with

**Table VII.** US findings in hand and wrist tendons, numbers of involved subjects.

	B-mode tenosynovitis	Power Doppler
lcSSc/dcSSc <i>p</i> -value	11/9 n.s.	1/4 n.s.
SSc/HS <i>p</i> -value	20/1 <i>p</i> =0.01	5/0 n.s.
lcSSc/HS <i>p</i> -value	11/1 <i>p</i> =0.032719	1/0 n.s.
dcSSc/HS <i>p</i> -value	9/0 <i>p</i> =0.001390	4/0 n.s.

SSc: total patients with systemic sclerosis (n=46); lcSSc: patients with limited form (n=28); dcSSc: patients with diffuse form (n=18); HS: healthy subjects (n=15); n.s.: non significant *p*-value.



**Fig. 1.** PDUS of the hand and wrist in systemic sclerosis.

**A:** Dorsal longitudinal scan of the wrist joint with evidence of synovial hypertrophy, joint effusion and PD positivity.

**B:** Palmar transverse scan of the 3<sup>rd</sup> finger showing tenosynovitis of the flexor tendons with PD positivity.

the presence of mild-to-severe inflammation.

During recent years a widespread application of musculoskeletal US has been registered with an increasing number of publications in the field of inflammatory arthritis, osteoarthritis and connective tissue diseases (8, 9; 12-17, 25, 26). However, only limited focus in SSc has developed so far and the few papers devoted to the analysis of that disease have either assessed exclusively joint involvement or median nerve entrapment syndrome or have been performed with the aim of comparing magnetic resonance imaging to US for the detection of inflammatory arthritis in selected symptomatic cases (27-30).

Our study demonstrated a high prevalence of involvement at hand and wrist joints level, particularly regarding the presence of inflammatory findings and with evidence of synovial hypertrophy, PD signs of active local inflammation and joint effusion. These abnormalities represent the single components of synovitis and, therefore, their presence in the examined joints is consistent with the presence of diffuse inflammatory involvement. Our results seem to be of interest, particularly when compared to clinical assessment: indeed, most of our patients had no clinical signs of musculoskeletal involvement and few of them had physical findings of arthritis. Interestingly, the US findings of inflammation have been

demonstrated both in the dcSSc and lcSSc forms, indicating that musculoskeletal involvement may be present in both subsets of the disease; indeed, no significant differences were revealed comparing the US findings in dcSSc to lcSSc (Tables VI and VII).

In addition, when the grade of local involvement was evaluated, we found that hand joints, besides being the site of mild effusion, were also characterised by mild synovial hypertrophy, which was accompanied by a severe PD signal. This last finding, demonstrating the presence of a highly active inflammation, represents a novel aspect of hand joint involvement in SSc, which needs further evaluations. On the other hand, the presence of mild to moderate involvement for all the 3 findings that are consistent with joint synovitis was demonstrated at wrist level.

The evaluation of joint structural damage lesions showed that bone erosions were not relevant abnormalities, while cortical irregularities may represent an interesting finding to be considered in the evaluation of SSc patients.

Our findings are partially in agreement with the study of Cuomo *et al.* who analysed, only at a global patient level, different US aspects of hand and wrist joint involvement and, compared to our results, showed a higher prevalence of structural damage lesions and a lower number of cases with inflammatory findings, which were particularly evident at the hand joints (27).

In addition, our research evaluated a huge number of tendons for the detection of tenosynovitis. Similarly to Chitale *et al.*, we found a high prevalence of B-mode tenosynovitis at the level of all local extensor and flexor tendons and, interestingly, active inflammation, as demonstrated by PD assessment, was detected in a great number of synovial tendon sites (29); furthermore, considering the evaluation of erosion, our findings are in line with results reported by Chitale *et al.*, who did not find erosions on US. However, Chitale *et al.*, in the same study and in the same patients, and also Low *et al.*, described a significant presence of erosions using magnetic resonance (MRI) in SSc; so it is possible to hypothesise that US presents limitations in detecting erosions in SSc due to limited acoustic windows in certain joints (29, 31). Unlike the other reports focused on the US evaluation of median nerve involvement at carpal tunnel in SSc and showing a high prevalence of nerve abnormalities, only 2 of our patients demonstrated to have sonographic signs of carpal tunnel syndrome (28, 30).

SSc is a chronic connective tissue disease characterised by musculoskeletal involvement in more than 30% of cases; this may be determinant for functional disability, in some cases. Articular involvement has been demonstrated by several studies (3, 4, 32, 33). However, imaging evaluation has registered only limited focus so far, by applying

either magnetic resonance imaging or US or conventional radiography for the examination of bone abnormalities (3, 27, 29, 31, 34).

In conclusion, the present US study, demonstrating a varied and complex involvement at hand and wrist joint level both in dcSSc and lcSSc forms, without significant differences between the 2 subsets, represents an interesting contribution to a more complete imaging evaluation of musculoskeletal abnormalities in SSc patients.

## References

- HINCHCLIFF M, VARGA J: Systemic sclerosis/scleroderma: a treatable multisystem disease. *Am Fam Physician* 2008; 15; 78: 961-8.
- DI FRANCO M, PARADISO M, RICCIERI V, BASILI S, MAMMARELLA A, VALESINI G: Autonomic dysfunction and microvascular damage in systemic sclerosis. *Clin Rheumatol* 2007; 26: 1278-83.
- LA MONTAGNA G, SODANO A, CAPURRO V, MALESCI D, VALENTINI G: The arthropathy of systemic sclerosis: a 12 month prospective clinical and imaging study. *Skeletal Radiol* 2005; 34: 35-41.
- BARON M, LEE P, KEYSTONE EC: The articular manifestations of progressive systemic sclerosis (scleroderma). *Ann Rheum Dis* 1982; 41: 147-52.
- LO MONACO A, BRUSCHI M, LA CORTE R, VOLPINARI S, TROTTA F: Epidemiology of systemic sclerosis in a district of northern Italy. *Clin Exp Rheumatol* 2011; 29 (Suppl. 65): S10-4.
- ERRE GL, MARONGIU A, FENU P *et al.*: The "sclerodermic hand": a radiological and clinical study. *Joint Bone Spine* 2008; 75: 426-31.
- AVOUAC J, GUERINI H, WIPFF J *et al.*: Radiological hand involvement in systemic sclerosis. *Ann Rheum Dis* 2006; 65: 1088-92.
- RIENTE L, DELLE SEDIE A, FILIPPUCCI E *et al.*: Ultrasound imaging for the rheumatologist XIV. Ultrasound imaging in connective tissue diseases. *Clin Exp Rheumatol* 2008; 26: 230-3.
- FILIPPUCCI E, MEENAGH G, DELLE SEDIE A *et al.*: Ultrasound imaging for the rheumatologist. XX. Sonographic assessment of hand and wrist joint involvement in rheumatoid arthritis: comparison between two- and three- dimensional ultrasonography. *Clin Exp Rheumatol* 2009; 27: 197-200.
- FILIPPUCCI E, IAGNOCCO A, MEENAGH G *et al.*: Imaging Ultrasound imaging for the rheumatologist. *Clin Exp Rheumatol* 2006; 24: 1-5.
- BACKHAUS M: Ultrasound and Structural Changes in Inflammatory Arthritis Synovitis and Tenosynovitis. *Ann NY Acad Sci* 2009; 1154: 139-51.
- SALAFFI F, CIAPETTI A, GASPARINI S, CAROTTI M, FILIPPUCCI E, GRASSI W: A clinical prediction rule combining routine assessment and power Doppler ultrasonography for predicting progression to rheumatoid arthritis from early-onset undifferentiated arthritis. *Clin Exp Rheumatol* 2010; 28: 686-94.
- RIENTE L, DELLE SEDIE A, FILIPPUCCI E *et al.*: Ultrasound Imaging for the rheumatologist XXVII. Sonographic assessment of the knee in patients with rheumatoid arthritis. *Clin Exp Rheumatol* 2010; 28: 300-3.
- IAGNOCCO A, MEENAGH G, RIENTE L *et al.*: Ultrasound imaging for the rheumatologist XXIX. Sonographic assessment of the knee in patients with osteoarthritis. *Clin Exp Rheumatol* 2010; 28: 643-6.
- SCIRÈ CA, IAGNOCCO A, MEENAGH G *et al.*: Ultrasound imaging for the rheumatologist XXXIII. Sonographic assessment of the foot in early arthritis patients. *Clin Exp Rheumatol* 2011; 29: 465-9.
- IAGNOCCO A, FILIPPUCCI E, RIENTE L *et al.*: Ultrasound imaging for the rheumatologist XXXV. Sonographic assessment of the foot in patients with osteoarthritis. *Clin Exp Rheumatol* 2011; 29: 757-62.
- FILIPPUCCI E, SCIRÈ CA, DELLE SEDIE A *et al.*: Ultrasound imaging for the rheumatologist. XXV. Sonographic assessment of the knee in patients with gout and calcium pyrophosphate deposition disease. *Clin Exp Rheumatol* 2010; 28: 2-5.
- IAGNOCCO A, EPIS O, DELLE SEDIE A *et al.*: Ultrasound imaging for the rheumatologist. XVII. Role of colour Doppler and power Doppler. *Clin Exp Rheumatol* 2008; 26: 759-66.
- SUBCOMMITTEE FOR SCLERODERMA CRITERIA OF THE AMERICAN RHEUMATISM ASSOCIATION DIAGNOSTIC & THERAPEUTIC CRITERIA COMMITTEE: Preliminary criteria for the classification of systemic sclerosis (scleroderma). *Arthritis Rheum* 1980; 23: 581-90.
- BACKHAUS M, BURMESTER G-R, GERBER T *et al.*: Guidelines for musculoskeletal ultrasound in rheumatology. *Ann Rheum Dis* 2001; 60: 641-9.
- WAKEFIELD RJ, BALINT PV, SZKUDLAREK M *et al.*: Musculoskeletal ultrasound including definitions for ultrasonographic pathology. *J Rheumatol* 2005; 32: 2485-7.
- SCHMIDT WA, SCHMIDT H, SCHICKE B, GROMNICA-IHLE E: Standard reference values for musculoskeletal Ultrasonography. *Ann Rheum Dis* 2004; 63: 988-94.
- NARANJO A, OJEDA S, MENDOZA D, FRANCISCO F, QUEVEDO JC, ERAUSIN C: What is the diagnostic value of ultrasonography compared to physical evaluation in patients with idiopathic carpal tunnel syndrome? *Clin Exp Rheumatol* 2007; 25: 853-9.
- IAGNOCCO A, MODESTI M, PRIORI R *et al.*: Subclinical synovitis in primary Sjögren's syndrome: an ultrasonographic study. *Rheumatology* 2010; 49: 1153-7.
- MEENAGH G, FILIPPUCCI E, DELLE SEDIE A *et al.*: Ultrasound imaging for the rheumatologist XIX. Imaging modalities in rheumatoid arthritis. *Clin Exp Rheumatol* 2009; 27: 3-6.
- MEENAGH G, FILIPPUCCI E, IAGNOCCO A *et al.*: Ultrasound imaging for the rheumatologist VIII. Ultrasound imaging in osteoarthritis. *Clin Exp Rheumatol* 2007; 25: 172-5.
- CUOMO G, ZAPPIA M, ABIGNANO G, IUDICI G, ROTONDO A, VALENTINI G: Ultrasonographic features of the hand and wrist in systemic sclerosis. *Rheumatology* 2009; 48: 1414-7.
- BANDINELLI F, KALOUDI O, CANDELIERI A *et al.*: Early detection of median nerve syndrome at the carpal tunnel with high-resolution 18 MHz ultrasonography in systemic sclerosis patients. *Clin Exp Rheumatol* 2010; 28: 15-8.
- CHITALE S, CIAPETTI A, HODGSON R *et al.*: Magnetic resonance imaging and musculoskeletal ultrasonography detect and characterize covert inflammatory arthropathy in systemic sclerosis patients with arthralgia. *Rheumatology* (Oxford) 2010; 49: 2357-61.
- TAGLIAFICO A, PANICO N, RESMINI E, DERCHI LE, GHIO M, MARTINOLI C: The role of ultrasound imaging in the evaluation of peripheral nerve in systemic sclerosis (scleroderma). *Eur J Radiol* 2011; 77: 377-82.
- LOW AHL, LAX M, JOHNSON SR, LEE P: Magnetic Resonance Imaging of the Hand in Systemic Sclerosis. *J Rheumatol* 2009; 36: 961-4.
- SANDQVIST G, HESSELSTRAND R, EBERHARDT K: A longitudinal follow-up of hand involvement and activities of daily living in early systemic sclerosis. *Scand J Rheumatol* 2009; 38: 304-10.
- BASSETT LW, BLOCKA KLN, FURST DE, CLEMENTS PJ, GOLD RH: Skeletal Findings in Progressive Systemic Sclerosis (Scleroderma). *AJR Am J Roentgenol* 1981; 136: 1121-6.
- BOUTRY N, HACHULLA E, ZANETTI-MUSIELAK C, MOREL M, DEMONDION X, COTTEN A: Imaging features of musculoskeletal involvement in systemic sclerosis. *Eur Radiol* 2007; 17: 1172-80.