

## Sonographic study of painful shoulder

A. Iagnocco, G. Coari,  
A. Leone, G. Valesini

Rheumatology Unit, Medical Therapy  
Department, University of Rome "La  
Sapienza", Rome, Italy

Annamaria Iagnocco, MD; Giulio Coari,  
MD; Antonella Leone, MD; Guido  
Valesini, MD, Professor of Rheumatology.

Please address correspondence and reprint  
requests to: Annamaria Iagnocco, MD,  
Cattedra di Reumatologia, Dipartimento  
di Clinica e Terapia Medica Applicata,  
Università di Roma "La Sapienza", Viale  
del Policlinico no. 155, Rome 00161, Italy.  
E-mail: aiagnocco@tiscali.it

Received on July 31, 2002; accepted in  
revised form on January 29, 2003.

© Copyright CLINICAL AND EXPERIMEN-  
TAL RHEUMATOLOGY 2003.

**Key words:** Painful shoulder,  
sonography.

### ABSTRACT

**Objective.** To identify sonographically the site and entity of alterations in a high number of patients with shoulder pain.

**Methods.** Two different experienced operators (both rheumatologists), who were blinded to the clinical data, performed sonographic examinations on 528 shoulders of 425 consecutive patients with painful shoulder and in both shoulders of 198 control subjects. They carried out ultrasound examinations separately using a 7.5 MHz linear transducer. Investigation included the long head of the biceps tendon, the supraspinatus tendon, infraspinatus tendon, subscapularis tendon, acromioclavicular joint, glenohumeral joint, subacromial-subdeltoid bursa, subscapularis bursa, and finally identification of calcifications. Before the ultrasonographic exam, a third experienced rheumatologist performed a physical examination in all patients using specific tests of movement for evaluation of the long head of biceps tendon, the supraspinatus tendon, infraspinatus tendon, subscapularis tendon, and acromioclavicular joint.

**Results.** Sonographic alterations were found in a total of 94.1% of patients. The structure most frequently involved was the supraspinatus tendon (64.6%). The long head of the biceps tendon (48.1%) and the acromioclavicular joint (51.5%) were also frequently involved. Different types of alterations in the various structures were detected. Significant differences were found with respect to controls. A high sensitivity and specificity of sonography was demonstrated compared to physical examination.

**Conclusions.** Sonography evaluates accurately the single anatomic structures of the shoulder and identifies both the site and type of changes in patients with painful shoulder. The high sensitivity/specificity, non-invasiveness and low costs of this technique justify its routine utilisation in clinical rheumatological practice.

### Introduction

Shoulder pain may be related to different diseases (1,2). Due to the complex

anatomy of the shoulder, however, it is often difficult to identify and assess the alterations from a physical examination (3). Many clinical tests may be used, but they have low accuracy compared to ultrasound (4). Recent improvements in ultrasound technology have led to a higher sensitivity and accuracy of musculoskeletal sonography. Consequently, it is presently considered an increasingly reliable method for the evaluation of shoulder changes (5-10).

The aim of this study was to identify sonographically the alterations in a large number of patients with painful shoulder. The sensitivity and specificity of the sonographic examination was calculated in comparison to physical examination. Previous studies have assessed the involvement of the shoulder in different diseases, but as far as we know they were limited to smaller groups of patients and controls (5-11). A larger cohort of patients was evaluated by Hedtmann *et al.*, but their study was limited to patients with pathology of the subacromial space (12).

### Materials and methods

#### Patients and controls

Sonography of the shoulder was performed in 425 patients (282 women and 143 men; mean age 57.9 years, range 18-90; mean symptom duration 5.3 months, range 1-19) who were consecutively referred to our rheumatology unit. Shoulder pain was related to different rheumatic disorders: 228 patients had clinically diagnosed periarticular disorders of the soft tissues of the shoulder, 13 had RA, 10 seronegative spondyloarthritis, 14 osteoarthritis, 15 previous trauma, 5 chondrocalcinosis, 6 SLE, and 3 systemic sclerosis. In 131 patients no clinical diagnosis had yet been made. In 103 cases bilateral involvement was present. For this reason a total of 528 shoulders were studied.

No treatment was being taken by 121 patients; 182 were taking analgesics and 122 NSAIDs.

In addition, both shoulders of 198 control subjects (109 women and 89 men; mean age 56.3 years; range 47-78) were examined. They had been referred to our unit either for knee or foot osteoarthritis and none of them had at the

time of the study or previously any episodes of painful shoulder.

#### Physical examination

Few days before the sonographic assessment an experienced rheumatologist performed the following tests (2): Speed's test (resisted flexion of the shoulder with the elbow extended and the palm upwards) for the long head of the biceps tendon; resisted abduction (with the arm abducted to 90°, flexed to 30° and internally rotated) for the supraspinatus tendon; resisted external rotation for the infraspinatus tendon; resisted internal rotation for the subscapularis tendon; and the adduction stress test (with the elbow and shoulder extended and then passively adducted across behind the back) for the acromioclavicular joint.

#### Sonography

Using a combination of reported techniques (4, 7, 11-13) sonography was performed by 2 operators (both rheumatologists and experienced in sonography) who were blinded to the clinical data and carried out the exams separately. A 7.5 MHz linear transducers was used. Ultrasound examinations were repeated twice by each operator and no significant intra-observer (intra-class correlation coefficient 0.81-0.93,  $p < 0.0001$ ) or inter-observer variability was found (intra-class correlation coefficient 0.82,  $p < 0.0001$ ). Investigations included: the long head of the biceps tendon; the supraspinatus, infraspinatus, and subscapularis tendons; the subacromial-subdeltoid and subscapularis bursae; the glenohumeral and acromioclavicular joints; and identification of calcifications.

Tendon thickness, homogeneity of the fibrillar pattern and regularity of the margins were studied. Thinning and the appearance of a hypoechoic area within the tendon were considered to be a sign of partial rupture of the fibres (1, 6, 8-10). Thickening, usually associated with tendon hypoechogenicity, was interpreted as a sign of tendinitis (1,4). Variations in tendon thickness were evaluated with respect to either the contralateral tendon or to the tendons of healthy subjects, when bilateral involvement

was present. Normal thickness of the supraspinatus tendon was considered to be 6 mm with an SD of 1.1 mm (10). Variations were considered significant when they were at least 1/3 of the normal tendon thickness (10).

The appearance of a hypoechoic discontinuity within the tendons' fibrillar pattern (1,6, 9) was interpreted as a tear (full-thickness tear: a defect extending through the entire tendon; partial thickness tear: defect limited to a part of its thickness). Non-visualisation of the tendon was also considered a sign of full-thickness tear (10). Diffuse hypoechogenicity with the absence of a fibrillar pattern and/or irregularity of the margins were interpreted as a sign of tendinitis/tendinosis (1, 8). With regard to the long head of the biceps tendon, an empty bicipital groove with identification of the displaced tendon in the surrounding area was interpreted as tendon subluxation (4, 8); the appearance of a hypo-anechoic area around the tendon and within its sheath  $> 2$  mm was considered as a sign of tenosynovitis (1, 4, 8, 10).

Involvement of the bursae was identified when accumulation of hypo-anechoic fluid appeared within them with thickening  $> 2$  mm (4, 10).

Effusion within the acromioclavicular joint was considered to be present when hypo-anechoic fluid accumulation distending the joint capsule was demonstrated within the joint cavity (1). Irregularities of the bone surfaces were detected on the basis of discontinuities (13).

Effusion within the glenohumeral joint was considered to be present when on transaxillar scan hypo-anechoic fluid was found in the joint cavity and the

bone surface-joint capsule distance was  $> 3.5$  mm (11).

Calcifications were identified when a hyperechoic area, with a possible posterior shadow, was found (4).

#### Statistical analysis

Data were analysed with the Statistical Package for the Social Sciences (SPSS, SPSS Inc software, Chicago, IL, USA). Statistical analysis was performed using the  $\chi^2$  test. A  $p$  value  $< 0.05$  was considered to be statistically significant. A  $2 \times 2$  table was used to assess the sensitivity and specificity of sonography with respect to the physical examination.

#### Results

The results are reported in Tables I, II and III.

The Speed's test was positive in 223 shoulders (42.2%), resisted abduction in 196 (37.1%), resisted external rotation in 69 (13.1%), resisted internal rotation in 18 (3.4%), and the adduction stress test in 61 (11.5%).

Sonography showed the presence of alterations in 400 patient (94.1%).

Alterations of the long head of the biceps tendon were found in 254 shoulders (48.1%;  $p < 0.0001$ ). Peritendinous effusion was found in 41.5% ( $p < 0.0001$ ; Fig. 1), echotexture changes in 8.5% ( $p < 0.0001$ ), tears in 0.9% ( $p < 0.049$ ); thickening in 0.2% (n.s.); and thinning in 0.6% (n.s.).

The supraspinatus tendon was involved in 314 cases (64.6%;  $p < 0.0001$ ). Tendon thickening was found in 4.0% ( $p < 0.0001$ ), thinning in 8.3% ( $p < 0.0001$ ), tears (Fig. 2) in 2.3% ( $p < 0.0001$ ), and echotexture changes in 49.4% ( $p < 0.0001$ ). The infraspinatus tendon was

**Table I.** Sonographic findings showing involvement of the various structures of the shoulder girdle in patients and controls.

	Cases (n=528)	Controls (n=396)	p value
Long head of the biceps tendon	254 (48.1%)	8 (2.0%)	$< 0.0001$
Supraspinatus tendon	314 (64.6%)	15 (3.8%)	$< 0.0001$
Infraspinatus tendon	89 (16.8%)	1 (0.25%)	$< 0.0001$
Subscapularis tendon	23 (4.3%)	0 (0.0%)	$< 0.0001$
Acromioclavicular joint	270 (51.5%)	11 (2.8%)	$< 0.0001$
Glenohumeral joint	59 (11.2%)	0 (0.0%)	$< 0.0001$
Bursae	85 (16.1%)	0 (0.0%)	$< 0.0001$

**Table II.** Sonographic findings with the spectrum of the specific alterations among the various anatomic structures of the shoulder.

Alterations		Cases (n=528)	Controls (n=396)	p value
Long head of the biceps tendon	Effusion	219 (41.5%)	0 (0.0%)	< 0.0001
	Thickening	1 (0.2%)	0 (0.0%)	n.s.
	Thinning	3 (0.6%)	0 (0.0%)	n.s.
	Tears	5 (0.9%)	0 (0.0%)	< 0.049
	Subluxation	0 (0.0%)	0 (0.0%)	n.s.
	Echotexture changes*	45 (8.5%)	8 (2.1%)	< 0.0001
Supraspinatus tendon	Thickening	21 (4.0%)	1 (0.2%)	< 0.0001
	Thinning	44 (8.3%)	3 (0.7%)	< 0.0001
	Tears	12 (2.3%)	0 (0.0%)	< 0.0001
	Echotexture changes*	261 (49.4%)	12 (3.0%)	< 0.0001
Infraspinatus tendon	Thickening	3 (0.6%)	0 (0.0%)	n.s.
	Thinning	10 (1.9%)	0 (0.0%)	< 0.005
	Tears	3 (0.6%)	0 (0.0%)	n.s.
	Echotexture changes*	77 (13.2%)	3 (0.7%)	< 0.0001
Subscapularis tendon	Thickening	5 (0.9%)	0 (0.0%)	< 0.049
	Thinning	2 (0.4%)	0 (0.0%)	n.s.
	Tears	0 (0.0%)	0 (0.0%)	n.s.
	Echotexture changes*	21 (4.0%)	1 (0.25%)	< 0.0001
Acromioclavicular joint	Irregularity	161 (30.5%)	9 (1.7%)	< 0.0001
	Effusion	142 (26.9%)	2 (0.5%)	< 0.0001
Glenohumeral joint	Effusion	59 (11.2%)	0 (0.0%)	< 0.0001
Subacromial-subdeltoid bursa	Effusion	43 (8.1%)	0 (0.0%)	< 0.0001
Subscapularis bursa	Effusion	42 (7.9%)	0 (0.0%)	< 0.0001
All tendons	Calcifications	38 (7.2%)	2 (0.5%)	< 0.0001

\* The term includes changes in both the homogeneity of the tendon fibrillar pattern and the regularity of their margins.

**Table III.** Involvement of the various anatomic structures of the shoulder girdle. Comparison between sonographic findings and physical examination.

	Physical examination	Sonography	
		Sensitivity (%)	Specificity (%)
Long head of the biceps tendon	223 (42.2%) (Speed's test)	86.5	254 (48.1%) 80
Supraspinatus tendon	196 (37.1%) (resisted abduction test)	94.4	314 (59.5%) 38.8
Infraspinatus tendon	69 (13.1%) (resisted external rotation)	94.2	89 (16.8%) 94.5
Subscapularis tendon	18 (3.4%) (resisted internal rotation)	94.4	23 (4.3%) 98.8
Acromioclavicular joint	61 (11.5%) (adduction stress test)	93.4	270 (51.1%) 54

involved in 89 shoulders (16.8%;  $p < 0.0001$ ). Echotexture changes were present in 13.2% ( $p < 0.0001$ ), thinning in 1.9% ( $p < 0.005$ ), thickening in 0.6% (n.s.), and tears in 0.6% (n.s.). The subscapularis tendon was involved in 23 cases (4.3%;  $p < 0.0001$ ). Echotexture

changes were found in 4.0% ( $p < 0.0001$ ), thickening in 0.9% ( $p < 0.049$ ), and thinning in 0.4% (n.s.).

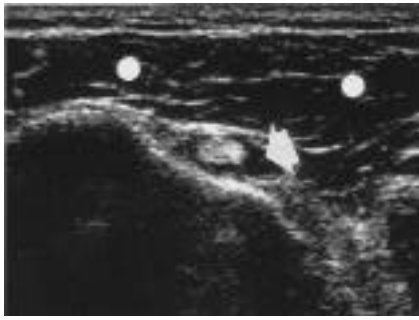
The acromioclavicular joint was involved in 270 joints (51.5%;  $p < 0.0001$ ). Effusion was found in 26.9% ( $p < 0.0001$ ) and irregularities of the bone

surfaces in 30.5% ( $p < 0.0001$ ). Effusion within glenohumeral joint was revealed in 59 cases (11.2%;  $p < 0.0001$ ). Fluid collection within the subacromial-subdeltoid bursa (Fig. 3) was present in 43 shoulders (8.1%;  $p < 0.0001$ ) and effusion in the subscapularis bursa in 42 cases (7.9%;  $p < 0.0001$ ). Finally, calcifications were revealed in a total of 38 shoulders (7.2%;  $p < 0.0001$ ).

Comparison between the findings of physical examination and sonography showed that the sensitivity of ultrasound was good for alterations of the acromioclavicular joint, and supraspinatus, infraspinatus, and subscapularis tendons, and fairly good for changes of the long head of the biceps tendon. Specificity was very high for alterations of the subscapularis tendon, high for changes of the infraspinatus tendon, and low for alterations of the acromioclavicular joint, supraspinatus and long head of biceps tendons.

**Discussion**

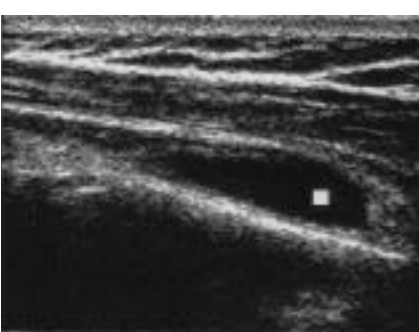
Different anatomic structures may be involved in painful shoulder and many



**Fig. 1.** Transverse scan of the long head of the biceps tendon. Evidence of hypoechoic fluid collection (→) surrounding the hyperechoic tendon. ● Deltoid muscle.



**Fig. 2.** Tear (→) in the supraspinatus tendon.



**Fig. 3.** Fluid collection (■) within the subacromial bursa.

clinical tests are usually performed (1-3). Nevertheless, the differential diagnosis is often difficult and a lower accuracy of physical examination compared with ultrasound has been reported (4). In the present study, based on a large number of patients, the greater sensitivity of ultrasound in comparison to physical examination was demonstrated for all the anatomic structures of the girdle. Specificity was high for the subscapularis and the infraspinatus tendons.

These findings confirm the importance of ultrasound in the clinical practice

and provide a demonstration that sonography is a valuable method for the assessment shoulder pathology. Many studies have been published regarding the ultrasonographic detection of shoulder alterations, but they have been limited either to small groups of patients (5, 7, 11, 12), to the assessment of single structures (7-9, 11-13), or to the evaluation of specific disorders (14, 15).

As far as we know, this is the first study evaluating a large cohort of patients with painful shoulder versus controls, examining most of the anatomic structures of the girdle, and comparing ultrasound with physical examination. The rotator cuff tendons were found to be frequently involved and the entire spectrum of alterations detectable by sonography were found. Changes in the fibrillar pattern and the tendons margins were present more often than the other alterations, demonstrating the possible presence of either inflammatory or degenerative processes and confirming multifactorial aetiology of the disease in the rotator cuff (1,3). Among the rotator cuff tendons, the anatomic structure most commonly involved was the supraspinatus tendon and this finding confirms the important role of that structure in the functional integrity of the girdle, which makes it particularly susceptible to damage and injury (3). Alterations in the long head of the biceps tendons were found in a high percentage of cases and tenosynovitis was the most frequent manifestation. That finding may be due either to a local inflammatory process or to the secondary production of fluid caused by other soft tissues abnormalities (1, 13). Changes in the acromioclavicular joint were often found, with the presence of both inflammatory and degenerative changes. Those findings demonstrate the presence of various possible mechanisms in the pathology of that joint. The rarer involvement of glenohumeral joint could be due to the limited number of subjects with synovitis. Calcifications were found in a low percentage of cases and this was probably a result of the short duration of the symptoms in

our cohort of patients.

In conclusion, the high sensitivity and specificity, non-invasiveness and low costs of sonography justify its routine utilisation for the assessment of painful shoulder in clinical rheumatological practice.

## References

1. COARI G, PAOLETTI F, IAGNOCCO A: Shoulder involvement in rheumatic diseases. Sonographic findings. *J Rheumatol* 1999; 26:668-73.
2. DALTON SE: Axial and peripherals joints. The shoulder. In KLIPPEL JH and DIEPPE PA (Eds.): *Rheumatology*, London, Mosby 1998; 4, 7.1-7.14.
3. TYTHERLEIGH-STRONG G, HIRAHARA A, MINIACI A: Rotator cuff disease. *Curr Opin Rheumatol* 2001; 13: 135-45.
4. NAREDO E, AGUADO P, De MIGUEL E *et al.*: Painful shoulder: comparison of physical examination and ultrasonographic findings. *Ann Rheum Dis* 2002; 61: 132-6.
5. ALASAARELA E, TAKALO R, TERVOONEN O, HAKALA M, SURAMO I: Sonography and MRI in the evaluation of painful arthritic shoulder. *Br J Rheumatol* 1997; 36:996-1000.
6. VAN HOLSBECK MT, KOLOWICH PA, EYLER WR *et al.*: US depiction of partial-thickness tear of the rotator cuff. *Radiology* 1995; 197: 443-6.
7. MACK LA, NYBERG DA, MATSEN FA: Sonographic evaluation of the rotator cuff. *Radiol Clin North Am* 1988; 26: 161-77.
8. PTASZNIK R, HENNESSY O: Abnormalities of the biceps tendon of the shoulder: sonographic finding. *Am J Rheumatol* 1995; 164: 409-14.
9. FARIN P, JAROMA H: Sonographic detection of tears of the anterior portion of the rotator cuff (subscapularis tendon tears). *J Ultrasound Med* 1996; 16: 221-5.
10. ALASAARELA EM, ALASAARELA ELI: Ultrasound evaluation of painful rheumatoid shoulders. *J Rheumatol* 1994; 21: 1642-8.
11. KOSKI JM: Axillar ultrasound of the glenohumeral joint. *J Rheumatol* 1989; 16:664-7.
12. HEDTMANN A, FETT H: Ultrasonography of the shoulder in subacromial syndromes with disorders and injuries of the rotator cuff. *Orthopade* 1995; 24: 498-508.
13. BACKHAUS M, BURMESTER G-R, GERBER T *et al.*: Guidelines for musculoskeletal ultrasound in rheumatology. *Ann Rheum Dis* 2001; 60: 641-9.
14. KOSKY JM: Ultrasonographic evidence of synovitis in axial joints in patients with polymyalgia rheumatica. *Br J Rheumatol* 1992; 31: 201-3.
15. LANGE U, PIEGSA N, TEICHMANN J, NEECK G: Ultrasonography of the glenohumeral joints - A helpful instrument in differentiation elderly onset rheumatoid arthritis and polymyalgia rheumatica. *Rheumatol Int* 2000; 19: 185-9.