

## Original article

## Subclinical synovitis in primary Sjögren's syndrome: an ultrasonographic study

Annamaria Iagnocco<sup>1</sup>, Mariagrazia Modesti<sup>1</sup>, Roberta Priori<sup>1</sup>,  
Cristiano Alessandri<sup>1</sup>, Chiara Perella<sup>1</sup>, Silvia Takanen<sup>1</sup> and Guido Valesini<sup>1</sup>

## Abstract

**Objectives.** To evaluate, by musculoskeletal ultrasound (MSUS), articular involvement in primary SS (pSS) patients by analysing hand and wrist changes, and to correlate them with clinical evaluation and laboratory tests.

**Methods.** Thirty-two pSS patients underwent clinical and laboratory examinations, including the SS Disease Damage Index (SSDDI) and the SS Disease Activity Index (SSDAI). MSUS was performed in all patients in both hands and wrists, evaluating the presence of inflammation within joints and periarticular tissues, and the existence of permanent joint damage. For synovial hypertrophy, joint effusion and Doppler signal findings, a semi-quantitative score (0–3) was used indicating the degree of involvement (0 = normal; 1 = mild change; 2 = moderate change; and 3 = severe change). For tenosynovitis and bone erosions, a dichotomous score (0 = absent and 1 = present) was applied.

**Results.** Sonographic signs of synovitis of the radio-ulno-carpal joint were found in 17 (26.5%) out of 64 wrists. Wrist synovitis was found in 12 (37.5%) out of 32 patients. Ultrasonographic examination of the hand did not show significant changes. A statistically significant correlation was found between SSDDI score and the degree of sonographic signs of synovial proliferation in the wrist ( $P = 0.04$ ). The correlation between the incidence of clinical involvement and the presence of pathological ultrasonographic findings was not significant. Patients with synovitis had a higher median age and higher median SSDDI ( $P = 0.004$ ).

**Conclusions.** In pSS patients, MSUS may be considered a useful tool for detecting synovitis since articular involvement can often be silent but correlated with SSDDI.

**Key words:** Ultrasonography, Sjögren's syndrome, Hand, Wrist, Synovium.

## Introduction

Primary SS (pSS) is a systemic autoimmune disease affecting women 9–10 times more commonly than men and characterized by keratoconjunctivitis sicca, xerostomia, due to chronic focal lymphocytic inflammation, and other extraglandular abnormalities. Musculoskeletal manifestations such as fatigue, myalgia, polyarthralgia and non-erosive symmetric polyarthropathy are the most

common ones and ~50% of the patients present with articular involvement [1]. Small joint involvement is frequent, and mild synovitis mimicking RA can be observed [2]. Furthermore, in these patients it is possible to detect serum RF, and, occasionally, anti-cyclic citrullinated peptide (anti-CCP) antibodies that seem to correlate with the presence of synovitis [3, 4].

In the last few years, musculoskeletal ultrasound (MSUS) has been demonstrated to be a useful imaging technique in the diagnosis and follow-up of various rheumatic diseases. Thanks to recent improvement in technology, with the production of more sophisticated equipment it is actually possible to detect and precisely define the presence and the entity of inflammation within joints and periarticular soft tissues, as well as to show the signs of even minimal structural damage. Using MSUS, we are able to detect various changes related to

<sup>1</sup>Department of Clinical and Medical Therapy, Rheumatology Unit, Sapienza Università di Roma, Rome, Italy.

Submitted 1 September 2009; revised version accepted 17 February 2010.

Correspondence to: Annamaria Iagnocco, Dipartimento di Clinica e Terapia Medica, Reumatologia, Sapienza Università di Roma, Policlinico Umberto 1, Viale del Policlinico 155, 00161, Rome, Italy. E-mail: [annamaria.iagnocco@uniroma1.it](mailto:annamaria.iagnocco@uniroma1.it)

synovitis, tenosynovitis, bursitis, bone erosions and cartilaginous abnormalities. The application of power Doppler technique provides for an accurate estimate of synovial perfusion, which increases in the presence of active synovitis [5–9].

We have already shown that, by using MSUS, a slight knee synovitis (defined as effusion and synovial proliferation) can be demonstrated in pSS patients [10]. While in pSS musculoskeletal symptoms are mainly due to synovitis, in SLE, another CTD, we found a high prevalence of tenosynovitis [11].

The aim of the present study was to evaluate hand and wrist joint changes in patients with pSS and to correlate them with clinical evaluation and laboratory tests. To our knowledge our study, executed in pSS, represents the first attempt to investigate, by using MSUS, a comprehensive involvement of both hand and wrist joints, including the periarticular structures of those areas.

## Patients and methods

This study received 'Sapienza' University of Rome ethical committee approval and all patients gave written informed consent. Thirty-two consecutive patients with a diagnosis of pSS, as qualified by the American–European Consensus Group criteria for SS, were recruited from the SS outpatient clinic of our rheumatology department. A rheumatologist (R.P.) asked the detailed clinical history of all patients and examined joints for clinical signs of synovitis. Clinical assessment (number of tender and swollen joints and disease activity score in 28 joints) was performed in all patients. The SS Disease Damage Index (SSDDI) and the SS Disease Activity Index (SSDAI) were also evaluated. ESR, CRP level and anti-SSA antibody were evaluated by routine methods according to in-house protocols. Anti-CCP antibodies were detected using a commercial anti-CCP2 ELISA kit (Immunoscan CCP Euro-Diagnostica, Malmö, Sweden). Anti-CCP antibodies were considered positive when the absorbance value was higher than the cut-off of the kit (25 U/ml). RF was assayed using the quantitative immunonephelometry test (Behring, Marburg, Germany). RF was considered positive when the concentration was higher than the cut-off value of the kit (15 IU/ml).

### Ultrasound examinations

An expert rheumatologist (A.I.), who was blinded to clinical and laboratory findings, performed MSUS bilaterally in hand and wrist (radio-ulno-carpal) joints and in the periarticular structures of those areas, using a multiplanar scanning technique, according to published guidelines [12, 13].

We used a Logiq9 machine (General Electric, Medical Systems, Milwaukee, WI, USA) equipped with a 9–15 MHz linear probe. In addition, power Doppler was applied with the following settings: frequency 7.5; pulse repetition frequency 900 Hz; gain adjusted just below the level that caused the appearance of noise artefacts; and low filter.

We evaluated the presence of inflammation within joints and/or periarticular tissues (effusion, synovial proliferation,

hyperaemia in the synovial tissue within the joints and tendon sheaths) and the existence of permanent joint damage (bone erosions). Changes within each articular and periarticular structure were recorded as being present according to the definitions in the literature [14]. For synovial hypertrophy, joint effusion and Doppler signal findings, a 4-point semi-quantitative scale (0–3) was used indicating the degrees of involvement (0=normal; 1=mild change; 2=moderate change; and 3=severe change). Mild synovitis was defined in the presence of minimal synovial proliferation and/or minimal joint effusion and/or minimal Doppler signal. Moderate synovitis was defined in the presence of moderate synovial proliferation and/or minimal–moderate joint effusion and/or minimal–moderate Doppler signal. Severe synovitis was defined in the presence of severe synovial hypertrophy and/or minimal–moderate severe joint effusion and/or minimal–moderate–severe Doppler signal. For tenosynovitis and bone erosions, we used a dichotomous score (0 = absent and 1 = present).

### Statistical analysis

The chi-square test with Yates's correction when required or Fisher's exact test when appropriate was used to evaluate associations of qualitative variables in the different groups. Differences between groups were analysed using the Mann–Whitney U-test. Correlation analysis was carried out using the Spearman test. A *P*-value of 0.05 was considered to be statistically significant. SPSS 13 (Chicago, IL, USA) was used for all calculations.

## Results

We studied 32 women with pSS: median age 58.5 years (range 26–69); median disease duration 5 years (range 0–18). Treatment included, for most of the patients, a low dose of prednisone equivalent per day and hydroxychloroquine (400 mg/day). Clinical evaluation revealed the presence of 13 (20.3%) tender wrists and 3 (4.6%) swollen wrists. Hand clinical examination showed that 101 MCP (31.5%) and 78 PIP (24.3%) joints of 33 hands were tender, and 33 MCP (10.3%) and 54 PIP (16.8%) joints of 22 hands were swollen. The mean number of hand tender joints was 2.55 (s.d. = 3.6) and the mean number of hand swollen joints was 1.24 (s.d. = 2.3).

Serological activity parameters showed median ESR as 26 mm/h (range 7–96); 22 (68.7%) patients were positive for RF, 25 (78.1%) for anti-SSA and 1 (3.1%) for anti-CCP antibodies. The median number of painful joints was 5.5 (range 0–28) and swollen joints was 1 (range 0–22). The median SSDAI score was 1 (range 0–4) and the median SSDDI score was 1 (range 0–5).

Ultrasonographic findings of this study are reported in Tables 1 and 2. Sonographic signs of synovitis of the radio-ulno-carpal joint (Fig. 1) were found in 17 (26.5%) of the 64 studied wrists. Totally, wrist synovitis was found in 12 (37.5%) out of 32 patients. In 10 wrists we could detect a moderate synovitis (58.8%), in 7 wrists mild synovitis (41.1%) and in none of the patients did we observe severe synovitis. In particular, synovial proliferation was

**Table 1** Ultrasonographic findings in hand and wrist joints

US findings	Synovial proliferation	Power Doppler	Joint effusion	Erosion	Tendon sheath distension
1° MCP	2	0	0	0	0
2° MCP	2	0	1	0	0
3° MCP	1	0	1	0	1
4° MCP	2	0	0	0	0
5° MCP	2	0	0	0	0
1° IP	2	0	0	0	0
2° PIP	5	3	2	0	0
3° PIP	2	0	0	0	0
4° PIP	2	0	0	0	0
5° PIP	2	0	0	0	0
2° DIP	2	0	1	0	0
3° DIP	2	0	0	0	0
4° DIP	2	0	0	0	0
5° DIP	2	0	0	0	0
Total	30	3	5	0	1
Wrist	19	16	28	2	0

PIP: proximal interphalangeal; DIP: distal interphalangeal.

**Table 2** Grade of ultrasonographic synovitis in hand and wrist joints

US degree of synovitis	Mild	Moderate	Severe
1° MCP	0	0	0
2° MCP	0	0	0
3° MCP	0	0	0
4° MCP	0	0	0
5° MCP	0	0	0
1° IP	0	0	0
2° PIP	2	1	0
3° PIP	0	0	0
4° PIP	0	0	0
5° PIP	0	0	0
2° DIP	0	0	0
3° DIP	0	0	0
4° DIP	0	0	0
5° DIP	0	0	0
No. of hand synovitis	2	1	0
No. of wrist synovitis	7	10	0

PIP: proximal interphalangeal; DIP: distal interphalangeal.

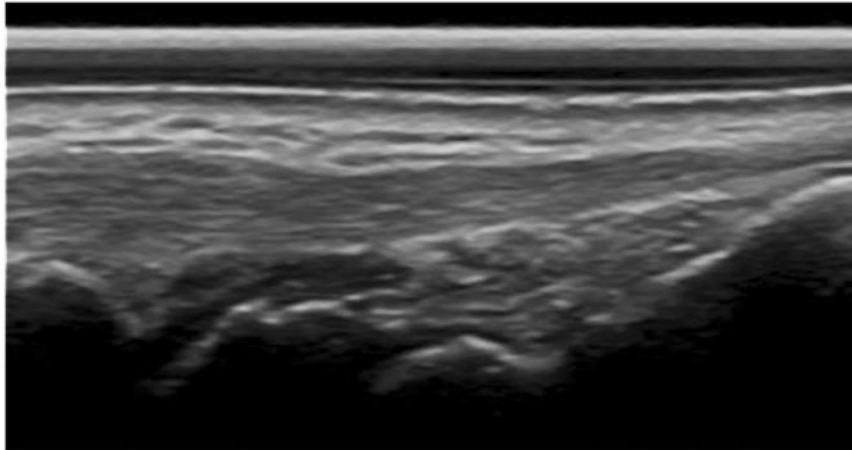
present in 19 (29.6%) joints, PD positivity in 16 (25%) and joint effusion in 28 (43.7%). Erosions were found in two wrists of one patient. Signs of tenosynovitis of one or more tendons at the wrist level were never present. In 27 (42.1%) wrists no alterations were found.

Ultrasonographic examination of the hand showed few and poor significant pathological changes. In fact, sonographic signs of hand synovitis were detected in only 3 (0.3%) hand joints (always 2° PIP) out of 896 examined. The grade of synovitis was mild in two cases and moderate in one case. In total, we observed hand synovitis in only 2 (6.2%) out of 32 patients. In particular, synovial proliferation was present in 30 (3.3%) joints, PD positivity

in 3 (0.3%) and joint effusion in 5 (0.5%). Signs of tenosynovitis at the hand level were present only at the flexor tendons of the third finger. Erosions were never found. In 863 (96.3%) hand joints no alterations were detected.

A statistically significant correlation was demonstrated between the SSDDI score and the degree of sonographic signs of synovial proliferation in the wrist ( $P=0.04$ ). The SSDAI score was significantly related to the number of tender joints and the titre of RF ( $P=0.02$ ). Moreover, we observed a positive correlation between the number of tender joints and joint effusion showed by ultrasound (US) ( $P=0.01$ ). No statistically significant correlations were found between tender and swollen joints detected by physical examination, and the presence and the degree of synovitis revealed by using MSUS. Interestingly, the clinical signs of synovitis in the wrist were less frequent than synovitis detected by MSUS.

Moreover, considering the higher percentage of synovitis at the wrist level, we divided our patients into two different subgroups, based on the presence/absence of radio-ulno-carpal joint synovitis. We could detect that patients with wrist synovitis had a median age of 64 years (range 43–68), whereas patients without synovitis had a median age of 48.5 years (range 26–69;  $P=0.005$ ). All patients with wrist synovitis were RF and anti-SSA positive. A statistically significant correlation was found between synovitis and RF positivity ( $P=0.01$ ). Furthermore, patients presenting with synovitis had a median SSDDI of 2 (range 0–3), whereas patients without synovitis had a median SSDDI of 1 (range 0–5;  $P=0.004$ ). Clinical and demographic characteristics of patients with subclinical synovitis and with symptomatic synovitis were not different.

**Fig. 1** Longitudinal dorsal scan of the wrist showing mild synovitis of the wrist joint.

## Discussion

pSS is a systemic autoimmune disease affecting mainly the function of salivary and lacrimal glands. The clinical spectrum of the disease is wide and extraglandular symptoms are very common. Articular involvement is reported, by several studies, as a frequent manifestation in these patients who mostly complain of arthralgias rather than arthritis [15–19]. In a large cohort of 1010 Spanish patients, the authors found that the main extraglandular manifestation was arthralgia (48%), whereas arthritis was present only in 15% of patients [20]. In a prospective study, Haga and Peen [21] analysed the pattern of arthritis, evaluated by clinical examination, in pSS patients. In this study, arthralgia was found in 73.5% of patients and arthritis in 17.6%, it was mild, resolving and not correlated with immunological and clinical aspects. The authors encouraged an ultrasonography study of hand joints in patients with pSS, so in this light we consider our study to be on time. While we showed a low prevalence of anti-CCP antibodies in pSS patients, the percentage of a moderate–mild degree of synovitis, detected by MSUS, was higher (26.5% vs 17.6%) than that reported by Haga and Peen. Our results confirm that MSUS is a more sensitive method to reveal joint involvement compared with simple clinical evaluation, and, most importantly, it also allows disclosure of subclinical disease. In fact, we did not find any significant correlation between joint clinical involvement, and the presence and the degree of synovitis revealed by MSUS. Thus, MSUS can help to show silent synovitis and this concept was already demonstrated in early, untreated oligoarthritis patients, where MSUS detected a high prevalence of subclinical synovitis. In fact, on the basis of these results, the authors wondered if oligoarthritis should be reclassified considering that having only clinical examination could be improper [22]. Many previous studies have shown that MSUS is a sensitive imaging technique able to reveal early synovial pathological changes and has demonstrated its superiority over clinical examination [9, 23].

In analogy to a Swedish study which demonstrated that subclinical myositis did not correlate with muscle pain in pSS patients [24], we have shown, by using MSUS, subclinical synovitis in patients without any symptoms. Moreover, we found a correlation between the degree of sonographic signs of synovial proliferation and the SSDDI score. In this light, MSUS could be considered a useful tool in the follow-up of these patients who can show a wide spectrum of symptomatic and subclinical manifestations.

We did not find any correlation between the presence and the degree of synovitis and disease duration, but dividing our patients into two different subgroups based on the presence/absence of wrist synovitis, we found that all patients with synovitis were RF and anti-SSA positive, and had a higher median age and higher SSDDI, suggesting that the presence of wrist synovitis might be considered as a sign of more severe disease. These findings have also been confirmed by positivity of serological parameters. Since clinical and demographic characteristics of patients with subclinical synovitis and symptomatic synovitis were not different, we suggest further study of these patients by using MSUS to eventually disclose a subset of subjects with a disease that requires more aggressive treatment and tight monitoring.

In conclusion, our study confirms that MSUS may be considered a useful tool for detecting synovitis in pSS patients, since this aspect can often be clinically silent and correlated with SSDDI. Furthermore, even though we observed a mild and self-limiting arthritis in most of the patients, the positivity of power Doppler signal could indicate more aggressive and active disease that might eventually lead to the appearance of erosive joint damage.

As far as we know, our study for the first time showed, by using MSUS, prevalent wrist joint involvement with signs of mild–moderate synovitis even in asymptomatic patient. Our findings thus confirm once again the usefulness of MSUS in detecting joint changes, in particular, demonstrating subclinical disease. Sonography can be

used to assess the pathological process and the presence of active joint inflammation, offering useful data in order to adopt the most adequate therapy in pSS patients.

#### Rheumatology key messages

- Sonography detects subclinical synovitis in pSS.
- MSUS is a useful imaging tool for analysing hand and wrist joint changes in pSS.

*Disclosure statement:* The authors have declared no conflicts of interest.

## References

- 1 Pease CT, Shattles W, Barrett NK *et al.* The arthropathy of Sjögren's syndrome. *Br J Rheumatol* 1993;32:609–13.
- 2 Castro-Poltronieri A, Alarcón-Segovia D. Articular manifestations of primary Sjögren's syndrome. *J Rheumatol* 1983;10:485–8.
- 3 Gottenberg JE, Mignot S, Nicaise-Rolland P *et al.* Prevalence of anti-cyclic citrullinated peptide and anti-keratin antibodies in patients with primary Sjögren's syndrome. *Ann Rheum Dis* 2005;64:114–7.
- 4 Atzeni F, Sarzi-Puttini P, Lama N *et al.* Anti-cyclic citrullinated peptide antibodies in primary Sjögren syndrome may be associated with non-erosive synovitis. *Arthritis Res Ther* 2008;10:R51.
- 5 Iagnocco A, Epis O, Delle Sedie A *et al.* Ultrasound imaging for the rheumatologist. XVII. Role of colour Doppler and power Doppler. *Clin Exp Rheumatol* 2008;26:759–62.
- 6 Filippucci E, Iagnocco A, Meenagh G *et al.* Ultrasound imaging for the rheumatologist VII. Ultrasound imaging in rheumatoid arthritis. *Clin Exp Rheumatol* 2007;25:5–10.
- 7 Filippucci E, Iagnocco A, Meenagh G *et al.* Ultrasound imaging for the rheumatologist. *Clin Exp Rheumatol* 2006;24:1–5.
- 8 Wakefield RJ, Gibbon WW, Conaghan PG *et al.* The value of sonography in the detection of bone erosions in patients with rheumatoid arthritis: a comparison with conventional radiography. *Arthritis Rheum* 2000;43:2762–70.
- 9 Wakefield RJ, Kong KO, Conaghan PG *et al.* The role of ultrasonography and magnetic resonance imaging in early rheumatoid arthritis. *Clin Exp Rheumatol* 2003;21:S42–9.
- 10 Iagnocco A, Coari G, Palombi G *et al.* Knee joint synovitis in Sjögren's syndrome. Sonographic study. *Scand J Rheumatol* 2002;31:291–5.
- 11 Iagnocco A, Ossandon A, Coari G *et al.* Wrist joint involvement in systemic lupus erythematosus. An ultrasonographic study. *Clin Exp Rheumatol* 2004;22:621–4.
- 12 Backhaus M, Burmester G-R, Gerber T *et al.* Guidelines for musculoskeletal ultrasound in rheumatology. *Ann Rheum Dis* 2001;60:641–9.
- 13 Schmidt WA, Schmidt H, Schicke B *et al.* Standard reference values for musculoskeletal ultrasonography. *Ann Rheum Dis* 2004;63:988–94.
- 14 Wakefield RJ, Balint PV, Szkudlarek M *et al.* OMERACT 7 Special Interest Group. Musculoskeletal ultrasound including definitions for ultrasonographic pathology. *J Rheumatol* 2005;32:2485–7.
- 15 Kruize AA, Henè RJ, Van Der Heide A *et al.* Long-term follow-up of patients with Sjögren's syndrome. *Arthritis Rheum* 1996;39:297–303.
- 16 Kelly CA, Foster H, Pal B *et al.* Primary Sjögren's syndrome in North East England – a longitudinal study. *Br J Rheumatol* 1991;30:437–42.
- 17 Davidson KS, Kelly CA, Griffiths ID. Primary Sjögren's syndrome in North East England: a long term follow-up study. *Rheumatology* 1999;38:245–53.
- 18 Pertovaara M, Pukkala E, Laippala P *et al.* A longitudinal cohort study of Finnish patients with primary Sjögren's syndrome: clinical, immunological and epidemiological aspects. *Ann Rheum Dis* 2001;60:467–72.
- 19 Pavlidis NA, Karsh J, Moutsopoulos HM. The clinical picture of primary Sjögren's syndrome: a retrospective study. *J Rheumatol* 1982;9:685–90.
- 20 Ramos-Casals M, Solans R, Rosas J *et al.* Primary Sjögren syndrome in Spain: clinical and immunologic expression in 1010 patients. *Medicine* 2008;87:210–9.
- 21 Haga HJ, Peen E. A study of the arthritis pattern in primary Sjögren's syndrome. *Clin Exp Rheumatol* 2007;25:88–91.
- 22 Wakefield RJ, Green MJ, Marzo-Ortega H *et al.* Should oligoarthritis be reclassified? Ultrasound reveals a high prevalence of subclinical disease. *Ann Rheum Dis* 2004;63:382–5.
- 23 Brown AK, Quinn MA, Karim Z *et al.* Presence of significant synovitis in rheumatoid arthritis patients with disease-modifying antirheumatic drug-induced clinical remission: evidence from an imaging study may explain structural progression. *Arthritis Rheum* 2006;54:3761–73.
- 24 Lindvall B, Bengtsson A, Ernerudh J *et al.* Subclinical myositis is common in primary Sjögren's syndrome and is not related to muscle pain. *J Rheumatol* 2002;29:717–25.