

Osteoarthritis and Cartilage (2008) 16, S4–S7

© 2008 Published by Elsevier Ltd on behalf of Osteoarthritis Research Society International.

doi:10.1016/j.joca.2008.06.005

Osteoarthritis and Cartilage

**International
Cartilage
Repair
Society**

Ultrasound in the study and monitoring of osteoarthritis

I. Möller M.D.^{†*}, D. Bong M.D.[‡], E. Naredo M.D.[§], E. Filippucci M.D., Ph.D.^{||}, I. Carrasco M.D.[¶],
C. Moragues M.D.[#] and A. Iagnocco Ph.D.^{††}[†] *Instituto Poal de Reumatologia, Barcelona, Spain*[‡] *The Vancouver Clinic, Vancouver, USA*[§] *Hospital Severo Ochoa, Leganes, Spain*^{||} *Universita Politecnica della Marche, Ancona, Italy*[¶] *Hospital Platon, Barcelona, Spain*[#] *Hospital Bellvitge, Barcelona, Spain*^{††} *Università di Roma La Sapienza, Roma, Italy*

Summary

This review addresses the use of ultrasound (US) as an imaging technique for the evaluation and monitoring of the osteoarthritic joint. US complements both the clinical examination and radiological imaging by allowing the rheumatologist to recognize not only the bony profile but also to visualize the soft tissues. Systematic US scanning following established guidelines can demonstrate even minimal abnormalities of articular cartilage, bony cortex and synovial tissue. US is also extremely sensitive in the detection of soft tissue changes in the involved joints including the proliferation of the synovium and changes in the amount of fluid present within the joint. Monitoring the amount of fluid in the hip and knee joint with osteoarthritis may be a potentially useful finding in the selection of patients for clinical investigation and for assessing their response to therapeutic interventions.

© 2008 Published by Elsevier Ltd on behalf of Osteoarthritis Research Society International.

Key words: Ultrasound, Osteoarthritis, Synovitis, Osteophytes, Cartilage.

Introduction

The use of high frequency transducers with greater resolution of superficial musculoskeletal structures has promoted an increasing use of ultrasound (US) in musculoskeletal system assessment¹. US has also been used in recent years as a technique to evaluate, diagnose and monitor patients with distinct rheumatic diseases^{2,3}.

Osteoarthritis (OA) is the most frequent cause of rheumatic complaints and a relevant public health problem. OA is characterized by changes in bone, cartilage and the soft tissues. In the cartilage, focal degeneration with progressive thinning occurs in the involved joints. Articular cartilage lacks its own vascular supply and is deficient of innervation. Therefore pain possibly arises from other peri-articular and/or intra-articular structures such as the joint capsule, synovium, periosteum, bone, tendons, bursae, ligaments or menisci. Non-destructive synovial proliferation, joint effusions and popliteal cysts are common findings in OA. Synovitis has been confirmed in knee OA especially in patients with early disease⁴.

Plain radiography is the imaging modality most frequently used for assessing joint involvement. However, the articular cartilage cannot be shown by plain radiographs. In addition, this technique lacks the ability to visualize synovial recesses, menisci and other tissues involved in OA.

OA is one of the rheumatic disorders in which advances in high resolution US have greatly enhanced our ability to observe the detailed changes in the pathological joint⁵ potentially providing insight into the causes of pain⁶, the role of inflammation and the progression of the disease process.

The many advantages of US have been well described and are not limited to the fact that it is a non-invasive cost effective technique. It provides unique information that bridges the gap between the clinical and the radiologic evaluation. US can be performed in the examination room minimizing the discomfort and inconvenience to the patient. This facilitates repeated evaluation of all the peripheral joints. The real time imaging capability of US not only allows dynamic assessment of joints but also provides a dimensional aspect not achieved with static radiologic techniques. In addition, US is able to show minute soft tissue changes including those involving the articular cartilage. The changes of the articular cartilage are not limited to the articular surface as in routine arthroscopy. Synovial recesses, tendons, ligaments, bursae and the peripheral aspect of the menisci can be evaluated by US. Along with early detection, subtle progression can be visualized⁷ providing for excellent monitoring of the OA pathology. Since the early 1980s, when the first studies on US and OA were published^{8–11}, technological advances have continuously improved both the hardware and the software of US imaging with the development of broadband multi-frequency probes, matrix probes, volumetric probes¹², probes that can be used inside the joint during arthroscopy, and more recently fusion imaging.

*Address correspondence and reprint requests to: Ingrid Möller M.D., Instituto Poal de Reumatologia, Barcelona, Spain; E-mail: ingrid.moller@ipoal.com

Received 17 June 2008; revision accepted 6 July 2008.

Basic science research, along with clinical investigation, in OA and US will continue to explore the correlation of US images with histomorphometry¹³, standardize measurements of the hyaline cartilage, analyze the acoustic properties of human cartilage¹⁴, correlate the levels of pain with the US findings, further delineate US from other imaging techniques, and increase our understanding of crystalline-associated joint disease¹⁵.

Technique

The US ability to assess OA pathology has been mainly investigated at hand, hip and knee joints^{16–19}. US equipment requirements and scanning technique differ greatly according to the anatomic site and the tissue examined²⁰. General rules on US assessment of OA pathology include: choosing the highest frequency that allows the visualization of the target area (i.e., higher than 13 MHz for the optimal imaging of the hyaline cartilage of the metacarpal head, lower than 10 MHz for hip joint assessment), adopting a multiplanar scanning technique to document US findings indicative of OA on at least two perpendicular planes of scanning and performing dynamic examination during flexion–extension movements. Scanning protocol for a tailored US assessment of OA pathology should include the evaluation of the articular cartilage involvement, the identification and measurement of the osteophytes and the detection of joint inflammation. Position of the joint under US examination is an important aspect affecting the US visualization of the hyaline cartilage.

Optimal visualization of a significant portion of the articular cartilage in OA in the small joints of the hand is achieved by longitudinal and transverse scanning of the dorsal aspects with the joint in full flexion. The volar aspect of the finger joints is scanned in a neutral position. Hip joint scanning is conventionally limited to the anterior surface of the joint with the leg extended and slightly rotated externally. In the knee, the weight bearing surfaces of the femoral condyle are scanned in the suprapatellar region with the knee fully flexed.

The healthy joint

An adequate knowledge of the normal qualitative and quantitative US features of the healthy joint is required to avoid misinterpretations while scanning a patient with OA. Ultrasonographic features of a normal joint include the uniformity of the bone profile, homogeneous echogenicity of the periarticular soft tissues and the potential presence of minimal amounts of fluid located in the joint recesses or bursae depending on the joint.

Hyaline cartilage can be visualized directly by US at different peripheral joints, including the knee, elbow, wrist, shoulder, tibiotalar and metacarpophalangeal joints. It appears as a well-defined anechogenic or homogeneously hypoechogenic band between the chondrosynovial and osteochondral margins. The lack of echoes of the cartilage layer and the sharpness of the margins are its principal features in healthy subjects (Fig. 1). Various studies have shown that knee articular cartilage thickness can be measured by US with a good intraobserver and interobserver reliability^{21–24}.

The normal profile of the bones is typically regular and the presence of a meniscal fibrocartilage in between them usually appears as a homogeneously echogenic triangle-shaped structure.

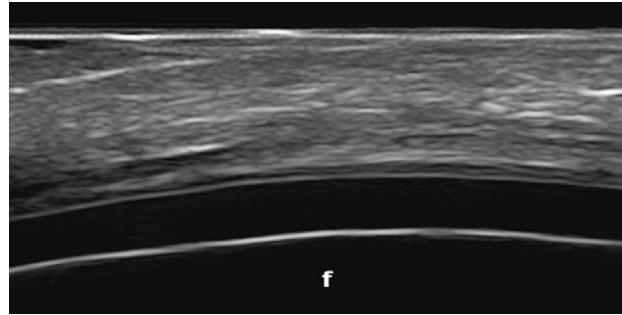


Fig. 1. Longitudinal view of the normal curvilinear cartilage of the femoral condyle of the knee demonstrating homogeneous anechoic appearance.

Scanning for fluid should be performed both by dynamic examination and in the standard static position. Since minimal amounts of fluid can be detected also in a small percentage of asymptomatic healthy subjects, comparison with the contralateral side is useful to reduce misinterpretations in daily clinical practice. The measurement of the maximum diameter of the anterior recess of the knee joint and in the bursae in a healthy joint has been described²⁵. The preliminary definition of synovial fluid and synovial hypertrophy proposed by the outcome measures in rheumatoid arthritis trials (OMERACT) US special interest group in 2004 for patients with rheumatoid arthritis can be applied also for the detection of joint inflammation in patients with OA (Fig. 2)²⁶. Intra-articular Doppler signal is noted only in the usual vascular structures of the joint.

The osteoarthritic joint

US allows the detection of a wide spectrum of pathologic findings indicative of OA, involving articular cartilage, bony cortex and synovial tissue.

The US appearance of the cartilage in OA is initially characterized by a loss of the sharp contour and variations in the echogenicity of the cartilage matrix. In the later stages, an asymmetric narrowing of the cartilaginous layer occurs. In 2002, a study investigated the relationship between the acoustic properties of matrix degeneration and proteoglycan loss of cartilage²⁷, the early structural changes by arthroscopic ultrasound, and has measured the diseased cartilage thickness for the purpose of standardization. In a recent study, cadaver knee joints were examined to investigate

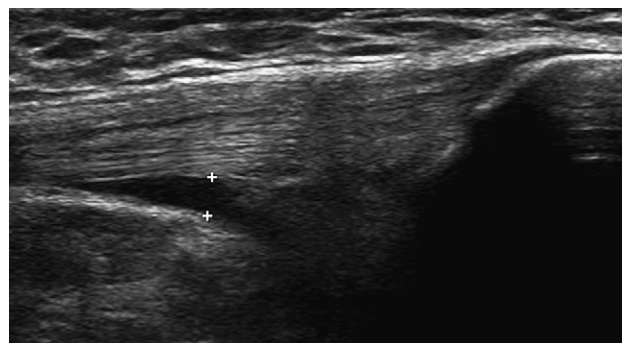


Fig. 2. Longitudinal view of the anterior recess of the knee (+, caliper markers delineating synovitis).

both discriminant and criterion validity of US in the measurement of femoral cartilage thickness. Multiple sonographers obtained good reproducibility and high levels of agreement were found between US and histology in the assessment of normal to moderately damaged cartilage²⁸.

The early bone changes in the OA joint are detected as hyperechoic signal in the area of the attachment of the joint capsule to the bony cartilaginous margin that correspond with the eventual appearance of osteophytes visualized on the conventional radiography (Fig. 3). In advanced disease the bony profile of the osteophytes is evident. In 2005, a study has described the ability of US in the detection of bone erosions in the central aspect of the joint in erosive hand OA²⁹.

A semiquantitative scoring system has been proposed in the assessment of the US findings of hip, knee and hand OA^{30–32}. Recently, a study group from European League Against Rheumatism (EULAR) has published a study demonstrating that US is more sensitive than conventional radiography in the detection of osteophytes and joint space narrowing in patients with hand OA³¹.

Patients with OA commonly have a small to moderate amount of synovitis and effusion. Depending on the study, between 47% and 100% of patients were noted to have synovitis and/or effusion of the symptomatic knee^{33,34}. US is more sensitive than clinical examination in detecting synovitis and correlates well with magnetic resonance imaging (MRI) and arthroscopic findings. Synovitis or joint effusion detected by US also correlates well with pain in knee OA^{35,36}.

Both color Doppler and power Doppler US techniques detect synovial flow, which is a sign of increased synovial vascularization³⁷. Increased Doppler signal correlates with increased synovial vascularity seen on histologic examination in patients with OA^{17,18}.

Monitoring of therapy

In clinical trials outcomes measurements in OA include structural measures, functional status and the level of pain the patient experiences. Serological markers are not available for use in OA. The need to identify and precisely measure a population in which OA progresses more rapidly is lacking³⁸.

US has proved to be an effective and safe imaging technique for guiding intra-articular injections, showing the proper needle positioning inside the joint cavity. This is especially important when hyaluronic acid is injected^{39–41}.

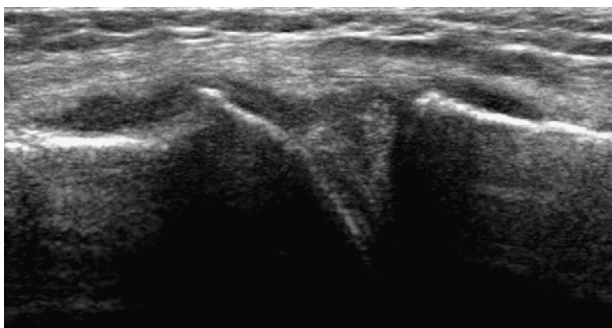


Fig. 3. Longitudinal view of medial aspect of the knee joint. Small osteophytes present on the medial femoral condyle and tibia.

All US findings indicative of OA pathology can be monitored. So far, very few studies have investigated this potential of US. Contrast-enhanced (CE) US has been used as a monitoring tool in a clinical trial showing good agreement with CE MRI in assessing inflammatory changes in knee OA⁴².

US enables us to image both the structural change and the inflammatory activity of the OA. US is one of the best techniques to detect minimal synovitis in a joint. For this reason, US has the potential to study the role of inflammation and identify the patients with a higher risk of progression.

Chondroitin sulfate has been demonstrated to reduce the swelling in patient with mild to moderate OA⁴³. A preliminary report suggests a response in reducing synovitis detected by US in knee OA patients treated with chondroitin sulfate⁴⁴. This preliminary report indicates a role for US that may have wider application in the future.

Limitations

The main limitation is the inability of the US beam to penetrate bony cortex. Thus, US visualization of the articular cartilage is restricted by the acoustic windows whose width is determined by the anatomy of the joint under examination.

There are also limitations that wait to be overcome including: the lack of a standardized method for measuring of cartilage thinning and joint space narrowing, the lack of a validated scoring system for the US findings indicative of OA, and the lack of a solid body of evidence on US reliability in the assessment of OA pathology.

In addition, US has been viewed as one of the most operator-dependent imaging techniques. This is partly due to the intrinsic real time nature of US image acquisition. The recorded US images largely display the subjective selection of findings observed by the individual performing the examination. This has limited the development of both multicentre and longitudinal US studies. A strict standardization of scanning technique and diagnostic criteria are necessary to perform reliable US assessment.

Conclusion

US is valuable in the early detection of OA and is helpful in defining the type and extent of bone and cartilage damage. US is an excellent tool for the detection of synovitis. US has the potential to further elucidate the role of soft tissues, including but not limited to synovium, in the generation and progression of OA. US also has potential in monitoring OA progression. The US evaluation of the OA disease process represents a dynamic area of rheumatologic investigation that will provide much needed insight into this important aspect of rheumatic disease.

Conflict of interest

No potential conflicts of interest relevant to this article were reported.

References

1. Grassi W, Cervini C. Ultrasonography in rheumatology: an evolving technique. *Ann Rheum Dis* 1998;57:268–71.
2. Manger B, Kalden JR. Joint and connective tissue ultrasonography – a rheumatologic bedside procedure? A German experience. *Arthritis Rheum* 1995;38:736–42.

3. Kane D, Grassi W, Sturrock R, Balint PV. Musculoskeletal ultrasound – a state of the art review in rheumatology. Part 2: clinical indications for musculoskeletal ultrasound in rheumatology. *Rheumatology* 2004;43:829–38.
4. Benito MJ, Veale DJ, FitzGerald O, van den Berg WB, Bresnihan B. Synovial tissue inflammation in early and late osteoarthritis. *Ann Rheum Dis* 2005;64:1263–7.
5. Grassi W, Filippucci E, Farina A. Ultrasonography in osteoarthritis. *Semin Arthritis Rheum* 2005;34:19–23.
6. Naredo E, Cabero F, Palop MJ, Collado P, Cruz A, Crespo M. Ultrasonographic findings in knee osteoarthritis: a comparative study with clinical and radiographic assessment. *Osteoarthritis Cartilage* 2005;13:568–74.
7. Saeed A, Cherin E, Gaucher H, Laugier P, Gillet P, Floquet J, *et al.* Assessment of articular cartilage and subchondral bone: subtle and progressive changes in experimental osteoarthritis using 50 MHz echography *in vitro*. *J Bone Miner Res* 1997;12:1378–86.
8. Aisen AM, McCune WJ, MacGuire A, Carson PL, Silver TM, Jafri SZ, *et al.* Sonographic evaluation of the cartilage of the knee. *Radiology* 1984;153:781–4.
9. McCune WJ, Dedrick DK, Aisen AM, MacGuire A. Sonographic evaluation of osteoarthritic femoral condylar cartilage. Correlation with operative findings. *Clin Orthop* 1990;254:230–5.
10. Chiang EH, Laing TJ, Meyer CR, Boes JL, Rubin JM, Adler RS. Ultrasonic characterization of *in vitro* osteoarthritic articular cartilage with validation by confocal microscopy. *Ultrasound Med Biol* 1997;23:205–13.
11. Hodler J, Resnick D. Current status of imaging of articular cartilage. *Skeletal Radiol* 1996;25:703–12.
12. Landes CA, Goral W, Mack MG, Sader R. 3-D sonography for diagnosis of osteoarthritis and disk degeneration of the temporomandibular joint, compared with MRI. *Ultrasound Med Biol* 2006;32:627–32.
13. Spriet M, Girard CA, Foster S, Harasiewicz K, Holdsworth D, Laverty S. Validation of a 40 MHz B-scan ultrasound biomicroscope for the evaluation of osteoarthritis lesions in an animal model. *Osteoarthritis Cartilage* 2005;13:171–9.
14. Hattori K, Takakura Y, Ishimura M, Tanaka Y, Habata T, Ikeuch K. Differential acoustic properties of early cartilage lesions in living human knee and ankle joints. *Arthritis Rheum* 2005;10:3125–31.
15. Meenagh G, Filippucci E, Iagnocco A, Delle Sedie A, Riente L, Bombardieri S, *et al.* Ultrasound imaging for the rheumatologist VIII. Ultrasound imaging in osteoarthritis. *Clin Exp Rheumatol* 2007;25:172–5.
16. Ruiz-Santiago F, Garofano P, Ruiz F, Tristan JM. Imaging study of psoitriquetral osteoarthritis. A role for ultrasound? *Eur J Radiol Extra* 2005;52:33–6.
17. Walther M, Harms H, Krenn V, Radke S, Kirschner S, Gohlke F. Synovial tissue of the hip at power Doppler US. Correlation between vascularity and power Doppler US signal. *Radiology* 2002;225:225–31.
18. Walter M, Harás H, Krenn V, Radke S, Faehndrich T, Gohlke F. Correlation of the power Doppler sonography with the synovial tissue of the knee joint in patients with osteoarthritis and rheumatoid arthritis. *Arthritis Rheum* 2001;44:331–8.
19. Iagnocco A, Coari G, Zoppini A. Sonographic evaluation of femoral condylar cartilage in osteoarthritis and rheumatoid arthritis. *Scand J Rheumatol* 1992;21:201–3.
20. Backhaus M, Burmester GR, Gerber T, Grassi W, Machold KP, Swen WA, *et al.* Guidelines for musculoskeletal ultrasound in rheumatology. *Ann Rheum Dis* 2001;60:641–9.
21. Castriota-Scanderberg A, De Micheli V, Scarale MG, Bonetti MG, Cammisa M. Precision of sonographic measurement of articular cartilage: inter- and intraobserver analysis. *Skeletal Radiol* 1996;25:545.
22. Mathiesen O, Konradsen L, Torp-Pedersen S, Jørgensen U. Ultrasonography and articular cartilage defects in the knee: an *in vitro* evaluation of the accuracy of cartilage thickness and defect size assessment. *Knee Surg Sports Traumatol Arthrosc* 2004;12:440–3.
23. Saarakkal S, Laasanen MS, Jurvelin JS, Toyras. Quantitative ultrasound imaging detects degenerative changes in articular cartilage surface and subchondral bone. *Phys Med Biol* 2006;51:5333–46.
24. Martino F, Ettore GC, Angelelli G, Macarini L, Patella V, Moretti B, *et al.* Validity of ecographic evaluation of cartilage in gonarthrosis. Preliminary report. *Clin Rheumatol* 1993;12:178–83.
25. Schmidt WA, Schmidt H, Schicke B, Gromnica-Ihle E. Standard reference values for musculoskeletal ultrasonography. *Ann Rheum Dis* 2004;63:988–94.
26. Wakefield R, Balint PV, Szkudlarek M, Filippucci E, Backhaus M, D'Agostino MA, *et al.* Musculoskeletal ultrasound including definitions for ultrasonographic pathology. *J Rheumatol* 2005;32:2485–7.
27. Nieminen HJ, Toyras J, Rieppo J, Nieminen MT, Hirvonen J, Korhonen R, *et al.* Real-time ultrasound analysis of articular cartilage degradation *in vitro*. *Ultrasound Med Biol* 2002;28:519–25.
28. Naredo E, Acebes JC, Möller I, Canillas F, de Agustín JJ, de Miguel E, *et al.* Validity and reproducibility of ultrasonographic measurement of femoral articular cartilage thickness [Abstract]. *Ann Rheum Dis* (in press).
29. Iagnocco A, Filippucci E, Ossandon A, Ciapetti A, Salaffi F, Basili S, *et al.* High resolution ultrasonography in detection of bone erosions in patients with hand osteoarthritis. *J Rheumatol* 2005;32:2381–3.
30. Qvistgaard E, Christensen R, Torppedersen S. Bliddal reproducibility and inter-reader agreement of a scoring system for ultrasound evaluation of hip osteoarthritis. *Ann Rheum Dis* 2006;65:1613–9.
31. Keen HI, Wakefield RJ, Grainger AJ, Hensor EM, Emery P, Conaghan PG. Can ultrasonography improve on radiographic assessment in osteoarthritis of the hands? A comparison between radiographic and ultrasonographic detected pathology. *Ann Rheum Dis* 2008;67(8):1116–20.
32. Lee CL, Huang MH, Chai CY, Chen CH, Su JY, Tie YC. The validity of *in vivo* ultrasonographic grading of osteoarthritic femoral condylar cartilage: a comparison with *in vitro* ultrasonographic and histologic gradings. *Osteoarthritis Cartilage* 2008;16:352–8.
33. Kristoffersen H, Torp-Pedersen S, Terslev L. Indications of inflammation visualized by ultrasound in osteoarthritis of the knee. *Acta Radiol* 2006;47:281–6.
34. D'Agostino MA, Conaghan P, Le Bars M, Baron G, Grassi W, Martin-Mola E, *et al.* EULAR report on the use of ultrasonography in inflammation in osteoarthritis painful knee osteoarthritis. Part 1: prevalence of inflammation in osteoarthritis. *Ann Rheum Dis* 2005;64:1703–9.
35. De Miguel E, Cobo T, Uson J, Bonilla G, Martin-Mola E. Clinical and ultrasonographic findings related to knee pain in osteoarthritis. *Osteoarthritis Cartilage* 2006;14:540–4.
36. Möller I, Naredo E, Moragues C, De Agustín J, Acebes C, Uson J, *et al.* Ultrasonographic finding in knee osteoarthritis. A Nation-wide study in Spanish patients. *Osteoarthritis Cartilage* 2007;15(Suppl C). P286: C159.
37. Schmidt WA, Volker L, Zacher J, Schlafke M, Ruhnke M, Gromnica-Ihle E. Colour Doppler ultrasonography to detect pannus in knee joint synovitis. *Clin Exp Rheumatol* 2000;18:439–44.
38. Hunter DJ, Conaghan PG. Imaging outcomes and their role in determining outcomes in osteoarthritis and rheumatoid arthritis. *Curr Opin Rheumatol* 2006;18:157–62.
39. Robinson P, Keenan AM, Conaghan PG. Clinical effectiveness and dose response of image-guided intra-articular corticosteroid injection for hip osteoarthritis. *Rheumatology* 2007;46:285–91.
40. Acebes JC, Sanchez-Pernuete O, Diaz-Oca A, Herrero-Beaumont G. Ultrasonographic assessment of Baker's cysts after intra-articular corticosteroid injection in knee osteoarthritis. *J Clin Ultrasound* 2006;34:113–7.
41. Qvistgaard E, Christensen R, Torp-Pedersen S, Bliddal. Intra-articular treatment of hip osteoarthritis: a randomized trial of hyaluronic acid, corticosteroid, and isotonic saline. *Osteoarthritis Cartilage* 2006;14:163–70.
42. Song IH, Althoff CE, Hermann KG, Scheel AK, Knetsch T, Burmester GR, *et al.* Contrast-enhanced ultrasound in monitoring the efficacy of a bradykinin receptor-2 antagonist in painful knee osteoarthritis compared to magnetic resonance imaging. *Ann Rheum Dis* 2008 (Epub ahead of print).
43. Clegg DO, Reda DJ, Harris CL, Clein MA, O'Dell JR, Hooper MM, *et al.* Glucosamine, chondroitin sulfate, and the two in combination for painful knee osteoarthritis. *N Engl J Med* 2006;354:795–808.
44. Möller I, Moragues C, de Agustín J, Sabata R, Martínez G, Montell E, *et al.* Ultrasonography as a technique to diagnose and monitor synovitis in patients with osteoarthritis: results with chondroitin sulfate. *Osteoarthritis Cartilage* 2007;15(Suppl C). 351: C196.