

Imaging

Ultrasound imaging for the rheumatologist XIII. New trends. Three-dimensional ultrasonography

E. Filippucci¹, G. Meenagh², O. Epis³, A. Iagnocco⁵, L. Riente⁴, A. Delle Sedie⁴,
C. Montecucco³, G. Valesini⁵, S. Bombardieri⁴, W. Grassi¹

¹*Cattedra di Reumatologia, Università Politecnica delle Marche, Ancona, Italy;*

²*Department of Rheumatology, Antrim Hospital, Antrim, United Kingdom;*

³*Cattedra di Reumatologia, IRCCS Policlinico San Matteo, Università di Pavia, Pavia, Italy;* ⁴*Unità Operativa di Reumatologia, Università di Pisa, Pisa, Italy;* ⁵*Cattedra di Reumatologia, Sapienza Università di Roma, Roma, Italy.*

Emilio Filippucci, MD; Gary Meenagh, MD; Oscar Epis, MD; Annamaria Iagnocco, MD; Lucrezia Riente, MD; Andrea Delle Sedie, MD; Carlomaurizio Montecucco, MD; Guido Valesini, MD, Professor of Rheumatology; Stefano Bombardieri, MD, Professor of Rheumatology; Walter Grassi, MD, Professor of Rheumatology.

Please address correspondence to: Prof. Walter Grassi, Cattedra di Reumatologia Università Politecnica delle Marche, Ospedale "A. Murri", Via dei Colli 52, 60035 Jesi (Ancona) - Italy. E-mail: walter.grassi@univpm.it

Received and accepted on January 24, 2008.

Clin Exp Rheumatol 2008; 26: 1-4.

© Copyright CLINICAL AND EXPERIMENTAL RHEUMATOLOGY 2008.

Key words: Three-dimensional ultrasonography, volumetric probe, power Doppler, learning curve.

Introduction

In recent years, ultrasound (US) has demonstrated its potential in diagnosis, monitoring and therapy of several rheumatic diseases (1-6). There is now little doubt that US can play a key role in early diagnosis of rheumatoid arthritis through its capacity to document synovial proliferation and perfusion, tendon involvement, cartilage damage and bone erosion in an evolutionary phase of the disease in which conventional radiography is usually normal (7-15). Unfortunately, US still has limited diffusion within rheumatology related principally to the image acquisition process and linked with at least five main factors: the steep learning curve, lack of standardisation of the technique, intra- and inter-observer variability, time consumption and the high initial cost of top quality sonographic equipment. Of all these barriers, the first four are undoubtedly the most difficult to overcome.

This review discusses the available evidence supporting the potential of three-dimensional (3D) US with high-frequency volumetric probe to overcome the first four barriers.

Revolution on the horizon

US technology is a very fast-moving process. Over the last few years, 3D US has appeared as one of the most interesting and fascinating new tools with potential to revolutionise the traditional approach to musculoskeletal US in rheumatology (16-21). It not only produces separate slices, but also cubes of echoes that can be explored on an endless number of planes, including the coronal plane that cannot be assessed on two-dimensional (2D) US. Moreover, 3D US allows three-dimensional reconstruction that can add

further useful information otherwise unavailable on single traditional sonographic slices. The specific characteristics of acquisition and reconstruction of the images make it the ideal tool to consider as the potential 'final solution' to the main problems which limit the diffusion and reliability of traditional US. The challenge to 3D US is to prove itself to be a method that requires no particular skills, that can be mastered in just a few minutes and is not operator-dependant.

3D US technology

3D US images can be obtained with different techniques (16). In rheumatological practice two methods are employed. The first and more common requires active involvement of the operator who has to move very carefully and homogeneously on the area of interest. The main limit of this approach is the creation of artefacts due to incorrect movement of the probe. The second and more innovative approach is based on large footprint probes that cover a relatively wide anatomical area and must not be moved on the skin surface to ensure acquisition of the cubes of echoes. The acquisition is performed by an automatic movement of the beam that is not operator-dependant. This kind of technique would seem to provide the best guarantee to limit any influence by the operator on the quality of the images. In practical terms, the operator has to select the area, put a layer of acoustic gel on the skin, place the probe surface on the gel layer, preferably avoiding any contact with skin, press the acquisition button, wait four seconds, and then move to another area. The volumetric echoes stored are available for further off-site examination on longitudinal, transverse, coronal and 3D reconstructions.

Competing interests: none declared.

Learning curve

There is a general consensus amongst experts that in order to master US there is a virtually endless learning curve related mainly to the image acquisition process (1, 4, 22-24). There is no formal agreement on the minimal requirement for competency in musculoskeletal US. According to the American College of Radiology, a minimum of 500 supervised scans must be performed by trainees to reach a suitable standard (25). Extrapolating this to rheumatologists, such a number of supervised scans would be virtually impossible to achieve within the current constraints of rheumatology training where US may not be included in the core curriculum. The visuo-spatial nature of US is so dependant on good acquisition technique that the time spent perfecting this skill is vital. Obviously, the possibility of taking high quality US pictures with minimal experience in musculoskeletal US would represent the ideal solution to the problems related to the learning curve.

Standardisation of the technique

Careful standardisation of the image acquisition technique plays a key role in musculoskeletal US. US findings should be explored on both longitudinal and transverse scans. In some anatomical areas where landmarks are less well defined it is often difficult to convincingly demonstrate clear transverse and longitudinal views thereby compounding the difficulties in satisfying image standardisation. Considerable time is, therefore, required during conventional 2D US to ensure that standardisation error has been minimised. The exploration of an anatomical region with 3D US whilst not negating the need for recognition of traditional landmarks, does reduce the degree of inherent error in image standardisation by virtue of the navigation through volumetric imagery obtained from the data set off-site at the operator's leisure (Fig. 1). Moreover, coronal and 3D reconstruction add further precision to the standard views and add otherwise inaccessible information. In particular these views can be of rel-

evant practical benefit in assessing the full extent of anatomical damage and the relationship between the lesion and the surrounding tissues. The point of intersection of the three perpendicular planes is evident and permits perfect correlation between the three windows contemporaneously.

Inter- and intra- operator variability

Reproducibility in US is a challenge. The extent of inter- and intra-operator variability in terms of the acquisition of US images has not been extensively investigated to date (4, 20, 23, 26-30). The results are encouraging even if reproducibility of an acceptable standard has been demonstrated in only a few pathological conditions. Reproducibility is affected by several aspects of the scanning technique which include the positioning of the patient, setting of the US equipment, quantity of acoustic gel applied, positioning of the probe, angulation of the probe with respect to the skin surface and pressure applied to

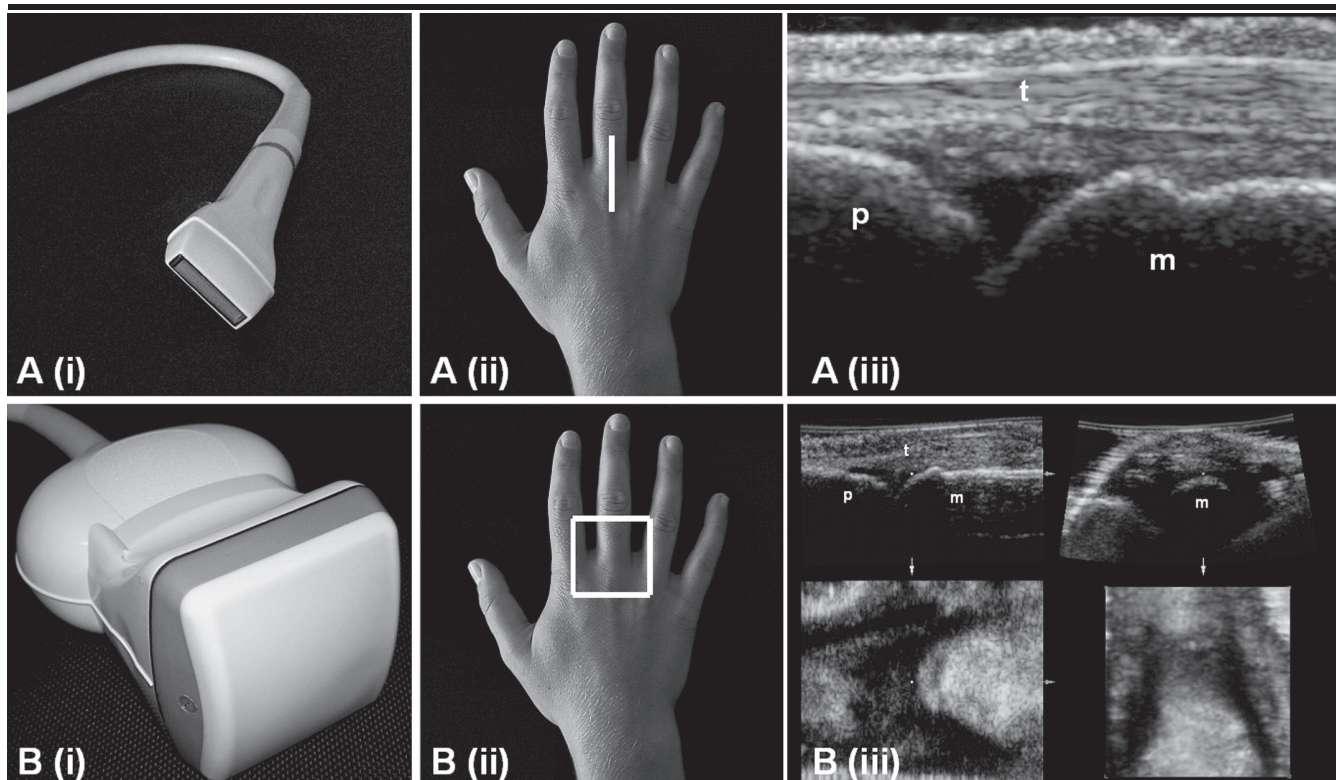


Fig. 1. Healthy subject. Metacarpophalangeal joint. In conventional 2D US (A) the sonographic landmarks are used to standardise the scanning technique. **A(i):** The linear probe; **A(ii):** The probe position; **A(iii):** The image obtained. In 3D US (B) the anatomical landmarks are used to standardise the image acquisition process. **B(i):** The volumetric probe; **B(ii):** The quadratic footprint; **B(iii):** The images obtained. 3D US images were obtained using a Logiq 9 (General Electric Medical Systems, Milwaukee, WI) equipped with a 8-15 MHz volumetric probe (4D16L). **m** = metacarpal head; **p** = proximal phalanx; **t** = extensor tendon.

the skin surface by the probe. The only technical aspects to consider during the 3D acquisition process are the correct placement of the probe and the avoidance of direct contact with the skin by using an adequate quantity of acoustic gel together with a steady hand. Only minimal modulation of the setting of the US equipment is required. An operator-independent method of image acquisition is particularly important for power Doppler. The assessment of soft tissue perfusion can be dramatically affected by the dexterity of the operator and the position of the probe. Final comments on the extent of hyper-vascularity are traditionally made upon a single representative slice selected by the operator during the real time examination. The patchy distribution of synovial proliferation is another element that makes standardisation a difficult task even for an experienced sonographer. 3D imagery conveys in a single image all the information relating to power Doppler signal with the generation of a volume containing the regions of increased vascularity. The potential of this approach is particularly important in the field of therapeutic monitoring.

Time

The acquisition time of traditional 2D US is widely variable and dependent upon the anatomical area being examined and the experience of the operator. For a metacarpophalangeal joint, which is one of the most frequently evaluated joints in rheumatology, the time required for a detailed US assessment that includes depiction of bone profile, cartilage, joint cavity and adjacent tendons may require up to five minutes. The acquisition of 3D grey and power Doppler images require merely four seconds and eight seconds respectively (Fig. 2). Following this process the operator can navigate the plane of view of their choice and can contemporaneously obtain the corresponding coronal view. The interpretation of the images can be redirected to a more convenient time for the operator. From the patient's perspective a 3D examination is more attractive than a 2D examination in terms of time required.

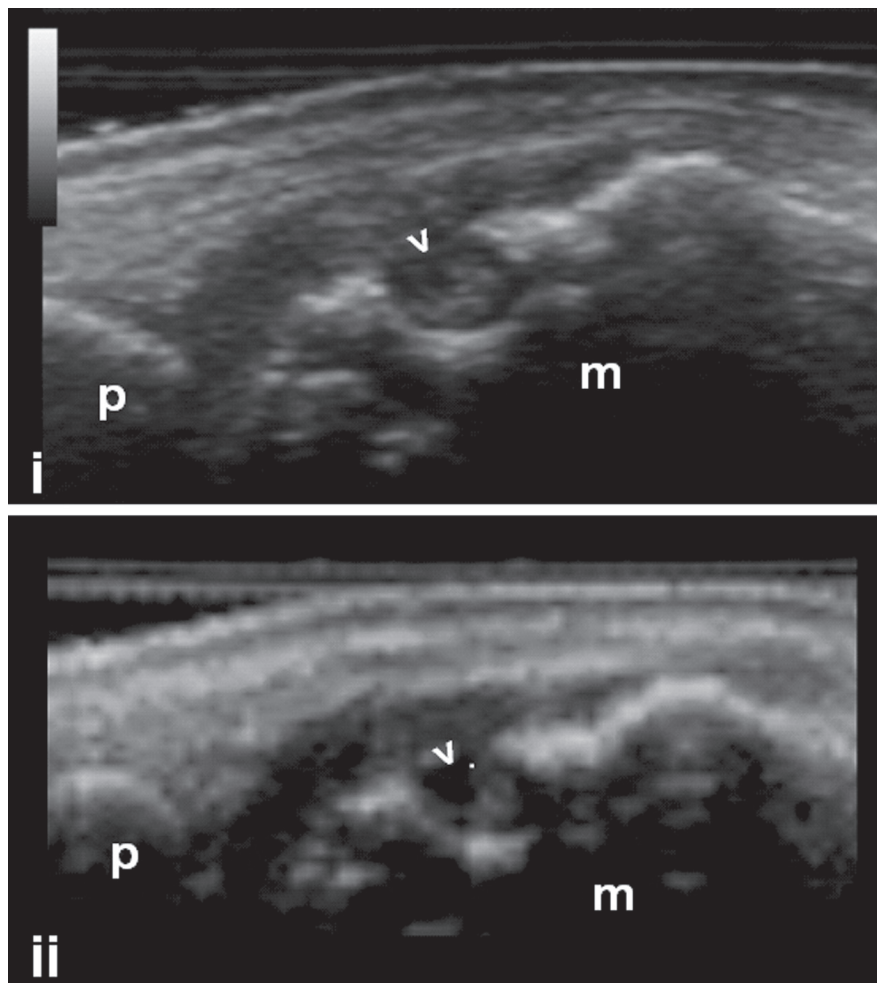


Fig. 2. Rheumatoid arthritis. Erosive involvement of the metacarpal head of the second metacarpophalangeal joint.

i: This high quality image was obtained by an experienced sonographer using 2D US following a skilled examination lasting approximately five minutes.

ii: One of the virtually unlimited number of longitudinal scans obtained using 3D US. In spite of slightly lower quality of the image, the same sonographic pathology is depicted as in (i). This image took approximately 3 seconds to obtain and was obtained by a novice operator. US images were obtained using a Logiq 9 (General Electric Medical Systems, Milwaukee, WI) equipped with a 8-15 MHz volumetric probe (4D16L). **m** = metacarpal head; **p** = proximal phalanx; **>** = bone erosion.

For further ultrasound images, please go to www.clinexprheumatol.org

Cost

The cost of conventional 2D US no longer appears to be a significant barrier to the widespread use of US in rheumatological practice. This is primarily due to the continuously improving cost-performance ratio. The cost-benefit ratio of 3D US outweighs that of its 2D counterpart and whilst cost may initially be a barrier to some the inherent benefits of this technology surely make it the more attractive option in the ever evolving technological era.

Limitations of the technology

The advent of 3D technology has heralded a new era in imagery for the rheu-

matologist sonographer but it does also bring some limitations which must be considered. The acquisition process does not currently allow for movement and therefore removes the possibility of obtaining a dynamic image which is a fundamental part of the examination process in some tissues and anatomical areas *e.g.*, tendons. As with 2D US, the image visualised is delimited by the footprint of the probe and does not allow for a more panoramic view of anatomical details which exceed this dimension *e.g.*, shoulder examination. The size and shape of the 3D probe can restrict its ability to explore certain anatomical regions of interest *e.g.*, lateral aspect of the digits.

Conclusion

Due to the specific characteristics of 3D US mentioned in this article, it seems likely that will become a more attractive imaging modality when compared with other techniques *e.g.* magnetic resonance imaging for imaging musculoskeletal disorders in many circumstances. For some rheumatologists 2D US may remain the sonographic modality of choice in the shorter term principally due to cost issues and in some circumstances where its dynamic capabilities may be more relevant. Once the practical benefits of 3D are widely known we predict that 3D US will prevail where applicable. In an era when time is a precious commodity, 3D US in the hands of a dedicated clinician is a powerful tool that can be used immediately without ascending great heights on the US learning curve. The 2D alternative to this innovative and attractive approach to US is a more complex, time-consuming and involved process. This shift in the balance between image acquisition and image interpretation will appeal to many. With conventional 2D US considerable effort is made both in image acquisition and interpretation during the scanning process. Akin to conventional radiography, 3D US does not require the reader to be actively involved in the acquisition process and the main input from the clinician is in the image interpretation process. Future application of 3D US within the research arena is likely to provide the necessary evidence to widely use this tool in rheumatological practice and clinical trials.

Link

For further ultrasound images, go to: www.clinexp Rheumatol.org/ultrasound

References

- FILIPPUCCI E, IAGNOCCO A, MEENAGH G *et al.*: Ultrasound imaging for the rheumatologist. *Clin Exp Rheumatol* 2006; 24: 1-5.
- KANE D, GRASSI W, STURROCK R, BALINT PV: Musculoskeletal ultrasound – a state of the art review in rheumatology. Part 2: Clinical indications for musculoskeletal ultrasound in rheumatology. *Rheumatology* 2004; 43: 829-38.
- MEENAGH G, FILIPPUCCI E, KANE D, TAGGART A, GRASSI W: Ultrasonography in rheumatology: developing its potential in clinical practice and research. *Rheumatology* 2007; 46: 3-5.
- GRASSI W, FILIPPUCCI E: Ultrasonography and the rheumatologist. *Curr Opin Rheumatol* 2007; 19: 55-60.
- ALBRECHT K, MÜLLER-LADNER U, STRUNK J: Quantification of the synovial perfusion in rheumatoid arthritis using Doppler ultrasonography. *Clin Exp Rheumatol* 2007; 25: 630-8.
- BALINT PV, MANDL P, KANE D: “All that glitters is not gold” – separating artefacts from true Doppler signals in rheumatological ultrasound. *Ann Rheum Dis* 2008; 67: 141-2.
- WAKEFIELD RJ, GREEN MJ, MARZO-ORTEGA H *et al.*: Should oligoarthritis be reclassified? Ultrasound reveals a high prevalence of sub-clinical disease. *Ann Rheum Dis* 2004; 63: 382-5.
- SCHMIDT WA: Value of sonography in diagnosis of rheumatoid arthritis. *Lancet* 2001; 357: 1056-7.
- FILIPPUCCI E, IAGNOCCO A, MEENAGH G *et al.*: Ultrasound imaging for the rheumatologist VII. Ultrasound imaging in rheumatoid arthritis. *Clin Exp Rheumatol* 2007; 25: 5-10.
- TAYLOR PC, STEUER A, GRUBER J *et al.*: Ultrasonographic and radiographic results from a two-year controlled trial of immediate or one-year-delayed addition of infliximab to ongoing methotrexate therapy in patients with erosive early rheumatoid arthritis. *Arthritis Rheum* 2006; 54: 47-53.
- NAREDO E, COLLADO P, CRUZ A *et al.*: Longitudinal power Doppler ultrasonographic assessment of joint inflammatory activity in early rheumatoid arthritis: predictive value in disease activity and radiologic progression. *Arthritis Rheum* 2007; 57: 116-24.
- SZKUDLAREK M, KLARLUND M, NARVESTAD E *et al.*: Ultrasonography of the metacarpophalangeal and proximal interphalangeal joints in rheumatoid arthritis: a comparison with magnetic resonance imaging, conventional radiography and clinical examination. *Arthritis Res Ther* 2006; 8: R52.
- FILIPPUCCI E, IAGNOCCO A, SALAFFI F, CERIONI A, VALESINI G, GRASSI W: Power Doppler sonography monitoring of synovial perfusion at the wrist joints in patients with rheumatoid arthritis treated with adalimumab. *Ann Rheum Dis* 2006; 65: 1433-7.
- WAKEFIELD RJ, O'CONNOR PJ, CONAGHAN PG *et al.*: Finger tendon disease in untreated early rheumatoid arthritis: a comparison of ultrasound and magnetic resonance imaging. *Arthritis Rheum* 2007; 57: 1158-64.
- NAREDO E, GAMERO F, BONILLA G, USON J, CARMONA L, LAFFON A: Ultrasonographic assessment of inflammatory activity in rheumatoid arthritis: comparison of extended versus reduced joint evaluation. *Clin Exp Rheumatol* 2005; 23: 881-4.
- DOWNNEY DB, FENSTER A, WILLIAMS JC: Clinical utility of three-dimensional US. *Radiographics* 2000; 20: 559-71.
- MEENAGH G, FILIPPUCCI E, ABBATTISTA T, BUSILACCHI P, GRASSI W: Three-dimensional power Doppler sonography in short-term therapy monitoring of rheumatoid synovitis. *Rheumatology* 2007; 46: 1736.
- FILIPPUCCI E, MEENAGH G, DE AGUSTIN JJ *et al.*: Level of agreement between rheumatologists on US image acquisition using a 3D volumetric probe. *Clin Exp Rheumatol* 2007; 25: 116.
- STRUNK J, STRUBE K, MÜLLER-LADNER U, LANGE U: Three dimensional power Doppler ultrasonography confirms early reduction of synovial perfusion after intra-articular steroid injection. *Ann Rheum Dis* 2006; 65: 411-2.
- STRUNK J, STRUBE K, RUMBAUR C, LANGE U, MÜLLER-LADNER U: Interobserver agreement in two- and three-dimensional power Doppler sonographic assessment of synovial vascularity during anti-inflammatory treatment in patients with rheumatoid arthritis. *Ultraschall Med* 2007; 28: 409-15.
- JU JH, YOON CH, KIM HY, PARK SH: Clinical images: visualization of the inner synovial surface with three-dimensional ultrasonography. *Arthritis Rheum* 2007; 56: 214.
- FILIPPUCCI E, MEENAGH G, CIAPETTI A, IAGNOCCO A, TAGGART A, GRASSI W: E-learning in ultrasonography: a web-based approach. *Ann Rheum Dis* 2007; 66: 962-5.
- TAGGART A, FILIPPUCCI E, WRIGHT G *et al.*: Musculoskeletal ultrasound training in rheumatology: The Belfast experience. *Rheumatology* 2006; 45: 102-5.
- D'AGOSTINO MA, MAILLEFERT JF, SAID-NAHAL R, BREBAN M, RAVAUD P, DOUGADOS M: Detection of small joint synovitis by ultrasonography: the learning curve of rheumatologists. *Ann Rheum Dis* 2004; 63: 1284-7.
- AMERICAN COLLEGE OF RADIOLOGY: ACR standard for performing and interpreting diagnostic ultrasound examinations. In: *Standards*. Reston, VA American College of Radiology, 1996: 235-6.
- KOSKI JM, SAARAKKALA S, HELLE M *et al.*: Assessing the intra- and inter-reader reliability of dynamic ultrasound images in power Doppler ultrasonography. *Ann Rheum Dis* 2006; 65: 1658-60.
- BALINT PV, STURROCK RD: Intraobserver repeatability and interobserver reproducibility in musculoskeletal ultrasound imaging measurements. *Clin Exp Rheumatol* 2001; 19: 89-92.
- NAREDO E, MÖLLER I, MORAGUES C *et al.*: EULAR Working Group for Musculoskeletal Ultrasound. Interobserver reliability in musculoskeletal ultrasonography: results from a “Teach the Teachers” rheumatologist course. *Ann Rheum Dis* 2006; 65: 14-9.
- SCHEEL AK, SCHMIDT WA, HERMANN KG *et al.*: Interobserver reliability of rheumatologists performing musculoskeletal ultrasonography: results from a EULAR “Train the trainers” course. *Ann Rheum Dis* 2005; 64: 1043-9.
- SALAFFI F, FILIPPUCCI E, CAROTTI M *et al.*: Inter-observer agreement of standard joint counts in early rheumatoid arthritis: a comparison with grey scale ultrasonography – a preliminary study. *Rheumatology* 2008; 47: 54-8.