

## Imaging

# Ultrasound imaging for the rheumatologist

## XV. Ultrasound imaging in vasculitis

A. Delle Sedie<sup>1</sup>, L. Riente<sup>1</sup>, E. Filippucci<sup>2</sup>, A. Iagnocco<sup>3</sup>, G. Meenagh<sup>4</sup>, O. Epis<sup>5</sup>,  
W. Grassi<sup>2</sup>, G. Valesini<sup>3</sup>, C. Montecucco<sup>5</sup>, S. Bombardieri<sup>1</sup>

<sup>1</sup>*Cattedra di Reumatologia, Università di Pisa, Pisa, Italy;*

<sup>2</sup>*Cattedra di Reumatologia, Università Politecnica delle Marche, Jesi, Italy;*

<sup>3</sup>*Cattedra di Reumatologia, Sapienza Università di Roma, Italy;*

<sup>4</sup>*Department of Rheumatology, Antrim Hospital, Antrim, United Kingdom;*

<sup>5</sup>*Cattedra di Reumatologia, IRCCS Policlinico S. Matteo, Università di Pavia, Pavia, Italy.*

Andrea Delle Sedie, MD; Lucrezia Riente, MD; Emilio Filippucci, MD; Annamaria Iagnocco, MD; Gary Meenagh, MD; Oscar Epis, MD; Walter Grassi, MD, Professor of Rheumatology; Guido Valesini, MD, Professor of Rheumatology; Carlomaurizio Montecucco, MD, Professor of Rheumatology; Stefano Bombardieri, MD, Professor of Rheumatology.

Please address correspondence and reprint requests to: Dr. Andrea Delle Sedie, U.O. Reumatologia, Dipartimento di Medicina Interna, Università di Pisa, Via Roma 67, Pisa 56126, Italy.  
E-mail: [adellese@lycos.com](mailto:adellese@lycos.com)

Received and accepted on May 27, 2008.  
*Clin Exp Rheumatol* 2008; 26; 391-394.

© Copyright CLINICAL AND EXPERIMENTAL RHEUMATOLOGY 2008.

**Key words:** Ultrasound, vasculitis, polymyalgia rheumatica, Takayasu's arteritis, temporal arteritis.

### ABSTRACT

*Over the last few years, a large number of studies have emphasized the fundamental role of ultrasonography (US) in the clinical evaluation of patients affected by rheumatic disorders. However, not all rheumatic diseases have been studied by US. To date, very few reports exist on the use of US in the assessment of articular, periarticular structures and blood vessels in vasculitis.*

*In this review we provide an overview of the current data regarding the role of US in vasculitis. Sonographic evaluation of cardiac or renal involvement in these disorders will not be covered.*

### Introduction

Over the last few years, a large number of studies have emphasized the fundamental role of ultrasonography (US) in the clinical evaluation of patients affected by rheumatic disorders (1-15). Musculoskeletal US is considered a very useful tool for the diagnosis of arthritis and monitoring of joint and tendon involvement (16). However, not all rheumatic diseases have been studied by US. Systemic vasculitides are a group of disorders characterized by inflammation of vessel walls often leading to very serious organ damage. To date, very few reports on the potential role of US in the assessment of articular, periarticular structures and vessels in vasculitis exist (17-40).

In this review, we provide an overview of the current data regarding the role of US in vasculitis. Sonographic evaluation of cardiac or renal involvement in these disorders will not be covered.

### *Polymyalgia rheumatica*

US has demonstrated effusion in bursae (Figs. 1a, 1b), tendons sheaths and joints, together with enthesal involvement

in polymyalgia rheumatica (PMR). PMR is the widest studied vasculitis sonographically albeit with conflicting results from many of the studies published (19-22). This is mainly due to lack of conformity in patient selection criteria. Frediani *et al.* (22) studied patients with recent onset PMR who were all naïve to steroids or immunosuppressive drugs. Synovitis, at least in one site, was detected in 100% of the patients, according to reports obtained with different imaging techniques (US, MRI, scintigraphy) (20, 21, 23, 24). The most frequently involved articular and periarticular structures were in the shoulder. Subacromial-subdeltoid (SAD) bursitis, tenosynovitis of the long head of biceps tendon (LHBT) and glenohumeral (GH) joint effusion were visualized in 70%, 68% and 66% of patients respectively. Less commonly, hip joint effusion was shown in 40% and effusion of the knee (38%), elbow (2%) and radiocarpal (18%) joints were seen. Tenosynovitis was present in the wrist flexors and extensors and at the ankle (posterior tibial, foot extensors and peroneals). Enthesitis was more frequent in spondyloarthropathy (SpA) than in PMR while no statistically significant difference in the prevalence of LHBT and SAD involvement. GH and hip effusion were significantly more frequent in PMR than in SpA patients whilst the frequency of synovitis was significantly higher in SpA and in a group of patients with rheumatoid arthritis (RA). Distal extremity swelling with pitting edema was identified only in PMR.

Several studies have concentrated on US findings within the shoulder apparatus. Both Koski (20) and Coari (19) reported a low prevalence of SAD effusion in PMR whilst Lange *et al.* (21),

Competing interests: none declared.

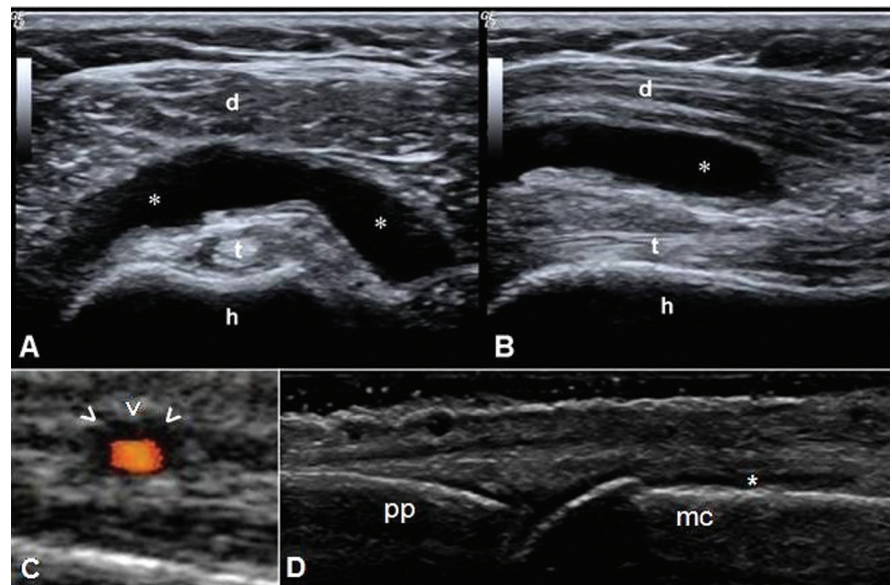
observed more frequent SAD involvement in early RA than in PMR with a tendency toward unilateral involvement in PMR. A further study by Cantini *et al.* (25) studied PMR using US and MRI and showed bilateral SAD bursitis in almost all of the patients studied, while the frequencies of GH effusion and LHBT tenosynovitis were not significantly different from a control group of patients with shoulder pain. The authors concluded that US and MRI were equally effective in confirming bilateral SAD effusion which appeared to be a typical finding with high specificity and sensitivity in PMR.

More recently, the same investigator studied pelvic pain in PMR patients again with MRI and US concentrating the examination to the hip region. They demonstrated that the trochanteric bursitis was the most frequent hip lesion (100% of patients, frequently bilateral), whilst the frequency of hip synovitis was similar to that reported by Falsetti *et al.* (22), but lower than reported by Koski *et al.* (20).

In conclusion, US detects inflammation involving joints or tendons in PMR very frequently. The distribution of involvement is variable but is dissimilar to those seen typically in SpA and RA. These US features of PMR may prove to be useful for the differential diagnosis in elderly patients.

### Giant cell arteritis (temporal arteritis)

A high quality US machine, with a linear high frequency probe should be used to visualize the temporal artery both in longitudinal and transverse scans (27). In giant cell arteritis (GCA) colour Doppler has great diagnostic potential as demonstrated by the results of the meta-analysis by Karassa *et al.* (28) showing high sensitivity and specificity (87% and 96% respectively) of this imaging technique compared to clinical diagnosis. US sensitivity and specificity are similar to those of histological examination. Whilst biopsy proven arteritis remains the gold standard technique for diagnosis, an experienced sonographer is also able to obtain images which may lead to the correct diagnosis. It has been demon-



**Fig 1.** *Polymyalgia rheumatica*: Anterior transverse (A) and longitudinal (B) views of the shoulder. The asterisk indicates a marked bursal enlargement due to a relevant increase of synovial fluid appearing homogeneously anechoic. **h** = humerus; **t** = long head of the biceps; **d** = deltoid. Images taken using a Logiq 9 (General Electric Medical Systems, Milwaukee, WI) equipped with a 6-9 MHz linear probe. *Giant cell arteritis (temporal arteritis)*: Transverse (C) scan of the temporal artery. The head arrows indicate the typical “halo sign” around the lumen of the temporal artery. Image taken using a Nemio (Toshiba, Japan) equipped with a 8-12 MHz linear probe. *Essential cryoglobulinemic vasculitis*: Dorsal longitudinal (D) scan of the second metacarpophalangeal joint. The asterisk indicates joint effusion. **mc** = metacarpus; **pp** = proximal phalanx. Image taken using a Logiq 9 (General Electric Medical Systems, Milwaukee, WI) equipped with a 14 MHz linear probe.

For further ultrasound images, go to: [www.clinexp Rheumatol.org/ultrasound](http://www.clinexp Rheumatol.org/ultrasound)

strated that US correlates directly with positron emission tomography in the anatomic distribution of changes in patients with large vessel giant cell arteritis (29). Moreover, it is well known that US can be an important tool to guide scalpel positioning for temporal artery biopsy.

The three characteristic features of an inflamed artery are: intimal edema, stenosis and occlusion. The first is also termed the “halo sign” due to the presence of a hypoechoic area around the lumen of the temporal artery (Fig. 1c); this sign may involve a short segment or the whole length of the artery, as expected in a skip lesion disease. The “halo sign” disappears within 2-3 weeks after the glucocorticoid therapy has started (27). Volpe *et al.* (30) reported that the “halo sign” is well visualized by colour Doppler and grey-scale US. The dimensions of the halo sign seem to be very important with maximum widths  $\geq 1$  mm being correlated with high specificity (93%) (31).

Stenosis is represented by a reduction

in lumen width and is associated with an increased blood flow velocity; color Doppler US shows a mixture of colours and persisting color signals in the diastolic phase (27). Finally, occlusion is represented by an US image of the artery with absence of color Doppler signal (28). In the presence of typical symptoms and the halo sign on US examination, Schmidt *et al.* (32) reported a specificity for US examination of 99.5%.

### Takayasu’s arteritis

This form of vasculitis involves predominantly the aorta and its primary branches. Similar to GCA US demonstrates the typical signs of an inflamed vessel (smooth, homogeneous, hypoechoic, concentric wall thickening), brighter than in temporal arteritis (27), sometimes termed the “macaroni sign” (33). The reason for this difference in echogenic pattern, probably lies in the more chronic course of Takayasu’s arteritis and less wall edema (34, 35). The detection of the “macaroni sign” helps

make a diagnosis in the earlier phases of the disease, when haemodynamically relevant stenoses are not yet evident. US examination in Takayasu arteritis has also been used at other arterial sites including the common carotid, subclavian and common femoral arteries (37) and with transcranial Doppler sonography (38). It has been demonstrated that US is superior to angiography in the detection of smaller carotid lesions (33, 36) but angiography demonstrates luminal changes in more arteries. Therefore, US and angiography are considered complementary in the evaluation of Takayasu patients. In conclusion, US of carotid and subclavian arteries can be performed not only to detect early phases of the disease but also to monitor disease progression and the effect of therapy.

### Behçet's syndrome

Articular pain is a common complaint in patients with Behçet's syndrome (BS) and often present with non-erosive mono or oligoarthritis. Occasionally destructive sacroiliitis or enthesitis can occur. In a recent paper, Özçakar *et al.* (39), focused their attention on changes in tendons in a group (n=31) of patients with BS. Control groups were represented by patients with familial Mediterranean fever (FMF) and normal subjects. US examination of the triceps tendon (TT), quadriceps tendon (QT) and Achilles tendon (AT) showed a significant increase in TT thickness in FMF patients with respect to both of the other groups, while QT was significantly greater in BS and AT was greater in BS respect to controls but not to the FMF group. Comparing these data with clinical features, a positive correlation was found between the pathergy test and the presence of thicker QT and AT, while no correlation was found for disease duration, colchicine treatment or joint involvement both in FMF and BS groups. The Authors concluded that continuous subclinical inflammation may occur even in the patients with apparent disease remission. Moreover, the high frequency of tendon involvement in BS appears to be a significant musculoskeletal manifestation of the disease. More recently, Ceccarelli *et al.* (40) investigated knee involvement in a

group (n=30) of Italian BS patients. US examination was performed according to the EULAR guidelines for US (41), using arbitrary scores for synovitis, erosions, PD signal and the presence/absence of Baker's cyst, with a total score ranging from 0 to 14 (with higher scores for more involved joints). Significant abnormalities were demonstrated in 60% of the patients, with joint effusion (46%), synovial proliferation (46% and PD positivity in 28% out of them) and erosions (10%). The most interesting finding was the presence of US changes in 4 asymptomatic patients. US features seemed to be linked with those bearing skin manifestations of BS (42), and a positive correlation between disease activity generally and US score in the group with more US findings. More recently, Hatemi *et al.* (43), comparing BD patients with acne and arthritis (n=35) to patients without arthritis (n=38), have demonstrated significant differences in enthesopathy and PD scores, supporting the hypothesis that BD patients who also have arthritis and acne form a distinct cluster.

As far as we know, no specific US studies have been performed on other vasculitides, such as Churg-Strauss syndrome, Wegener's granulomatosis, microscopic polyangiitis, Kawasaki syndrome, polyarteritis nodosa and essential cryoglobulinemic vasculitis (Fig. 1d). Future research using US in systemic vasculitis will need to concentrate on techniques to ensure reproducible quantification of power Doppler and the correlation of US findings with histological features. A new application of US, still under investigation in systemic sclerosis patients, is the evaluation of lung fibrosis (identifying both pleural effusion and interstitial changes) (44-46). Therefore, thoracic US could be a possible alternative to high resolution computed tomography in the follow-up of systemic sclerosis, and potentially other inflammatory conditions with lung involvement such as vasculitis (*e.g.*, Churg-Strauss syndrome, Wegener's granulomatosis).

### Link

For further ultrasound images, go to [www.clinexprheumatol.org/ultrasound](http://www.clinexprheumatol.org/ultrasound)

### References

- FILIPPUCCI E, IAGNOCCO A, MEENAGH G *et al.*: Ultrasound imaging for the rheumatologist. *Clin Exp Rheumatol* 2006; 24: 1-5.
- IAGNOCCO A, FILIPPUCCI E, MEENAGH G *et al.*: Ultrasound imaging for the rheumatologist. I. Ultrasound of the shoulder. *Clin Exp Rheumatol* 2006; 24: 6-11.
- FILIPPUCCI E, IAGNOCCO A, MEENAGH G *et al.*: Ultrasound imaging for the rheumatologist. II. Ultrasound of the hand and wrist. *Clin Exp Rheumatol* 2006; 24: 118-22.
- IAGNOCCO A, FILIPPUCCI E, MEENAGH G *et al.*: Ultrasound imaging for the rheumatologist. III. Ultrasound of the hip. *Clin Exp Rheumatol* 2006; 24: 229-32.
- MEENAGH G, IAGNOCCO A, FILIPPUCCI E *et al.*: Ultrasound imaging for the rheumatologist. IV. Ultrasonography of the knee. *Clin Exp Rheumatol* 2006; 24: 357-60.
- RIENTE L, DELLE SEDIE A, IAGNOCCO A *et al.*: Ultrasound imaging for the rheumatologist. V. Ultrasonography of the ankle and foot. *Clin Exp Rheumatol* 2006; 24: 493-8.
- DELLE SEDIE A, RIENTE L, IAGNOCCO A *et al.*: Ultrasound imaging for the rheumatologist. VI. Ultrasonography of the elbow, sacroiliac, parasternal, and temporomandibular joints. *Clin Exp Rheumatol* 2006; 24: 617-21.
- FILIPPUCCI E, IAGNOCCO A, MEENAGH G *et al.*: Ultrasound imaging for the rheumatologist. VII. Ultrasound imaging in rheumatoid arthritis. *Clin Exp Rheumatol* 2007; 25: 5-10.
- MEENAGH G, FILIPPUCCI E, IAGNOCCO A *et al.*: Ultrasound imaging for the rheumatologist. VIII. Ultrasound imaging in osteoarthritis. *Clin Exp Rheumatol* 2007; 25: 172-5.
- RIENTE L, DELLE SEDIE A, FILIPPUCCI E *et al.*: Ultrasound imaging for the rheumatologist. IX. Ultrasound imaging in spondyloarthritis. *Clin Exp Rheumatol* 2007; 25: 349-53.
- DELLE SEDIE A, RIENTE L, IAGNOCCO A *et al.*: Ultrasound imaging for the rheumatologist. X. Ultrasound imaging in crystal-related arthropathies. *Clin Exp Rheumatol* 2007; 25: 513-7.
- IAGNOCCO A, FILIPPUCCI E, MEENAGH G *et al.*: Ultrasound imaging for the rheumatologist. XI. Ultrasound imaging in regional pain syndromes. *Clin Exp Rheumatol* 2007; 25: 672-5.
- FILIPPUCCI E, MEENAGH G, DELLE SEDIE A *et al.*: Ultrasound imaging for the rheumatologist. XII. Ultrasound imaging in sports medicine. *Clin Exp Rheumatol* 2007; 25: 806-9.
- FILIPPUCCI E, MEENAGH G, EPIS O *et al.*: Ultrasound imaging for the rheumatologist. XIII. New trends. Three-dimensional ultrasonography. *Clin Exp Rheumatol* 2008; 26: 1-4.
- RIENTE L, DELLE SEDIE A, FILIPPUCCI E *et al.*: Ultrasound imaging for the rheumatologist. XIV. Ultrasound imaging in connective tissue diseases. *Clin Exp Rheumatol* 2008; 26: 230-3.
- DELLE SEDIE A, RIENTE L, BOMBARDIERI S: Limits and perspectives of ultrasound in the diagnosis and management of rheumatic diseases. *Mod Rheumatol* 2008; 18: 125-31.

17. SCHMIDT WA, KRAFT HE, VORPAHL K, VOLKER L, GROMNICA-IHLE EJ: Color duplex ultrasonography in the diagnosis of temporal arteritis. *N Eng J Med* 1997; 337: 1336-42.
18. SCHMIDT WA, GROMNICA-IHLE EJ: Incidence of temporal arteritis in patients with polymyalgia rheumatica: a prospective study using colour Doppler ultrasonography of the temporal arteries. *Rheumatology* 2002; 41: 46-52.
19. COARI G, PAOLETTI F, IAGNOCCO A: Shoulder involvement in rheumatic diseases. Sonographic findings. *J Rheumatol* 1999; 26: 668-73.
20. KOSKI JM: Ultrasonographic evidence of synovitis in axial joints in patients with polymyalgia rheumatica. *Br J Rheumatol* 1992; 31:201-3.
21. LANGE U, PIEGSA M, TEICHMANN J, NEECK G: Ultrasonography of the glenohumeral joints--a helpful instrument in differentiation in elderly onset rheumatoid arthritis and polymyalgia rheumatica. *Rheumatol Int* 2000; 19: 185-9.
22. FREDIANI B, FALSETTI P, STORRI L *et al.*: Evidence for synovitis in active polymyalgia rheumatica: sonographic study in a large series of patients. *J Rheumatol* 2002; 29: 123-30.
23. O'DUFFY JD, WAHNER HW, HUNDER GG: Joint imaging in polymyalgia rheumatica. *Mayo Clin Proc* 1976; 5: 519-24.
24. SALVARANI C, CANTINI F, OLIVIERI I *et al.*: Proximal bursitis in active polymyalgia rheumatica. *Ann Intern Med* 1997; 127: 27-31.
25. CANTINI F, SALVARANI C, OLIVIERI I *et al.*: Shoulder ultrasonography in the diagnosis of polymyalgia rheumatica: a case-control study. *J Rheumatol* 2001; 28: 1049-55.
26. CANTINI F, NICCOLI L, NANNINI C *et al.*: Inflammatory changes of hip synovial structures in polymyalgia rheumatica. *Clin Exp Rheumatol* 2005; 23: 462-8.
27. SCHMIDT WA: Technology Insight: the role of color and power Doppler ultrasonography in rheumatology. *Nat Clin Pract Rheumatol* 2007; 3: 35-42.
28. KARASSA FB, MATSAGAS MI, SCHMIDT WA, IOANNIDIS JP: Meta-analysis: test performance of ultrasonography for giant-cell arteritis. *Ann Intern Med* 2005; 142: 359-69.
29. SCHMIDT WA, BLOCKMANS D: Use of ultrasonography and positron emission tomography in the diagnosis and assessment of large-vessel vasculitis. *Curr Opin Rheumatol* 2005; 17: 9-15.
30. VOLPE A, CARAMASCHI P, MARCHETTA A, BIASI D, BAMBARA LM, ARCARO G: B-flow ultrasound in a case of giant cell arteritis. *Clin Rheumatol* 2007; 26: 1955-7.
31. SALVARANI C, SILINGARDI M, GHIRARDUZZI A *et al.*: Is duplex ultrasonography useful for the diagnosis of giant-cell arteritis? *Ann Intern Med* 2002; 137: 232-8.
32. SCHMIDT WA, GROMNICA-IHLE E: Duplex ultrasonography in temporal arteritis. *Ann Intern Med* 2003; 138: 609.
33. MAEDA H, HANDA N, MATSUMOTO M *et al.*: Carotid lesions detected by B-mode ultrasonography in Takayasu's arteritis: "macaroni sign" as an indicator of the disease. *Ultrasound Med Biol* 1991; 17: 695-701.
34. SCHMIDT WA, NERENHEIM A, SEIPELT E, POEHLS C, GROMNICA-IHLE E: Diagnosis of early Takayasu arteritis with sonography. *Rheumatology (Oxford)* 2002; 41: 496-502.
35. RINGLEB PA, STRITTMATTER EI, LOEWER M *et al.*: Cerebrovascular manifestations of Takayasu arteritis in Europe. *Rheumatology (Oxford)* 2005; 44: 1012-5.
36. TANIGUCHI N, ITOH K, HONDA M *et al.*: Comparative ultrasonographic and angiographic study of carotid arterial lesions in Takayasu's arteritis. *Angiology* 1997; 48: 9-20.
37. LEFEBVRE C, RANCE A, PAUL JF *et al.*: The role of B-mode ultrasonography and electron beam computed tomography in evaluation of Takayasu's arteritis: a study of 43 patients. *Semin Arthritis Rheum* 2000; 30: 25-32.
38. CANTÚ C, PINEDA C, BARINAGARREMENTERIA F *et al.*: Noninvasive cerebrovascular assessment of Takayasu arteritis. *Stroke* 2000; 31: 2197-202.
39. OZÇAKAR L, ONAT AM, URETEN K *et al.*: Sonographic evaluation of the tendons in familial Mediterranean fever and Behçet's disease. *Joint Bone Spine* 2006; 73: 514-7.
40. CECCARELLI F, PRIORI R, IAGNOCCO A *et al.*: Knee joint synovitis in Behçet's disease: a sonographic study. *Clin Exp Rheumatol* 2007; 25 (Suppl. 4): S76-9.
41. BACKHAUS M, BURMESTER GR, GERBER T *et al.*: Guidelines for musculoskeletal ultrasound in rheumatology. *Ann Rheum Dis* 2001; 60:641-9.
42. DIRI E, MAT C, HAMURYUDAN V, YURDAKUL S, HIZLI N, YAZICI H: Papulopustular skin lesions are seen more frequently in patients with Behçet's syndrome who have arthritis: a controlled and masked study. *Ann Rheum Dis* 2001; 60: 1074-6.
43. HATEMI G, FRESKO I, TASCILAR K, YAZICI H: Increased enthesopathy among Behçet's syndrome patients with acne and arthritis: an ultrasonography study. *Arthritis Rheum* 2008; 58: 1539-45.
44. LICHTENSTEIN DA: Ultrasound in the management of thoracic disease. *Crit Care Med* 2007; 35 (Suppl.): S250-61.
45. PICANO E, FRASSI F, AGRICOLA E, GLIGOROVA S, GARGANIL, MOTTOLA G: Ultrasound lung comets: a clinically useful sign of extravascular lung water. *J Am Soc Echocardiogr* 2006; 19: 356-63.
46. DOVERI M, FRASSI F, CONSENSI A *et al.*: Le comete ultrasoniche polmonari: un nuovo segno ecografico di fibrosi polmonare nella scleroderma. *Reumatismo* 2007; 59 (numero speciale 2): 12.