

## Imaging

### Ultrasound imaging for the rheumatologist

#### IV. Ultrasonography of the knee

G. Meenagh<sup>1</sup>, A. Iagnocco<sup>2</sup>, E. Filippucci<sup>3</sup>, L. Riente<sup>4</sup>, A. Delle Sedie<sup>4</sup>,  
S. Bombardieri<sup>4</sup>, G. Valesini<sup>2</sup>, W. Grassi<sup>3</sup>

<sup>1</sup>Department of Rheumatology, Musgrave Park Hospital, Belfast, UK; <sup>2</sup>Cattedra di Reumatologia, Università di Roma "La Sapienza", Roma; <sup>3</sup>Cattedra di Reumatologia, Università Politecnica delle Marche, Jesi, Italy; <sup>4</sup>Unità Operativa di Reumatologia, Università di Pisa, Italy.

Gary Meenagh, MD; Annamaria Iagnocco, MD; Emilio Filippucci, MD; Lucrezia Riente, MD; Andrea Delle Sedie, MD; Stefano Bombardieri, MD, Professor of Rheumatology; Guido Valesini, MD, Professor of Rheumatology; Walter Grassi, MD, Professor of Rheumatology.

Please address correspondence and reprint requests to: Prof. Walter Grassi, Cattedra di Reumatologia, Università Politecnica delle Marche, Ospedale "A. Murri", Via dei Colli 52, 60035 Jesi (AN), Italy.  
E-mail: [walter.grassi@univpm.it](mailto:walter.grassi@univpm.it)

*Clin Exp Rheumatol* 2006; 24: 357-360

Received on July 1, 2006; accepted on July 18, 2006.

© Copyright CLINICAL AND EXPERIMENTAL RHEUMATOLOGY 2006.

**Key words:** Ultrasonography, knee, synovitis, popliteal cyst.

#### ABSTRACT

*Ultrasound examination of the knee is particularly useful in the detection of synovitis, early degenerative changes within the articular cartilage of the femoral condyles, calcifications within the articular cartilage layer and menisci, bursitis, and popliteal cysts. Also, important anatomical information about the structural integrity of the supporting tissues around the knee can be obtained by ultrasound in patients presenting with 'knee pain'.*

*We review the available evidence about the use of ultrasound in knee examination, provide information on the technical equipment and scanning methods and discuss the still controversial issues.*

#### Introduction

The knee is one of the joints which can be extensively explored with ultrasound (US) due to the presence of wide acoustic windows which allow easy visualisation of different anatomical structures. The knee was one of the first sites of interest for musculoskeletal US in the 1970s and was initially used for the detection of Baker's cysts (1). The ease with which fluid collections in the popliteal fossa are detected, even with first generation equipment, has rapidly made arthrography obsolete. At present, a Medline search reveals that there are 1467 papers selected by the keys "ultrasound" and "knee". Most of the studies carried out by rheumatologists are focused on synovitis of the knee and underline the potential of US as a sensitive and reliable tool for the detection of knee inflammation (2-15). A comprehensive approach to knee US requires adequate training and experience because of the anatomical complexity of the joint and the related structures.

#### Indications

There is a broad spectrum of indications for US in the rheumatological setting (Table I). In inflammatory arthropathies, US is particularly useful in the detection of sub-clinical synovitis (5-8). Early degenerative changes within the articular cartilage of the femoral condyles can be demonstrated in the setting of primary osteoarthritis (OA) and as a secondary phenomenon in inflammatory arthritis (16-25). Hallmark features of crystalline arthritis, such as calcification within the articular cartilage layer and menisci, are also easily seen with US (1, 26). Important anatomical information about the structural integrity of the supporting tissues around the knee can be obtained by US in patients with no previous rheumatic history presenting with 'knee pain' (27).

#### US equipment

Depending on the specific targets of the examination, a wide range of frequencies can be used. The choice is influenced by the size of the patient and the distribution of body fat. A balance between the use of low frequency probes for a panoramic view (i.e. fluid collection in the supra-patellar pouch) and higher frequency probes for a more detailed assessment of more superficial anatomical structures (i.e. patellar tendon, collateral ligaments and anserine tendon) is ideal.

#### Scanning technique

For US examination of the knee, the patient must be positioned supine on a bed or couch to allow the examination of the anterior and lateral compartments. The prone position must be adopted to permit exploration of the posterior compartment. According to the guidelines (28) there are 10 main ac-

oustic windows for US examination of the knee. US access to the different anatomical structures of the knee may be tailored however, to include other scanning planes according to the specific aim of the investigation and the characteristics of the anatomical area explored. This is particularly true for the knee which is a large joint with several ligaments and bursae and a large articular surface which can be difficult to study using only longitudinal and transverse views. Longitudinal and transverse scans are required to ensure a detailed assessment of the key findings of normal healthy cartilage. Para-patellar and sub-patellar scans may be useful for a better assessment of parts of the weight-bearing cartilage. Sub-patellar transverse scans should be performed with the knee in the fully extended position.

## US anatomy

### Joints

The knee is the largest joint of the body with an extended joint space. In healthy subjects, a minimal amount of fluid can be detected in the supra-patellar pouch especially after active contraction of the knee with the leg fully extended.

The supra-patellar pouch is a virtual cavity and could be regarded as a bursa from a physiological point of view. The anatomical landmarks for its identification are represented by the deep margin of the quadriceps tendon, the quadriceps muscle and by a layer of connective tissue interposed between the deep wall and femoral bone profile. This connective tissue has a homogeneously hypoechoic structure, variable shape and distribution which can generate misinterpretation, even being mistaken for synovial proliferation in some cases.

Condylar cartilage is best assessed with the knee preferably maintained in maximal active flexion. The cartilaginous layer appears as a homogeneously anechoic band with sharply defined margins. The external margin is thinner and requires adequate calibration of the US equipment and appropriate positioning of the probe. The medial and lateral menisci appear as homogeneously triangular areas on longitudinal scans with their apices centred on the articular rim.

**Table I.** Main indications for performing an US examination of the knee.

Rheumatological setting	Indications for performing US examination.
Osteoarthritis	Detect synovitis (especially sub clinical knee inflammation). Reveal femoral cartilage involvement. Guide intra-articular injection of hyaluronic acid.
Rheumatoid arthritis	Detect synovitis (especially sub clinical knee inflammation). Assess pannus vascularity. Reveal cartilage and bone lesions.
Seronegative spondyloarthropathies	Assess enthesal involvement Detect synovitis (especially sub clinical knee inflammation).
Crystal related arthropathies	Detect meniscal calcification. Identify crystal aggregates within or on the surface of the cartilage layer. Guide aspiration of even small amounts of fluid for subsequent synovial fluid analysis.
Knee pain	Assess the morphostructural integrity of the assessable anatomic structures of the knee and identify characteristic pathologic changes eg. jumper's knee and Osgood-Schlatter disease.
Pseudo thrombophlebitis	Detect popliteal cyst and its topographic relationship with the popliteal vessels.

### Tendons

The quadriceps and patellar tendons have characteristic "fibrillar" echotexture and are clearly delimited from the surrounded tissues by sharp hyperechoic margins corresponding to the peritenonium. Neither tendon has a tendon sheath. The anatomical margins of the quadriceps tendon are clearly defined with soft tissue delimiting the anterior and the supra-patellar fat pad the posterior margins. The US features of the patellar tendon include more expanded transverse diameter at the proximal insertion compared to the tibial insertion. Both the patellar and tibial insertions demonstrate the typical features of an enthesis.

### Bursae

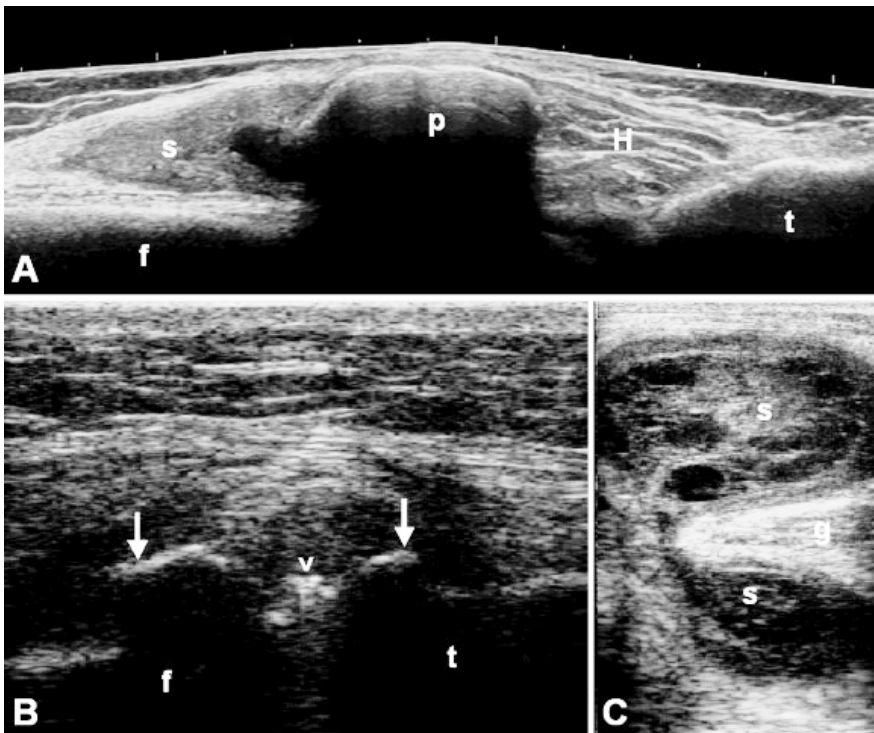
Synovial bursae of the knee are not detectable in healthy subjects. The superficial bursae are virtual cavities which are not in communication with the knee joint. The suprapatellar bursa is located deep to the quadriceps tendon and is in direct communication with the knee joint. The prepatellar bursa lies anterior to the lower pole of the patella and the origin of the patellar tendon. In the infrapatellar region there are two anatomically important bursae: superficial and deep with the tibial tubercle acting as the US landmark for

identification. The pes anserine bursa represents one of the most clinically relevant bursae around the knee. It is located on the antero-medial aspect of the tibia and is found between the tendons of semi-tendinosus, gracilis and sartorius. The gastrocnemius-semimembranosus bursa communicates with the knee joint cavity and may enlarge with knee joint effusions.

## US pathology

### Joints

Joint effusion represents one of the earliest clinical signs of synovial pathology within the knee joint. Its hallmark features include distension of the articular recesses within the knee joint with joint fluid of differing degrees of echogenicity. US is a particularly useful scanning modality to confirm the presence of effusion and document the presence of synovial hypertrophy and hypervascularity using power Doppler. There is compelling scientific evidence to support the superiority of US over clinical examination in detecting the presence of a knee effusion (8). Moreover, highly positive correlation has been demonstrated in the assessment of synovial tissue vascularity of the knee in patients with osteoarthritis and rheumatoid arthritis between power Doppler sonography and histo-



**Fig. 1.** Representative examples of knee US pathological findings. **A.** Rheumatoid arthritis. Proliferative synovitis of the knee joint on anterior longitudinal extended view. **B.** Calcium pyrophosphate deposition disease. Lateral longitudinal scan showing a meniscal calcification (<) and osteophytes (arrows). **C.** Psoriatic arthritis. Bilobate popliteal cyst. Bursal enlargement is mainly due to synovial tissue hypertrophy. f = femur; t = tibia; p = patella; s = synovial proliferation; H = Hoffa fat pad; g = gastrocnemius.

For further ultrasound images, please go to [www.clinexprheumatol.org](http://www.clinexprheumatol.org)

pathologic evaluations (12, 13).

Furthermore, various anatomical details within the effusion can provide the rheumatologist with further important information pertinent to making the final clinical diagnosis eg. the presence of crystalline matter, rice bodies etc.

There has been growing interest in the appearance of articular cartilage of the knee in various arthropathies, particularly OA. A spectrum of change has been described within the femoral cartilage particularly in the medial compartment of the tibio-femoral joint including focal thinning, loss of sharpness of the superior cartilagenous margin and eventual denuded areas. High frequency US has been used successfully in the quantitative assessment of degenerative changes in knee OA (16-21).

**Tendons**

US is regarded as the gold standard imaging modality for the assessment of the tendons (29-31). At knee level, US permits accurate and detailed morpho-structural analysis of the tendons. Sev-

eral sonographic abnormalities of quadriceps and patellar tendon echotexture can be documented including anechoic discontinuity of the “fibrillar” pattern, hypoechoic areas within the tendon, hyperechoic spots without acoustic shadow and hyperechoic bands which may generate acoustic shadow. The specific US findings and their distribution within the tendon are helpful for understanding the underlying pathology. In subjects with jumper’s knee for example, the proximal and deeper part of the patellar tendon is typically involved (32-34). In patients with Osgood Schlatter disease, US may detect a wide range of pathologic findings including soft tissue oedema, fragmentation of the ossified centre at the anterior tibial tubercle, thickening of the distal part of the patellar tendon and deep infrapatellar bursitis (35).

In routine rheumatological practice the major tendons around the knee joint are the focus of attention in cases where enthesopathy is suspected. As in other anatomical areas, enthesopathy of the

quadriceps and patellar tendons may show the following pathologic features: loss of normal fibrillar echotexture (with or without Doppler signal) and/or thickening of the tendon at its bony attachment and/or changes of the bone profile including enthesophytes, erosions or irregularity (36).

**Bursae**

Bursitis most often represents a primary inflammatory process depending on the specific bursa affected. Some bursae communicate with the knee joint and secondarily become involved in the inflammatory process. Pes anserine bursitis is a common clinical problem, particularly in knee OA and with US appears as a cystic area adjacent to the pes anserine tendon. It may develop into a chronic condition with synovial hypertrophy filling the bursal space and focal calcification.

With US, prepatellar and infrapatellar bursitis can be readily identified both by reproduction of pain upon sono-palpation over the area and by the rather flattened hypoechoic sac seen. Great care must be taken while performing US to prevent excessive pressure and therefore apparent collapse of these small distended bursal sacs.

One of the first pathological findings to be described by US in rheumatology was a popliteal or Baker’s cyst. These are synovially lined cysts and represent distended gastrocnemius-semimembranosus bursae filled with hypoechoic fluid and occasionally containing septae and loose bodies. The US confirmation of a popliteal cyst is made by identification of the neck which is located between the semimembranous tendon and the medial gastrocnemius muscle.

**Sonographic guided procedures**

US is particularly useful in guiding injections of the knee joint because it permits direct visualization of the needle into the joint cavity and ensures accurate delivery of the intra-articular substance injected.

This confirmation of correct placement of the tip of the needle within the joint space is particularly useful for hyaluronic acid injection into a “dry” knee. US is of tremendous help when soft tis-

sue injection is being performed into small bursae or in the skilled aspiration of a popliteal cyst where vital vascular structures are in close proximity.

### Controversial issues

At present the role of US in reliably performing quantitative measurements of articular cartilage thickness in degenerative arthropathies is perhaps one of the most stimulating areas of debate within rheumatology and musculoskeletal radiology. An expanding body of scientific knowledge is being developed in this area with several reporting very encouraging results (16, 17, 19-25).

### Link

For further ultrasound images, go to: [www.clinexprheumatol.org/ultrasound](http://www.clinexprheumatol.org/ultrasound)

### References

- MCDONALD DG, LEOPOLD GR: Ultrasound B-scanning in the differentiation of Baker's cyst and thrombophlebitis. *Br J Radiol* 1972; 45: 729-32.
- GRASSI W, SALAFFI F, FILIPPUCCI E: Ultrasound in rheumatology. *Best Pract Res Clin Rheumatol* 2005; 19: 467-85.
- KANE D, GRASSI W, STURROCK R, BALINT PV: Musculoskeletal ultrasound - a state of the art review in rheumatology. Part 2: Clinical indications for musculoskeletal ultrasound in rheumatology. *Rheumatology* 2004; 43: 829-38.
- GRASSI W, FILIPPUCCI E, BUSILACCHI P: Musculoskeletal ultrasound. *Best Pract Res Clin Rheumatol* 2004; 18: 813-26.
- NAREDO E, GAMERO F, BONILLA G, USON J, CARMONA L, LAFFON A: Ultrasonographic assessment of inflammatory activity in rheumatoid arthritis: comparison of extended versus reduced joint evaluation. *Clin Exp Rheumatol* 2005; 23: 881-4.
- D'AGOSTINO MA, CONAGHAN P, LE BARS M, BARON G, GRASSI W, MARTIN-MOLA E *et al.*: EULAR report on the use of ultrasonography in painful knee osteoarthritis. Part 1: Prevalence of inflammation in osteoarthritis. *Ann Rheum Dis* 2005; 64: 1703-9.
- CONAGHAN P, D'AGOSTINO MA, RAVAUD P, BARON G, LE BARS M, GRASSI W *et al.*: EULAR report on the use of ultrasonography in painful knee osteoarthritis. Part 2: Exploring decision rules for clinical utility. *Ann Rheum Dis* 2005; 64: 1710-4.
- KANE D, BALINT PV, STURROCK RD: Ultrasonography is superior to clinical examination in the detection and localization of knee joint effusion in rheumatoid arthritis. *J Rheumatol* 2003; 30: 966-71.
- SALAFFI F, CAROTTI M, MANGANELLI P, FILIPPUCCI E, GIUSEPPETTI GM, GRASSI W: Contrast-enhanced power Doppler sonography of knee synovitis in rheumatoid arthritis: assessment of therapeutic response. *Clin Rheumatol* 2004; 23: 285-90.
- FIOCCO U, COZZI L, RUBALTELLI L, RIGON C, DE CANDIA A, TREGNAGHIA *et al.*: Long-term sonographic follow-up of rheumatoid and psoriatic proliferative knee joint synovitis. *Br J Rheumatol* 1996; 35: 155-63.
- KARIM Z, WAKEFIELD RJ, QUINN PG *et al.*: Validation and reproducibility of ultrasonography in the detection of synovitis in the knee. A comparison with arthroscopic and clinical examination. *Arthritis Rheum* 2004; 2: 387-94.
- WALTHER M, HARMS H, KRENN V, RADKE S, FAENDRICH TP, GOHLKE F: Correlation of power Doppler sonography (PDS) in the diagnosis of synovial hypertrophy of the knee joint by verifying and comparing the PDS findings with histopathologic findings of synovial membrane vascularity. *Arthritis Rheum* 2001; 44: 331-8.
- SCHMIDT WA, VOLKER L, ZACHER J, SCHLAFKE M, RUHNKE M, GROMNICA-IHLE E: Colour Doppler ultrasonography to detect pannus in knee joint synovitis. *Clin Exp Rheumatol* 2000; 18: 439-44.
- RUBALTELLI L, FIOCCO U, COZZI L: Prospective sonographic evaluation of proliferative knee joint synovitis. *J Ultrasound Med* 1992; 13: 855-62.
- KRISTOFFERSEN H, TORP-PEDERSEN S, TERSLEV L *et al.*: Indications of inflammation visualized by ultrasound in osteoarthritis of the knee. *Acta Radiol* 2006; 47: 281-6.
- GRASSI W, FILIPPUCCI E, FARINA A: Ultrasonography in osteoarthritis. *Semin Arthritis Rheum* 2005; 34: 19-23.
- GRASSI W, LAMANNA G, CERVINI C: Sonographic imaging of normal and osteoarthritic cartilage. *Semin Arthritis Rheum* 1999; 28: 398-403.
- NAREDO E, CABERO F, PALOP MJ, COLLADO P, CRUZ A, CRESPO M: Ultrasonographic findings in knee osteoarthritis: a comparative study with clinical and radiographic assessment. *Osteoarthritis Cartilage* 2005; 13: 568-74.
- IAGNOCCO A, COARI G, ZOPPINI A: Sonographic evaluation of femoral condylar cartilage in osteoarthritis and rheumatoid arthritis. *Scand J Rheumatol* 1992; 21: 201-3.
- AISEN AM, MCCUNE WJ, MACGUIRE A *et al.*: Sonographic study of the cartilage of the knee. *Radiology* 1984; 153: 781-4.
- MCCUNE WJ, DEDRICK DK, AISEN AM, MACGUIRE A: Sonographic evaluation of osteoarthritic femoral condylar cartilage. Correlation with operative findings. *Clin Orthop* 1990; 254: 230-5.
- TARHAN S, UNLU Z: Magnetic resonance imaging and ultrasonographic evaluation of the patients with knee osteoarthritis: a comparative study. *Clin Rheumatol* 2003; 22: 181-8.
- ADLER RS, DEDRICK DK, LAING TJ *et al.*: Quantitative assessment of cartilage surface roughness in osteoarthritis using high frequency ultrasound. *Ultrasound Med Biol* 1992; 18: 51-8.
- MARTINO F, ETTORRE GC, ANGELELLI G *et al.*: Validity of echographic evaluation of cartilage in gonarthrosis. Preliminary report. *Clin Rheumatol* 1993; 12: 178-83.
- CASTRIOTA-SCANDERBEG A, DE MICHELI V, SCARALE MG, BONETTI MG, CAMMISA M: Precision of sonographic measurement of articular cartilage: inter- and intraobserver analysis. *Skeletal Radiol* 1996; 25: 545-9.
- FREDIANI B, FILIPPOU G, FALSETTI P *et al.*: Diagnosis of calcium pyrophosphate dihydrate crystal deposition disease: ultrasonographic criteria proposed. *Ann Rheum Dis* 2005; 64: 638-40.
- GRASSI W, FILIPPUCCI E, CAROTTI M, SALAFFI F: Imaging modalities for identifying the origin of regional musculoskeletal pain. *Best Pract Res Clin Rheumatol* 2003; 17: 17-32.
- BACKHAUS M, BURMESTER G-R, GERBER T *et al.*: Guidelines for musculoskeletal ultrasound in rheumatology. *Ann Rheum Dis* 2001; 60: 641-9.
- GRASSI W, FILIPPUCCI E, FARINA A, CERVINI C: Sonographic imaging of tendons. *Arthritis Rheum* 2000; 43: 969-76.
- MARTINOLI C, BIANCHI S, DERCHI LE: Tendon and nerve sonography. *Radiol Clin North Am* 1999; 37: 691-711.
- FILIPPUCCI E, IAGNOCCO A, MEENAGH G, RIENTE L, DELLE SEDIE A, BOMBARDIERI S, VALESINI G, GRASSI W: Ultrasound imaging for the rheumatologist. *Clin Exp Rheumatol* 2006; 24: 1-5.
- GISSLEN K, GYULAI C, SODERMAN K, ALFREDSON H: High prevalence of jumper's knee and sonographic changes in Swedish elite junior volleyball players compared to matched controls. *Br J Sports Med* 2005; 39: 298-301.
- TERSLEV L, QVISTGAARD E, TORP-PEDERSEN S, LAETGAARD J, DANNESKIOLD-SAMSOE B, BLIDDAL H: Ultrasound and Power Doppler findings in jumper's knee - preliminary observations. *Eur J Ultrasound* 2001; 13: 183-9.
- KHAN KM, BONAR F, DESMOND PM *et al.*: Patellar tendinosis (jumper's knee): findings at histopathologic examination, US, and MR imaging. Victorian Institute of Sport Tendon Study Group. *Radiology* 1996; 200: 821-7.
- BLANKSTEIN A, COHEN I, HEIM M *et al.*: Ultrasonography as a diagnostic modality in Osgood-Schlatter disease. A clinical study and review of the literature. *Arch Orthop Trauma Surg* 2001; 121: 536-9.
- WAKEFIELD RJ, BALINT PV, SZKUDLAREK M *et al.*: OMERACT 7 Special Interest Group. Musculoskeletal ultrasound including definitions for ultrasonographic pathology. *J Rheumatol* 2005; 32: 2485-7.