

IRIS A_{per}TO



UNIVERSITÀ
DEGLI STUDI
DI TORINO

This is the author's final version of the contribution published as:

Gaita, Fiorenzo; Guerra, Peter G; Battaglia, Alberto; Anselmino, Matteo. The dream of near-zero X-rays ablation comes true. *EUROPEAN HEART JOURNAL*. 37 (36) pp: 2749-2755.
DOI: 10.1093/eurheartj/ehw223

The publisher's version is available at:

<http://eurheartj.oxfordjournals.org/lookup/doi/10.1093/eurheartj/ehw223>

When citing, please refer to the published version.

Link to this full text:

<http://hdl.handle.net/>

This full text was downloaded from iris - AperTO: <https://iris.unito.it/>

iris - AperTO

University of Turin's Institutional Research Information System and Open Access Institutional Repository

The dream of near-zero x-rays ablation comes true

Matteo Anselmino¹, MD PhD, Peter G. Guerra², MD,

Alberto Battaglia¹, MD, Fiorenzo Gaita¹, MD Prof.

¹Division of Cardiology, Department of Medical Sciences, "Città della Salute e della Scienza" Hospital, University of Turin, Italy

²Electrophysiology Service, Department of Medicine, Montreal Heart Institute, Université de Montréal, QC, Canada

Word count: 3598 words, 2 Tables, 3 Figures, 49 reference (1907 words)

Key words: arrhythmia ablation, fluoroscopy, radiation risk, zero fluoroscopy

Running title: near-zero x-rays ablation

Corresponding Author:

Fiorenzo Gaita, MD Professor

Cardiology Division, Department of Medical Sciences,

"Città della Salute e della Scienza" University of Turin

Corso Bramante 88, 10126 Turin, Italy

Phone: +39-0116335570 Fax: +39-0116966015

Email: fiorenzo.gaita@unito.it

Abstract:

While radiation exposure related to natural sources plays a minor role, medicine-related exposure, represents, to date, a major exposure source. Within this exposure interventional electrophysiology is a relevant contributor. Unfortunately no safe dose in radioprotection exists, the negative acute and long term effects of radiological exposure may emerge at any radiation exposure dose. For this reason patients and physicians should be aware of the risk of radiation exposure and the benefits of the imaging/procedure balanced by the required radiation exposure. Given this, performing a near to zero x-rays transcatheter ablation procedure should therefore represent an aim for all electrophysiological lab. Fortunately, the introduction of electroanatomic mapping systems, have provided the possibility to perform simple and complex electrophysiological procedures avoiding, or at least, limiting the use of radiations. The present review summarizes state of the art of feasibility and safety of the near to zero approach for the main electrophysiological procedures, highlighting the potential health benefits.

Introduction

Over the last two decades, the field of cardiac electrophysiology has undergone tremendous change and evolution. The scope of available therapies has widened considerably, and hitherto ðuntreatableö arrhythmias have become commonplace in most laboratories. More complex arrhythmia substrates such as atrial fibrillation, atypical atrial flutter, and ventricular tachycardia are no longer relegated to medical therapy, however these more extensive ablative procedures result in longer procedural times, and consequently, longer fluoroscopy times. Given that considerable evidence exists as to hazards of this exposure to both the patient and the medical personnel, developing technologies and techniques to reduce fluoroscopy use in the electrophysiology environment is crucial¹.

The advent of three-dimensional mapping and cartographic systems originally introduced to allow electrophysiologists to target more challenging arrhythmias, have also helped to reduce fluoroscopy times during complex procedures. Beyond offering three-dimensional views of the cardiac chambers, these systems provide information about activation and voltage, integration of other non-fluoroscopic imaging modalities, visualization of catheters within 3-D geometry, and lesion localization as well as catheter contact force sensing. These same technologies can be used to reduce radiation exposure in the more common ðstandardö electrophysiology procedures as well, thereby advancing our field towards the dream of near-zero radiation interventions.

Biological effects of radiation and evidence of harm.

Radiation exposure related to natural sources is relatively minimal, whereas nowadays, medicine-related exposure is considered a major exposure source². Biological effects of radiation are well known. Hydroxyl radicals created by X ray interaction with water molecules interact with the DNA causing strand breaks or base damage. In addition X-rays also ionize DNA directly. Cellular clearance and repair mechanisms limit oxidative damages to the DNA. However, when double

strand damages rather than point mutations occur, radiation related injury can be caused. In general, radiation injuries are induced by the stochastic mechanism or the deterministic effect. The stochastic mechanism represents an unpredictable, unrepaired radiation damage to the DNA of a limited, potentially single, number of viable cells. The deterministic effect, instead, occurs when a significant, predictable number of existing cells are sufficiently damaged to cause a directly observable injury. Radiological induced damage can be evident following both acute exposition (eg radiation induced skin injuries) or during long term follow up. In medicine, both radiological examinations (eg. computed tomography, and scintigraphy scans) and several interventional procedures (eg. percutaneous coronary intervention, arrhythmia ablation) can result in exposure to a significant amount of radiation. In fact, data from large sample size observational studies reported an increased malignancy rate, over a long term follow up, both for patients undergoing radiological examinations than electrophysiological procedures³. An intervention such as atrial fibrillation ablation, for example, exposes patients to a dose of around 15 mSv (ranging from 1-60 mSv), increasing the absolute lifetime risk of a fatal cancer in an adult by about 0.08% (considered on a background fatal cancer risk of about 20%)^{4,5} and this biological harm is obviously even higher within the paediatric population.^{6,7} Additionally, one must consider this exposure risk not only for the patient but also for physicians and lab personnel dealing with radiation use in their routine clinical practice. Low dose exposures are also related to biological damage⁸. It has been estimated that an interventional cardiologists presents a median radiation exposure per year equivalent to approximately 250 chest X-rays (5mSv), a two to three times higher dose compared to a typical radiologists⁹ and this has, recently been related to an increased risk of cognitive impairment and brain malignancy (in particular on the left side)^{10,11}. For these reasons, in the attempt to avoid an uncontrolled increase in radiation exposure and consequent risks, the American College of Cardiology stated that the risk of radiation exposure always needs to be balanced by the benefits of the imaging/procedure itself. Based on the following three principles: justification, optimization, and responsibility for dose limitation, all interventional laboratories should therefore mandatory be

guided by the ALARA (radiation doses As Low As Reasonably Achievable) principles¹². In the following sections, we will review systems and techniques that are already showing significant reductions in radiation exposure during interventional electrophysiology procedures.

3D mapping systems in Electrophysiology

Electrophysiological procedures were originally performed using fluoroscopic guidance to introduce and position mapping and ablation catheters within the heart. Three-dimensional mapping systems have emerged as an alternative to fluoroscopy and have become the only viable method for limiting or avoiding radiation exposure. To date, four 3-D mapping systems (Table 1) are widely used to visualize electrophysiology catheters without X-rays: EnSite NavX and Mediguide technologies (both by St. Jude Medical, St Paul, Minnesota, USA), Carto (Biosense Webster, Diamond Bar, California, USA), and Rhythmia (Boston Scientific San Jose, CA. 95134 USA). The EnSite NavX relies on three pairs of nominally orthogonal skin patches in x-y and z-axis positioned on the patient's chest. An additional patch positioned on the abdomen serves as a reference during the initial phase of catheterization while advancing the catheters up the iliofemoral venous axis. Electrodes from standard electrophysiology catheters sense the electrical signals transmitted between the surface electrode patches. The system collects electrical data from the catheters and uses this information to track or navigate their movement, construct 3D models of the chamber and create activation and voltage maps¹³. More recently the same company has improved the tools for a non fluoroscopic approach by introducing the Mediguide, technology. This system enables organ motion on established methods of 3D catheter localization (4-dimensional catheter tracking)¹⁴ providing the possibility to move catheters into previously acquired fluoroscopic loops. Pre-acquired ecg and respiration triggered biplane short sequences of conventional fluoroscopic frames allow traditional catheter and structure visualisation tracking within dynamic, virtual cardiac chamber models (4D model). The system is based on a dynamic electromagnetic field integrated

with a miniaturized single coil sensor mounted on dedicated electrophysiology catheters and a reference sensor attached to the patient's chest¹⁵. In fact, given these features, Mediguide technology, is not only dedicated to arrhythmia ablation procedures but is also useful in other procedures requiring long fluoroscopy time exposure, as cardiac resynchronization implantation¹⁶. The Carto system, in its present third generation (Carto 3), instead is based on six skin patches positioned on patient's chest and back. These patches, together with a location pad technology (with 9 coils), create a magnetic field in which catheter movements can be detected. As the catheter moves around the chamber, a multitude of such associated locations are created throughout the visited area, and stored by the system. The result is a calibrated current-based field. Advanced Catheter Location Technology combines the magnetic location technology with current based visualization data in a virtual chamber reference system built by catheter movements. As with most of the other systems, this technology offers the possibility of merging this virtual chamber with a preacquired anatomical image (e.g. magnetic resonance or computed tomography) allowing physicians to navigate catheters in an accurate representation of the patient's anatomy. Also with this system, activation mapping information, during arrhythmias or sinus rhythm, may be projected to the map with a color coded mode, useful for guiding the ablation to the origin of the arrhythmia. A further refinement has come with the recent implementation of Carto-Univu, a module permitting real-time catheter tracking superimposed on pre-recorded cine loops.

The most recently introduced mapping system, Rhythmia, is based on both magnetic and impedance localization, reaching a position accuracy of 1-2 mm. This system is based on an open architecture permitting the choice of different diagnostic catheters. However, activation and substrate mapping can be performed only with a dedicated catheter (IntellaMap Orion[®]) that has the peculiarity of being a basket, high resolution mapping catheter with 64 low-noise electrodes and 2.5 mm inter-electrode spacing. Thanks to the latter and an advanced point acquisition software and process, this system is able to generate, by automated and continuous mapping, accurate, high-resolution 3D electroanatomical maps.

Near zero fluoroscopy approach.

As discussed above, performing electrophysiological procedures with minimal radiological exposure is of paramount relevance, both for patients and physicians in order to avoid both acute and longer term radiation related injuries. The use of the aforementioned technologies to reduce radiation exposure and the state of art of feasibility and safety for the most frequently encountered electrophysiological procedures are discussed below.

Typical atrial flutter Typical atrial flutter is an atrial arrhythmia maintained by an anatomical re-entry localized in the right atrium. In this arrhythmia, the portion between the inferior vena cava (IVC) and the annulus of the tricuspid valve is the critical isthmus and the target of the percutaneous ablation procedure¹⁷. Due to the unsatisfactory success rates of antiarrhythmic drugs, to date, percutaneous ablation of typical atrial flutter represents the first line approach¹⁸. Given the relatively simple anatomic positioning of catheters to treat this arrhythmia, near zero fluoroscopy approaches for typical atrial flutter ablation have been reported for the last ten years^{19, 20, 21, 22, 23}. The clear evidence emerging is that 3D real time electroanatomic mapping system broadly reduced fluoroscopy exposure without affecting procedure safety and outcome. In a recent study by Macias et al²⁴, a zero fluoroscopy approach was attempted in all consecutive procedures of typical atrial flutter. In this series, a duo-decapolar catheter and an irrigated-tip ablation catheter were inserted via two punctures in the femoral vein and fluoroscopy was to be used only in case of challenging catheter positioning. In over 60 cases, no fluoroscopy was used for about 90% of the procedures. Even more recently Schoene et al²⁵ systematically applied Mediguide technology to 20 patients undergoing percutaneous ablation of cavo-tricuspid isthmus reporting no difference both in terms of freedom from recurrences, safety, and procedure duration while achieving a significant radiation exposure reduction.

Atrioventricular nodal re-entrant tachycardia. Atrioventricular nodal reentrant tachycardia is perhaps the most frequently encountered supraventricular tachycardia (SVT) in the electrophysiology lab. Patients afflicted by this condition are young, mostly female, and have little other cardiac conditions. Given the high success and low complication rates, transcatheter ablation is considered first line therapy in this population ²⁶. Since it may be performed in centers with differing levels of experience, fluoroscopy times for this procedure are quite variable. Further, in younger children or in women of child-bearing age, the potential for radiation exposure is non-negligible.

The previously described mapping systems have typically been utilized in more difficult arrhythmia substrates for which three-dimensional views of the heart were more useful than standard fluoroscopic views. However, Kopelman et al initially reported on the use of nonfluoroscopic mapping systems for a common AVNRT ²⁷. As would be intuitively expected, fluoroscopy times were significantly decreased when compared to conventional approach (4.2+/-1.4 vs 15.9+/-6.4 min). Importantly, this did not impact negatively on success and complication rates and total intervention times. Evidently, interest for this in the pediatric population led to similar reports confirming diminished fluoroscopy times ²⁸. The feasibility of eliminating x-ray use altogether by using a 3D mapping system was demonstrated in a relatively small pediatric study showing a 95% reduction in fluoroscopy time with 24 of 30 patients requiring no fluoroscopy whatsoever ²⁹. The near-zero radiation objective has been achieved in subsequent studies using the NavX system for all steps of the procedure instead of fluoroscopy, other than in a variety of arrhythmias, also for atrioventricular nodal reentry tachycardia ^{30, 31}.

In fact, the most recent innovation of the systems permitting real-time catheter tracking superimposed on pre-recorded cine loops, as Mediguide (St Jude Medical) (Figure 1) and Carto-Univu (Biosense Webster) have facilitated this approach also in physicians fond of traditional fluoroscopic views. These systems are proving sufficiently versatile and are permitting to reduce radiation exposure even further than conventional 3D mapping ^{32, 33}.

Atrioventricular re-entrant tachycardia. Reciprocating atrioventricular reentry tachycardia (AVRT) is a supraventricular arrhythmia maintained by the presence of an accessory pathway (Figure 2). Given the typical young age of patients involved and the high efficacy of the treatment, radiofrequency ablation is here again considered the first line option. Conversely, for the same reason, radiation exposure due to an interventional approach in these patients has been of concern. Drago et al ³⁴ reported their experience on 22 paediatric patients in whom a non-fluoroscopic approach was attempted using the Carto mapping system. In this series, ablation success rate was 95% and no complications occurred. A more recent study reported on the systematic use of a non-fluoroscopic approach in a larger cohort of 328 patients³⁵. This group consisted of 35 patients with AVRT whereas patients with left sided accessory pathway or those who needed a transeptal puncture were excluded from the study. Procedural success was achieved in 99.1% of cases and in 94.7% the procedure was completed without any fluoroscopy use at all. A wider experience has been recently reported by Scaglione et al ³⁶. In this series a total no fluoroscopic approach was used in 44 consecutive paediatric patients with planned accessory pathway ablation. Right chambers were accessed through a venous transfemoral approach while a retrograde transaortic approach was used to access mitral annulus. Only three cases of left sided accessory pathway were ablated through a patent foramen ovalis. In this experience a total of 47 accessory pathways (left sided 45%) were ablated without the use of fluoroscopic guidance. A multicentre, randomized, controlled experience has recently become available in this group of patients, dubbed the NO PARTY Trial ³⁷. It is a prospective approach of no fluoroscopy use based on a 3D mapping system and was adopted in 262 patients undergoing electrophysiological study for supraventricular tachycardia (SVT). In this experience, 72% of procedures were performed without any use of fluoroscopy. Unfortunately, in this setting, left sided accessory pathways requiring transeptal puncture were not studied. As discussed subsequently in the section on, atrial fibrillation ablation, intracardiac echography (ICE)

may eventually play a role in reducing fluoroscopy exposure during transeptal puncture³⁸, but such an approach still needs to be standardized and validated.

Ventricular tachycardia Percutaneous ablation of ventricular tachycardia (VT) has been increasingly recommended (Figure 3) but is more frequently performed in higher volume, more experienced centers. Ventricular tachycardia may be triggered by an ectopic focus or, especially in case of an underlying cardiomyopathy, by an area of slow conduction (eg. scar due to a previous myocardial ischemia) localized in the myocardial muscle mass, creating the ideal substrate for re-entry triggered arrhythmias. In any case, the ablation procedure necessitates identification of the ectopic spot and/or the critical isthmus of the arrhythmia. For both right and left sided ventricular tachycardias, 3D electroanatomic mapping systems have the potential to significantly reduce fluoroscopic exposure. In addition to this, the ability to perform substrate mapping (based on both voltage and activation maps) in sinus rhythm together with the detection of fractionated or late potentials (seen in the scar areas in underlying ischemic heart disease) holds the great advantage of identifying ablation targets without mandatory inducing and/or maintaining the clinical arrhythmia (commonly not well tolerated).³⁹ The first study looking at the feasibility of a near to zero approach was in the treatment of right ventricular outflow tract (RVOT) premature ventricular contractions (PVCs)⁴⁰ both in adults and in the pediatric population⁴¹. More recently 3D electroanatomic mapping proved feasible for treating PVCs in adult patients with complex congenital heart disease⁴². Overall it is becoming clear that, in this setting, activation mapping during ventricular arrhythmia together with substrate mapping enhance the clinical utility of 3D mapping systems beyond radiation exposure reduction. Further, left-sided ventricular tachycardias not amenable to a retrograde approach and requiring transeptal access remain, for the moment, best suited to fluoroscopic guidance.

Atrial fibrillation Atrial fibrillation (AF) is the most common arrhythmia in the adult population (particularly in older patients), and it represents the widest indication for transcatheter ablation. In fact, considering the limited efficacy of antiarrhythmic therapy, often associated with relevant side effects, percutaneous ablation has emerged in recent years as the perhaps the most promising therapeutic strategy. Two main mechanisms are involved in AF onset: triggers and perpetuation. Arrhythmia triggers are commonly localized in the pulmonary veins and this mechanism of arrhythmia is particularly relevant in young patients without underlying cardiomyopathy (and atrial remodelling) suffering paroxysmal AF. Perpetuating factors, instead, are related to atrial enlargement, tissue fibrosis and consequent shortening of atrial refractory period. This mechanism is particularly observable within patients with underlying cardiomyopathy suffering persistent or long-standing AF.

Three-dimensional real-time reconstruction systems able to evaluate instantaneous catheter positioning, respiration triggered movement and the offering the possibility of integrating radiological images are allowing users to perform pulmonary vein isolation (Figure 3) and left atrial substrate modification with minimal use of fluoroscopy⁴³, **Errore. Il segnalibro non è definito.****Errore. Il segnalibro non è definito.** In addition to non fluoroscopic mapping systems, other technologies have emerged to facilitate AF ablation: contact force technology, for example, is able to monitor and measure the tissue/catheter contact in order to avoid excessive or insufficient forces on the tip of the catheter. After a brief learning curve⁴⁴, this technology further supports manoeuvring in a zero fluoroscopy setting⁴⁵. In a multicentre study on 240 consecutive patients undergoing catheter ablation of AF, adoption of a 3D mapping system proved to significantly impact routine activity in all centres involved, achieving an average fluoroscopy time decrease from 26 ± 15 min to 16 ± 12 min ($P < 0.001$) **Errore. Il segnalibro non è definito.** More recently a prospective, randomized, blinded trial, clearly showed that the systematic use of third generation mapping systems reduced fluoroscopy exposure in patients undergoing AF ablation, without increasing procedure duration or affecting safety and short-term efficacy⁴⁶. Eventually the systematic use of electroanatomic mapping systems integrated

with preacquired imaging, in this case cardiac magnetic resonance with use of oral gadobenate dimeglumine,⁴⁷ also presents the advantage of visualizing the esophagus in relation to points of radiofrequency delivery. This anatomical correlation indeed holds the potential to limit atrio-esophageal fistulas, a rare but potentially fatal periprocedural complication of percutaneous AF ablation. As previously stated, to date, the only remaining issue that limits a complete zero fluoroscopy approach for AF ablation and other left sided arrhythmias not approachable by retrograde aortic access is the transeptal puncture. In this respect, preliminary data suggest that intracardiac ultrasound echography (ICE) may become a routine strategy to guide transeptal puncture without fluoroscopy use Errore. Il segnalibro non è definito., Errore. Il segnalibro non è definito.. A recent experience in 80 patients showed that by using a third generation mapping system, contact force technology and ICE guiding transeptal puncture, RF ablation of AF was not only feasible without fluoroscopy but also safe, without affecting procedure duration, RF application time and mid-term efficacy⁴⁸. Mansour et al⁴⁹ recently reported on the use of the equipment compatible with the Mediguide Technology in order to perform a transeptal puncture without fluoroscopy in a small population of consecutive patients. In fact, by the use of a guidewire with a magnetic sensor on the tip, the authors managed to perform the transeptal puncture with a very low fluoroscopy exposure.

Reasons for performing a fluoroscopy-free procedure

How is radiation exposure risk perceived by the patient? How many patients would decline undergoing a diagnostic imaging scan or an interventional procedure to avoid increasing their lifetime cancer risk? To date, awareness on the topic is poor. In our opinion patients need to be sensitized to radiation exposure risks. How is radiation exposure risk perceived by physicians? Unfortunately, although negative long-term effects of radiation exposure are relevant, awareness is suboptimal in physicians as well.

Though extremely simplified, to provide a significant highlight on the expected results of an increased awareness on the topic, we suggest circulating the findings of the recent NO-PARTY

Trial ³⁷ described above. This study, has reported a potential 96% reduction in the estimated risks of cancer incidence and mortality and a significant reduction in estimated years of life lost and of life affected by a zero fluoroscopy approach compared to the conventional approach. Performing a conventional ablation procedure in patients with 35 years of age will result in 1 week of life lost and 2 weeks of life affected in contrast with 5 and 12 hours, respectively by adapting a fluoroscopy-free procedure. Other compelling risk reductions are reported in Table 2.

Future perspective. Biological effects of radiation are known and in our opinion, respecting the ALARA principles should be mandatory both for health of the operators and the patients. In the last two decades, technology has significantly improved, we can currently use the systems and techniques described previously to achieve relevant radiation exposure reductions. The reviewed experiences have demonstrated that a near to zero approach is indeed feasible, without affecting safety, efficacy, and procedure duration. The medical community and patients need to become aware of this possibility to permit and support the evolution from traditional electrophysiology practices towards approaches that significantly limit the use of fluoroscopy. The only significant issue that remains is how to minimize fluoroscopy during the transeptal puncture for left-sided procedures, and achieving this could potentially nearly eliminate radiation use. Presently, the usual anatomic landmarks used to guide transeptal punctures can be identified on fluoroscopy but not by electroanatomic mapping systems. The use of other technologies such as ICE, transoesophageal echocardiography or sensor enabled guidewires are still relatively cumbersome, requiring adjunctive vascular access, deep sedation, and/or extra intravascular material. Once the transeptal needle becomes traceable in any of the available non-fluoroscopic mapping systems, a total non-fluoroscopic approach will be possible for the vast majorities of electrophysiological procedures. In conclusion, strongly motivated by evidence of feasibility and of a clear measurable cancer risk reduction, all electrophysiology laboratories should aim to significantly reduce X-ray exposure by

the judicious of available systems and technology. Meanwhile, continued technological progress is clearly showing that the dream of a complete zero fluoroscopy approach for all arrhythmias management is close at hand.

Table 1. Lifetime Attributable Risks of Cancer Mortality

Lifetime Attributable Risks of cancer mortality with 95% confidence intervals from minimal fluoroscopic approach (N=118) and conventional approach (N=113) ablations in function of age at exposure and sex

Cancer	Age	Minimal Fluoroscopic Approach		Conventional approach	
		Men	Women	Men	Women
All Cancers	15	4.1 (2.1, 7.0)	5.1 (3.3, 7.8)	150 (90, 237)	204 (144, 291)
	25	3.3 (1.5, 6.0)	4.0 (2.4, 6.2)	116 (65, 189)	151 (103, 220)
	35	3.1 (1.3, 5.7)	3.5 (2.0, 5.7)	103 (55, 172)	130 (86, 192)
	45	3.2 (1.3, 5.8)	3.5 (1.9, 5.7)	104 (54, 174)	127 (83, 188)
Breast	15		0.46 (0.33, 0.66)		20.4 (14.6, 28.9)
	25		0.28 (0.20, 0.39)		12.3 (8.7, 17.3)
	35		0.16 (0.12, 0.23)		7.3 (5.2, 10.3)
	45		0.10 (0.07, 0.14)		4.2 (3.0, 5.9)
Lungs	15	0.81 (0.38, 1.76)	1.61 (1.09, 2.35)	35 (17, 77)	71 (48, 103)
	25	0.56 (0.27, 1.22)	1.11 (0.75, 1.62)	25 (12, 54)	49 (33, 71)
	35	0.47 (0.22, 1.02)	0.92 (0.62, 1.34)	21 (10, 45)	40 (27, 59)
	45	0.46 (0.22, 1.01)	0.91 (0.61, 1.32)	20 (10, 44)	40 (27, 58)
Thyroid	15	0.0259 (0.0068, 0.0977)	0.0687 (0.0183, 0.2552)	1.14 (0.30, 4.30)	3.02 (0.81, 11.23)
	25	0.0114 (0.0030, 0.0431)	0.0301 (0.0080, 0.1117)	0.50 (0.13, 1.89)	1.32 (0.35, 4.92)
	35	0.0050 (0.0013, 0.0189)	0.0131 (0.0035, 0.0487)	0.22 (0.06, 0.83)	0.58 (0.15, 2.14)
	45	0.0022 (0.0006, 0.0082)	0.0057 (0.0015, 0.0210)	0.10 (0.03, 0.36)	0.25 (0.07, 0.93)

(number of cases in 100.000). Data From Casella M et al Europace 2015.

Table 2. Available electroanatomic mapping software

Different electroanatomic mapping software to date available to perform minimally fluoroscopic exposure procedures.

Commercial name	Ensite NavX	Mediguide Technology	Carto 3 system	Localisa	Rhythmia
Localization based system	Voltage guided field	Low powered electromagnetic field	Magnetic field	Electrical field	Magnetic and impedance field
Movement sensibility (mm)	1.4	0.5	1.0	1.4	1-2
Multipoint mapping catheter available	Yes (max 128 point)	Yes (max 10 point)	Yes (max 20 point)	No	Yes (max 64 point)
Open architecture system	Yes	No	Yes	Yes	Yes
Possibility to merge with preacquired images	Yes	No	Yes	No	No

Figure 1. Example of cryoablation of a slow pathway by the use of the Navex System (St. Jude Medical). In white hisian catheter (Supreme electrophysiology catheter CRD2 5F quadripolar St Jude Medical). In green decapolar diagnostic catheter in the coronary sinus (Inquiry steerable diagnostic catheter, 6F decapolar St Jude Medical). In blue diagnostic catheter for the right ventricle (Spike Ultra LC R Josephson curve, 6 F quadripolar, FIAB). In Yellow the ablator catheter (CrioCath Freezor Xtra 5, 8F quadripolar, Medtronic). Panel A. Right anterior oblique view (left panel) and right anterior oblique view (right panel) showing fast anatomical reconstruction of the right chambers to guide catheter positioning. Panel B. Left anterior oblique view (left panel) and left lateral view (right panel) showing cryoenergy delivery at slow pathway potential site (yellow traces).

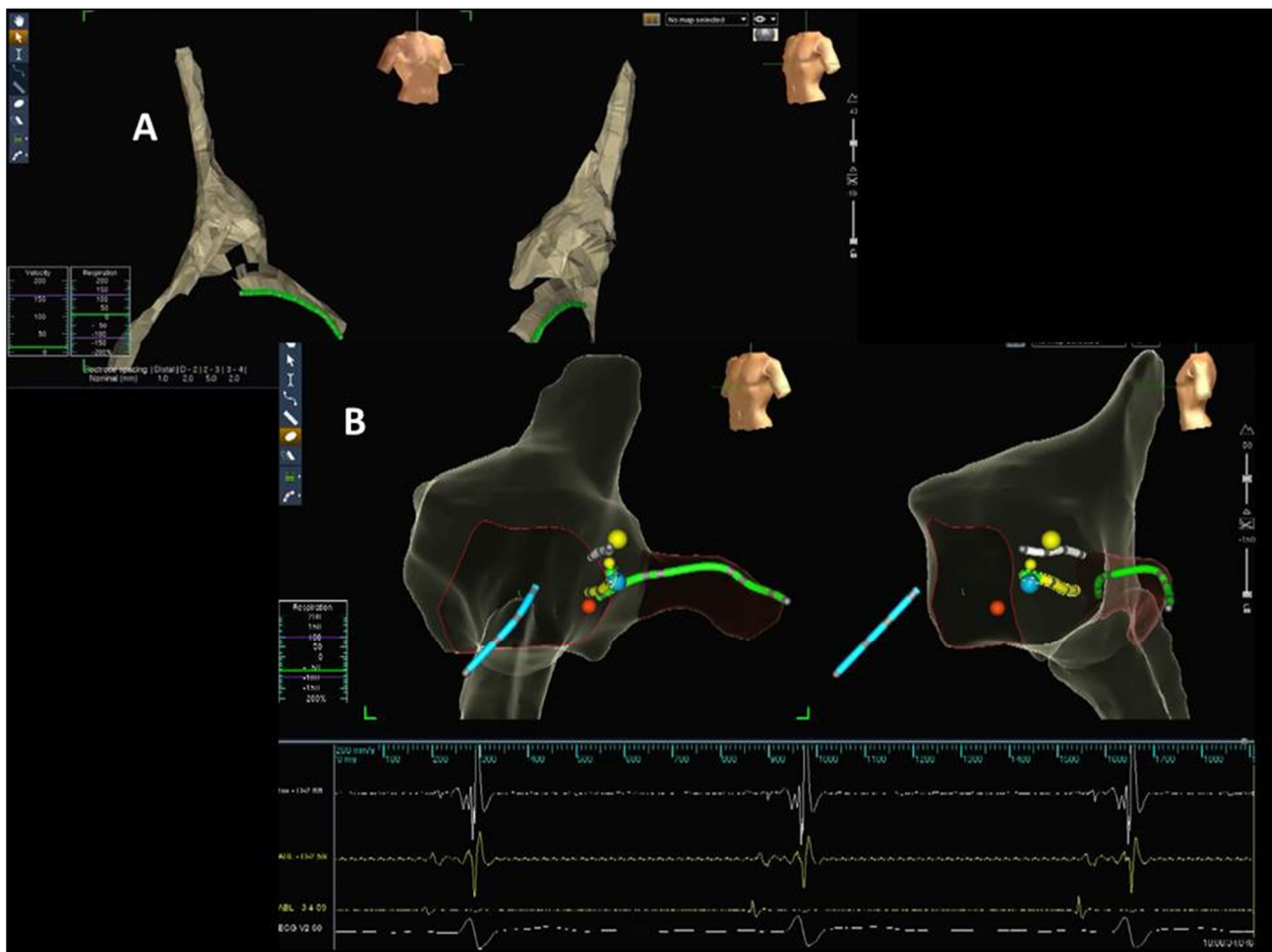


Figure 2. Example of ablation of a left sided accessory pathway using a minimal fluoroscopy approach by EnSite NavX and Mediguide systems. In white hisian catheter (Supreme electrophysiology catheter CRD2 5F quadripolar St Jude Medical). In green decapolar diagnostic catheter for coronary sinus (Inquiry steerable diagnostic catheter, 6F decapolar St Jude Medical). In blue diagnostic catheter for right ventricle (Spike Ultra LC R Josephson curve, 6 F quadripolar, FIAB). In Yellow ablator catheter (Therapy Cool Path Duo, 8F quadripolar, St Jude Medical)

Panel A. Endocavitary electrograms during ventricular stimulation showing, during the first beats, eccentric retrograde conduction with first atrium on the distal coronary sinus (CS 1,2). During Radiofrequency ablation retrograde of the accessory pathway retrograde conduction is modified and, in the last beat, eliminated. Panel B: EnSite NavX system views of the left atrium (right panel postero-anterior view, left panel left anterior oblique view) electroanatomic 3D reconstruction showing the position of the ablation catheter, the decapolar catheter in the coronary sinus and the catheter for the right ventricle. Panel C: Mediguide left anterior oblique view showing ablation catheter position (yellow) in the previously acquired fluoroscopic loop.

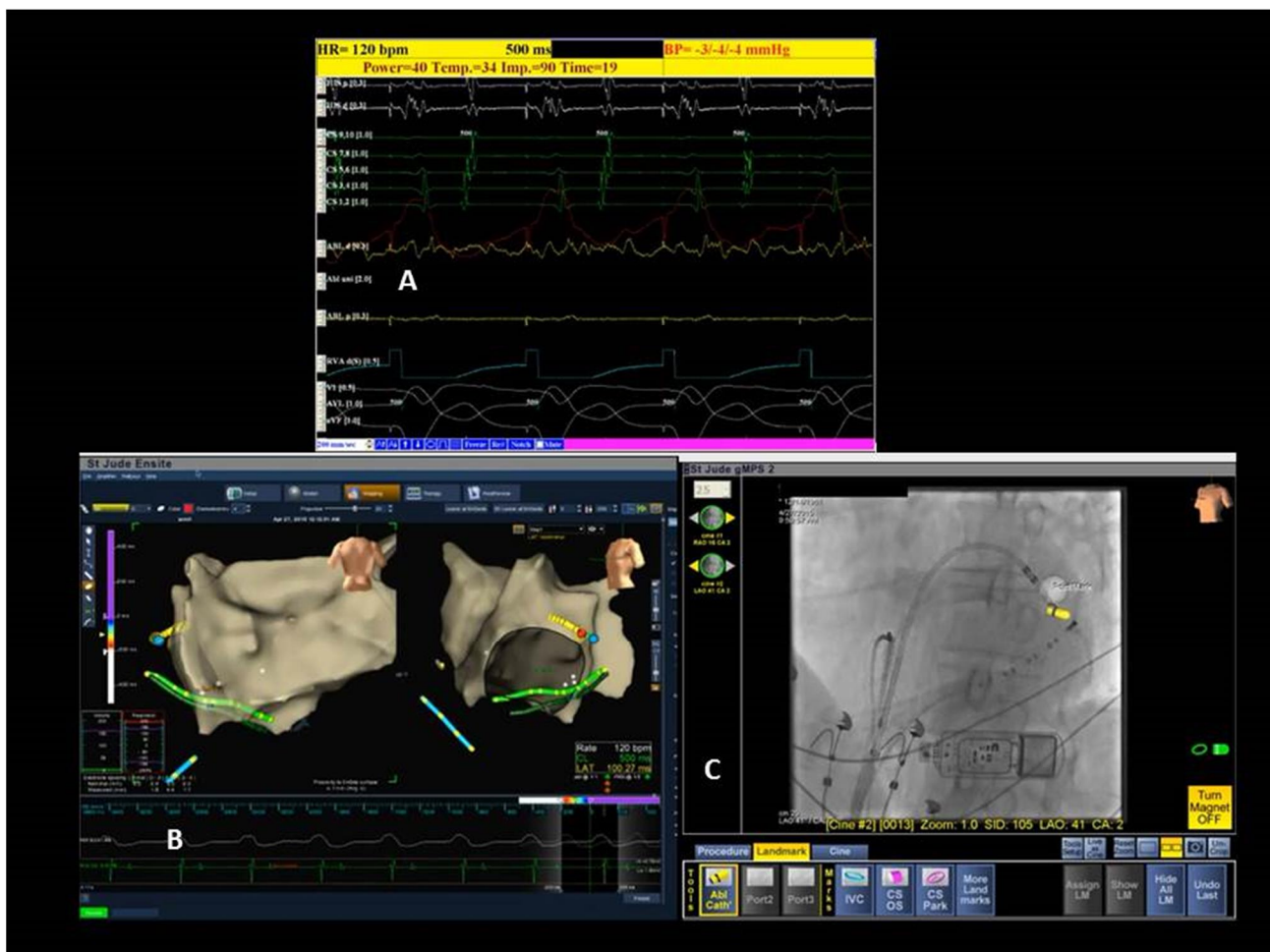

Figure 3. Example of ventricular tachycardia ablation in different clinical context. Note ablator catheter (Navistar Smart Touch curve FJ, 8 F quadripolar, Biosense Webster) Example of right ventricle outflow tract tachycardia management with a zero fluoroscopy approach (Carto 3). Panel A shows unipolar (left panel, antero-posterior view) and bipolar (right panel, posterior tricuspid anulus centred view) voltage maps simultaneously during chamber navigation. Panel B show activation mapping during tachycardia (centre panel left lateral view, right panel more posterior view), note earliest site of activation in the posterior portion of the right ventricle outflow tract with a complete negative unipolar signal on ablator traces (right panel, yellow trace on top) and sharp bipolar signal (right panel blue trace on top) preceding QRS onset on superficial ecg. Note contact force technology advising the physician of 3 gr pressure on the ventricular wall. Radiofrequency delivering on this site (red dots on centre panel) resulted in arrhythmia interruption and sinus rhythm restoration. In the lower section an example of left ventricle ventricular tachycardia in a patient with coronary artery disease managed by Carto 3 mapping system. Voltage map documented a wide scar area involving the entire apex of the left ventricle (panel C). The activation mapping during ventricular tachycardia showed earliest activation in the anterior portion of the periscar area (panel D), site of a mid-diastolic fragmented potential of 150 msec preceding QRS onset.

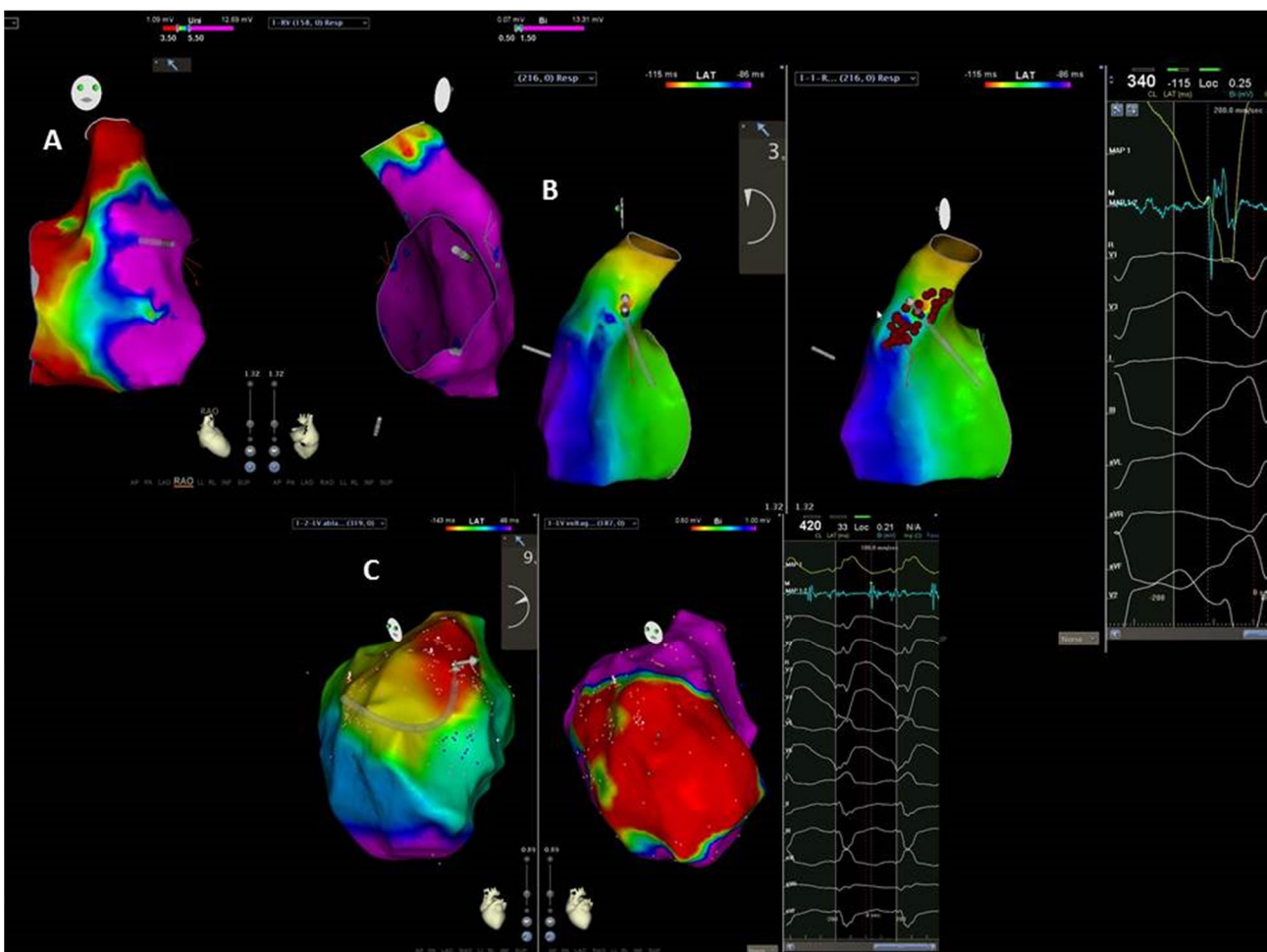
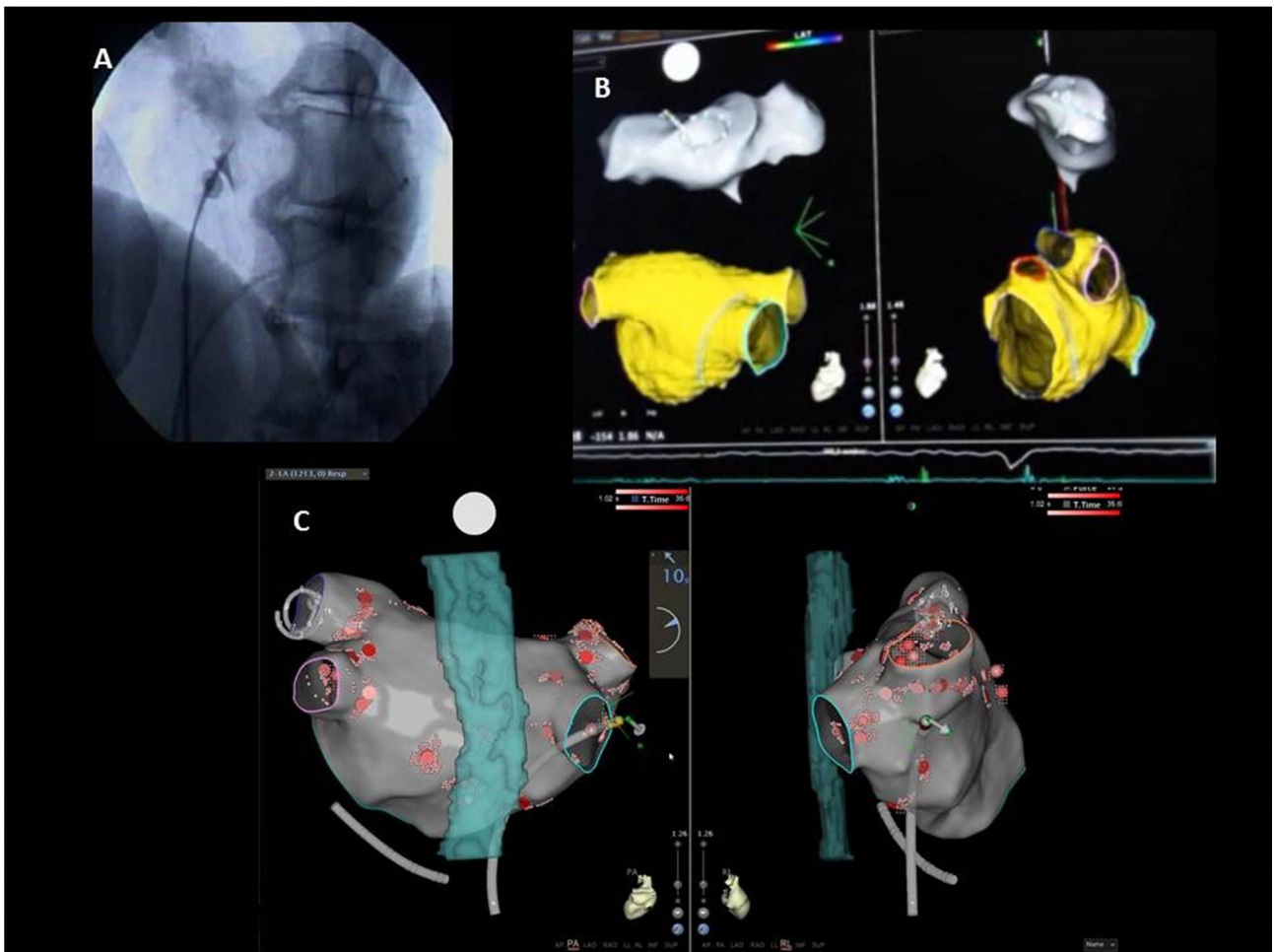


Figure 4. An Atrial Fibrillation ablation case performed by Carto 3 system. Panel A. Fluoroscopic left anterior oblique projection showing a decapolar catheter in the coronary sinus (Webster CS catheter Ez steer, 7F decapolar, Biosense Webster) and the device useful to perform transseptal access (BRKÎ Transseptal Needles and Swartz Braided Transseptal guiding introducer St Jude Medical). To date to perform transseptal access fluoroscopy is still necessary. Panel B: fast anatomic mapping (FAM, performed with Lasso Catheter, circular decapolar 7F catheter, Biosense Webster) permits to obtain, by catheter movement, a virtual electro-anatomic 3D left atrium image that is then merged to the preintervention imaging scan (in this case cardiac RMI) Panel c: postero-anterior and left lateral Carto views showing ablation points obtaining pulmonary vein isolation (ablator catheter Navistar Smart Touch FJ, 8F quadripolar, Biosense Webster), please note proximity of the posterior wall of the left atrium to the oesophagus (visualized at preintervention MR scan).



References

-
- ¹ Anselmino M, Sillano D, Casolati D, Ferraris F, Scaglione M, Gaita F. A new electrophysiology era: zero fluoroscopy. *J Cardiovasc Med (Hagerstown)*. 2013 Mar;14(3):221-7. doi: 10.2459/JCM.0b013e3283536555. Review. PubMed PMID: 22526222.
- ² Burr WW. Exposure of the U.S. Population from diagnostic medical radiation. Bethesda, MD: National Council on Radiation Protection and Measurements; 1989: Report No. 100.
- ³ Carpeggiani C, Rossi G, Landi P, Michelassi C, Brambilla M, Cortigiani L, Picano E. Long-term outcome and medical radiation exposure in patients hospitalized for cardiovascular disease. *Int J Cardiol*. 2015 Sep 15;195:30-6.
- ⁴ Heidbuchel H, Wittkampfh FH, Vano E, Ernst S, Schilling R, Picano E, Mont L; Reviewers: Jais P, de Bono J, Piorkowski C, Saad E, Femenia F; European Heart Rhythm Association. Practical ways to reduce radiation dose for patients and staff during device implantations and electrophysiological procedures. *Europace*. 2014 Jul;16(7):946-64
- ⁵ Gerber TC, Carr JJ, Arai AE, Dixon RL, Ferrari VA, Gomes AS et al. Ionizing radiation in cardiac imaging: a science advisory from the American Heart Association Committee on Cardiac Imaging of the Council on Clinical Cardiology and Committee on Cardiovascular Imaging and Intervention of the Council on Cardiovascular Radiology and Intervention. *Circulation* 2009;119:1056-65.
- ⁶ Johnson JN, Hornik CP, Li JS, Benjamin DK Jr, Yoshizumi TT, Reiman RE, Frush DP, Hill KD. Cumulative radiation exposure and cancer risk estimation in children with heart disease. *Circulation*. 2014;130:1616-17
- ⁷ Andreassi MG, Picano E. Reduction of radiation to children: our responsibility to change. *Circulation*. 2014 Jul 8;130(2):135-7.
- ⁸ Andreassi MG, Piccaluga E, Gargani L, Sabatino L, Borghini A, Fatta F, Bruno RM, Padovani R, Guagliumi G, Picano E. Subclinical carotid atherosclerosis and early vascular aging from long-term low-dose ionizing radiation exposure: a genetic, telomere, and vascular ultrasound study in cardiac catheterization laboratory staff. *JACC Cardiovasc Interv*. 2015 Apr 20;8(4):616-27.
- ⁹ Picano E, Santoro G, Vano E. Sustainability in the cardiac cath lab. *Int J Cardiovasc Imaging* 2007; 23:1436-147
- ¹⁰ Marazziti D, Tomaiuolo F, Dell'Osso L, Demi V, Campana S, Piccaluga E, Guagliumi G, Conversano C, Baroni S, Andreassi MG, Picano E. Neuropsychological Testing in Interventional Cardiology Staff after Long-Term Exposure to Ionizing Radiation. *J Int Neuropsychol Soc*. 2015 Oct;21(9):670-6.
- ¹¹ Roguin A, Goldstein J, Bar O, Goldstein JA. Brain and neck tumors among physicians performing interventional procedures. *Am J Cardiol* 2013;111:1368-72.
- ¹² Limacher M, Douglas P, Germano G, et al. Radiation safety in practice of cardiology. *J Am Coll Cardiol* 1998; 31:892-913.
- ¹³ Packer DL. Three-dimensional mapping in interventional electrophysiology: techniques and technology. *J Cardiovasc Electrophysiol*. 2005;16:1110-6.
- ¹⁴ Fenici R, Brisinda D. From 3D to 4D imaging: is that useful for interventional

cardiac electrophysiology? Conf Proc IEEE Eng Med Biol Soc.
2007;2007:599665999

¹⁵ Rolf S, Sommer P, Gaspar T, John S, Arya A, Hindricks G, Piorkowski C. Ablation of atrial fibrillation using novel 4-dimensional catheter tracking within autoregistered left atrial angiograms. *Circ Arrhythm Electrophysiol.* 2012 Aug 1;5(4):684-90. doi: 10.1161/CIRCEP.112.971705. Epub 2012 Jul 7. PubMed PMID: 22773023.

¹⁶ Richter S, Döring M, Gaspar T, John S, Rolf S, Sommer P, Hindricks G, Piorkowski C. Cardiac resynchronization therapy device implantation using a new sensor-based navigation system: results from the first human use study. *Circ Arrhythm Electrophysiol.* 2013 Oct;6(5):917-23. doi: 10.1161/CIRCEP.113.000066. Epub 2013 Sep 3. PubMed PMID: 24002003.

¹⁷ Scaglione M, Caponi D, Di Donna P, Riccardi R, Bocchiardo M, Azzaro G, Leuzzi S, Gaita F. Typical atrial flutter ablation outcome: correlation with isthmus anatomy using intracardiac echo 3D reconstruction. *Europace.* 2004 Sep;6(5):407-17. PubMed PMID: 15294265.

¹⁸ Natale A, Newby KH, Pisanó E, Leonelli F, Fanelli R, Potenza D, Beheiry S, et al. Prospective randomized comparison of antiarrhythmic therapy vs. first-line radiofrequency ablation in patient with atrial flutter. *J Am Coll Cardiol* 2000; 35:189861904.

¹⁹ Kottkamp H, Hügler B, Krauss B, Wetzel U, Fleck A, Schuler G, Hindricks G. Electromagnetic versus fluoroscopic mapping of the inferior isthmus for ablation of typical atrial flutter: A prospective randomized study. *Circulation* 2000; 102:208262086.

²⁰ Willems S, Weiss C, Ventura R, Ruppel R, Risius T, Hoffmann M, Meinertz T. Catheter ablation of atrial flutter guided by electroanatomical mapping (CARTO): A randomized comparison to conventional mapping. *J Cardiovasc Electrophysiol* 2000; 11:122361230.

²¹ Ventura R, Rostock R, Klemm HU, Lutomsky B, Demir C, Weiss C, Meinertz T, et al. Catheter ablation of common-type atrial flutter guided by three-dimensional right atrial geometry reconstruction and catheter tracking using cutaneous patches: A randomized prospective study. *J Cardiovasc Electrophysiol* 2004; 15:115761161.

²² Hindricks G, Willems S, Kautzner J, De Chillou C, Wiedemann M, Schepel S, Piorkowski C, et al. EuroFlutter Investigators: Effect of electroanatomically guided versus conventional catheter ablation of typical atrial flutter on the fluoroscopy time and resource use: A prospective randomized multicenter study. *J Cardiovasc Electrophysiol* 2009; 20:7346740.

²³ Sommer P, Wojdyla-Hordynska A, Rolf S, Gaspar T, Eitel C, Arya A, Hindricks G, et al. Initial experience in ablation of typical atrial flutter using a novel three-dimensional catheter tracking system. *Europace* 2013; 15:5786581.

²⁴ Macías R, Uribe I, Tercedor L, Jiménez-Jáimez J, Barrio T, Álvarez M. A zero-fluoroscopy approach to cavotricuspid isthmus catheter ablation: comparative analysis of two electroanatomical mapping systems. *Pacing Clin Electrophysiol.* 2014 Aug;37(8):1029-37. doi: 10.1111/pace.12376. Epub 2014 Mar 13. Erratum in: *Pacing Clin Electrophysiol.* 2015 Jul;38(7):908. Jiménez, Juan [corrected to Jiménez-Jáimez, Juan]. PubMed PMID: 24628051.

-
- 25 Schoene K, Rolf S, Schloma D, John S, Arya A, Dinov B, Richter S, Bollmann A, Hindricks G, Sommer P. Ablation of typical atrial flutter using a non-fluoroscopic catheter tracking system vs. conventional fluoroscopy--results from a prospective randomized study. *Europace*. 2015 Jul;17(7):1117-21. doi: 10.1093/europace/euu398. Epub 2015 Mar 3. PubMed PMID: 25736724
- 26 2015 ACC/AHA/HRS Guideline for the Management of Adult Patients With Supraventricular Tachycardia
- 27 Kopelman, H.A., Prater, S.P., Tondato, F., Chornos, N.A.F., Peters, N.S. Show pathway catheter ablation of atrioventricular nodal re-entrant tachycardia guided by electroanatomical mapping: a randomized comparison to the conventional approach. *Europace*. 2003;5:1716174.
- 28 PAPAGIANNIS, J., TSOUTSINOS, A., KIRVASSILIS, G., SOFIANIDOU, I., KOUSSI, T., LASKARI, C., KIAFFAS, M., APOSTOLOPOULOU, S. and RAMMOS, S. (2006), Nonfluoroscopic Catheter Navigation for Radiofrequency Catheter Ablation of Supraventricular Tachycardia in Children. *Pacing and Clinical Electrophysiology*, 29: 9716978.
- 29 Smith, G., Clark, J.M. Elimination of fluoroscopy use in a pediatric electrophysiology laboratory utilizing three-dimensional mapping. *Pacing Clin Electrophysiol*. 2007;30:5106518.
- 30 FERNÁNDEZ-GÓMEZ, J. M., MORIÑA-VÁZQUEZ, P., MORALES, E. D. R., VENEGAS-GAMERO, J., BARBA-PICHARDO, R. and CARRANZA, M. H. Exclusion of Fluoroscopy Use in Catheter Ablation Procedures: Six Years of Experience at a Single Center. *Journal of Cardiovascular Electrophysiology*, 2014;25: 6386644.
- 31 Casella M, Pelargonio G, Dello Russo A, Riva S, Bartoletti S, Santangeli P, Scarà A, Sanna T, Proietti R, Di Biase L, Gallinhouse GJ, Narducci ML, Sisto L, Bellocchi F, Natale A, Tondo C. Near-zero fluoroscopic exposure in supraventricular arrhythmia ablation using the EnSite NavX mapping system: personal experience and review of the literature. *J Interv Card Electrophysiol*. 2011 Aug;31(2):109-18.
- 32 Philipp Sommer, Christopher Piorkowski, Thomas Gaspar, Charlotte Eitel, Michael Derndorfer, Martin Martinek, Helmut Pürerfellner, Arash Arya, Gerhard Hindricks, Sascha Rolf. MediGuide in supraventricular tachycardia: initial experience from a multicentre registry. *Europace* Sep 2013, 15 (9) 1292-1297
- 33 Marian Christoph, Carsten Wunderlich, Stefanie Moebius, Mathias Forkmann, Judith Sitzy, Jozef Salmas, Julia Mayer, Yan Huo, Christopher Piorkowski, Thomas Gaspar. Fluoroscopy integrated 3D mapping significantly reduces radiation exposure during ablation for a wide spectrum of cardiac arrhythmias. *Europace* Jun 2015, 17 (6) 928-937
- 34 Drago F, Silvetti M, Di Pino A, et al. Exclusion of fluoroscopy during ablation treatment of right accessory pathway in children. *J Cardiovasc Electrophysiol* 2002; 13:7786782.
- 35 Fernández-Gómez JM, Moriña-Vázquez P, Morales Edel R, Venegas-Gamero J, Barba-Pichardo R, Carranza MH. Exclusion of fluoroscopy use in catheter ablation procedures: six years of experience at a single center. *J Cardiovasc Electrophysiol*. 2014 Jun;25(6):638-44. doi: 10.1111/jce.12385. Epub 2014 Mar 10. PubMed PMID: 24611978
- 36 Scaglione M, Ebrille E, Caponi D, Siboldi A, Bertero G, Di Donna P, Gabbarini F, Raimondo C, Di Clemente F, Ferrato P, Marasini M, Gaita F. Zero-Fluoroscopy Ablation of Accessory Pathways in Children and Adolescents: CARTO3 Electroanatomic Mapping Combined with RF and Cryoenergy. *Pacing Clin Electrophysiol*. 2015 Jun;38(6):675-81. doi: 10.1111/pace.12619. Epub 2015 Apr 15. PubMed PMID: 25727697.
- 37 Casella M, Dello Russo A, Pelargonio G, Del Greco M, Zingarini G, Piacenti M, Di Cori A, Casula V, Marini M, Pizzamiglio F, Zucchetti M, Riva S, Russo E, Narducci ML, Soldati E, Panchetti L, Startari U, Bencardino G, Perna F, Santangeli P, Di Biase L, Cichocki F, Fattore G, Bongiorno M, Picano E, Natale A, Tondo C. Near zero fluoroscopic exposure during catheter ablation of supraventricular arrhythmias: the NO-PARTY multicentre randomized trial. *Europace*. 2015 Nov 10. pii: euv344. [Epub ahead of print] PubMed PMID: 26559916.

-
- 38 Mah DY, Miyake CY, Sherwin ED, Walsh A, Anderson MJ, Western K, Abrams DJ, Alexander ME, Cecchin F, Walsh EP, Triedman JK. The use of an integrated electroanatomic mapping system and intracardiac echocardiography to reduce radiation exposure in children and young adults undergoing ablation of supraventricular tachycardia. *Europace*. 2014 Feb;16(2):277-83. doi: 10.1093/europace/eut237. Epub 2013 Aug 8. PubMed PMID: 23928735.
- 39 Komatsu Y, Daly M, Sacher F, Derval N, Pascale P, Roten L, Scherr D, Jadidi A, Ramoul K, Denis A, Jesel L, Zellerhoff S, Lim HS, Shah A, Cochet H, Hocini M, Haïssaguerre M, Jaïs P. Electrophysiologic characterization of local abnormal ventricular activities in postinfarction ventricular tachycardia with respect to their anatomic location. *Heart Rhythm*. 2013 Nov;10(11):1630-7.
- 40 Yamada T, Murakami Y, Yoshida N, Okada T, Toyama J, Yoshida Y, Tsuboi N, Muto M, Inden Y, Hirai M, Murohara T, McElderry HT, Epstein AE, Plumb VJ, Kay GN. Efficacy of electroanatomic mapping in the catheter ablation of premature ventricular contractions originating from the right ventricular outflow tract. *J Interv Card Electrophysiol*. 2007 Sep;19(3):187-94. Epub 2007 Sep 22.
- 41 Von Bergen NH, Bansal S, Gingerich J, Law IH. Nonfluoroscopic and radiation-limited ablation of ventricular arrhythmias in children and young adults: a case series. *Pediatr Cardiol* 2011; 32:7436747.
- 42 Giaccardi M, Chiodi L, Del Rosso A, Colella A. 'Zero' fluoroscopic exposure for ventricular tachycardia ablation in a patient with situs viscerum inversus totalis. *Europace*. 2012 Mar;14(3):449-50.
- 43 Ferguson JD, Helms A, Mangrum JM, Mahapatra S, Mason P, Bilchick K, McDaniel G, Wiggins D, DiMarco JP. Catheter ablation of atrial fibrillation without fluoroscopy using intracardiac echocardiography and electroanatomic mapping. *Circ Arrhythm Electrophysiol* 2009; 2: 611-619
- 44 De Ponti R. Reduction of radiation exposure in catheter ablation of atrial fibrillation: Lesson learned. *World J Cardiol*. 2015 Aug 26;7(8):442-8.
- 45 Kerst G, Weig HJ, Weretka S, Seizer P, Hofbeck M, Gawaz M, Schreieck J. Contact force-controlled zero-fluoroscopy catheter ablation of right-sided and left atrial arrhythmia substrates. *Heart Rhythm* 2012; 9: 709-714
- 46 Huo Y, Christoph M, Forkmann M, Pohl M, Mayer J, Salmas J, Sitzy J, Wunderlich C, Piorkowski C, Gaspar T. Reduction of radiation exposure during atrial fibrillation ablation using a novel fluoroscopy image integrated 3-dimensional electroanatomic mapping system: A prospective, randomized, single-blind, and controlled study. *Heart Rhythm*. 2015 Sep;12(9):1945-55. doi: 10.1016/j.hrthm.2015.05.018. Epub 2015 May 19. PubMed PMID: 26001508.
- 47 Faletti R, Rapellino A, Barisone F, Anselmino M, Ferraris F, Fonio P, Gaita F, Gandini G. Use of oral gadobenate dimeglumine to visualise the oesophagus during magnetic resonance angiography in patients with atrial fibrillation prior to catheter ablation. *J Cardiovasc Magn Reson*. 2014 Jun 13;16:41. doi: 10.1186/1532-429X-16-41. PubMed PMID: 24927953; PubMed Central PMCID: PMC4071331.
- 48 Bulava A, Hanis J, Eisenberger M. Catheter Ablation of Atrial Fibrillation Using Zero-Fluoroscopy Technique: A Randomized Trial. *Pacing Clin Electrophysiol*. 2015 Jul;38(7):797-806. doi: 10.1111/pace.12634. Epub 2015 Apr 16. PubMed PMID: 25790320.
- 49 Mansour M, Afzal MR, Gunda S, Pillarisetti J, Heist K, Acha MR, Heard M,

Ruskin J, Lakkireddy D. Feasibility of Transseptal Puncture Using a Nonfluoroscopic Catheter Tracking System. *Pacing Clin Electrophysiol.* 2015 Jul;38(7):791-6. doi: 10.1111/pace.12617. Epub 2015 Mar 27. PubMed PMID: 25712806.