

Early repolarization, an evolving concept over the last 70 years.

Luigi Biasco^{1,2},MD; Yvonne Cristoforetti¹,MD, Ole De Backer,MD², PhD; Davide Castagno¹, MD,PhD; Carla Giustetto¹,MD; Fulvio Orzan¹,MD; Fiorenzo Gaita¹,MD.

1. University of Turin, Department of Medical Science, Division of Cardiology, Città della Salute e della Scienza Hospital, Turin.
2. The heart center, Rigshospitalet, Copenhagen, Denmark.

Correspondence to:

Luigi Biasco

University of Turin, Department of Medical Science, Division of Cardiology, Città della Salute e della Scienza Hospital

C.so Bramante 88, 10126. Torino, Italy.

Phone: + 39 011 6335571

Fax: + 39 011 6336769

E-mail: luigi.biasco@gmail.com

Disclosures: none

Total word count: 3596

Key words: Early repolarization syndrome, athlete, sudden cardiac death, J point elevation.

Abstract

For more than 70 years, early repolarization has been considered as a common normal variant.

In the general population, its prevalence ranges between 5% and 13%, rising in athletes from 20 to 90%. Nevertheless, from the last half of the '90s, a growing number of case reports, series, observational and prospective studies reported that the presence of various electrocardiographic patterns attributed to early repolarization may constitute a potential marker of increased risk of sudden death in otherwise normal subjects, casting a dark shadow on this ECG peculiarity. This review provides an historical summary of the evolution of the concept of early repolarization from its original description to the latest works and a guide to help physicians in evaluating subjects with this common electrocardiographic pattern.

Introduction.

For more than 70 years since its original description in 1936[1], the electrocardiographic pattern defined as “early repolarization” (ER), “unusual RT-segment deviation”, “juvenile ST variant” or “normal RS-T segment elevation variant” has been unanimously considered as a common normal variant.

In the general population, its prevalence ranges between 5% and 13%, rising in athletes from 20 to 90% [2-4]. Nevertheless, from the last half of the '90s, a growing number of case reports, series, observational and prospective studies reported that the presence of various electrocardiographic patterns attributed to early repolarization may constitute a potential marker of increased risk of sudden death in otherwise normal subjects, casting a dark shadow on this ECG peculiarity.

Historical background

The classical definition

The first available electrocardiographic description of an ER pattern as a normal variant dates back to the work by Shipley et Hallaran [1]. These authors described the common presence in medical students and young nurses' ECGs of a terminal QRS slurring or notching defined respectively as “a momentary retardation of string movement” or “an actual change in direction of the string movement” (fig. 1A).

Early reports from the '50 to '70 utilized relatively imprecise and inconsistent definitions to describe the same ECG finding. In 1961 Wasserburger [5] defined a “normal precordial RS-T segment elevation variant” characterized by “(1) an elevated take off of the S-T segment at the J

junction of the QRS complex, varying from 1 to 4 mm... (2) a downward concavity of the S-T segment; and (3) symmetrically limbed T waves..." (fig. 1B).

In 1977, H. H. Friedman defined the early repolarization as a normal variant characterized by the presence of a notch at the transition of the QRS complex into the S-T segment, the latter with a concave upward displacement of 2 or even 3 mm in the precordial and occasionally in the peripheral leads, and tall, broad based and upright T waves [6] (fig.1C).

In 1988 Leo Schamroth used the term "early repolarization syndrome, vagotonia, the athlete's heart" to indicate a common normal pattern characterized by the presence of a thickening or slur of the terminal part of the QRS that may appear as a distinct notch or "hook" on the distal limb of the QRS complex associated with concave upward elevated S-T segment, tall and symmetrical T waves and other minor characteristics [7] (fig. 1D).

The interest towards ER was mainly oriented in differentiating this common, and possibly misleading pattern, from other conditions such as acute myocardial infarction, pericarditis, hyperkalemia, or hypothermia also characterized by a displacement of the ST segment.

Milestone works confirmed the benign nature of the ER pattern together with the characteristic features of a prevalent manifestation in male, black, young and physically active subjects [5,8,9].

Abnormal QRS-ST segment transitions as a possible marker of increased arrhythmic risk

In 1984 Otto et al. described the features of 3 young male immigrants from south east Asia with idiopathic recurrent ventricular fibrillation occurred during the early hours of the morning [10]. Their ECGs showed a broad slurring of the terminal portion of the QRS complex, that was interpreted as a possible sign of ischemia or intraventricular conduction defect. At

electrophysiological (EP) testing, rapid polymorphous ventricular tachycardia was induced, not suppressed by procainamide infusion, while oral quinidine prevented the re-induction of ventricular arrhythmias.

Some years later, Aizawa et al. published a series of 8 young Japanese patients with idiopathic ventricular fibrillation. Their ECGs were characterized by the presence of an unusual terminal QRS notching in the inferior and lateral leads. The terminal QRS notching became more marked in post extrasystolic depolarizations. This phenomenon was attributed to a bradycardia dependent intraventricular block [11] (fig.2A) .

In 1998 Garg et al. reported the case of a 18-year-old male with family history of premature sudden death, who was resuscitated after an episode of idiopathic ventricular fibrillation. At ECG an abnormal low-amplitude terminal QRS deflection (labeled for the first time as “ J wave”) in the inferior (II, III, aVF) and anterolateral leads (V3 to V6, I and aVL) (fig. 2B), that persisted on serial ECG tracings was evident. Neither intravenous procainamide nor oral atenolol could prevent the re-induction of the ventricular arrhythmias. Oral quinidine caused the disappearance of the abnormal J waves and prevented further induction of ventricular arrhythmias [12].

Kalla et al. described in 2000 the similar case of a 29-year-old Vietnamese patient resuscitated after a nocturnal episode of ventricular fibrillation [13]. The electrocardiogram recorded a prominent J wave (labeled by the author Osborn wave, like the terminal QRS slurring commonly observed during hypothermia) with ST segment elevation mainly evident in leads II, III, and aVF (fig.2C). Of note, the authors described dynamic changes of the ECG pattern observed at serial monitoring during hospitalization. The authors interpreted this electrocardiographic pattern as a Brugada syndrome variant.

In the same year Takagi et al. reported two cases of nocturnal idiopathic ventricular fibrillation and one case of nocturnal syncope with inducible ventricular fibrillation in otherwise healthy young men. The ECGs were characterized by a terminal slurring of the QRS complex (labeled J wave) in the inferior leads (fig. 2D) [14]. A 24-hour ECG recording revealed infrequent or no PVCs in all three patients. Intravenous disopyramide increased ST segment elevation in the inferior leads while treadmill testing caused the ST segment elevation to decrease or disappear at peak exercise. Also in this paper, the similarities with the clinical and the dynamic electrocardiographic presentation of Brugada syndrome were highlighted.

All these early reports have some aspects in common:

- (1) all those patients had idiopathic ventricular fibrillation with structurally normal heart, but at ECG an abnormal transition between the QRS complex and the ST segment was evident, variously labeled by the authors;
- (2) similarities with other entities characterized by an abnormal QRS-ST transition such as the Brugada syndrome or the hypothermic Osborn wave are underscored;
- (3) no relation proposed between the described electrocardiographic abnormalities and the classical ER pattern.

In 2000 Gussak and Antzelevitch analyzed the similarities between the ER and the Brugada ECG pattern not only from a clinical but also from an electrophysiological point of view [15]. The mechanism proposed for the J point and S-T segment elevation in both syndromes, derived from studies in hypothermic canine models with Osborn wave, is an I_{to} -mediated loss or reduction of the transmembrane voltage gradient during phase 2 of the myocardial action potential, leading to a transmural voltage gradient between the epicardial and endocardial layers. Since this could be a

substrate for phase 2 reentry, the authors proposed the hypothetical possibility that ER may not be as benign as generally believed particularly if associated with conditions characterized by an increased dispersion of refractoriness such as myocardial ischemia.

The interpretation of Gussak and Antzelevitch appeared to be contradicted by the results of a study by Klatsky et al. in 2003, where the authors reviewed the medical history and ECG recordings of 2234 subjects obtained during screening examinations from 1983 to 1985. In line with classical definitions, the presence of a S-T segment elevation >1.0 mm was required. After a follow up of 14 years the authors concluded that there was no evidence that early repolarization was associated with a greater likelihood of fatal or nonfatal cardiovascular events [16].

The redefined concept of early repolarization

In 2008 Haissaguerre et al. published a case-control retrospective study that compared the electrocardiographic characteristics of 206 patients with idiopathic ventricular fibrillation with those of 412 control healthy subjects. In this work a new definition of early repolarization was proposed representing a turning point from previous classical descriptions [17]. Haissaguerre and colleagues adopted the definition of ER as a J point elevation > 1 mm in inferior and/or lateral leads irrespective of the morphology of the ST segment that was not taken into consideration. As evident when comparing provided images, the difference between Haissaguerre's tracings (fig. 2F) and those reported by Wasserburger, Friedman and Schamroth (fig.1 B,C,D) is obvious. The prevalence of this redefined early repolarization was significantly higher in ventricular fibrillation cases versus controls (31% vs 5 % $p<0,001$). Moreover, cases showed a significantly higher J point elevation that became even more evident in concomitance of an arrhythmic event. Haissaguerre's

patients also were more frequently male, had frequent arrhythmic events in the early hours of the morning, and were protected by oral quinidine.

In the same year, Rosso et al. added to the complexity by defining the transition of the QRS –ST segment as “J point elevation or J wave” when a positive notch was evident during the terminal portion of the QRS complex (fig.3A) or “slurred” when the R wave gradually merged to the ST segment, with upright concavity without a clearly evident J point (fig. 3B) [3]. The presence of a J point elevation was confirmed to be more common in patients with idiopathic ventricular fibrillation than in young control subjects or athletes. The “J point elevation or J wave”, but not the morphology of the ST segment or the location of the J waves (anterolateral vs. inferior leads), was thus recognized as a possible marker of increased arrhythmic risk.

In 2009 Tikkanen et al. published an analysis of 10864 ECGs recorded in adult subjects at a mean age of $44,0 \pm 8,5$ years enrolled in the *Finnish Social Insurance Institution's Coronary Heart Disease Study* between 1966 and 1972 [18]. Utilizing the definition proposed by Haissaguerre [16], they reported a 5,8% prevalence of J point elevation. This work moved a step forward in the recognition of an electrocardiographic pattern associated with an increased risk of arrhythmic events. A J point elevation ≥ 2 mm in the inferior leads (recorded only in 0,3%), was associated with an increased risk of death, whether arrhythmic, from cardiac causes or from any cause. A subsequent reanalysis of this population [2] introduced the concept that not only a marked J point elevation in the inferior leads but also a horizontal/descending ST segment is associated with an increased arrhythmic risk. This finding was subsequently confirmed by Rosso et al [19].

In 2012 the group of Aizawa noted that the presence of a “pause dependency phenomenon” i.e. a striking accentuation of the J waves after a sudden prolongation of the R-R interval, originally

described in 1992 [11], could be an adjunctive electrocardiographic marker of increased arrhythmic risk, being manifest in 55,6% of ventricular fibrillation cases but not in any of the control subjects [20].

In summary, recent large scale retrospective [2,3,17,18] and prospective [21] studies have identified a particular subgroup of subjects with clinical (young, male) and ECG characteristics (a markedly anomalous transition of the QRS complex into the ST segment defined by a significant, dynamic J point elevation in the inferior leads, occasionally associated with inverted T waves), that may be at increased risk of sudden death if compared to the general population. This risk has also estimated to be 3,4/100.000 in the normal population, 11/100.000 in subjects with J point elevation and 34/100.000 in the presence of J point elevation and horizontal ST segment [3,19].

The need for a time out.

Despite the above mentioned acquisitions great uncertainties still exist.

These are mainly related to the electrocardiographic definitions and terms used to describe this pattern, to its role as a predictor of arrhythmic events in the various subgroups of the general population in terms of age, sex, and level of physical activity and to its arrhythmic potential during situations predisposing to a marked dispersion of refractoriness such as myocardial ischemia.

Electrocardiographic definitions.

As evident from the historical background section, the electrocardiographic definition of early repolarization has varied considerably. For years any deflection noted at the transition between the QRS complex and the S-T segment, independently from its morphology, has been identified as

J wave (comprising the traditional early repolarization, the Brugada ECG pattern, the slurred and prominent wave described in the reports of idiopathic ventricular fibrillation, and the Osborn wave).

Clearly, the morphology of the transition between the QRS complex and the S-T segment plays a pivotal role in the differentiation between normal and abnormal ECG patterns, but unfortunately univocal and codified terms are still unavailable.

In a commentary entitled “Inappropriate and confusing electrocardiographic terms. J wave syndrome and early repolarization” Surawicz and Macfarlane made an appeal for not using in publications the terms “J wave syndromes” and “early repolarization” until such terms were properly defined by appropriate task forces [22]. The need for a careful description of the transition between QRS complex and S-T segment in terms of J point elevation, terminal QRS abnormalities and S-T segment elevation was stressed [22].

Surawicz and Macfarlane defined the **J (junction) point** as the point of transition between the QRS complex and the S-T segment. As such it is present in every electrocardiogram. It is often situated above the baseline both in healthy individuals and in pathological conditions (e.g.: acute myocardial infarction, pericarditis). The degree of J point elevation may also vary according to sex, age, race and recording lead [23-25]. Considering the wide variability of the J point elevation in healthy subjects it is not known how elevated a normal J point can be.

The **J wave**, originally identified in hypothermic patients (Osborn wave), is a discrete slow deflection at the end of the QRS complex of uncertain genesis that is rarely encountered. In the presence of a J wave the correct identification of the J point and the evaluation of the QRS duration become challenging.

Since the beginning for the description of the transition between the QRS complex and the ST segment the terms “notched” or “slurred” have been used. Not only the morphological differentiation between these two entities is often subtle, but notched and slurred morphologies can be recorded in different leads of the same ECG tracing.

In 2004 Gussak et al. proposed the term “ λ (lambda) wave” to describe an anomalous morphology of the QRS-ST segment transition characterized by the presence of a positive QRS complex, J point elevation, descending ST segment and negative T waves in inferior and lateral leads [26,27] (fig. 2.f). The term “lambda wave” together with other proposed terms such as “terminal delta waves” - preferred by our group - points the attention to the final portion of the QRS complex that shows an enlargement and a change in the slope of the descending limb of the R wave. These terms appear as being less confusing and more informative than those currently used.

“Early repolarization” in the athletes.

The classical ER pattern appears to be the rule in the athletes, being manifest in a large percentage of the athletic population²⁻⁴. From an historical perspective, the surge of interest towards early repolarization in athletes is evident from the second half of the '60s [28-30].

Of interest, for more than forty years some characteristics associated with early repolarization, such as a male prevalence, the increased incidence in athletes of black ethnicity, the heart rate dependency of its appearance and the possible effect of an increased vagal tone as a mechanistic determinant of the pattern were almost unanimously adopted by researchers as a dogma.

The necessity of a clear discrimination between training related ECG changes and pathological findings was even more perceived in that historical setting in whom the only non-invasive imaging technique available was limited to the chest X ray.

Nonetheless nowadays, despite the significant development of imaging technique, very little is changed from what Lichtman et al. described in 1973: “routine medical evaluations of well-trained endurance athletes frequently disclose electrocardiographic abnormalities suggestive of organic heart disease. First- and second-degree atrioventricular block, altered ventricular conduction, criteria for atrial enlargement or ventricular hypertrophy, and repolarization abnormalities are commonly found. On the basis of such abnormal tracings, the athlete may be advised to refrain from his customary strenuous exertion, even though the results of physical examination are normal and there is no history suggesting cardiovascular disease.”[31].

Renewed interest in early repolarization arose in the '90s after the description of the Brugada syndrome, interest justified by substantial analogies in terms of possible overlapping electrocardiographic appearances, shared electrophysiological mechanism (i.e. an increased transmural dispersion of repolarization) as well as the modulating effects of beta blocking / antagonist drugs.

Bianco et al. in 2001 showed that a more accurate differential diagnosis between traditional ER pattern and suspected Brugada morphology was necessary only in a small percentage of top level athletes (about 8%, i.e. those with ST elevation limited to the right precordial leads with a “convex toward the top morphology”)[32].

As stated before, after the work published on NEJM by Haissaguerre et al. the introduction of a newly defined early repolarization had a groundbreaking effect causing the complete collapse of the common believe about its benign significance.

Noseworthy et al. were the first that re evaluated the problem of ER in athletes facing this new scenario. Using Haissaguerre’s definition of ER, they reported a prevalence of J point elevation of

25,1% in 879 US collegiate athletes [33]. The pattern was primarily evident in the lateral leads (V4-V6, I and aVL) rather than in the inferior leads (21,3% vs 2,5%); J point elevation was rarely ≥ 2 mm in two or more contiguous leads (2% of the population studied). An ascending elevation of the ST segment was evident almost universally (99% in lateral leads and 55% in inferior leads), while a horizontal or descending ST segment was rare (1,7%).

Another remarkable feature in athletes is that early repolarization is substantially stable: it only becomes less evident during exercise, and it disappears in case of prolonged detraining [33], while waxing and waning of the abnormalities of the QRS-ST transition have known to occur in patients with ventricular arrhythmias[11,13,14,17].

Our group recently published a retrospective analysis performed in a relatively large population of 332 elite professional football players. In this series the incidence of J point elevation was 35.6%, no cardiovascular death were observed at a long term follow up (median of median 13.3 years). At multivariable analysis the known inverse association with heart rate was confirmed while a strong signal in the direction of a potential mechanistic role of left ventricular hypertrophy was also evident [34].

The classical morphology of early repolarization has not been recognized as a marker of risk in the general population [2,3,18,19]. On the other hand the electrocardiographic features associated with an increased arrhythmic risk [2,3,18,19] (marked J point elevation, inferior leads presentation, horizontal/descending ST segment) occur very rarely in the athletes [33,34]. Thus by inference from the general population [2], from short [33] and long [34] term follow up studies the classical ER pattern in the athlete is considered a benign phenomenon. This notion is also

supported by the ESC Recommendations for Interpretation of 12 Leads ECG in the Athlete [35] and the Italian Guidelines on the eligibility to competitive sports [36].

QRS-ST segment abnormal transition as a marker of arrhythmic potential in the course of increased dispersion of refractoriness.

Most authors have approached the problem of ER as a pure electrical disorder capable *per se* of causing ventricular arrhythmias. This concept is in keeping with the absence of a structural cardiac abnormality, the young age of the patients and with some analogies with other ion channel diseases such as the Brugada syndrome. A genetic base for the “malignant” form of ER is slowly coming into better focus: a rare variant of KCNJ8 responsible for the pore forming subunit of the I_{K-ATP} channel and loss of function mutations in the $\alpha 1$, $\beta 2$ $\alpha 2\delta$ subunits of the cardiac L-type calcium channels have been reported in patients with J point elevation and malignant ventricular arrhythmias [38.39].

Besides this conventional approach that considers ER as a primary electrical disorder, recent reports add a possible and unexplored characteristic. In accordance with the hypothesis proposed by Gussak, ER itself may serve as a promoter or modulator of ventricular arrhythmias in the setting of structural heart disease and myocardial ischemia [15]. Patel et al. have shown an association between the terminal QRS notching and ventricular arrhythmias in patients with stable coronary artery disease and ICDs, suggesting that ER in the inferior leads is associated with the occurrence of ventricular tachyarrhythmias independently of left ventricular ejection fraction [39]. Rudic et al. found an increased prevalence of J point elevation in patients with ischemic ventricular fibrillation compared to a control group of patients with acute myocardial infarction and no ventricular arrhythmias (47% vs 13% $p=0.005$) [40]. This perhaps could explain why patients with J point

elevation >2 mm in the population of Tikkanen et al. had a higher mortality from the fifth decade onwards, and not earlier as a channelopathy would have implied.

A practical clinical approach to subjects with early repolarization.

Uncertainties upon Early Repolarization puzzle not only the diagnostic criteria but also management of subjects.

When assessing a subject with electrocardiographic evidence of ER, a good advice to keep in mind is to evaluate not only the electrocardiogram but to apply an holistic approach, adding all available data to complete the puzzle.

Current evidences do not support any kind of warning, limitation or treatment to healthy subjects with any kind of ER pattern.

Paradoxically, treatment of patients who survived an episode of idiopathic ventricular fibrillation and in whom the only alteration discovered with a multimodality approach is the presence of a J point elevation is somehow easier than the management of more ambiguous situations.

After an episode of successfully resuscitated idiopathic ventricular fibrillation an implantable cardioverter device is indicated. In case of arrhythmia recurrences, to reduce the number of appropriate shocks, therapy with oral quinidine has shown to be effective.

Some initial evidences in small series support the use of intravenous isoproterenol infusion in the management of patients presenting with arrhythmic storms. Adrenaline also showed to be effective in 2 patients while procainamide, lidocaine, verapamil, amiodarone, nifekalant,

dofetilide, beta-blockers, and magnesium sulfate failed to control recurrent arrhythmic episodes [41].

Forse manca un indicazione per quei pazienti che presentano un ER pattern potenzialmente maligno e hanno una sintomatologia dubbia (eg. Palpitazioni, lipotimie, sincopi inspiegate). In questi casi credo che sarebbe opportuno ricorrere a all'impianto di un loop recorder. Che ne pensate?

In conclusion, an increasing burden of evidence support the concept that the classically defined early repolarization and the presence of J point elevation/J waves are not two sides of the same coin but two distinct electrocardiographic patterns. Even if some analogies exist, important differences are recognized as markers of increased risk, such as the dynamicity, the localization of the J point elevation in the inferior leads and the association with horizontal descending ST segment or inverted T waves, markers of a diffuse abnormality of the repolarization process.

The new hypothesis that the presence of a J point elevation itself may also serve as a promoter or modulator of ventricular arrhythmias in the setting of structural heart disease and myocardial ischemia opens new and unexplored research fields.

Nonetheless, an increasing burden of evidence

support the hypothesis that early repolarization in athletes is not associated with an increased risk of sudden cardiac death and may not be as generally believed only related to an increased vagal tone, but those morphological adaptations typical of the athlete's heart such as mild ventricular hypertrophy may play a mechanistic role in the genesis of early repolarization.

Figure 1. a) ECG published by Shipley and Hallaran with terminal QRS *notching* (up) or *slurring* (down) in leads II and III (modified)¹; b) ECG pattern defined as “*normal RS-T segment elevation variant*” from Wasserburger et al. in 1961⁵; (modified); c) early repolarization pattern presented by H.H. Friedman⁶; d) “*early repolarization syndrome, vagotonia, the athlete’s heart*” ECG pattern as defined by Schamroth (modified)⁷.

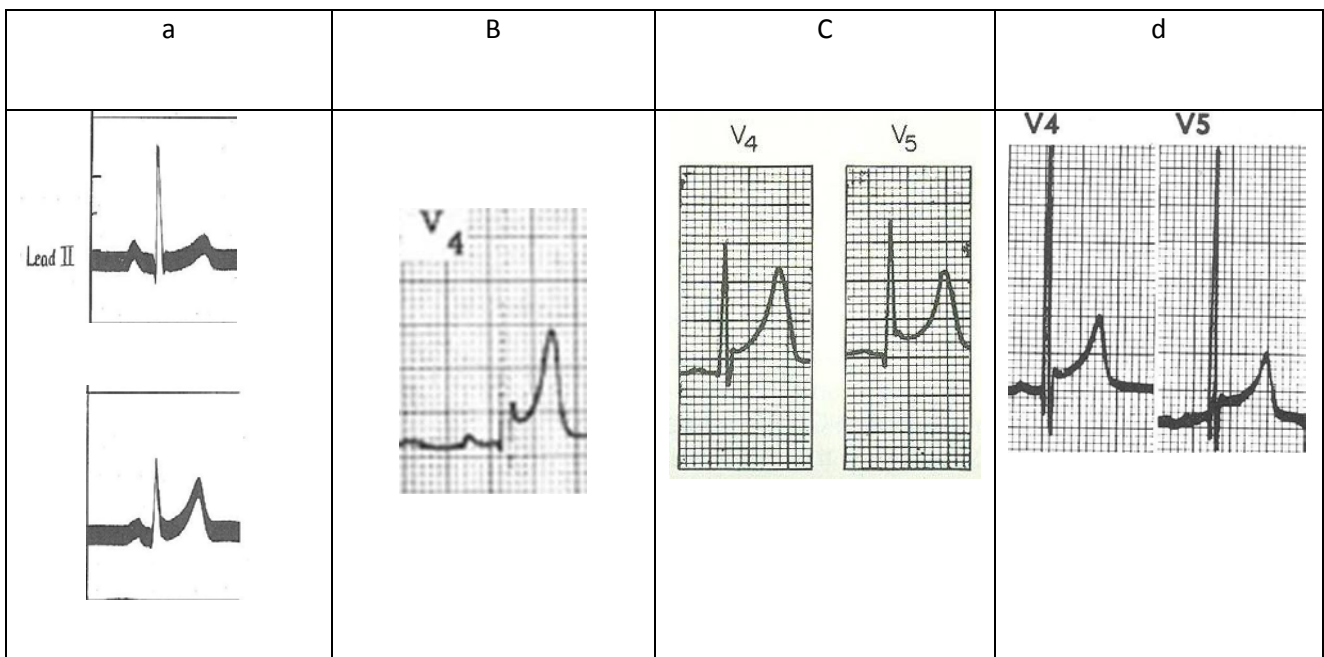


Figure 2. Morphologies of the QRS-ST transition in patients with ventricular arrhythmias as presented (modified from): a) Aizawa et al.¹¹; b) Garg et al.¹²; c) Kalla et al.¹³; d) Takagi et al.¹⁴; e) Riera et al.²⁷; f) Haissaguerre et al.¹⁷.

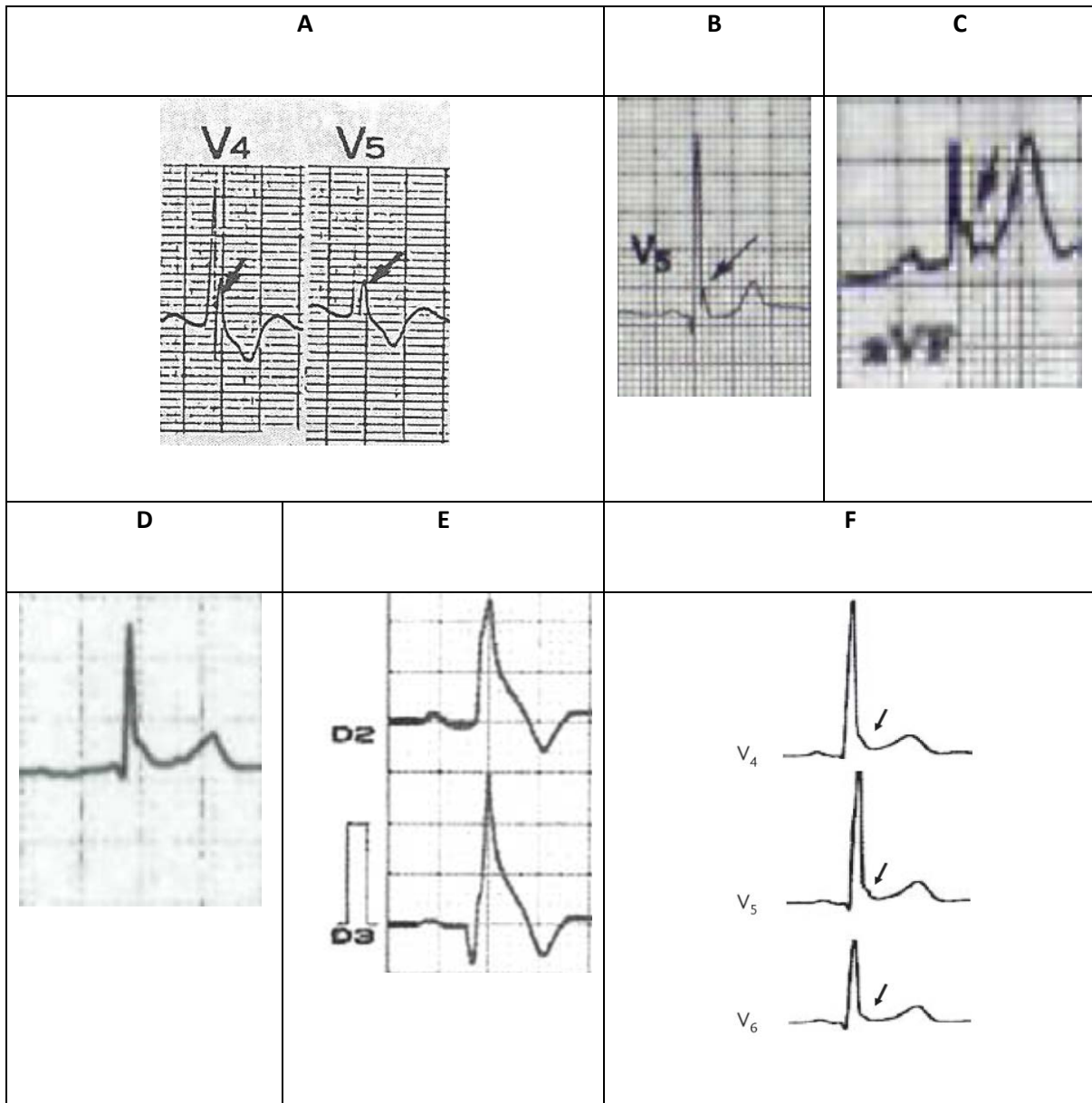
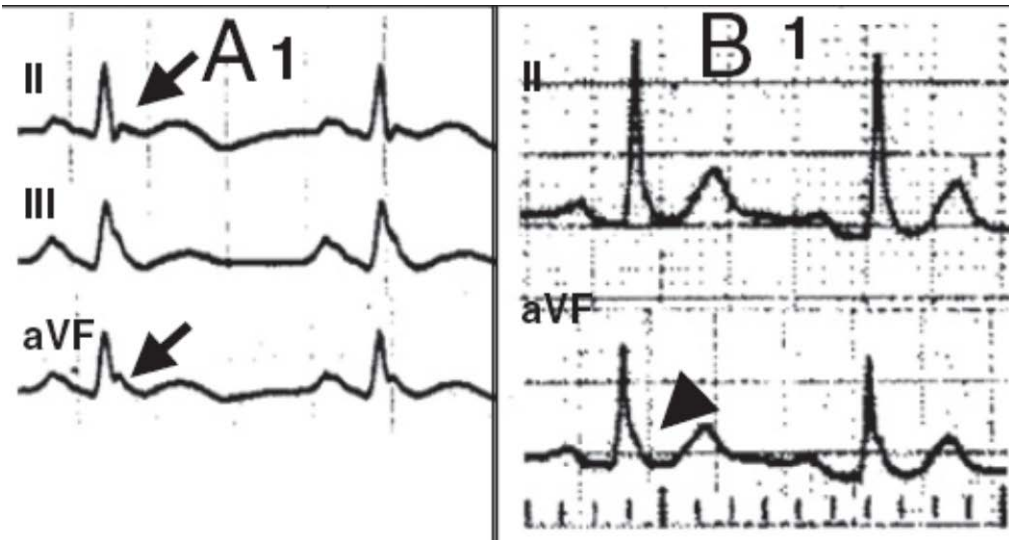


Figure 3. Morphologies of the QRS-ST transition presented (modified from) Rosso et al.³ and defined as : A) J point elevation; B) slurring.



References:

1. Shipley RA, Hallaran WR. The four-lead electrocardiogram in two hundred normal men and women. *Am Heart J* 1936; 11: 325-345.
2. Tikkanen JT, Junttila MJ, Anttonen O, et al. Early repolarization: electrocardiographic phenotypes associated with favorable long-term outcome. *Circulation* 2011; 123: 2666-2673.
3. Rosso R, Kogan E, Belhassen B, et al. J-point elevation in survivors of primary ventricular fibrillation and matched control subjects. Incidence and clinical significance. *J Am Coll Cardiol* 2008; 52: 1231-1238.
4. Bianco M, Bria S, Gianfelici A, et al. Does early repolarization in the athlete have analogies with the Brugada syndrome? *Eur Heart J* 2001; 22: 504-510.
5. Wasserburger RH, Alt WJ. The normal RS-T segment elevation variant. *Am J Cardiol* 1961; 8: 184-192.
6. Friedman HH. Diagnostic electrocardiography and vectorcardiography. 2nd ed. McGraw-Hill; 1977: 71.
7. Schamroth L. The 12 lead electrocardiogram. 2nd ed. Blackwell scientific publications; 1988: 97-99.
8. Goldman MJ. RS-T segment elevation in mid- and left precordial leads as a normal variant. *Am Heart J* 1953; 46: 817-820.
9. Grusin H. Peculiarities of the Africans electrocardiogram and changes observed in serial studies. *Circulation* 1954; 9: 860-887.
10. Otto CM, Tauxe RV, Cobb LA, et al. Ventricular fibrillation causes sudden death in southeast Asian immigrants. *Ann Intern Med* 1984; 100: 45-47.

11. Aizawa Y, Tamura M, Chinushi M, et al. Idiopathic ventricular fibrillation and bradycardia-dependent intraventricular block. *Am Heart J* 1993; 126: 1473-1474.
12. Garg A, Finneran W, Feld GK. Familial sudden cardiac death associated with terminal QRS abnormality on surface 12-lead electrocardiogram in the index case. *J Cardiovasc Electrophysiol* 1998; 9: 642-647.
13. Kalla H, Yan GX, Marinchak R. Ventricular fibrillation in a patient with prominent J (Osborn) waves and ST-segment elevation in the inferior electrocardiographic leads: a Brugada syndrome variant? *J Cardiovasc Electrophysiol* 2000; 11: 95-98.
14. Takagi M, Aihara N, Takaki H, et al. Clinical characteristics of patients with spontaneous or inducible ventricular fibrillation without apparent heart disease presenting with J wave and ST-segment elevation in inferior leads. *J Cardiovasc Electrophysiol* 2000; 11: 844-848.
15. Gussak I, Antzelevitch C. Early repolarization syndrome: clinical characteristics and possible cellular ionic mechanisms. *J Electrocardiol* 2000; 33: 299-309.
16. Klatsky AL, Oehm R, Cooper RA, et al. The early repolarization normal variant electrocardiogram: correlates and consequences. *Am J Med* 2003; 115: 171-177.
17. Haïssaguerre M, Derval N, Sacher F, et al. Sudden cardiac arrest associated with early repolarization. *N Engl J Med* 2008; 358: 2016-2023.
18. Tikkanen JT, Anttonen O, Junttila MJ, et al. Long term outcome associated with early repolarization on electrocardiography. *N Eng J Med* 2009; 361: 2529-2537.
19. Rosso R, Glikson E, Belhassen B et al. Distinguishing “benign” from “malignant early repolarization”: the value of the ST-segment morphology. *Heart Rhythm* 2012; 9: 225-229.

20. Aizawa Y, Sato A, Watanabe H, et al. Dynamicity of the J-wave in idiopathic ventricular fibrillation with a special reference to pause-dependent augmentation of the J-wave. *J Am Coll Cardiol* 2012; 59: 1948-1953.
21. Sinner MF, Reinhard W, Müller M, et al. Association of early repolarization pattern on ECG with risk of cardiac and all-cause mortality: a population-based prospective cohort study (MONICA/KORA) *PLoS Med* 2010; 27: 7: e1000314
22. Surawicz B, Macfarlane PW. Inappropriate and confusing electrocardiographic terms: J-wave syndromes and early repolarization. *J Am Coll Cardiol* 2011; 57: 1584-1586.
23. Bazett HA. An analysis of the time relation of the electrocardiogram. *Heart* 1920; 7: 353-370.
24. Macfarlane PW. Age, Sex and the ST amplitude in health and disease. *J Electrocardiol* 2001; 34: 235-241.
25. Macfarlane PW, Clark E, Devine B, et al. Normal limits of the ECG in African blacks (abstr). *J Electrocardiol* 2010; 43: 643.
26. Gussak I, Bjerregaard P, Kostis J. Electrocardiographic "lambda" wave and primary idiopathic cardiac asystole: a new clinical syndrome? *J Electrocardiol* 2004; 37: 105-107.
27. Riera AR, Ferreira C, Schapachnik E et al. Brugada syndrome with atypical ECG: downsloping ST-segment elevation in inferior leads. *J Electrocardiol* 2004; 37: 101-104.
28. Nakamoto K. Electrocardiograms of 25 marathon runners before and after 100 meter dash. *Jpn Circ J* 1969;33:105–26.

29. Gibbons L, Cooper K, Martin R, et al. Medical examination and electrocardiographic analysis of elite distance runners. *Ann N Y Acad Sci* 1977;301:283–96.
30. Venerando A, Rulli V. Frequency Morphology and meaning of the electrocardiographic anomalies found in olympic marathon runners and walkers. *J Sports Med Phys Fitness* 1964; 50:135-41.
31. Lichtman J, O'Rourke RA, Klein A, Karliner JS. Electrocardiogram of the athlete. Alterations simulating those of organic heart disease. *Arch Intern Med.* 1973; 132: 763-70.
32. Bianco M, Bria S, Gianfelici A et al. Does early repolarization in the athlete have analogies with the Brugada syndrome? *Eur Heart J.* 2001; 22: 504-10.
33. Noseworthy PA, Weiner R, Kim J, et al. Early repolarization pattern in competitive athletes: clinical correlates and the effects of exercise training. *Circ Arrhythm Electrophysiol* 2011; 4: 432-440.
34. Biasco L, Cristoforetti Y, Castagno D, et al. Clinical, electrocardiographic, echocardiographic characteristics and long-term follow-up of elite soccer players with J-point elevation. *Circ Arrhythm Electrophysiol.* 2013;6:1178-84.
35. Corrado D, Pelliccia A, Heidbuchel H, et al. Recommendations for interpretation of 12-lead electrocardiogram in the athlete. *Eur Heart J* 2010; 31: 243-259.
36. Corrado D, Pelliccia A, Heidbuchel H. Lo screening cardiologico dell'atleta. *Medicina dello Sport* 2010; 63: 15-24.

37. Haïssaguerre M, Chatel S, Sacher F, et al. Ventricular fibrillation with prominent early repolarization associated with a rare variant of KCNJ8/ K_{ATP} channel. *J Cardiovasc Electrophysiol* 2009; 20: 93-98.
38. Burashnikov E, Pfeiffer R, Barajas-Martinez H, et al. Mutations in the cardiac L-type calcium channel associated with inherited J-wave syndromes and sudden cardiac death. *Heart Rhythm* 2010; 7: 1872-1882.
39. Patel RB, Ng J, Reddy V, Chokshi M, et al. Early repolarization associated with ventricular arrhythmias in patients with chronic coronary artery disease. *Circ Arrhythm Electrophysiol* 2010; 3: 489-495.
40. Rudic B, Veltmann C, Kuntz E, et al. Early repolarization pattern is associated with ventricular fibrillation in patients with acute myocardial infarction. *Heart Rhythm* 2012;9:1295-1230.
41. Aizawa Y, Chinushi M, Hasegawa K, Naiki N, Horie M, Kaneko Y, Kurabayashi M, Ito S, Imaizumi T, Aizawa Y, Takatsuki S, Joo K, Sato M, Ebe K, Hosaka Y, Haissaguerre M, Fukuda K. Electrical storm in idiopathic ventricular fibrillation is associated with early repolarization. *J Am Coll Cardiol*. 2013 ;62:1015-9.