

# Joints

## Results of meniscectomy and meniscal repair in anterior cruciate ligament reconstruction

DAVIDE DELEDDA, FEDERICA ROSSO, UMBERTO COTTINO, DAVIDE EDOARDO BONASIA, ROBERTO ROSSI

Department of Orthopedic and Traumatology, H. Umberto I, Torino, Italy

### Abstract

Meniscal tears are commonly associated with anterior cruciate ligament (ACL) injuries. A deficient medial meniscus results in knee instability and could lead to higher stress forces on the ACL reconstruction. Comparison of results in meniscectomy and meniscal repairs revealed worse clinical outcomes in meniscectomy, but higher re-operation rates in meniscal repairs. Our aim was to review the results of ACL reconstruction associated with meniscectomy or meniscal repair.

**Keywords:** anterior cruciate ligament reconstruction, cartilage, meniscectomy, meniscal repair, osteoarthritis.

### Introduction

The role of anterior cruciate ligament (ACL) rupture in the development of knee osteoarthritis (OA) is still debated (1-3). Many studies have analyzed and compared the natural history of “ACL-deficient” knees compared to ACL reconstructions. In a recent review, no statistical difference in clinical outcomes and return to sports activity was found between patients who underwent ACL replacement and those who underwent only rehabilitation after an ACL rupture (4). The menisci play a fundamental role in knee OA: meniscal lesions with an intact ACL treated with meniscectomy evolved into a three- to seven-fold higher degree of radiographic OA, measured according to Ahlbäck

grade (5). However, no association has yet been demonstrated between radiographic changes and clinical symptoms (6,7).

An increased incidence of injury to the medial meniscus after ACL tears is reported in the literature (8). In the presence of chronic ACL lesions, the percentage of medial meniscus lesions may range from 90 to 98% (9). Comparison of ACL ruptures only and ACL ruptures associated with meniscal tears revealed a higher percentage of radiographic OA in the second group, without a direct correlation with subjective symptoms (4). A deficient medial meniscus may contribute to ACL failure and lead to OA and general weakness of the knee (10). Different studies demonstrated that medial meniscectomy results in knee instability (11), and could lead to higher stress forces on the ACL reconstruction, especially if we consider the anterior-posterior (AP) translation of the joint (12).

Comparison of the results of meniscectomy and meniscal repairs revealed a statistical difference: various studies reported worse clinical outcomes, as evaluated by the International Knee Documentation Committee (IKDC) rating system, in meniscectomy, but a higher reoperation rate with meniscal repairs (13). The aim of this paper is to review the results of ACL reconstruction associated with meniscectomy or meniscal repair.

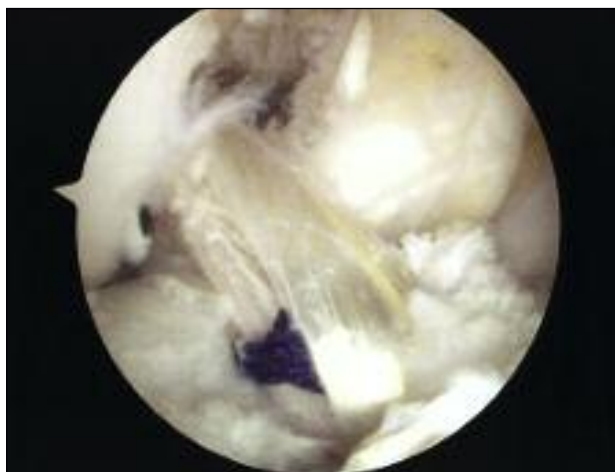
### ACL replacement and post-traumatic osteoarthritis

ACL lesions are responsible for knee radiographic changes and joint narrowing at long-term evaluations (3, 14, 15). Although the natural history of an ACL-deficient knee cannot be defined with precision, it is known that an ACL tear can induce knee degenerative changes over time. The long-term prevalence of

### Corresponding Author:

Davide Deledda, MD  
Department of Orthopedic and Traumatology,  
H. Umberto I  
Via Magellano 1, 10128 Torino, Italy  
E-mail: [deledda.d@libero.it](mailto:deledda.d@libero.it)

radiographic OA after ACL reconstruction has been found to range from 10 to 71% (16) (**Fig. 1**). In the literature, a 75-86% prevalence of radiographic OA is reported in patients affected by an ACL lesion and associated meniscectomy, at an average of 27 years after surgery (17). According to other Authors, the combination of ACL injury and meniscal tears can lead to a higher rate of radiographic OA (prevalence 59%) compared to ACL injury alone (prevalence of 31%) at 14 years (18). The reasons for the radiographic changes, as well as the potential protective role of ACL reconstruction, are not easy to identify. The studies reported in the literature may have different biases, due to the evaluation of different clinical scores or different radiographic projections, or differences in features of the populations considered (age, sex, activity, kind of injury, sports activity). It can be difficult to compare the prevalence of radiographic OA in ACL-reconstructed or deficient knees, as well as the percentage of protection conferred by ACL reconstruction on the progressive degeneration (19,4).



**Fig. 1.** Arthroscopic view of a replaced ACL.

## Etiological factors of post-traumatic osteoarthritis of the knee

Many factors can influence the development of post-traumatic OA in injured knees (20).

A recent study demonstrated that an inflammatory state after ACL reconstruction, involving mRNA expression and synovial response, could lead to OA in a sheep

model. The Authors investigated joint morphology and synovial mRNA expression of inflammatory and catabolic molecules 20 weeks after ACL reconstruction. Levels of mRNA expression were investigated in different cartilage samples. At the final follow-up, early OA was detected as only slight progression of post-injury damage. However, the levels of mRNA and catabolic molecules had normalized 20 weeks after surgery. The Authors hypothesized that synovial inflammatory processes begin very early after ACL reconstruction and might lead to cartilage and joint abnormalities (21). It has also been found that arthrosis could be induced by synovial alterations, but these are biochemical factors present after any injury. Obviously, any capsule or cartilage damage associated with ACL lesions is directly linked to this process (22). MRI studies demonstrated that subchondral lesions are present just after the ACL injury and they can evolve after many years (23). Since the prevalence of concomitant articular cartilage injuries after acute ACL tears is not precisely known, it is difficult to determine their association with the natural history of the joint. Brophy et al. suggested that the incidence of articular cartilage injury can be estimated at between 16 and 46% (24).

## The relationship between meniscal tears and osteoarthritis

It has been demonstrated that partial or total meniscectomy, compared to an uninjured knee, can be associated with a three- to seven-fold increased risk of radiographic changes (17). These changes are extensively described in the literature (6, 25, 26); however, cartilage damage and joint space narrowing are not usually correlated with clinical symptoms, even if signs of initial OA are visible.

Petty and Lubowitz (7) published a systematic review in order to help clarify the role of partial meniscectomy in the development of knee OA present at long-term follow-up. They selected studies, providing level I to level IV evidence, that reported either clinical outcome or radiographic OA at follow-up performed at least 8 years after partial arthroscopic meniscectomy. The studies had follow-up durations ranging between 8 and 16 years, and all showed a statistically significant incidence of radiographic OA in this population, but there was no relationship between radiographic findings and clinical symptoms (7, 27, 28).

## The role of meniscectomy in knee instability

The medial meniscus plays an important role both in knee stability and in spreading loads (29). Meniscal tears are often irreparable and they are commonly located in the posterior horn (**Figs. 2, 3**); they are generally treated with a partial meniscectomy (30). Total meniscectomy has been shown to increase AP instability of the knee (11). For this reason, surgeons prefer partial meniscectomy which gives better results with, overall, fewer stability-related complications (31). In addition, fewer radiographic changes and less joint space narrowing were demonstrated with partial



Fig. 2. Arthroscopic view of a medial meniscus posterior horn tear.

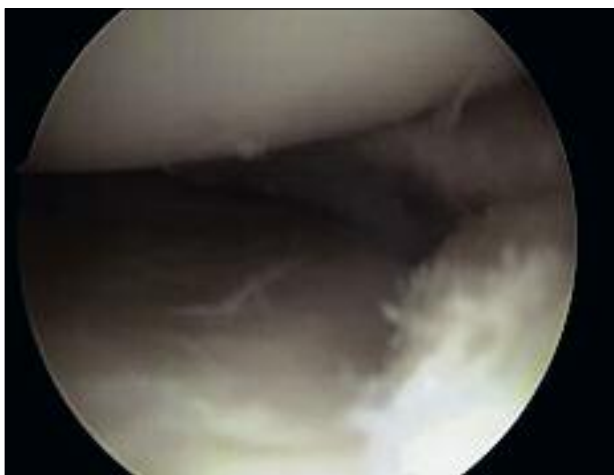


Fig. 3. Arthroscopic view of meniscectomy of the medial meniscus posterior horn.

meniscectomy compared to total meniscectomy (28). Arno et al. (32) recently published the results of an MRI study performed in five fresh human male cadaveric knees. Each knee was dissected, preserving all ligaments and the quadriceps tendon. Laxity testing was performed with different loads measured in Newtons and repeated at 15, 30, 60 and 90° of flexion. MRI was performed with intact menisci in all knees. Subsequently, an arthroscopic partial medial meniscectomy was performed. After 22% of resection, no significant differences in AP laxity were observed, but a statistically significant increase in AP laxity was observed with at least 46% of resection. After full resection, the laxity measured was similar to that found with 46% of resection. These results showed that partial medial meniscectomy in which resection exceeded 46% of the original width of the medial meniscus altered the AP stability of the medial femoral condyle and led to increased AP laxity. These mechanical changes are responsible for an abnormal cartilage load and early OA.

## How meniscectomy can influence the biomechanics of the knee

The role of the meniscus and its importance in joint stabilization and load transmission in normal and ACL-deficient knees is well established (29, 33). Unfortunately, medial meniscal tears of the posterior horn are common, and in 10-30% of cases they are associated with ACL tears. As already pointed out by others, the posterior horn, being difficult to repair, is more often removed than repaired (30).

Papageorgiou et al. (12) tried to establish the biomechanical relationship between the ACL graft and the medial meniscus. Using a robotic sensor testing system, they examined 10 human cadaveric knees, measuring the kinematics of the knee and the forces on the ACL, the ACL graft and the medial meniscus in the presence of a combined anterior and compressive tibial load. Anterior tibial translation increased after ACL transection and the resultant forces on the medial meniscus were doubled. Then, after ACL reconstruction, anterior tibia translations and the forces on the medial meniscus were restored to the levels of the intact knee. Instead, after medial meniscectomy, the forces on the ACL graft increased between 33 and 50%. These results indicated that ACL grafts may be at increased risk of failure in

the absence of the medial meniscus. Thus, meniscal repair or replacement may protect the ACL graft from increasing stress forces.

Spang et al. (11) evaluated the effect of meniscectomy and meniscal allograft transplantation on the ACL and knee biomechanics of 10 human cadaveric knees.

Tibial displacement was recorded in relation to the position of the femur. The test was performed at 30, 60 and 90° of knee flexion. Six testing cycles involving application of AP loads were performed; after each cycle, a medial meniscectomy was performed and the testing cycle was repeated. Testing was performed again after a meniscal allograft transplantation. The Authors concluded that tibial displacement after meniscectomy was significantly increased at all angles. The meniscal allograft was able to restore tibial displacement to normal values at 30 and 90°. In addition, ACL tension increased after meniscectomy at 60 and 90° of flexion, and meniscal transplantation restored the strain values to normality at 60 and 90°.

## Meniscectomy versus meniscal repair

Many studies have demonstrated better results with partial *versus* total meniscectomy in relation to weight transmission (34), AP stabilization of the joint (33) and proprioception (35). The percentage of meniscus removed is directly related to the development of clinical and radiographic changes in the knee joint. As previously described the meniscus exerts a protective role on the ACL reconstruction in term of stress forces. In the presence of large or irreparable meniscal lesions the most common surgical treatment is partial meniscectomy, which is kept as conservative as possible. Many techniques have been described for meniscal repair (Fig. 4), such as inside-out or outside-in suturing techniques. Devices allowing an all-inside repair have recently been marketed.

Paxton et al. (13) recently published a systematic review comparing re-operation rates and clinical outcomes after meniscal repair and partial meniscectomy surgery. The Authors demonstrated a lower long-term re-operation rate (3.9%) with partial meniscectomy compared to isolated meniscal repair (20.7%), but meniscal repairs were associated with better clinical outcomes (13).

Melton et al. (36) studied the long-term outcome of patients submitted to meniscal repair associated with ACL reconstruction. They excluded patients with pre-

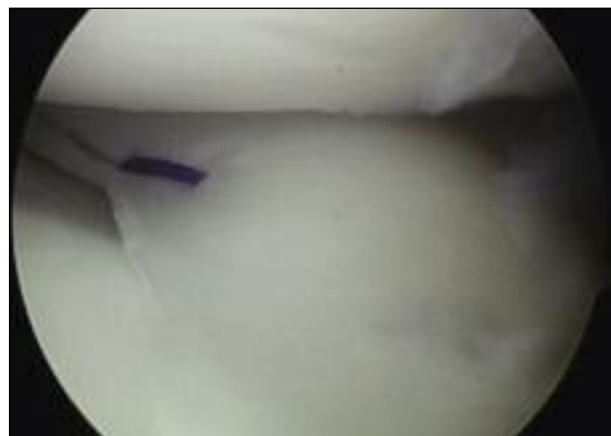

Fig. 4. Arthroscopic view of meniscal repair of the medial meniscus posterior horn.

vious ACL or meniscal pathology. The Authors divided the patients into two cohorts (selected for age and sex): the first cohort included patients who undergone combined ACL reconstruction and meniscectomy (Group M), while the second included patients who undergone ACL reconstruction with normal menisci (Group N). Clinical assessment included IKDC and Lysholm scores. Forty-four patients were evaluated with a median follow-up of 10 years (7.7-12.6). Patients undergoing ACL reconstruction and meniscal repair had a mean IKDC score of 84.2 compared with 70.5 ( $p = 0.008$ ) in the M group and 88.2 ( $p = 0.005$ ) in the N group. Among the patients with ACL reconstruction and meniscal repair, 86.2% had a Lysholm score of between 80 and 100%. The Authors concluded that good long-term outcomes can be obtained in patients after combined ACL reconstruction and meniscal repair compared to meniscectomy. In their view, it is advisable, when possible, to attempt repair of the meniscus during ACL reconstruction.

Magnussen et al. (37) performed a systematic review of the literature to identify studies publishing clinical outcomes of ACL reconstructions with follow-up durations of two years or longer. They excluded the following cases: young patients with an immature skeleton, revisions of ACL reconstructions, procedures performed using allografts or grafts different from the patellar tendon or hamstring, open procedures, and complex and multi-ligament injuries. Mini-open, arthroscopic-assisted or endoscopic techniques were used in the studies reviewed. The follow-ups ranged from 4.5 to 13 years, with an average of 8.3 years. Follow-

up X-rays were obtained in more than 60% of patients; the clinical evaluation was performed using the IKDC rating system. The analysis showed that patients who underwent partial meniscectomy associated with ACL reconstruction were more likely to develop radiographic OA than those with normal menisci at 5-10 years of follow-up. The authors described no differences between patients who underwent a meniscal repair compared to those with normal menisci.

Another interesting correlation between partial meniscectomy and the development of cartilage injuries was reported in a study by Brophy et al. (24) in 2010. The authors concluded that in patients undergoing revision of ACL reconstruction, those who had previously undergone a partial meniscectomy had a higher rate of chondral lesions, whereas this association was not demonstrated in cases in which a meniscal repair was performed. The patients included in this study were candidates for revision ACL reconstructions, due to instability, laxity testing or imaging indicating ACL tears. Patients were asked to complete a series of questionnaires and the surgeons documented the clinical history, and recorded failure mechanisms, type of ACL reconstruction, and associated injuries such as meniscal tears or chondral lesions. The final cohort included 725 patients undergoing ACL revision. The results showed a direct correlation between the status of articular cartilage at the time of revision ACL and outcome; partial meniscectomy was related to the development of OA, while meniscal repair was not. Another important result was the association between partial meniscectomy and OA signs in the same compartment of the joint, which provided evidence of a direct link between meniscectomy and cartilage damage. The patients with repaired menisci showed a lower rate of OA, similar to that of knees without meniscal tears. The lateral side of the knee seemed to be more susceptible to chondral damage after partial meniscectomy, probably due to the anatomy of the lateral femoral condyle. An intact medial meniscal repair was associated with less OA in the medial compartment. An interesting finding was the association between meniscal surgery and OA in the patellofemoral joint, probably attributable to associated injuries during the first trauma that led to ACL rupture and to a biochemical response occurring just after the lesion and after the surgical treatment. These findings suggest that, when possible, it is preferable to perform meniscal repair at the time of ACL reconstruction, but this is not applicable to all lesions, as we said before.

## Discussion

There are various aspects of ACL injuries that surgeons should bear in mind when approaching an ACL reconstruction. An ACL rupture is the start of a pathway that leads to inevitable changes in the knee. First of all, the indication for ACL reconstruction should be carefully evaluated, taking into account the patient's characteristics. In order to obtain better results the surgeon should carefully evaluate any associated injuries.

Meniscal tears are among the injuries most commonly associated with ACL tears. Meniscal tears treated with meniscectomy have been shown to evolve into a higher degree of radiographic OA, three to seven times greater than that occurring in a normal knee. Association of an ACL lesion with meniscal tears increases the prevalence of long-term radiographic OA (prevalence 59%) compared to ACL injury alone (prevalence of 31%). The precise natural history of an ACL-deficient knee is not known, but ACL tears lead to degenerative changes in the knee. This process involves many other injuries, involving the capsule, cartilage and ligaments, that can be associated with ACL lesions. In these cases an inflammatory state with catabolic molecules is responsible for cartilage damage, especially immediately after the injury. Similar biochemical modifications have been described after surgical treatment.

The medial meniscus is an important structure in the knee, involved in stabilizing the joint and spreading loads. It has been demonstrated that meniscectomy plays a role in knee instability, and some authors have suggested that it plays a role in ACL graft failure. It is also very important to consider the bi-directional relationship between the ACL and the medial meniscus; their biomechanical interdependence is involved in stabilizing the joint. It has been shown that after ACL rupture, tibial translation increases and the resultant forces on the medial meniscus are doubled. The literature reports that total meniscectomy leads to increased AP instability of the knee: the more meniscus the surgeon removes, the more joint stability is lost.

Meniscectomy exceeding 22% of the total width of the medial meniscus does not cause instability, whereas when it exceeds 46% of the total width, the resulting instability is comparable to what is observed in the absence of the meniscus. These mechanical changes are responsible for an abnormal cartilage load and early OA. Instead, after medial meniscectomy the forces in the ACL replacement graft increased between

33 and 50%. This bi-directional correlation explains why the surgeon should preserve the medial meniscus, to reduce the forces acting on the graft.

An analysis of literature comparing meniscectomy and meniscal repair showed that meniscectomy has a lower re-operation percentage in the long term, but meniscal repair is associated with better clinical outcomes. Many Authors recommend that meniscectomy should be kept as conservative as possible or that every effort should be made to repair the meniscus, when possible during ACL replacement (36), in order to reduce the risk of development of OA (37).

In conclusion, ACL rupture can lead to clinical and radiological changes in the knee, but commonly these are not directly correlated. ACL and meniscal lesions could also be involved in knee OA. The menisci contribute to stabilizing the joint, to an extent that is directly related to their dimensions. Meniscal tears are sometimes irreparable due to the site of the lesion, in particular when the damage is located in the posterior horn. The literature shows that meniscal repair gives better clinical and radiological outcomes: surgeons should, when possible, always try to suture meniscal tears in order to protect the ACL graft and obtain better long-term outcomes.

## References

1. Torg JS, Conrad W, Kalen V. Clinical diagnosis of anterior cruciate ligament instability in the athlete. *Am J Sports Med.* 1976;4:84-93.
2. Noyes FR, Mooar PA, Matthews DS, et al. The symptomatic anterior cruciate-deficient knee. Part I: the long-term functional disability in athletically active individuals. *J Bone Joint Surg Am.* 1983;65:154-162.
3. Kannus P, Järvinen M. Conservatively treated tears of the anterior cruciate ligament. Long-term results. *J Bone Joint Surg Am.* 1987;69:1007-1012.
4. Delincé P, Ghafil D. Anterior cruciate ligament tears: conservative or surgical treatment? A critical review of the literature. *Knee Surg Sports Traumatol Arthrosc.* 2012;20:48-61.
5. Ahlbäck S. Osteoarthritis of the knee. A radiographic investigation. *Acta Radiol Diagn (Stockh).* 1968; Suppl 277:7-72.
6. Roos EM, Ostenberg A, Roos H, et al. Long-term outcome of meniscectomy: symptoms, function, and performance tests in patients with or without radiographic osteoarthritis compared to matched controls. *Osteoarthritis Cartilage.* 2001;9:316-324.
7. Petty CA, Lubowitz JH. Does arthroscopic partial meniscectomy result in knee osteoarthritis? A systematic review with a minimum of 8 years' follow-up. *Arthroscopy.* 2011;27:419-424.
8. Bellabarba C, Bush-Joseph CA, Bach BR Jr. Patterns of meniscal injury in the anterior cruciate-deficient knee: A review of the literature. *Am J Orthop (Belle Mead NJ).* 1997;26:18-23.
9. Warren RF, Marshall JL. Injuries of the anterior cruciate and medial collateral ligaments of the knee: a long-term follow-up of 86 cases - part II. *Clin Orthop Relat Res.* 1978;(136):198-211.
10. Arnold JA, Coker TP, Heaton LM, et al. Natural history of anterior cruciate tears. *Am J Sports Med.* 1979;7:305-313.
11. Spang JT, Dang AB, Mazzocca A, et al. The effect of medial meniscectomy and meniscal allograft transplantation on knee and anterior cruciate ligament biomechanics. *Arthroscopy.* 2010;26:192-201.
12. Papageorgiou CD1, Gil JE, Kanamori A, et al. The biomechanical interdependence between the anterior cruciate ligament replacement graft and the medial meniscus. *Am J Sports Med.* 2001;29:226-231.
13. Paxton ES, Stock MV, Brophy RH. Meniscal repair versus partial meniscectomy: a systematic review comparing reoperation rates and clinical outcomes. *Arthroscopy.* 2011;27:1275-1288.
14. Sherman MF, Warren RF, Marshall JL, et al. A clinical and radiographical analysis of 127 anterior cruciate insufficient knees. *Clin Orthop Relat Res.* 1988;227:229-237.
15. Meunier A, Odensten M, Good L. Long-term results after primary repair or non-surgical treatment of anterior cruciate ligament rupture: a randomized study with a 15-year follow-up. *Scand J Med Sci Sports.* 2007;17:230-237.
16. Hui C, Salmon LJ, Kok A, et al. Fifteen-year outcome of endoscopic anterior cruciate ligament reconstruction with patellar tendon autograft for "isolated" anterior cruciate ligament tear. *Am J Sports Med.* 2011;39:89-98.
17. Neyret P, Donell ST, Dejour H. Results of partial meniscectomy related to the state of the anterior cruciate ligament. Review at 20 to 35 years. *J Bone Joint Surg Br.* 1993;75:36-40.
18. Von Porat A, Roos EM, Roos H. High prevalence of osteoarthritis 14 years after an anterior cruciate ligament tear in male soccer players: a study of radiographic and patient relevant outcomes. *Ann Rheum Dis.* 2004;63:269-273.
19. Øiestad BE, Engebretsen L, Storheim K, et al. Knee osteoarthritis after anterior cruciate ligament injury: a systematic review. *Am J Sports Med.* 2009;37:1434-1443.
20. Lohmander LS, Englund M, Dahl LL, et al. The longterm consequence of anterior cruciate ligament and meniscus injuries: osteoarthritis. *Am J Sports Med.* 2007;35:1756-1769.
21. Heard BJ, Solbak NM, Achari Y, et al. Changes of early post-traumatic osteoarthritis in an ovine model of simulated ACL reconstruction are associated with transient acute post-injury synovial inflammation and tissue catabolism. *Osteoarthritis Cartilage.* 2013;21:1942-1949.
22. Meyer EG, Baumer TG, Slade JM et al. Tibiofemoral contact pressures and osteochondral microtrauma during anterior cruciate ligament rupture due to excessive compressive loading and internal torque of the human knee. *Am J Sports Med.* 2008;36:1966-1977.
23. Faber KJ, Dill JR, Amendola A, et al. Occult osteochondral lesions after anterior cruciate ligament rupture. Six-year magnetic resonance imaging follow-up study. *Am J Sports Med.* 1999;27:489-494.
24. Brophy RH, Zeltser D, Wright RW, et al. Anterior cruciate ligament reconstruction and concomitant articular cartilage injury: incidence and treatment. *Arthroscopy.* 2010;26:112-120.
25. Bolano LE, Grana WA. Isolated arthroscopic partial meniscectomy. Functional radiographic evaluation at five years. *Am J Sports Med.* 1993;21:432-437.
26. Roos H, Laurén M, Adalberth T, et al. Knee osteoarthritis after meniscectomy. Prevalence of radiographic changes after

- twenty-one years, compared with matched controls. *Arthritis Rheum.* 1998;41:687- 693.
27. Hede A, Larsen E, Sandberg H. Partial versus total meniscectomy. A prospective, randomised study with long-term follow-up. *J Bone Joint Surg Br.* 1992;74:118-121.
  28. Andersson-Molina H, Karlsson H, Rockborn P. Arthroscopic partial and total meniscectomy: A long-term follow-up study with matched controls. *Arthroscopy.* 2002;18:183-189.
  29. Ahmed AM, Burke DL. In-vitro measurement of static pressure distribution in synovial joints - Part I: tibial surface of the knee. *J Biomech Eng.* 1983;105:216-225.
  30. McDermott ID, Amis AA. The consequences of meniscectomy. *J Bone Joint Surg Br.* 2006;88:1549-1556.
  31. Ihn JC, Kim SJ, Park IH. In vitro study of contact area and pressure distribution in the human knee after partial and total meniscectomy. *Int Orthop.* 1993;17:214-218.
  32. Arno S, Hadley S, Campbell KA, et al. The effect of arthroscopic partial medial meniscectomy on tibiofemoral stability. *Am J Sports Med.* 2013;41:73-79.
  33. Allen CR, Wong EK, Livesay GA, et al. Importance of the medial meniscus in the anterior cruciate ligament-deficient knee. *J Orthop Res.* 2000;18:109-115.
  34. Radin EL, de Lamotte F, Maquet P. Role of the menisci in the distribution of stress in the knee. *Clin Orthop Relat Res.* 1984;(185):290-294.
  35. Zimny ML, Albright DJ, Dabezies E. Mechanoreceptors in the human medial meniscus. *Acta Anat (Basel).* 1988;133:35-40.
  36. Melton JT, Murray JR, Karim A, et al. Meniscal repair in anterior cruciate ligament reconstruction: a long-term outcome study. *Knee Surg Sports Traumatol Arthrosc.* 2011;19:1729-1734.
  37. Magnussen RA, Mansour AA, Carey JL, et al. Meniscus status at anterior cruciate ligament reconstruction associated with radiographic signs of osteoarthritis at 5- to 10-year follow-up: a systematic review. *J Knee Surg.* 2009;22:347-357.