



UNIVERSITÀ DEGLI STUDI DI TORINO

This is an author version of the contribution published on:

Questa è la versione dell'autore dell'opera:

Heart Rhythm, 12(8), 2015, doi: 10.1016/j.hrthm.2015.05.025

The definitive version is available at:

La versione definitiva è disponibile alla URL:

<http://www.sciencedirect.com/science/article/pii/S1547527115006281>

Safety and efficacy of pulmonary vein isolation using a circular, open irrigated mapping and ablation catheter: a multi center registry

Giuseppe Stabile, MD (1), Ermenegildo De Ruvo, MD (2), Massimo Grimaldi, MD (3), Giovanni Rovaris, MD (4), Ezio Soldati, MD (5), Matteo Anselmino, MD (6), Francesco Solimene, MD (7), Assunta Iuliano, MD (1), Luigi Sciarra, MD (2), Vincenzo Schillaci, MD (7), Maria Grazia Bongiorno, MD (5), Fiorenzo Gaita, MD (6), Leonardo Calò, MD (2).

1 Clinica Mediterranea, Napoli; 2 Policlinico Casilino, Roma; 3 Ospedale Miulli, Acquaviva Delle Fonti (BA); 4 Ospedale San Gerardo, Monza; 5 Azienda Ospedaliero Universitaria Pisana, Pisa; 6 Dipartimento di Scienze Mediche, Università di Torino; 7 Clinica Montevergine, Mercogliano (AV), Italia.

Multicenter experience with nMARQ catheter

No conflict of interest exists

Word count: 3649

Address for correspondence:

Giuseppe Stabile,

Laboratorio di Elettrofisiologia,

Clinica Mediterranea,

Via Orazio 2, 80100 Napoli

TEL +390817259641;

FAX +390817259777;

e-mail gmrstabile@tin.it

ABSTRACT

Background. Pulmonary vein (PV) isolation is the cornerstone of catheter ablation in patients with atrial fibrillation (AF). Single shot ablation devices have been recently engineered.

Objectives. We report on the safety and efficacy of a novel ablation catheter for PV isolation in patients with AF.

Methods. One hundred-eighty consecutive patients (58 ± 10 years, 125 males, 31% with structural heart disease) referred for paroxysmal (140) or persistent (40) AF underwent PV isolation by an open-irrigated mapping and radiofrequency (RF) decapolar ablation catheter in 7 centers. Ablation was guided by electroanatomic mapping allowing RF energy delivery in the antral region of PVs from 10 irrigated electrodes simultaneously.

Results. Mean overall procedure time was 113 ± 53 min with a mean fluoroscopy time of 13.1 ± 8.4 min. The use of a pre-ablation PV imaging related to a significant reduction in fluoroscopy time (from 14.7 ± 9.7 to 8.7 ± 6.6 , $p < 0.001$). Mean ablation time was 12.5 ± 5.1 min, 98% of the targeted veins were isolated with a mean of 23.4 ± 6.3 RF pulses per patient. In only four (2.2%) patients a single point ablation strategy was required to achieve PV isolation. One groin hemathoma and one PV stenosis were reported. During a mean follow-up of 13.9 ± 8.2 months 38/140 (27%) patients with paroxysmal AF and 12/40 (30%) patients with persistent AF had an atrial arrhythmia relapse ($p = 0.671$)

Conclusions. In this multicenter registry, irrigated multi-electrode RF ablation resulted feasible, achieving a high rate of isolated PVs. Procedural and fluoroscopy times and success rates were comparable with other techniques with a low complication rate.

KEYWORDS: Atrial fibrillation; Catheter ablation; Multielectrode ablation catheter; Safety; Mid-term outcome

ABBREVIATIONS LIST

CA= catheter ablation

AF= atrial fibrillation

PV= pulmonary vein

INTRODUCTION

Catheter ablation (CA) has become a well-established and widespread treatment for recurrent, symptomatic, drug-resistant atrial fibrillation (AF) (1,2). Although several approaches and techniques have been proposed, ablation strategies that target pulmonary veins (PVs) or PV antra are the cornerstone for most AF ablation procedures (3). When targeted, complete electrical PV isolation should be the goal, particularly when AF is paroxysmal, that is, when triggers play a predominant role. However the ablation procedure may still require long procedure and fluoroscopy time. Another weak point of single-tip ablation catheter procedure is the deployment of a durable, contiguous transmural ablation line around the PVs. Reconnection of the PVs play a pivotal role in the mid- and long-term AF recurrences after CA. These limitations led to the development of single-shot devices (4-7) that allow delivery of different energy forms by anatomically designed ablation tools aimed at the creation of standardized linear lesions by only a few impulse applications. We report data from a multicenter registry on the acute safety and efficacy of a novel irrigated multielectrodes ablation catheter for PV isolation in patients with paroxysmal and persistent AF.

METHODS

Patients selection. This multicenter registry enrolled patients in 7 Italian centers (see the Appendix). Patients aged between 18 and 90 years with documented symptomatic paroxysmal or persistent AF episodes refractory to drug therapy (Class I or III drugs). Exclusion criteria were: (1) long-standing persistent AF, defined as AF being the sole rhythm for >12 months before the enrolment; (2) previous CA of AF; (3) New York Heart Association functional class > II; (4) unstable angina or acute myocardial infarction within three months; (5) need for or prior cardiac surgery within six months; (6) contraindication

to treatment with oral anticoagulants or bleeding diathesis; and (7) severe chronic renal or hepatic impairment. In patients in which a pre-ablation left atrial/PV imaging (computed tomography or magnetic resonance scan) was available inclusion was not based on any anatomical characteristics.

This study was approved by the institutional review committees, and all patients signed informed consents. The principle outlined in latest update of the Declaration of Helsinki were followed.

Ablation procedure. Vascular access were obtained through one or two femoral veins, and in some patients one subclavian vein. A quadripolar or decapolar catheter was introduced into the coronary sinus. A transseptal access to the left atrium was achieved using standard approach. By placing a wire in the left superior PV, the fixed sheath was exchanged, in the majority of the cases, for a steerable sheath (8.5F Agilis™ St Jude Medical, or Zurpaz™, Boston Scientific) by using the Seldinger technique. Then, the nMARQ™ (Biosense Webster Inc, Diamond Bar, CA) catheter was introduced into the steerable sheath. After transseptal access, an intravenous bolus of heparin (0.1. 0.5 mg/kg of body weight according to INR) was administered and repeated if needed to maintain an activated clotting time > 320 s. The transseptal sheath was continuously flushed (200 mL/h) with heparinized saline.

Briefly, the nMARQ™ is a steerable 8.4 F ablation and mapping 10-pole irrigated RF catheter with a novel irrigation design. Platinum electrodes are 3 mm long, with a spacing of 4 mm. Each of the electrodes retains a thermocouple and holes for irrigation. Each 3-mm electrode is individually irrigated via 10 irrigation holes using a constant flush of 4 mL/min during mapping and 60 mL/min flushing rate during ablation. By a steering mechanism placed at the handle, the catheter can be deflected unidirectionally. The 10 electrodes are arranged in a nearly circular array and the diameter may be changed in between 35mm down to 20 mm. RF ablations were preset at 30-60 seconds duration in

temperature-controlled mode and energy delivery can be individually arranged over each combination of the 10 electrodes in unipolar mode (maximum 25 W and 45 °C) or bipolar mode over 2 adjacent electrodes (maximum 15W and 45 °C). The nMARQ™ catheter was visualized in the CARTO3 system (Biosense Webster Inc, Diamond Bar,CA) and ablation was directed towards the antrum of each PV sequentially. Before ablation, the left atrial anatomy was acquired using the nMARQ™ catheter or with the decapolar catheter previously placed in the coronary sinus (DecaNav, Biosense Webster Inc, Diamond Bar,CA). Maps were acquired during AF or sinus rhythm using respiratory gating. Fast anatomic mapping or imaging integration with a pre-acquired computed tomography or magnetic resonance scan was used, according to operators preference. Further information on wall contact was gained from an impedance based technology built into the EAMS (Tissue Connect, Biosense Webster Inc, Diamond Bar,CA). Electrodes not in contact were deactivated before the start of ablation. Ablations were performed usually via all 10 electrodes and increase in temperature, drop in local impedance, and energy delivery were continuously monitored using the novel nMARQ™ Multi-Channel RF System ablation generator (Biosense Webster Inc, Diamond Bar,CA) capable of synchronously applying energy to all 10 nMARQ™ electrodes.

All ablations in our patient group ablations were usually performed in unipolar mode. After ablation the catheter was slightly rotated to ablate in potential gap regions only if electrograms were still identified. Electrodes were only deselected for ablation if no electrogram was visible on adjacent bipolar readings. In our patient cohort ablations were performed in a range between 20 and 25W over all applicable electrodes. Pacing for phrenic nerve capture was usually performed during right PVs isolation. Esophageal temperature monitoring was not routinely performed. However, a power limited to 15-20W was used for electrodes in contact with the posterior wall. Before ablation, electrograms templates were captured for each PV and after PV isolation abatement of electrograms

and PV potentials were controlled using the nMARQ™ (Figure 1). In addition, PV high-output pacing (10 V, 2.0 milliseconds) was performed to identify PV exit block if the nMARQ™ was managed into the PV. Early PV reconnection was tested 30 minutes after PV isolation, or by means of adenosine infusion, for each PV using the nMARQ™ catheter. The necessity of touch-up lesions using a conventional-irrigated-tip catheter (SmartTouch™, Biosense Webster Inc. CA) was recorded in each patient. In cases, conventional ablation was performed with 30-35 W depending on the site of ablation. Procedures were performed either with continued oral anticoagulation using warfarin and therapeutic INR (2.0-2.5) or new oral anticoagulants or using low-molecular weight heparin bridging.

Postablation management and follow-up. Oral anticoagulation was continued the same day for all patients and administered for at least 3 months and with no time limit in patients with a CHA₂DS₂-VASC score \geq 2. Antiarrhythmic drugs were usually discontinued \approx 5 half-lives prior to ablation, except for amiodarone. Patients with paroxysmal AF were usually discharged without antiarrhythmic drugs. Patients with persistent AF were discharged with or without antiarrhythmic drugs according to clinician preference. Patients were scheduled for follow-up examinations 3, 6, and 12 months after the initial treatment, and rhythm monitoring during the follow-up visits was performed by the clinical assessment of AF recurrence and Holter monitoring.

Ablation was deemed successful in the absence of symptomatic or asymptomatic atrial tachyarrhythmias lasting more than 30 seconds identified on surface ECG or on Holter monitoring, off antiarrhythmic drug therapy. In patients with persistent AF we considered the ablation successful in absence of symptomatic or asymptomatic atrial tachyarrhythmias regardless of antiarrhythmic drug therapy used. As early relapse of atrial tachyarrhythmias within the first 3 months after RF ablation may be a transient phenomenon, this transition period was excluded from the final analysis (8).

Statistical analysis. Normally distributed continuous variables were expressed as mean (\pm SD) and compared by unpaired Student's *t* test. Skewed variables were expressed as median (25-75 quartiles) and compared by the rank-sum test. Normality was assessed by the Shapiro-Wilk test. Categorical variables were presented as counts and percentages, and compared by Chi square test (Pearson, Yates or Fisher's exact test as appropriate). A Kaplan-Meier (KM) curve was plotted for the time to first atrial arrhythmia recurrence following initial ablation procedure. The probabilities of freedom from atrial arrhythmia recurrence at each 3-month follow-up time point post-blanking were presented. Differences between the curves were tested for significance by means of the log-rank statistics. A *p* value <0.05 was considered statistically significant. Analysis was performed by means of SPSS (version 11.0, SPSS Inc., Chicago, Illinois, USA).

RESULTS

Study population. One hundred-eighty consecutive patients were included in the study, 140 (78%) patients had paroxysmal AF, 40 (22%) had persistent AF. Their clinical characteristics are showed in Table I.

Procedural data. Mean overall procedure time was 113 ± 53 min with a mean fluoroscopy time of 13.1 ± 8.4 min. Image integration was used in 42/180 (23%) patients. The use of a pre-ablation PV imaging related to a significant reduction in fluoroscopy time (from 14.7 ± 9.7 to 8.7 ± 6.6 , $p<0.001$). Mean ablation time (RF time needed for PV isolation) was 12.5 ± 5.1 min, 98% of the targeted veins were isolated with a mean of 23.4 ± 6.3 RF pulses per patient. In only four (2.2%) patients a single point ablation strategy was required to achieve the PV isolation. Intraprocedural early PV reconnection occurred in 187/695 (27%) PVs and all PVs were effectively re-isolated.

Follow-up data. During the blanking period 25/140 (18%) patients with paroxysmal AF had an atrial arrhythmia recurrence. Among them 5 were atrial tachycardia or atrial flutter and the remaining AF episodes. During the blanking period 4/40 (10%) patients with persistent AF had an atrial arrhythmia recurrence, in all cases an AF episode was documented. During a mean follow-up of 13.9 ± 8.2 months 38/140 (27%) patients with paroxysmal AF and 12/40 (30%) patients with persistent AF had an atrial arrhythmia relapse ($p=0.671$) (Figure 2). At time of atrial arrhythmias recurrence, 31/40 (78%) patients with persistent AF were on antiarrhythmic drugs. Overall 10/50 (20%) patients with atrial arrhythmia relapses underwent a second ablation procedure.

Complications. No stroke/TIA, pericardial effusion, or cardiac tamponade were observed. One groin hemathoma and one PV stenosis were reported. Both were conservatively treated.

DISCUSSION

In this multicenter registry, CA of AF aiming at PV isolation by means of an irrigated multi-electrode RF ablation catheter resulted feasible, achieving a high rate of isolated PVs. In addition, procedural and fluoroscopy times were comparable with other techniques. Pre-ablation imaging allowed reduced fluoroscopy time. The mid-term success rates was comparable with other techniques with a low complication rate.

Procedural data. PV isolation, using an open irrigated catheter, with a point-by-point ablation strategy and a circular mapping catheter to validate it, is a well-established approach for AF CA (3). However it could be time consuming, often requires long fluoroscopy exposure, and the clinical results and complications are still depending on center volume and operator experience. To overcome some of these limitations and simplify the CA procedure different one-shot techniques have been developed (4-7). The nMARQTM catheter is a novel multipolar ablation catheter using irrigated RF technology

and integration into the CARTO3 system. To date five (7,9-12) single center experiences have been reported, documenting the feasibility and acute efficacy of AF ablation by the use of nMARQ™. However each of these studies included only a maximum 43 patients. In our registry, instead, we collected data on 180 patients from 7 centers. We confirmed the high success rate (98%) in achieving PV isolation. Only in four patients an additional point-by-point+ablation was required to achieve complete PV isolation. Our procedure and fluoroscopy time were similar to that reported by single centers. Our data were gathered as soon as the nMARQ™ system became available at each centre, with operators using this new technology for the first time. We could suppose that after a learning curve and greater experience further reduction in procedure duration and fluoroscopy time would become evident. It is well known that PVs anatomy variability is remarkable and, due to this, the use of a presized circular multipolar ablation catheter may present some limitations. In our cohort we were able to achieve PV isolation in nearly all patients, regardless of the PV/left atrium anatomy, however the prior knowledge of the anatomy allowed a significant reduction in the fluoroscopy time.

Safety concerns. Preliminary reports raised concerns about the safety of the nMARQ™ catheter. Deneke et al (7,13) reported one esophago-pericardial fistula, a high incidence of mild thermal esophageal lesions, and an incidence of silent cerebral lesions higher than single-tip irrigated RF. However Scaglione et al (12), using a specific and cautious procedural workflow, observed the complete absence of periprocedural silent cerebral ischemia. In our series no stroke/TIA, pericardial effusion, or cardiac tamponade were observed. Moreover, no phrenic nerve paralysis was observed thus confirming the safety profile of this catheter as compared with other one-shot+devices (e.g. phrenic nerve palsies were registered following cryoballoon ablation in the STOP-AF (14) trial in 11.2% cases).

Although all maneuvers to reduce the risk of PV stenosis, like adjusting the diameter of the circular ablation catheter to deliver RF at the antrum of the vein, were followed, in our series, a case of PV stenosis was documented.

Mid-term outcome. Few data are available on the follow-up. In the Scaglione et al (12) series 17/25 (68%) patients with paroxysmal AF were free from AF without antiarrhythmic drugs at a 6-month follow-up; in the Shin et al (10) series, after 3 months, sinus rhythm was stable off antiarrhythmic drugs in 17 of 21 (80.9%) patients; in the Zellerhof et al (11) series single and multiple procedure success rates during a mean follow-up of 140+75 days were 66 and 77%, respectively. In our cohort the freedom of atrial arrhythmias was similar at a longer follow-up (13.9 months) and also patients with persistent AF showed a recurrence rate of 30%.

Limitations. Several limitations of our study have to be addressed. The validation of the PV isolation is probably the major weak point of this technology. We used the signals recorded by the nMARQ™ catheter to demonstrate the PV entrance block. However reliability of local electrograms recorded by the nMARQ™ catheter in detecting the PV isolation remains to be demonstrated. Rosso et al (9) and Scaglione et al (12) showed that the overall concordance between Lasso and nMARQ™ signals in demonstrating PV isolation ranged from 78 to 92%. Possible explanations may be the difference in interelectrode spacing, the electrodes size, and more proximal position in the PVs ostia of the nMARQ™, which may influence the endocardial electrograms characteristics. Nevertheless, our acute and mid-term outcome can be attributed only to the use of the nMARQ™ technology because, in our study protocol, the Lasso catheter was not used to confirm PV isolation. Second, the length of mean follow-up was a little more than one year. A conclusion on long-term success rates is therefore not yet available. Third, this is a multicenter study and the ablation strategy (pre-procedural imaging, oral anticoagulant management) was not standardized. However, this observational prospective study may

provide a representative image of the real-life scenario on the use of nMARQ™ for AF ablation. The data on the number of electrodes activated during each RF pulse is unfortunately not available. Moreover, exit block from the PV was not checked in all patients, this could overestimate the rate of effective PV isolation. Finally, we did not provide data on asymptomatic cerebral ischemia and esophageal lesions were not searched for by endoscopy. Neither a standardized methodology for screening for PV stenosis was used, but a routine surveillance took place in each center according to local practice.

CONCLUSIONS

Irrigated multi-electrode RF ablation of AF using the nMARQ catheter was feasible and effective. We observed an high rate of isolated PVs in an unselected, consecutive cohort of patients with paroxysmal and persistent AF. Success rates were comparable with other techniques applied in AF ablation with a low complication rate, although severe in one patient. Longer FU and larger, multicenter randomized studies are needed to confirm these results.

Appendix

Participating centers:

Clinica Mediterranea, Napoli (Giuseppe Stabile, Assunta Iuliano, Alfonso Panella); Policlinico Casilino, Roma (Leonardo Calò, Gildo De Ruvo, Luigi Sciarra); Ospedale Miulli, Acquaviva Delle Fonti (BA) (Massimo Grimaldi); Ospedale San Gerardo, Monza (Giovanni Rovaris); Azienda Ospedaliero Universitaria Pisana, Pisa (Ezio Soldati, Maria Grazia Bongiorno); Dipartimento di Scienze Mediche, Università di Torino (Matteo Anselmino, Federico Ferraris, Fiorenzo Gaita); Clinica Montevergine, Mercogliano (AV), Italia (Francesco Solimene, Vincenzo Schillaci).

REFERENCES

1. Camm AJ, Lip GYH, De Caterina R, Savelieva I, Atar D, Honloser SH, Hindricks G, Kirchhof P. ESC Committee for Practice Guidelines. 2012 focused update of the ESC Guidelines for the management of atrial fibrillation. An update of the 2010 ESC Guidelines for the management of atrial fibrillation. *Europace* 2012;14:1385-413.
2. January CT, Wann LS, Alpert JS, et al. 2014 AHA/ACC/HRS guideline for the management of patients with atrial fibrillation: a report of the American College of Cardiology/American Heart Association Task Force on Practice Guidelines and the Heart Rhythm Society. *Circulation*. 2014;130:2071-104.
3. Calkins H, Kuck KH, Cappato R, et al. Heart Rhythm Society Task Force on Catheter and Surgical Ablation of Atrial Fibrillation. 2012 HRS/EHRA/ECAS Expert Consensus Statement 2012 HRS/EHRA/ECAS Expert Consensus Statement on Catheter and Surgical Ablation of Atrial Fibrillation: Recommendations for Patient Selection, Procedural Techniques, Patient Management and Follow-up, Definitions, Endpoints, and Research Trial Design. *Heart Rhythm*. 2012;9:632-696.
4. Sarabanda AV, Bunch TJ, Johnson SB, Mahapatra S, Milton MA, Leite LR, Bruce GK, Packer DL. Efficacy and safety of circumferential pulmonary vein isolation using a novel cryothermal balloon ablation system. *J Am Coll Cardiol*. 2005;46:1902-12.
5. De Filippo P, He DS, Brambilla R, Gavazzi A, Cantù F. Clinical experience with a single catheter for mapping and ablation of pulmonary vein ostium. *J Cardiovasc Electrophysiol*. 2009;20:367-73.
6. Dukkipati SR, Kuck KH, Neuzil P, et al. Pulmonary vein isolation using a visually guided laser balloon catheter: the first 200-patient multicenter clinical experience. *Circ Arrhythm Electrophysiol*. 2013;6:467-472.
7. Deneke T, Schade A, Müller P, Schmitt R, Christopoulos G, Krug J, Szöllösi G, Mügge A, Kerber S, Nentwich K. Acute safety and efficacy of a novel multipolar irrigated

- radiofrequency ablation catheter for pulmonary vein isolation. *J Cardiovasc Electrophysiol.* 2014;25:339-45.
8. Bertaglia E, Stabile G, Senatore G, Zoppo F, Turco P, Amellone C, De Simone A, Fazzari M, Pascotto P. Predictive value of early atrial fibrillation recurrence after circumferential pulmonary vein ablation. *Pace and Clinical Electrophysiology* 2005;28:366-71.
 9. Rosso R, Halkin A, Michowitz Y, Belhassen B, Glick A, Viskin S. Radiofrequency ablation of paroxysmal atrial fibrillation with the new irrigated multipolar nMARQ ablation catheter: verification of intracardiac signals with a second circular mapping catheter. *Heart Rhythm.* 2014;11:559-65.
 10. Shin DI, Kirmanoglou K, Eickholt C, Schmidt J, Clasen L, Butzbach B, Rassaf T, Merx M, Kelm M, Meyer C. Initial results of using a novel irrigated multielectrode mapping and ablation catheter for pulmonary vein isolation. *Heart Rhythm.* 2014 Mar;11:375-83.
 11. Zellerhoff S, Daly M, Lim HS, et al. Pulmonary vein isolation using a circular, open irrigated mapping and ablation catheter (nMARQ): a report on feasibility and efficacy. *Europace.* 2014;16:1296-303.
 12. Scaglione M, Caponi D, Anselmino M, et al. Pulmonary Vein Isolation with a New Multipolar Irrigated Radiofrequency Ablation Catheter (nMARQ[®]): Feasibility, Acute and Short-Term Efficacy, Safety, and Impact on Postablation Silent Cerebral Ischemia. *J Cardiovasc Electrophysiol.* 2014;25:1299-1305.
 13. Deneke T, Schade A, Diegeler A, Nentwich K. Esophago-pericardial fistula complicating atrial fibrillation ablation using a novel irrigated radiofrequency multipolar ablation catheter. *J Cardiovasc Electrophysiol.* 2014;25:442-3.
 14. Packer DL, Kowal RC, Wheelan KR, Irwin JM, Champagne J, Guerra PG, Dubuc M, Reddy V, Nelson L, Holcomb RG, Lehmann JW, Ruskin JN; STOP AF Cryoablation Investigators. Cryoballoon ablation of pulmonary veins for paroxysmal atrial fibrillation:

first results of the North American Arctic Front (STOP AF) pivotal trial. J Am Coll
Cardiol. 2013;61:1713-23.

CLINICAL PERSPECTIVES

The nMARQ™, irrigated multi-electrode RF ablation catheter, is a safe and effective tool to perform AF ablation aiming at PV isolation. We were able to achieve PV isolation in nearly all patients, regardless of the PV/left atrium anatomy, however the prior knowledge of the anatomy allowed a significant reduction in the fluoroscopy time. Overall procedural and fluoroscopy times and mid-term success rate were comparable with other techniques, with a low complication rate.

The use of this one-shot tool, as others, might facilitate AF ablation, perhaps overcoming the limitation that clinical results and complications of single point technologies are still dependent on center volume and operator experience.

Further and randomized studies are required to compare the safety and the efficacy of this catheter with the other single point or single shot technologies.

Figure legend.

Figure 1. Panel A: Endocardial and surface recordings during coronary sinus pacing of right inferior pulmonary vein, after radiofrequency delivery and pulmonary vein isolation.

Panels B: Endocardial and surface recordings during coronary sinus pacing of right inferior pulmonary vein before radiofrequency delivery. (arrow= pulmonary vein potentials. Panel

C: Postero-anterior view of left atrium CARTO3 reconstruction with nMARQ catheter positioned at the ostium of the right inferior pulmonary vein (red dots: radiofrequency ablation points). Panel D: Latero-lateral view of left atrium CARTO3 reconstruction.

Figure 2. Kaplan. Meier estimation of the time to atrial arrhythmia recurrence after the blanking period in patients with paroxysmal (PAROX) and persistent (PERS) patients.

Figure 1.

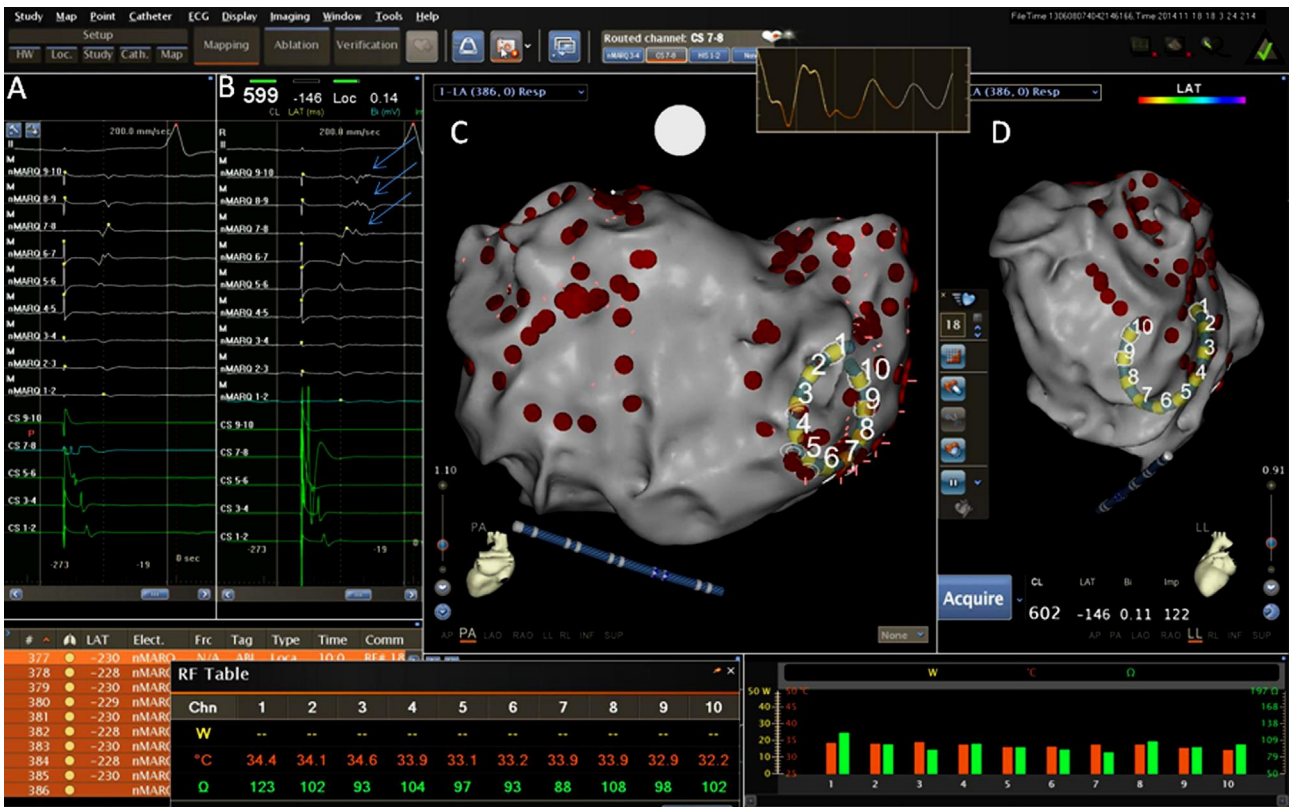


Figure 2.

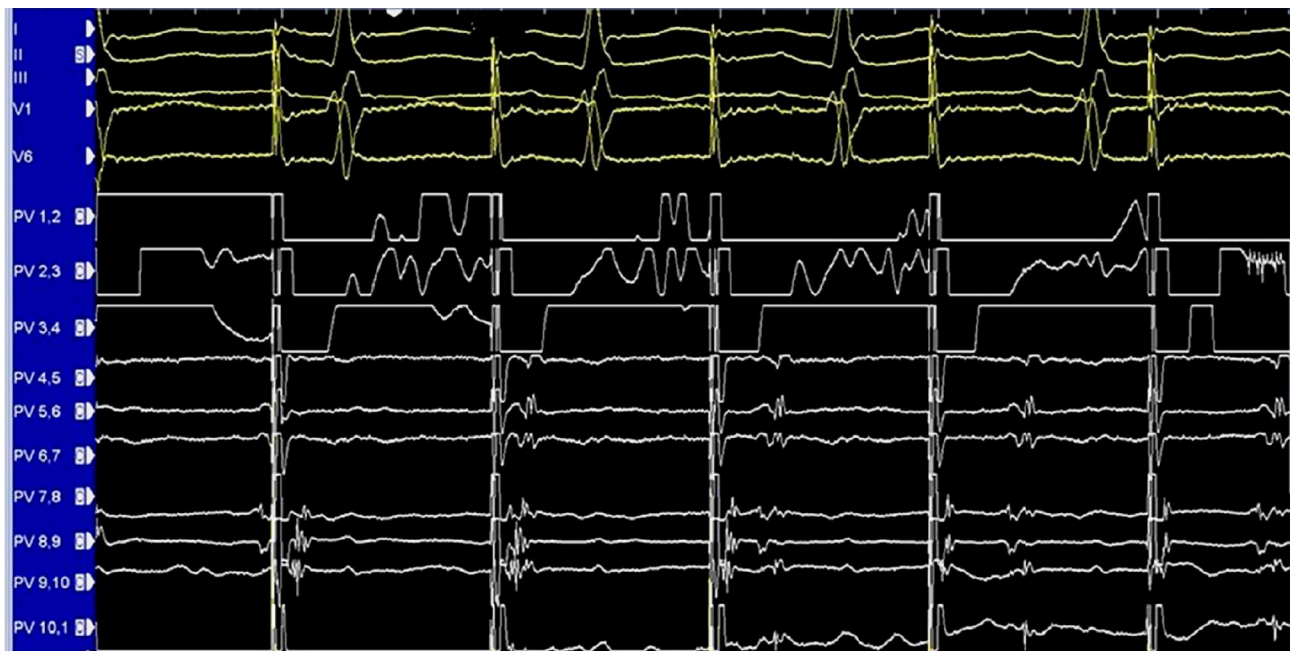


Table I. Clinical characteristics of study population

| | |
|--------------------------------------|----------------------|
| Mean age (years) | 58±10 (range 21-75) |
| Male sex | 69% |
| Left atrium diameter (mm) | 46±10 (range 33-73) |
| Left atrium volume (ml) | 79±26 (range 46-131) |
| Left ventricle ejection fraction (%) | 59±5 (range 30-70) |
| Previous stroke/TIA | 6% |
| Heart disease | 51% |
| Hypertensive | 48% |
| Ischemic | 4% |
| Valvular | 2% |
| Restrictive | 1% |
| Diabetes | 4% |