

# The Perfect Pathology Report After Neoadjuvant Therapy

Caterina Marchiò, Francesca Maletta, Laura Annaratone, Anna Sapino

Department of Medical Sciences, University of Turin, Turin, Italy (CM, FM, LA, AS).

Correspondence to: Prof. Anna Sapino, MD, Department of Medical Sciences, University of Turin, Via Santena 7, Turin 10126, Italy (e-mail: [anna.sapino@unito.it](mailto:anna.sapino@unito.it)).

## Abstract

Neoadjuvant therapy is increasingly being used in the management of breast cancer patients and, since comprehensive specimen handling and precise histological reporting is essential to assess the degree of response to therapy, histopathologists are acknowledged to play a key role in this multidisciplinary setting. However, as a matter of fact, only minimal guidelines for specimen handling are on record. This means that in every day routine practice it is not uncommon for oncologists to deal with pathology reports where important parameters are missing (such as formal comments about therapy response). According to the latest American Joint Committee on Cancer (AJCC) staging classification, posttreatment size of residual disease (ypT) should be estimated based on the best combination of imaging, gross and microscopic histological findings. Therefore, pathologists should ideally be provided with clinical and radiological information before proceeding with careful grossing. During the cut-up, large sections or extensive mapping of samples submitted to microscopic evaluation should be carried out to reconstruct the disease extent: this is particularly crucial when the lesion is unapparent both at imaging and at macroscopic observation. Histopathological reports cannot preclude from mandatory information about the presence of residual invasive carcinoma, such as histotyping, staging (ypTNM), reevaluation of prognostic and predictive factors, and categorization of degree of response according to dedicated classification systems (performed by comparing pretreatment biopsies with surgical specimens). In this review we will analyze the critical issues in such an assessment and we will provide a pragmatic approach with the intent to aim at the “perfect” pathology report.

## Background and Critical Issues

Neoadjuvant treatment (NAT) has represented a major paradigm shift in the management of breast cancer over the last years and it is increasingly being used (1,2). In the context of clinical trials NAT has offered a unique opportunity for the evaluation of treatment response, with pathological complete response (pCR) acting as a surrogate marker of survival, thus 1) allowing more rapid assessment of the efficacy of new chemotherapeutic agents, 2) enabling early ending of ineffective treatments, and 3) providing an opportunity to individualize patient treatment at early stages (1). In addition, it offers the possibility to collect tumor samples before, during, and after treatment facilitating translational research to identify markers of response (3).

Each expertise taking part in the multidisciplinary team involved in NAT for breast cancer patients has to face critical

issues. From a pathology standpoint, handling of surgical breast cancer specimens has proven challenging and pathologists have to come up with a dedicated approach to sort out troublesome sampling and reporting. A crucial point of the whole concept of NAT is represented by the assessment of degree of response to therapy that has been shown to correlate with patient outcome (4). Indeed, pCR is associated with long-term survival and has been adopted as the primary endpoint for neoadjuvant trials (5–10).

Based on a multidisciplinary vision of the issue, it has to be acknowledged that assessment of disease extension (residual tumor burden) at the end of NAT is a major challenge for radiologists before pathologists. Indeed, evaluation of disease extension based on imaging guides the decision on the best surgical approach for single patients. With the introduction of magnetic resonance imaging the accuracy in discriminating residual disease versus pCR has improved (11). However, it may

## The “perfect” histopathology report

### PATIENT INFORMATION

- Patient clinical information (age, distant metastasis)
- Radiological information before and after NAT (size, morphology and location of the tumor, multifocality, ultrasound examination of the axilla)
- NAT treatment (details)
- Accurate histopathological features assessed on biopsies before NAT

### Mandatory info:

- Histotype, tumor cellularity, necrosis
- Grade
- ER/PR/HER2/Ki67
- Sentinel lymph node

### Optional info:

- Microscopic images (to be compared with the histopathological features of the surgical specimen)

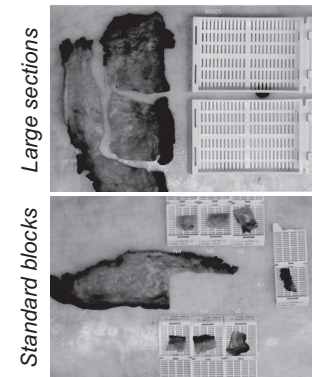
### GROSS DESCRIPTION

#### ➤ Mandatory info:

- Description of macroscopic appearance and measurement of disease extension
- Whenever macroscopic appearance is inconspicuous, best to proceed by sampling with macroblocks or multiple sampling with mapping

#### ➤ Optional info:

- Whenever macroscopic appearance is inconspicuous, if available, adopt photographic documentation (by using instruments such as Macropath®)



### NON-pCR DIAGNOSIS

#### ➤ Mandatory info:

- Tumor histological type, size, multifocality
- Lymph node assessment
- Staging (ypTNM)
- Surgical margins
- Prognostic & predictive factors

#### ➤ Optional info:

- Necrosis, fibrosis
- Grading

### pCR DIAGNOSIS

#### ➤ Mandatory info:

- Description of residual *in situ* lesions (if present) with margin evaluation

#### ➤ Optional info:

- Description of changes induced by treatment (fibrosis, necrosis, calcifications) in the breast and in the axillary lymph nodes (recommended for radiological-histological correlations)

### ➤ Categorization of tumor response to therapy according to published classification systems (MANDATORY INFO):

- In the mammary gland
- In the axillary lymph nodes

Performed by comparing pre-NAT core biopsy with surgical specimen

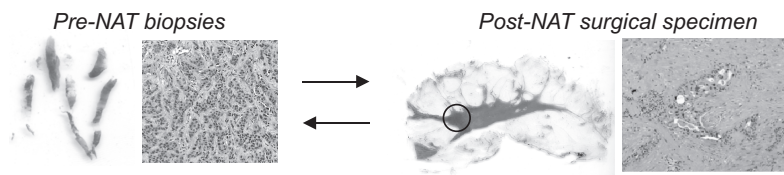


Figure 1. Schematic representation of a pathology report for a surgical specimen in a patient subjected to neoadjuvant treatment (NAT) before surgery. ER = estrogen receptor; pCR = pathologic complete response; PR = progesterone receptor.

occur to perform NAT on large lesions and to end up still performing mastectomy due to persistence of a large lesion that, at histopathological observation, is reported as residual fibrosis only [false-positive rate reported around 6% (12)]. On the other

hand, cases described as “complete responders” at imaging may have at histological observation either small foci of carcinoma, scattered neoplastic cells [false-negative rate reported around 11% (12)], or neoplastic embolization [C. Marchio and A. Sapino,

personal observation and (13)]. Altogether these data bring to the forefront the controversial facets of residual disease assessment by imaging, which strongly impacts on the balance between overtreatment (less conservative surgical procedure) and underestimation of disease burden (minimal residual disease with pervasive lymphovascular neoplastic embolization). Williams et al. (12) have recently reported in their cohort a 67% of patients undergoing mastectomy after NAT versus 33% receiving breast conserving surgery.

Moving to a histopathological perspective, when focusing on the assessment of residual tumor burden hot topics involve mainly sampling methods and type of information reported. For these pragmatic issues a solution is here suggested, whereas for others, such as the clinical significance of vascular embolization only and of residual small foci of cancer cells, just speculative hypotheses can be made and questions remain to be answered.

### Best Practice Recommendations: A Roadmap Toward the “Perfect” Pathology Report

#### Biopsy Reporting Before NAT

In our daily practice correct and standardized evaluation of the surgical specimens after NAT starts with an accurate evaluation of all features characterizing the carcinoma before NAT. Therefore, in terms of pathological assessment of response it is crucial to correctly define, within the pretreatment setting, the nature of different lesions composing large tumor masses. In our experience, sampling of different tumor areas by multiple core biopsies before NAT is instrumental to define the precise nature of the lesion (benign vs malignant, in situ vs invasive), the different tumor histological types, and the heterogeneity of the expression of predictive markers (hormone receptors, HER2, and Ki67) (4). For example, it is demonstrated that infiltrating carcinomas of lobular histological type have a poor response to chemotherapy and rarely show histological changes after NAT compared with invasive ductal carcinomas (14). Conversely, high grade invasive carcinomas of triple-negative phenotype may show a massive response to chemotherapy, probably due to high proliferation indices (15). In addition, an accurate description of tumor cellularity and type of stroma (sclerotic vs edematous) of the pre-NAT biopsies are crucial to correctly assess the response to treatment after NAT. Microscopic images of pre-NAT biopsies may be of help particularly for cases managed at different institutions (Figure 1). Ultrasound examination of the axillary lymph nodes should be reported as well, to plan the sentinel node biopsy (4).

#### Gross Handling and Reporting of Surgical Specimens After NAT

A recent study within a national neoadjuvant breast cancer trial has found a considerable variability both in terms of pathology sampling (methods and extension), reporting and, most importantly, in the interpretation of response to treatment (1). These results stress the need for consensus guidelines among trial groups on histopathology reporting, and the participation of histopathologists throughout the development and analysis of neoadjuvant trials (1). The pathologists of the European Working Group For Breast Cancer Screening have actually considered the pathological reporting of post-NAT specimens in the supplement “Quality Assurance Guidelines for Pathology Updates” that

will soon be available. In addition, according to the latest TNM classification system (16), posttreatment size of residual disease (ypT) should be estimated based on the best combination of imaging, gross and microscopic histological findings. Therefore, it is mandatory to have radiologic information attached to the pathology request. Some radiologists mark the site and extent of the tumor before NAT by using tattoos or clips. This will be particularly useful for sampling of surgical specimens in cases of pCR. Whenever a lesion is unapparent to both imaging modalities and gross pathological examination, the ways to estimate residual invasive cancer size are: 1) by using large section processing (macroblocks and macrosections) (17,18) or 2) by careful measuring and recording the relative positions of tissue samples submitted to microscopic evaluation and by determining which contain invasive cancer (16) (Figure 1). Photographic documentation of sampling is extremely helpful in this respect and for accurate evaluation of the status of resection margins (Figure 1). The examination of sentinel lymph node after NAT should be as accurate as possible, but molecular test (such as One Step Nucleic Acid Amplification assay, ie, OSNA (19)) and immunocytochemistry for cytokeratins are not recommended (20).

At microscopic observation, histotyping, staging (ypTNM), presence of in situ carcinoma (particularly requested for the evaluation of margin status in breast conserving surgery), reevaluation of prognostic and predictive factors, and categorization of degree of response according to dedicated classification systems are mandatory fields. Although grading is a predictive parameter of response to NAT and must be accurately assessed before treatment, chemotherapy may alter the nuclear morphology and preclude a correct grading on surgical specimens. Optional features to be included in the report are represented by description of changes suggesting response to chemotherapy (fibrosis, necrosis) (Figure 1). Presence of calcification outside or within in situ lesions may be described. These alterations could be usefully compared with the imaging reports to improve the interpretation of residual disease by radiologists.

While the pCR is easily derived from the diagnosis of absence of residual tumor, Provenzano et al. (1) have recently highlighted that, in their experience, a formal comment about therapy response is missing in up to 55% of all non-pCR cases. This may be due to the plethora of classification systems described and proposed so far or, alternatively, to the unavailability of the pretreatment biopsy to compare the surgical specimens with (especially for cases managed at different institutions). As a general concept, it should be considered that all of the systems recognize a category of pCR and a category of no response, with a variable number of categories of partial response (4) [for a detailed description of the different available classifications, see table 1 in (4)].

### Conclusions

NAT is increasingly used in daily practice and it is, by antonomasia, the best example of multidisciplinary approach for breast cancer patients. Multidisciplinary is of utmost importance to plan the most tailored therapeutic approach and to guarantee an accurate evaluation of response to treatment. From a strict pathological standpoint, pathologists should perform a careful grossing and complete microscopic description by comparing also, whenever possible, the surgical specimens with the pretreatment biopsies. Given the large offer of classification systems, the type of formal comment on patient's response should be wisely shared with oncologists and radiologists and standardized as much as possible. Standardization of minimal

requirements of the histopathology report is instrumental to provide oncologists with the right background to plan the second phase of treatment to be addressed to these patients (adjuvant therapy).

## Funding

CM is funded by Associazione Italiana per la Ricerca sul Cancro (AIRC) (My First AIRC Grant (MFAG) 13310), AS is funded by AIRC (IG 10787) and by the Ministry of Health (RF-2010-2310674).

## References

- Provenzano E, Vallier AL, Champ R, et al. A central review of histopathology reports after breast cancer neoadjuvant chemotherapy in the neo-tango trial. *Br J Cancer*. 2013;108(4):866–872.
- Rastogi P, Anderson SJ, Bear HD, et al. Preoperative chemotherapy: updates of National Surgical Adjuvant Breast and Bowel Project Protocols B-18 and B-27. *J Clin Oncol*. 2008;26(5):778–785.
- Berruti A, Generali D, Kaufmann M, et al. International expert consensus on primary systemic therapy in the management of early breast cancer: highlights of the Fourth Symposium on Primary Systemic Therapy in the Management of Operable Breast Cancer, Cremona, Italy (2010). *J Natl Cancer Inst Monogr*. 2011;2011(43):147–151.
- Marchiò C, Sapino A. The pathologic complete response open question in primary therapy. *J Natl Cancer Inst Monogr*. 2011;2011(43):86–90.
- Bear HD, Anderson S, Smith RE, et al. Sequential preoperative or postoperative docetaxel added to preoperative doxorubicin plus cyclophosphamide for operable breast cancer: National Surgical Adjuvant Breast and Bowel Project Protocol B-27. *J Clin Oncol*. 2006;24(13):2019–2027.
- Fisher B, Bryant J, Wolmark N, et al. Effect of preoperative chemotherapy on the outcome of women with operable breast cancer. *J Clin Oncol*. 1998;16(8):2672–2685.
- Kaufmann M, Hortobagyi GN, Goldhirsch A, et al. Recommendations from an international expert panel on the use of neoadjuvant (primary) systemic treatment of operable breast cancer: an update. *J Clin Oncol*. 2006;24(12):1940–1949.
- Sataloff DM, Mason BA, Prestipino AJ, Seinige UL, Lieber CP, Baloch Z. Pathologic response to induction chemotherapy in locally advanced carcinoma of the breast: a determinant of outcome. *J Am Coll Surg*. 1995;180(3):297–306.
- Symmans WF, Peintinger F, Hatzis C, et al. Measurement of residual breast cancer burden to predict survival after neoadjuvant chemotherapy. *J Clin Oncol*. 2007;25(28):4414–4422.
- Bonadonna G, Valagussa F, Brambilla C, et al. Primary chemotherapy in operable breast cancer: eight-year experience at the Milan Cancer Institute. *J Clin Oncol*. 1998;16(1):93–100.
- Marinovich ML, Houssami N, Macaskill P, et al. Meta-analysis of magnetic resonance imaging in detecting residual breast cancer after neoadjuvant therapy. *J Natl Cancer Inst*. 2013;105(5):321–333.
- Williams M, Eatrides J, Kim J, et al. Comparison of breast magnetic resonance imaging clinical tumor size with pathologic tumor size in patients status post-neoadjuvant chemotherapy. *Am J Surg*. 2013;206(4):567–573.
- Grimbsy GM, Gray R, Dueck A, et al. Is there concordance of invasive breast cancer pathologic tumor size with magnetic resonance imaging? *Am J Surg*. 2009;198(4):500–504.
- Sullivan PS, Apple SK. Should histologic type be taken into account when considering neoadjuvant chemotherapy in breast carcinoma? *Breast J*. 2009;15(2):146–154.
- Carey LA, Dees EC, Sawyer L, et al. The triple negative paradox: primary tumor chemosensitivity of breast cancer subtypes. *Clin Cancer Res*. 2007;13(8):2329–2334.
- Edge SB, Byrd DR, Compton CC, Fritz AG, Greene FL, Trotti A, eds. *AJCC Cancer Staging Manual*. 7th ed. New York, NY: Springer; 2010.
- Tot T. Cost-benefit analysis of using large-format histology sections in routine diagnostic breast care. *Breast*. 2010;19(4):284–288.
- Tot T, Gere M. Radiological-pathological correlation in diagnosing breast carcinoma: the role of pathology in the multimodality era. *Pathol Oncol Res*. 2008;14(2):173–178.
- Castellano I, Macri L, Deambrogio C, et al. Reliability of whole sentinel lymph node analysis by one-step nucleic acid amplification for intraoperative diagnosis of breast cancer metastases. *Ann Surg*. 2012;255(2):334–342.
- Loya A, Guray M, Hennessy BT, et al. Prognostic significance of occult axillary lymph node metastases after chemotherapy-induced pathologic complete response of cytologically proven axillary lymph node metastases from breast cancer. *Cancer*. 2009;115(8):1605–1612.