



UNIVERSITÀ DEGLI STUDI DI TORINO

This Accepted Author Manuscript (AAM) is copyrighted and published by Elsevier. It is posted here by agreement between Elsevier and the University of Turin. Changes resulting from the publishing process - such as editing, corrections, structural formatting, and other quality control mechanisms - may not be reflected in this version of the text. The definitive version of the text was subsequently published in INTERNATIONAL JOURNAL OF SURGERY, 12 Suppl 2, 2014, 10.1016/j.ijisu.2014.08.372.

You may download, copy and otherwise use the AAM for non-commercial purposes provided that your license is limited by the following restrictions:

- (1) You may use this AAM for non-commercial purposes only under the terms of the CC-BY-NC-ND license.
- (2) The integrity of the work and identification of the author, copyright owner, and publisher must be preserved in any copy.
- (3) You must attribute this AAM in the following format: Creative Commons BY-NC-ND license (<http://creativecommons.org/licenses/by-nc-nd/4.0/deed.en>), 10.1016/j.ijisu.2014.08.372

The definitive version is available at:

<http://linkinghub.elsevier.com/retrieve/pii/S1743919114008565>

Percutaneous drainage and sclerosis of mesenteric cysts: Literature overview and report of an innovative approach

Giada Pozzi, Alessia Ferrarese, Alessandro Borello, Silvia Catalano, Alessandra Surace,
Silvia Marola, Valentina Gentile, Valter Martino, Mario Solej, Mario Nano

Abstract

We present the case of a 29-years-old male patient, affected by a voluminous post-traumatic mesenteric cyst, a rare abdominal disease; our patient represents a rarely affected age group.

Treatment was based on interventional radiology with an US-guided drainage and sclerosis by ethyl alcohol of the lesion.

The intervention performed on this patient represents the application of a standardized radiological technique to a new contest, mesenteric cysts, whose gold-standard treatment is represented in literature by surgery.

In our case we obtained an optimal result, with complete regression of the treated cyst: it proved to be an effective, feasible, safe and minimally invasive procedure.

List of abbreviations

BMI, Body Max Index; US, ultrasound; ECG, electrocardiogram

1. Introduction

We present the case of a 29-years-old male patient, affected by a voluminous post-traumatic and symptomatic mesenteric cyst. Treatment was based on interventional radiology with an US-guided drainage and sclerosis by ethyl alcohol of the lesion, unlike most of other cases described in literature.

2. Case presentation

29-years-old male, employee, BMI 24.9; he referred to the Outpatients clinic of our Surgical Section because of self-palpation of an abdominal mesogastric distension, with sporadic episodes of colic abdominal pain and subjective discomfort. His medical history included tonsillectomy, removal of a pilonidal cyst, and a post-traumatic abdominal wall haematoma due to a contusive trauma of abdominal right quadrants by a domestic accident, spontaneously resolved.

Familiar and pharmacological anamnesis was silent.

The abdominal clinical examination revealed a palpable solid mass of about 10 cm, sliding from nearby tissues, in mesogastric – right paraumbilical region; the mass was not painful.

He underwent instrumental exams:

- Abdominal US: in right paraumbilical region presence of an ovalar, anecogenous, 82 mm mass, with sharp margins, not vascularized, referable to a cystic formation (Fig. 1).

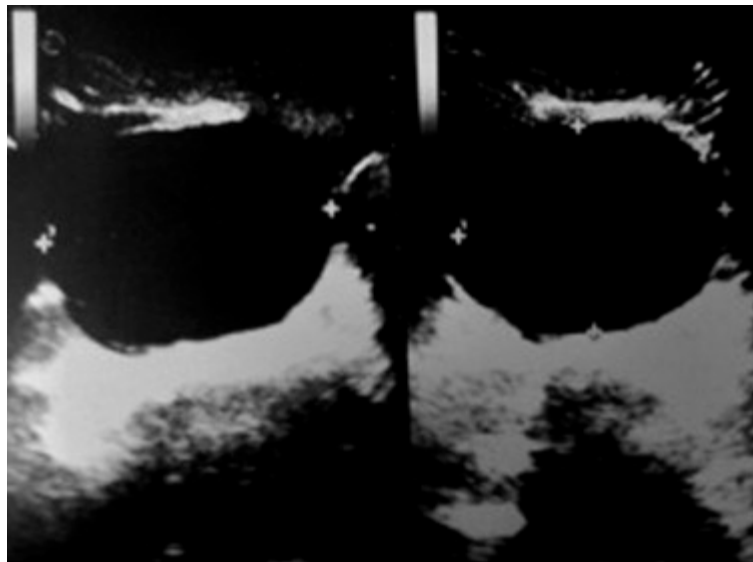


Figure 1 US image of the mesenteric cyst.

- Abdominal CT: voluminous fluid, ovalar, 85×70 mm formation in mesenteric adipose tissue of umbilical region, contiguous to abdominal wall fascia, communicating with an analogue 2 cm formation; lesions suggestive for mesenteric cysts (Fig. 2).

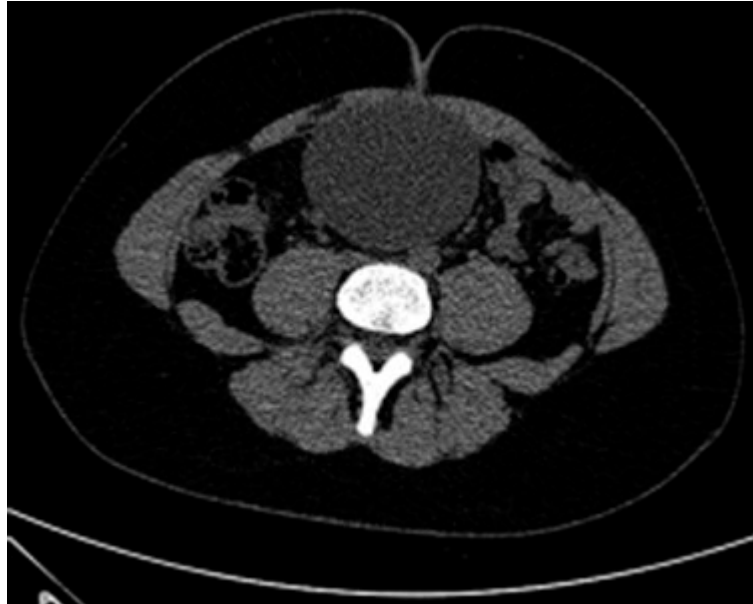

Figure 2 CT image of the mesenteric cyst.

Blood tests and EKG performed in preparation for possible subsequent therapeutic interventions were normal.

We evaluated the case by an equipe discussion with surgeons and radiologists.

The options, based on literature, were:

- watchful waiting with US follow-up, indicated for asymptomatic cysts [1].
- interventional radiology, mostly described for non mesenteric abdominal cysts treatment; for mesenteric cysts few cases are reported, treated with percutaneous drainage only, or with drainage followed by sclerosis by ethyl alcohol [1], [2] and [3].
- surgical laparoscopic or laparotomic operation, with cyst dissection and removal, or removal with involved bowel tract resection, or cystic drainage and marsupialization [4], [5], [6] and [7].

In our case, to choose the most appropriate treatment, we evaluated:

- patient age;
- symptoms and subjective discomfort;
- lesion volume;
- risk of complications due to the cyst and its volume amount;

- suspect benign nature of the cyst, probably post-traumatic;
- the entity of surgery that, even if started laparoscopically, could require a laparotomic conversion or a bowel resection;
- the availability in our hospital of radiologists expert in interventional treatments.

The collective decision was an interventional radiologic treatment including cysts drainage and its sclerosis by ethyl alcohol to reduce recurrence risk.

In day-hospital regime an US-guided sclerosis by 95% ethyl alcohol was performed. The lesion was centred by US, a pig-tail drainage was positioned, and 250 cc of yellow limpid fluid were aspirated; then 60 cc of ethyl alcohol were injected and left it in place for 20 min. Afterwards about 70 cc of fluid were aspirated, composed of ethyl alcohol and reactive cystic fluid. Post-procedure US control demonstrated the absence of residual fluid collections.

The patient was reassessed with clinical examination after 7 days and didn't present any post-procedure symptoms or complications.

Cystic fluid cytological examination was negative for neoplastic cells. We programmed an US follow-up 2 months after the procedure. This US control demonstrated a mesogastric 36×20 mm fluid collection of about 15 cc (Fig. 3).

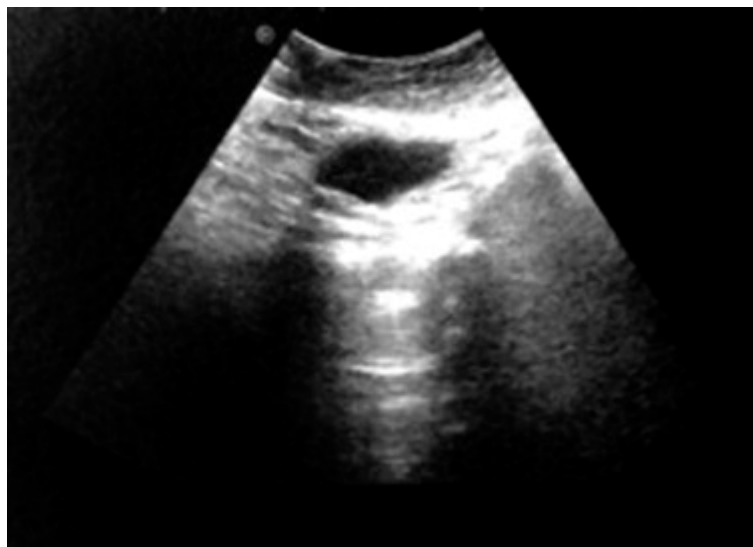


Figure 3 US image of mesogastric fluid collection - 2 months after treatment.

This image isn't interpretable as a recurrence of the lesion but it's likely due to sierositis of cystic wall reacting to ethyl alcohol treatment, typical of the first post-procedure period; the patient was asymptomatic with negative clinical examination, so we didn't perform any additional treatment and programmed an US control after 6 months (8 months from treatment). In this occasion, 8 months from treatment, the US appreciated the complete regression of the fluid collection (Fig. 4).

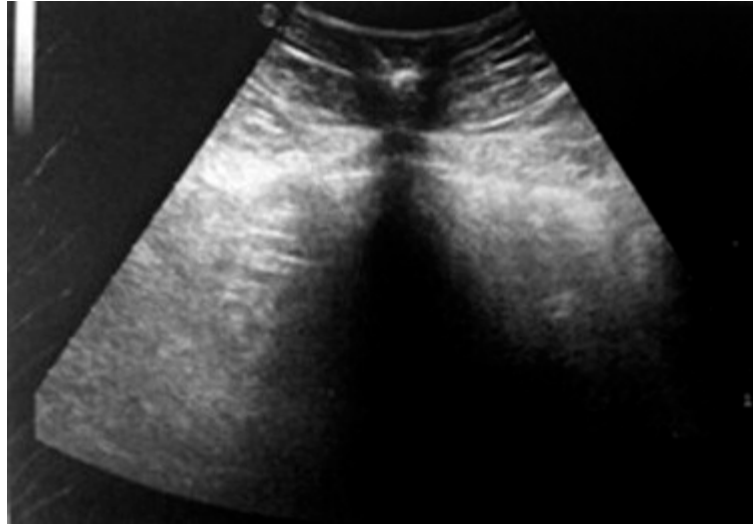


Figure 4 US image of cyst's complete regression - 8 months after treatment.

We programmed next follow-up control up to 1 year, still preferring US as imaging method instead of CT, for radioprotectionistic reasons because of patient's young age.

3. Results and discussion

Mesenteric cysts are a rare disease, representing 1/140,000 total hospital admissions and 1/20,000 paediatric hospital admissions, with a median age of 5-years-old [8]. Our patient, therefore, represents a rarely affected age group.

Mesenteric cysts diagnosis is clinical and radiological. It can be: occasional, clinical (after abdominal distension), surgical (during other operations), radiological (during examinations performed for other reasons), after complications – mostly represented by abdominal pain, bowel obstruction, volvulus formation, infection, cyst's breakage or haemorrhage, or rarely an irreducible hernia [8], [9], [10] and [11].

Among the most recent classifications we find the division in lymphatic cysts (simple or lymphangioma), mesothelial cysts (simple or benign/malignant mesothelioma), enteric cysts (simple or duplication), uro-genital cysts, dermoid cysts (mature teratoma), pseudocysts (traumatic or infective) [12]. In our case the most likely origin, basing on patient history, was traumatic. The main question was about choosing the right therapeutic approach. Would it be enough a watchful waiting with clinical and radiological follow-up, seen the little entity of cysts-related symptoms? Our answer was negative, considering among various analysed factors especially subjective discomfort and cyst's volume amount with relative complications risk [1]. Would it be more appropriate, once decided to treat the lesion, a radical surgical approach to guarantee a definitive resolution, moreover being surgery the gold-standard treatment in literature? Surgery entity was hard to define, because even opting for a laparoscopic dissection and removal of the cyst, a laparotomic conversion or the necessity of a bowel resection could occur, in a patient with a benign disease and poor symptoms [4], [5], [6] and [7].

Interventional radiology gave us a less risky way, able to obtain a valid result or even a definitive resolution, although cystic wall remains in situ, not being removed with this manoeuvre.

In literature only two cases of mesenteric cysts drainage and sclerosis by ethyl alcohol are described, and a case of US guided drainage only. Standardized procedure technique is described in detail in some reviews, being anyway only applied for treatment of abdominal cysts of not mesenteric nature, mostly parenchymal[1], [2] and [3].

An additional question is represented by the possibility of a relapse. Which approach can we foresee to apply in that case? The answer is uncertain: in the eventuality of the identification of a relapse with important volume amount or symptoms, the patient will be re-evaluated by our equipe, with the options of a new radiological treatment or a radical surgical approach.

The intervention performed on this patient represents therefore the application of a standardized radiological technique to a new context, mesenteric cysts, whose gold-standard treatment is represented in literature by surgery.

In our case the procedure obtained an optimal result, with complete regression of the treated cyst, proving to be a valid option to consider for mesenteric cysts treatment. It proved to be an effective, feasible, safe and minimally invasive procedure. We put our trust for other institutions to report more cases of mesenteric cysts interventional radiology treatment, to increase experience and discussion possibilities.

Ethical approval

Written informed consent was obtained from the patient for publication of this case report and accompanying images. A copy of the written consent is available for review by the Editor-in-Chief of this journal.

Funding

All Authors have no source of funding.

Author contribution

Giada Pozzi: Participated substantially in conception, design, and execution of the study and in the analysis and interpretation of data; also participated substantially in the drafting and editing of the manuscript.

Alessia Ferrarese: Participated substantially in conception, design, and execution of the study and in the analysis and interpretation of data.

Alessandro Borello: Participated substantially in conception, design, and execution of the study and in the analysis and interpretation of data.

Silvia Catalano: Participated substantially in conception, design, and execution of the study and in the analysis and interpretation of data.

Alessandra Surace: Participated substantially in conception, design, and execution of the study and in the analysis and interpretation of data.

Silvia Marola: Participated substantially in conception, design, and execution of the study and in the analysis and interpretation of data.

Valentina Gentine: Participated substantially in conception, design, and execution of the study and in the analysis and interpretation of data.

Valter Martino: Participated substantially in conception, design, and execution of the study and in the analysis and interpretation of data.

Mario Solej: Participated substantially in conception, design, and execution of the study and in the analysis and interpretation of data.

Mario Nano: Participated substantially in conception, design, and execution of the study and in the analysis and interpretation of data; also participated substantially in the drafting and editing of the manuscript.

Conflicts of interest

All Authors have no conflict of interests.

References

- [1] B.C. Lucey, E. Kuligowska, Radiologic management of cysts in the abdomen and pelvis, *Am. J. Roentgenol.*, 186 (2006), pp. 562–573
- [2] T. Irie, M. Kuramochi, N. Takahashi, T. Kamoshida, Percutaneous ablation of a mesenteric cyst using ethanol: is it feasible?, *Cardiovasc. Interv. Radiol.*, 33 (2010), pp. 654–656
- [3] A. Ma, K. Ayre, S. Wijeyekoon, Giant mesenteric cyst: a rare cause of abdominal distension diagnosed with CT and managed with ultrasound-guided drainage, *BMJ Case Rep.* (2012)
- [4] D. Dequanter, J.C. Lefebvre, P. Belva, M. Takieddine, P. Vaneukem, Mesenteric cysts. A case treated by laparoscopy and a review of the literature, *Surg. Endosc.*, 16 (2002), p. 1493
- [5] V. Trompetas, N. Varsamidakis, Laparoscopic management of mesenteric cysts, *Surg. Endosc.*, 17 (2003), p. 2036
- [6] P.K. Bhattacharjee, D. Purakayastha, P.C. Biswas, D. Ray, S. Chakroborty, Gigantic post-traumatic pseudocyst of sigmoid mesentery, *Indian J. Gastroenterol.*, 24 (2005), pp. 26–27
- [7] R. Al-Harfoushi, L. Stevenson, N. Binnie, Mesenteric cyst: drained and marsupialised laparoscopically avoiding enterectomy, *BMJ Case Rep.* (2012)
- [8] A. Casarotto, A. Cerofolini, F. Denitto, et al., Mesenteric cyst: case report and review of the literature, *G. Chir.*, 31 (2010), pp. 239–242
- [9] B.N. Wani, S.N. Jajoo, K.B. Golhar, A.M. Bhole, Mesenteric cyst causing acute intestinal obstruction: a rare occurrence, *Trop. Gastroenterol.*, 32 (2011), pp. 246–248
- [10] P.R. Ros, W.W. Olmsted, R.P. Moser Jr., A.H. Dachman, B.H. Hjermstad, L.H. Sobin, Mesenteric and omental cysts: histologic classification with imaging correlation, *Radiology*, 164 (1987), pp. 327–332
- [11] C. Rispoli, N. Rocco, L. Iannone, B. Amato, Developing guidelines in geriatric surgery: role of the grade system, *BMC Geriatr.*, 9 (Suppl. 1) (2009), p. A99
- [12] M. De Perrot, M. Bründler, M. Tötsch, G. Mentha, P. Morel, Mesenteric cysts. Toward less confusion?, *Dig. Surg.*, 17 (2000), pp. 323–328