



UNIVERSITÀ DEGLI STUDI DI TORINO

This is an author version of the contribution published on:

Questa è la versione dell'autore dell'opera:

[[Transpl Infect Dis.](#) 2014 Aug;16(4):653-7. doi: 10.1111/tid.12245. Epub 2014 Jun 11..]

ovvero [[Festuccia M](#)¹, [Giaccone L](#), [Gay F](#), [Brunello L](#), [Maffini E](#), [Ferrando F](#), [Talamo E](#), [Boccardo M](#), [Serra R](#), [Barbui A](#), [Bruno B.](#)]

The definitive version is available at:

La versione definitiva è disponibile alla URL:

[<http://onlinelibrary.wiley.com.offcampus.dam.unito.it/doi/10.1111/tid.12245/full>]

***Trichoderma* species fungemia after high-dose chemotherapy and autologous stem cell transplantation: a case report**

M. Festuccia^{1,2}, L. Giaccone^{1,2}, F. Gay¹, L. Brunello^{1,2}, E. Maffini^{1,2}, F. Ferrando^{1,2}, E. Talamo^{1,2}, M. Boccadoro^{1,2}, R. Serra³, A. Barbui³ and B. Bruno^{1,2,*}

1. Division of Hematology of the University of Torino, Azienda Ospedaliera Città della Salute e della Scienza di Torino, Torino, Italy

2. Dipartimento di Biotecnologie Molecolari e Scienze per la Salute, University of Torino, Torino, Italy

3. Department of Laboratory Diagnostics – Laboratory of Microbiology, Azienda Ospedaliera Città della Salute e della Scienza di Torino, Torino, Italy

* Correspondence to:

Benedetto Bruno, Division of Hematology of the University of Torino, Azienda Ospedaliera Città della Salute e della Scienza di Torino, Via Genova 3, 10126 Torino, Italy

Tel: +39 011 6334354

Fax: +39 011 6963737

E-mail: benedetto.bruno@unito.it

Keywords:

- *Trichoderma* ;
- fungemia;
- autologous transplant

Abstract

We present a case of *Trichoderma* fungemia with pulmonary involvement in a multiple myeloma patient, who was severely immunocompromised and heavily treated with high-dose melphalan, and underwent autologous hematopoietic cell transplantation. This is the first report, to our knowledge, of proven *Trichoderma* fungemia, defined by published criteria, successfully treated with voriconazole.

Despite recent advances in the therapy of infectious diseases, opportunistic mold disseminated infections remain a major cause of morbidity and mortality in patients with hematological malignancies and in transplant recipients, and prompt diagnosis and treatment are crucial. During the past 15 years, the epidemiology of invasive fungal infections has greatly changed. Although *Candida* species constitute the third to fourth most common cause of nosocomial bloodstream infection, *Aspergillus* species remain the most common cause of lethal lung infections in hematopoietic transplant recipients, and *Cryptococcus neoformans* is the most common cause of fungal-related mortality in human immunodeficiency virus patients.

However, less common but emerging fungal pathogens also cause morbidity and mortality in the increasingly expanding immunocompromised patient population. These pathogens include septate

filamentous fungi, such as *Fusarium*, *Scedosporium*, and *Trichoderma* species, and various dematiaceous molds [1, 2].

The 7 currently identified *Trichoderma* species are distributed worldwide, usually found in humid soil and decaying biological material, and rarely infect humans. In the immunocompromised host, *Trichoderma* infections are characterized by the presence of septate hyphae in tissue sections, for which differential diagnosis with invasive aspergillosis may be difficult. Few cases have been reported and included localized as well as disseminated infections, with mortality rates as high as 50%. Principal sources of contamination were ambient air, water-related sites, food, and venous catheters [3-16].

Case report

A 45-year-old Caucasian male was diagnosed with micromolecular multiple myeloma. At diagnosis, the patient presented with nephrotic syndrome with proteinuria >5 g/day and hyaline casts associated with hypertension. Other than renal failure, no signs of end-organ damage, such as hypercalcemia, anemia, and/or bone lesions, were observed. A bone marrow aspirate revealed a monoclonal plasma cell infiltration of 15%. Prompt treatment was instituted with 4 cycles of bortezomib, adriamycin, and dexamethazone followed by cyclophosphamide and recombinant human granulocyte colony-stimulating factor (G-CSF) mobilized peripheral hematopoietic cell collection. A very good partial remission was reached [17].

One month later, the patient was admitted to the Transplant Unit to receive high-dose melphalan and autologous hematopoietic cell transplantation. Upon admission, he was in good general condition with no fever and no signs of infections. Routine pretransplant chest x-ray showed no abnormalities. Hemoglobin levels, white blood cell and platelet counts, and blood biochemistry profile were normal. Melphalan was administered at the total dose of 440 mg (200 mg/m²) on day -2 and 5 × 10⁶ autologous CD34+ cells/kg were reinfused on day 0. From day +3 post transplant, G-CSF was administered for 10 days to reduce the duration of neutropenia. Antimicrobial prophylaxis consisted of acyclovir and fluconazole.

On day +5, the patient developed melphalan-induced pancytopenia with undetectable neutrophils by hemocytometer. On day +8, fever up to 38.1°C was observed. Fever work-up included central and peripheral venous blood cultures and chest x-ray, which showed no infiltrates. Empirical treatment with ceftazidime was initiated, at the dose of 2 g 3 times a day. On day +10, pulse oximetry showed an O₂ saturation of 90% that required oxygen therapy with nasal cannula. Fever became intermittent with spikes up to 39°C. Levofloxacin at 500 mg/day was added and the central venous catheter (CVC) removed and replaced with a new one at a different insertion site. Cultures from the CVC tip remained negative for fungal and bacterial pathogens.

Moreover, given the onset of right flank pain, a lung high-resolution computed tomography (HRCT) scan was performed and showed a parenchymal nodular opacity with a halo sign associated with pleural effusion, suggestive of invasive mold infection (Fig. 1A). No neurological signs or symptoms were observed. Abdominal ultrasonography showed no signs of abscess or deep tissue infiltration suggestive of fungal infection. Serum galactomannan monitoring was negative.

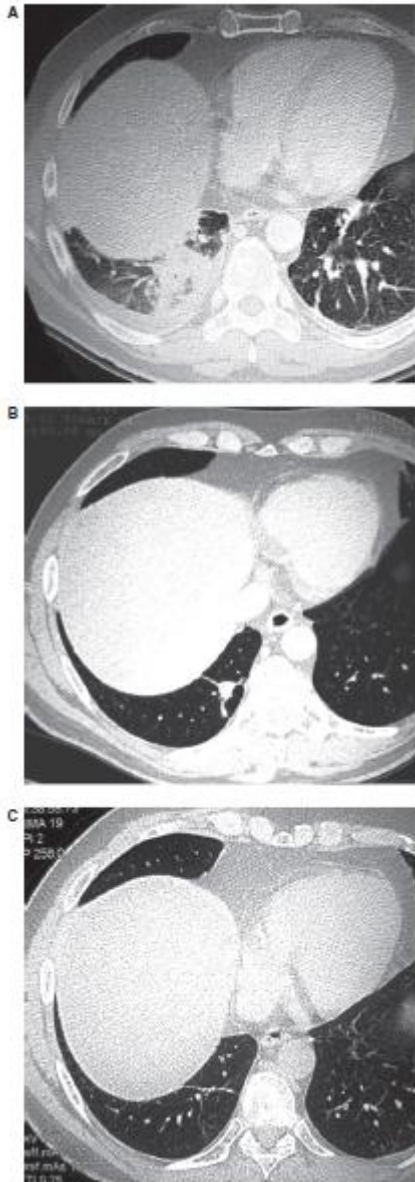

Figure 1. High-resolution computed tomography scans of the lungs: nodular opacity with halo sign in the right lung with plural effusion at 1 month post transplant (A); disappearance of the ground-glass halo sign and major reduction in the nodular opacity at 2 months post transplant (B); complete resolution of the lung infiltrate at 12 months post transplant (C).

However, after 3 days of incubation at 37°C on Sabouraud dextrose agar, blood cultures drawn on day +8 from the basilic CVC and from a peripheral vein yielded a filamentous fungus (Fig. 2A). Initially, white colonies became wooly and yellow-green within a week. At first, microscopic examination showed septate hyaline hyphae and, after a few days, conidiophores, phialides, and conidia were observed. Conidiophores were hyaline, branched with a pyramidal arrangement, and phyalide were hyaline, flask-shaped, and producing round, smooth green conidia. The fungus was identified as *Trichoderma* species by colony aspect on Sabouraud dextrose agar and by morphological features of the conidia and phialides.

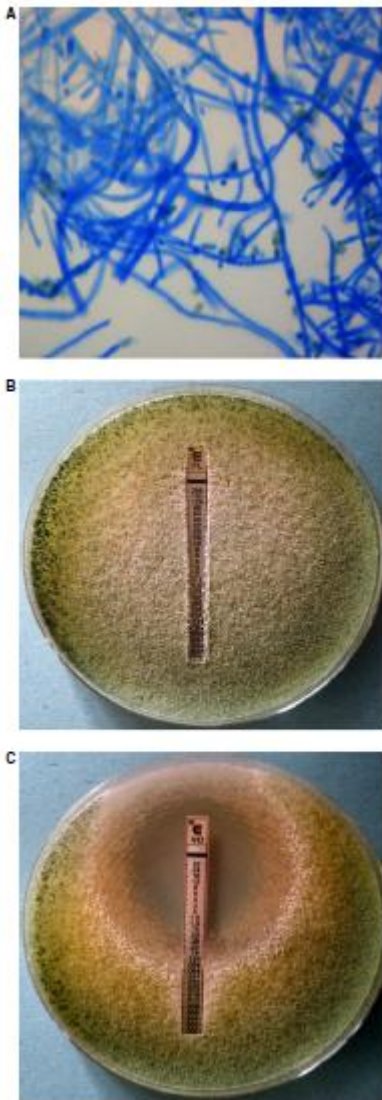


Figure 2. Microscopic appearance of *Trichoderma* species in tape mount preparation (A); antifungal susceptibility tests: fluconazole (B); and voriconazole (C).

Microscopic identification was confirmed by sequence analysis of internal transcribed spacer ITS2 rDNA [18]. The acquired sequence, compared with those reported in the Entrez Nucleotide Database of the National Center for Biotechnology Information using the BLAST algorithm to determine sequence homology, showed 100% homology with *Trichoderma* species. Antifungal susceptibility tests were performed by the Epsilometer test method as per manufacturer's instructions, compared with ATCC204350 *Aspergillus fumigatus* (Fig. 2B and C). Minimal inhibitory concentration values obtained were as follows: fluconazole >256 µg/mL, itraconazole >32 µg/mL, voriconazole 0.125 µg/mL, and caspofungin 0.047 µg/mL.

Intravenous voriconazole was started at a loading dose of 400 mg twice a day on the first day, followed by maintenance dose at 200 mg twice a day. Voriconazole plasma levels remained within the therapeutic range of 1000–5500 ng/mL (1622 ng/mL on day +22) [19]. A bronchoalveolar lavage was performed 3 days after the start of voriconazole. Cultures were negative for fungal, bacterial, and viral pathogens, as well as for galactomannan. Repeated blood cultures from CVC on day +15 were negative.

After the start of voriconazole, the patient's respiratory symptoms gradually improved. Meanwhile, blood counts recovered up to leukocytes of $2260/\text{mm}^3$, neutrophils of $1390/\text{mm}^3$, and lymphocytes of $180/\text{mm}^3$. On day +32, a repeated lung HRCT scan showed the disappearance of the ground-glass halo sign and shrinking of the nodular opacity.

The patient was eventually discharged from the Transplant Unit on day +42 post transplant in good general condition. Voriconazole therapy was continued up to 8 months post transplant. No liver or neurological toxicities were observed. On follow-up lung HRCT scans in the outpatient service, the right lung infiltrate gradually shrank and completely healed at 1 year post transplant (Fig. 1B and C).

Discussion

Trichoderma species are ubiquitous molds associated with rare, though severe, localized or disseminated infections in the immunocompromised host. Clinical manifestations may greatly vary and include pulmonary mycetoma, ulceronecrotic skin lesions, brain or liver abscess, endocarditis, sinusitis, necrotizing stomatitis, and dialysis-related peritonitis. *Trichoderma longibrachiatum*, the main human pathogen within the genus, has been isolated in 18 of the total 37 patients described in the literature [3-16]. Of note, invasive infections caused by this pathogen have more frequently been reported in patients with hematological or solid organ malignancies on immunosuppressive therapies and in patients on ambulatory peritoneal dialysis [3, 7, 12, 13]. Treatment usually requires removal of the foreign bodies, systemic antifungal therapy, treatment of the underlying disease, and in case of isolated mycetoma, surgical excision. Nevertheless, the prognosis remains poor.

To our knowledge, despite well-documented *Trichoderma* systemic disseminations, only 2 cases of positive blood cultures have so far been described [14, 15]. Here, we reported a case of proven invasive fungal infection supported by both imaging (halo sign at HRCT scan) and, importantly, proven by both central and peripheral venous blood cultures [20, 21]. In particular, blood cultures were a crucial diagnostic tool, as they were positive on samples collected before the occurrence of pulmonary symptoms and allowed for the prompt start of susceptibility testing-based antifungal therapy.

Voriconazole was preferred to caspofungin as per Center guidelines on the treatment of mold infections and its distribution through the hemato-encephalic barrier. Antifungal combination therapy as front-line therapy was avoided, given the lack of convincing data on the advantage of its use [21, 22]. Single-agent therapy with voriconazole was well tolerated, and cured the infection.

An increased awareness is needed of this uncommon, but frequently fatal, fungal infection other than *Aspergillus* species, and it should be considered in immunosuppressed patients, as timely diagnostic work-up, including imaging studies and blood cultures, allowed a prompt diagnosis of a potentially life-threatening infection. In our experience, voriconazole was efficient in the treatment of fungal pneumonia associated with *Trichoderma* fungemia in a severely immunocompromised patient.

Acknowledgements

Support: This study was supported in part by Progetti di Ricerca ex-60%, Ministero dell'Università e della Ricerca Scientifica (M.I.U.R.); Regione Piemonte: Ricerca Finalizzata 2008, 2009; Fondazione Cassa di Risparmio di Torino (C.R.T.); Compagnia di San Paolo; Comitato Regionale Piemontese Gigi Ghirotti; Fondazione Neoplasie Sangue Onlus (FO.NE.SA.).

References

1. Walsh TJ, Groll A, Hiemenz J, Fleming R, Roilides E, Anaissie E. Infections due to emerging and uncommon medically important fungal pathogens. *Clin Microbiol Infect* 2004; 10 (Suppl 1): 48–66.
2. Neofytos D, Horn D, Anaissie E, et al. Epidemiology and outcome of invasive fungal infection in adult hematopoietic stem cell transplant recipients: analysis of Multicenter Prospective Antifungal Therapy (PATH) Alliance registry. *Clin Infect Dis* 2009; 48 (3): 265–273.
3. Campos-Herrero MI, Bordes A, Perera A, Ruiz MC, Fernandez A. *Trichoderma koningii* peritonitis in a patient undergoing peritoneal dialysis. *Clin Microbiol Newslett* 1996; 18: 150–151.
4. Guiserix J, Ramdane M, Finielz P, Michault A, Rajaonarivelo P. *Trichoderma harzianum* peritonitis in peritoneal dialysis. *Nephron* 1996; 74 (2): 473–474.
5. Richter S, Cormican MG, Pfaller MA, et al. Fatal dissemination of *Trichoderma longibrachiatum* infection in an adult bone marrow transplant patient: species identification and review of literature. *J Clin Microbiol* 1999; 37 (4): 1154–1160.
6. Eşel D, Koç AN, Utaş C, Karaca N, Bozdemir N. Fatal peritonitis due to *Trichoderma* sp. in a patient undergoing continuous ambulatory peritoneal dialysis. *Mycoses* 2003; 46 (1–2): 71–73.
7. Chouaki T, Lavarde V, Lachaud L, Raccurt CP, Hennequin C. Invasive infections due to *Trichoderma* species: report of 2 cases, findings of in vitro susceptibility testing, and review of the literature. *Clin Infect Dis* 2002; 35 (11): 1360–1367.
8. Bustamante-Labarta MH, Caramutti V, Allende GN, Weinschelbaum E, Torino AF. Unsuspected embolic fungal endocarditis of an aortic conduit diagnosed by transesophageal echocardiography. *J Am Soc Echocardiogr* 2000; 13: 953–954.
9. Furukawa H, Kusne S, Sutton DA, et al. Acute invasive sinusitis due to *Trichoderma longibrachiatum* in a liver and small bowel transplant recipient. *Clin Infect Dis* 1998; 26 (2): 487–489.
10. Munoz FM, Demmler GJ, Travis WR, Ogden AK, Rossmann SN, Rinaldi MG. *Trichoderma longibrachiatum* infection in a pediatric patient with aplastic anemia. *J Clin Microbiol* 1997; 35 (2): 499–503.
11. Seguin P, Degeilh B, Grulois I, et al. Successful treatment of a brain abscess due to *Trichoderma longibrachiatum* after surgical resection. *Eur J Clin Microbiol Infect Dis* 1995; 14 (5): 445–448.
12. Alanio A, Brethon B, Feuilhade de Chauvin M, et al. Invasive pulmonary infection due to *Trichoderma longibrachiatum* mimicking invasive aspergillosis in a neutropenic patient successfully treated with voriconazole combined with caspofungin. *Clin Infect Dis* 2008; 46 (10): 116–118.
13. Myoken Y, Sugata T, Fujita Y, Asaoku H, Fujihara M, Mikami Y. Fatal necrotizing stomatitis due to *Trichoderma longibrachiatum* in a neutropenic patient with malignant lymphoma: a case report. *Int J Oral Maxillofac Surg* 2002; 31 (6): 688–691.
14. Lagrange-Xélot M, Schlemmer F, Gallien S, Lacroix C, Molina JM. *Trichoderma* fungaemia in a neutropenic patient with pulmonary cancer and human immunodeficiency virus infection. *Clin Microbiol Infect* 2008; 14 (12): 1190–1192.

15. Kuhls K, Lieckfeldt E, Börner T, Guého E. Molecular reidentification of human pathogenic *Trichoderma longibrachiatum* and *Trichoderma citrinoviride*. *Med Mycol* 1999; 37 (1): 25–33.
16. De Miguel D, Gómez P, González R, et al. Nonfatal pulmonary *Trichoderma viride* infection in an adult patient with acute myeloid leukemia: report of one case and review of the literature. *Diagn Microbiol Infect Dis* 2005; 53 (1): 33–37.
17. Kyle RA, Rajkumar SV. Criteria for diagnosis, staging, risk stratification and response assessment of multiple myeloma. *Leukemia* 2009; 23 (1): 3–9.
18. Turenne CY, Sanche SE, Hoban DJ, Karlowsky JA, Kabani AM. Rapid identification of fungi by using the ITS2 genetic region and an automated fluorescent capillary electrophoresis system. *J Clin Microbiol* 1999; 37 (6): 1846–1851.
19. Park WB, Kim NH, Kim KH, et al. The effect of therapeutic drug monitoring on safety and efficacy of voriconazole in invasive fungal infections: a randomized controlled trial. *Clin Infect Dis* 2012; 55 (8): 1080–1087.
20. Ascioglu S, Rex JH, de Pauw B, et al.; Invasive Fungal Infections Cooperative Group of the European Organization for Research and Treatment of Cancer; Mycoses Study Group of the National Institute of Allergy and Infectious Diseases. Defining opportunistic invasive fungal infections in immunocompromised patients with Cancer and Hematopoietic Stem Cell Transplants: an international consensus. *Clin Infect Dis* 2002; 34 (1): 7–14.
21. De Pauw B, Walsh TJ, Donnelly JP, et al.; European Organization for Research and Treatment of Cancer/Invasive Fungal Infections Cooperative Group; National Institute of Allergy and Infectious Diseases Mycoses Study Group (EORTC/MSG) Consensus Group. Revised definitions of invasive fungal disease from the European Organization for Research and Treatment of Cancer/Invasive Fungal Infections Cooperative Group and the National Institute of Allergy and Infectious Diseases Mycoses Study Group (EORTC/MSG) Consensus Group. *Clin Infect Dis* 2008; 46 (12): 1813–1821.
22. Maertens J, Marchetti O, Herbrecht R, et al.; Third European Conference on Infections in Leukemia. European guidelines for antifungal management in leukemia and hematopoietic stem cell transplant recipients: summary of the ECIL 3–2009 update. *Bone Marrow Transplant* 2011; 46 (5): 709–718.