



# UNIVERSITÀ DEGLI STUDI DI TORINO

***This is an author version of the contribution published on:***

*Questa è la versione dell'autore dell'opera:*

*Journal of Periodontal Research, 2013, doi: 10.1111/jre.12133.*

***The definitive version is available at:***

*La versione definitiva è disponibile alla URL:*

*<http://onlinelibrary.wiley.com/doi/10.1111/jre.12133/full>*

**Unexpected resilience to experimental gingivitis of subepithelial connective tissue grafts in gingival recession defects: a clinical-molecular evaluation.**

A. Graziano <sup>1</sup>, N. Cirillo <sup>2</sup>, S. Pallotti <sup>1</sup>, L. Cricenti <sup>1</sup>, F. Romano <sup>1</sup>, M. Aimetti <sup>1</sup>

<sup>1</sup>Department of Periodontology, Dental School, University of Turin, Torino, Italy

<sup>2</sup>Melbourne Dental School & Oral Health CRC, The University of Melbourne, Melbourne, Vic., Australia

**Corresponding Author:**

Prof. Dr. Nicola Cirillo, Melbourne Dental School, The University of Melbourne, 720 Swanston Street, Carlton, Melbourne, 3053 Vic., Australia

Tel/Fax. +61 03 9341 1581

e-mail: [nicola.cirillo@unimelb.edu.au](mailto:nicola.cirillo@unimelb.edu.au)

## **Abstract**

**Background and objective:** The subepithelial connective tissue graft (SCTG) is the most widely used procedure for the treatment of gingival recession defects. Little is known, however, as to whether the apposed gingival flaps are more predisposed to develop plaque-related inflammation compared to healthy sites. This has salient clinical implications, as the long-term results of root coverage will depend largely on the level of inflammation of the grafted tissue.

**Methods:** In the present split-mouth case-control study, clinical and biomolecular parameters were used to assess the level of inflammation of periodontal sites 12 mo after treatment with SCTG (test) and healthy non-treated gingivae (control) following the induction of plaque-related gingivitis in 19 patients.

**Results:** The data showed that test sites had a significantly ( $P < 0.05$ ) lower gingival index and angulated bleeding score compared to control sites (gingival index =  $1.05 \pm 0.23$  vs.  $1.34 \pm 0.47$ ; angulated bleeding score =  $0.34 \pm 0.37$  vs.  $0.61 \pm 0.39$ ) after induction of experimental gingivitis, whereas the plaque index did not differ in the two groups ( $P > 0.05$ ). With regard to the biomolecular parameters, baseline levels of the proinflammatory cytokine interleukin- $1\beta$  were higher in the gingival crevicular fluid of test sites. However, control sites exhibited more pronounced increase in the levels of interleukin- $1\beta$  compared to test sites, upon plaque accumulation, so that the final concentration was similar in both groups. No changes were recorded in the gingival crevicular fluid volume.

**Conclusion:** Analysis of the data demonstrates that the sites of gingival recession treated with SCTG develop a lower degree of plaque-induced inflammation compared to healthy gingivae.

This strongly suggests that SCTG does not predispose to inflammation and to further gingival recession and makes it a safe technique in the treatment of gingival defects.

**Key words:** chemokines; dental plaque, gingivitis; inflammation; periodontal surgery

## **Introduction**

Gingival recession - the apical shift of the gingival margin respect to cemento-enamel junction (CEJ) - determines an exposure of the root surface to the oral cavity (1,2). This has major aesthetic consequences especially in the anterior sectors, when the disharmony is visible during the patient's smile or speaking. Furthermore, the irregular outline of the gingival margin makes it difficult to achieve plaque control and can cause dentin hypersensitivity.

To correct both aesthetic and functional defects associated with gingival recession, root-coverage techniques have been developed as part of periodontal plastic surgery procedures (3). The subepithelial connective tissue graft (SCTG), or bilaminar technique, is the most predictable procedure for the treatment of gingival recession defects with a mean root coverage up to the 97.3% and teeth with complete root coverage up to 86.7% (4).

The use of SCTG, proposed by Langer and Langer in 1985 (5) and modified by Bruno in 1994 (6), provides the placement of a subepithelial connective tissue graft, directly on the exposed root, and a coronally advanced flap.

At the microscopic level, the nature of the attachment between the grafted tissue and root surface is not completely understood. The few data from human studies indicate that a new connective tissue attachment can occur in the lateral and apical regions of the recession defect,

even with rare regeneration of bone and cementum, while a long junctional epithelium extends over most of the root (7,8). This kind of attachment is considered a periodontal repair and not regeneration, and could potentially act as a “locus minoris resistentiae” in the presence of detrimental environmental factors. Nothing is known, however, as to whether the SCTGs are at a higher risk of developing inflammation and new gingival recession compared to healthy sites when challenged by dental plaque. To gain insight into these understudied questions, in the present study we investigated the changes of clinical parameters in SCTGs 1 year after surgery in response to plaque accumulation, as seen in experimental gingivitis.

The ideal area to obtain a graft with an appropriate thickness (2 mm) is the palatine mucosa in the premolar region where there is a well-differentiated submucosa layer in addition to the loose connective tissue crossed by neurovascular bundles. However, the palatine mucosa is fixed and inseparable from the periosteum of the hard palate by strong bands of inelastic connective tissue that define spaces containing mucous glands and fatty cells (9).

Successful connective tissue graft procedures should ensure not only an esthetic integration between tissues but also a physiological activity of the graft in terms of sensitivity and immunity (10–12). We have shown previously that alteration of the epicritical and/or protopical sensation was found in all the gingival sites where SCTG was performed 12 mo before the sensorial tests, which was possibly related to an increase of free Merkel cells in the grafts (13). Similarly, an altered inflammatory response of the grafted tissues could affect the success of SCTGs. Unfortunately, limited or no data are available about the immune responsiveness of the treated areas to de novo plaque accumulation. In the normal gingival tissue, exposure to the bacterial biofilm causes inflammation, reversible after removal of the plaque, which manifests by the clinical signs of gingivitis (14). Dilation and increased

vascular permeability leading to edema formation, associated with a color change of the tissues towards deep red and bleeding tendency after stimulation. The junctional epithelium is interrupted by a leukocyte infiltrate also present in the increased gingival crevicular fluid (15–19). It is possible that this process is altered in the grafted tissue areas. To investigate this working hypothesis, we evaluated the concentration of interleukin (IL)-1 $\beta$  in the gingival crevicular fluid, together with gingival crevicular fluid volume. IL-1 $\beta$  is one of the main inflammatory markers identified in crevicular fluid and its expression, in addition to being genetically modulated (20), increases with the rise of the clinical parameters associated with the severity of periodontal disease (21,22).

The aim of this split-mouth study was to compare the clinical and molecular response of SCTGs in gingival recession defects and healthy gingiva before and after experimental gingivitis. Surprisingly, analysis of the data demonstrates that the sites treated with SCTG develop a lower degree of plaque-related inflammation compared to healthy gingivae.

## **Material and methods**

### **Study Population**

The recruitment of the sample occurred among patients subjected to mucogingival surgery for problems of aesthetics and/or sensitivity due to recessions of Miller Class I or II.

The surgical treatment was conducted at the Department of Periodontology (Dental School, University of Turin), between 2006 and 2010. Ethical approval was obtained for this study.

The surgery was performed at sites without root caries, cervical restorations of Black Class V, veneers or prosthetic crowns.

Exclusion criteria for the performance of surgery were:

- Systemic diseases which can influence periodontal tissues (diabetes, collagen or immunological diseases, organ transplants);
- Taking drugs that can induce an increase in gingival volume (anti-epileptics, calcium channel blockers, immunosuppressants or estroprogestogen therapy);
- Chronic or aggressive periodontitis;
- Pregnancy or breast-feeding.

The operations of root coverage were scheduled at the end of the no-surgical therapy, in the presence of an adequate control of plaque and inflammation (Full Mouth Plaque Score <20% and Full Mouth Bleeding Score <20%).

The surgical procedure of SCTG, performed by periodontists experts with additional lenses and instruments for micro-invasive surgery, provided the use of the bilaminar technique with coronally positioned flap and palatal connective tissue graft.

### **Sample selection**

All patients of the study population have been recalled 12 mo from the surgery and the research protocol was presented to them.

For the patients who have agreed to take part in the research, providing a written consent, it was verified that the exclusion criteria highlighted above did not subsist, with the addition of the following (23,24):

- Probing depths above 3 mm;
- Intake of antibiotics during the month before the start of the experimental phase;
- Current orthodontic treatments;
- Consumption of more than 10 cigarettes / day.

At the end of the selection the sample included 19 patients (nine male and 10 female, one of them a light smoker) from 24 to 48 years old (average  $34.67 \pm 8.65$ ).

### **Experimental Design**

The research was a split-mouth case-control study. Each test site, represented by a dental element subjected to root coverage, was combined with a healthy control untreated site. Clinical assessments were made 1 mo before surgery to achieve good plaque control, and then 3, 6, 9, and 12 mo after surgery.

Clinical evaluations and biomolecular analysis were performed for each site at the beginning of the experimental phase (baseline, 12 mo after surgery) and repeated after 14 d of total suspension of oral hygiene by patients.

### **Test and control sites selection**

*Surgical procedures*— Patients underwent a training session on tooth brushing 2 mo before surgery. The free gingival graft technique was undertaken as follows: epithelium was eliminated from the graft by putting the connective tissue side on a sterile plate and passing a blade on the epithelium side to remove the outer layer. The depth of the graft was homogeneous and measured approximately 1.5 mm. Wires were in vicryl 5/0 and GORE Tex suture with C3 needle.

Chlorexidine 0.12% twice a day for 10 d and non-steroidal anti-inflammatory drugs for 3 d after surgery if needed were prescribed to all patients; they were recalled after surgery at 3, 6, 9 mo and weekly the last month before the experimental phase (12th month).

All surgical procedures were undertaken by the same operator to avoid biases and reduce variability.



*Experimental procedures* - A session of professional supragingival scaling with ultrasonic instrument (Air-Flow S2, Universal handpiece Piezon, tip insert A, EMS, Electro Medical Systems S.A., Nyon, Switzerland) was performed with all patients to achieve maximal plaque control, optimum gingival health and to standardize gingival baseline conditions (25). Moreover, all subjects were motivated and trained to oral house hygiene (roll brushing technique, flossing).

Three days after the scaling, each patient was recalled and the Gingival Index (GI) (26) in the mid-buccal and mesial-buccal sites of examined teeth was recorded. Only the patient with GI=0 was entered into the experimental phase.

Plaque Index (27), Periotron® volume of the gingival crevicular fluid (28), collected with absorbent strips, and Angulated Bleeding Score (AngBS) (29) were recorded at test and control site for baseline.

The clinical measurements were taken over by the same operator, using a graduated periodontal probe (PCP15/11.5; Hu Friedy, Mfg. B.V., Rotterdam, Netherland).

To detect the AngBS, after lightly drying the gingiva with compressed air, the periodontal probe was held at an angle of approximately 60° to the longitudinal axis of the tooth and in contact with the sulcular gingival tissues.

After measuring the volume of GCF, the samples were prepared for the dosage of IL-1β by enzyme-linked immunosorbent assay test.

After the data collection, the patients were asked not to clean the teeth or rinse the mouth for 14 d. At the end of this period all the periodontal values and the gingival crevicular fluid sampling were taken again.

### **Gingival crevicular fluid sampling and volume analysis**

For the collection of GCF we used sterile paper strips (PerioPaper®; OraFlow Inc., Plainview, NY, USA). Briefly, each site was gently air-dried in an apico-coronal direction; the area was carefully isolated with cotton rolls, to avoid salivary contamination of the sample; the paper strip was introduced into the gingival sulcus until mild resistance was felt, whilst care was taken to avoid mechanical injury of the tissues. The strip was left *in situ* for 30 s and immediately transferred, for volume determination, to the electronic analyzer Periotron® 8000 (OraFlow Inc.).

Before starting the measurements the Periotron® was calibrated with a sterile strip, according to the manufacturer's instructions. The two plates were cleaned with sterile gauze among a sample and the other.

The gingival crevicular fluid sample was collected before and after the non-cleaning phase at the same time to exclude variation due to the fluctuation of the concentration of IL-1 $\beta$  within the 24 hours (23).

If a strip, after being removed from the gingival sulcus, had presented an obvious blood contamination, it was removed and, after at least 60 s, the collection was repeated.

The scores provided by Periotron® were converted to microliters (mL) using the equation that best describes the calibration curve (30).

### **Interleukin-1 $\beta$ assay**

The biomolecular research was conducted in the laboratories of the section of General Pathology, Department of Medicine and Experimental Oncology, University of Turin.

Each strip, removed from the Periotron®, was immediately placed in a polypropylene test tube

containing 350 mL of a buffer solution, phosphate buffered saline. The tubes (Micro Test Tubes, Eppendorf AG, Hamburg, Germany) were kept at room temperature and occasionally stirred. After 60 min, the strips were removed from the test tubes, which were stored at -80°C. The tubes were thawed and the phosphate-buffered saline contained inside was centrifuged at 2700 g for 5 min so the epithelial residues, dissolved in solution, adhered to only one wall. The supernatant was transferred to a new tube, preventing the tip contacted the walls of the tube.

The level of IL-1 $\beta$  in the gingival crevicular fluid was determined using the Human IL-1 $\beta$  Instant enzyme-linked immunosorbent assay kit (Bender MedSystem GmbH, Wien, Austria), according to the manufacturer's instruction.

The test sensitivity is 0.7 pg/ml and the resulting standard curve expresses the IL-1 $\beta$  values as pg/100 mL. The quality and reproducibility of the IL-1 $\beta$  analysis was tested by measuring standard solutions with known concentration of IL-1 $\beta$ .

The IL-1 $\beta$  concentration was then compared to the paper strip elution (350 $\mu$ L).

### **Statistical analysis**

The dental site was regarded as the statistical unit. For each clinical and biomolecular parameter, the average of the two recordings, from the mid-and mesial-buccal position of all the sites of interest, was calculated. These data were obtained for the baseline and after 14 d.

As the non-Gaussian data distribution, the non-parametric Wilcoxon test was used to analyze the changes between baseline and follow-up to 14 d.

As the split-mouth design of the research, the Wilcoxon test was also used to assess the significance of the differences between test and control both at the baseline and after the no-cleaning phase.  $P < 0.05$  was considered statistically significant.

The statistical analysis was performed using the software STATPLUS 2009 Professional 5.8.4 (Analystsoft Inc., Alexandria, VA, USA)

## **Results**

### **Study sample**

The pre-experimental phases of the research and the study design have been summarized in the flow chart (Fig. 1). All the patients in the sample ( $n = 19$ ), previously subjected to bilaminar technique for the treatment of gingival recessions, have completed the experimental phase of the research and no one needed antibiotics during this period, so there were no drop-outs. Measurements of probing depth, clinical attachment loss, bone loss, bleeding on probing in all sample groups were undertaken (not shown). The measurements of the parameters analyzed in this study from control and test sites are reported as mean  $\pm$  standard deviation (SD) in Table 1.

### **Grafts are more resilient than healthy tissues to experimental gingivitis**

First, we wanted to understand whether there was any major change in clinical parameters of inflammation 1 year after surgery. At baseline, test and control sites showed homogeneous clinical features ( $P > 0.05$ ). The GI was equal to 0 for all sites, which was a necessary requirement to enter the experimental phase. The plaque index and AngBS followed a different trend in the sites subjected to bilaminar surgery compared to controls, although the

difference was not statistically significant. Specifically, treated sites showed a lower AngBS and a greater plaque index at baseline, compared with control sites (Fig. 2).

After the non-cleaning phase, both groups showed a statistically significant increase in all parameters ( $P < 0.05$ ). Interestingly, GI and AngBS were higher in control sites compared to grafted tissues ( $P < 0.05$ ) (Table 1 and Figs 2–4).

As revealed by key clinical parameters of gingival inflammation such as GI and AngBS, the data demonstrate that grafted tissues are less susceptible to experimental gingivitis than normal gingival tissues.

#### **Analysis of biomolecular parameters**

The next step was to investigate whether any differences were present between grafted and normal tissues in terms of molecular markers of gingival inflammation. Unlike clinical parameters, evaluation of gingival crevicular fluid volume and IL-1 $\beta$  levels at baseline displayed significant differences between the two groups ( $P < 0.05$ ). The test sites showed a mean volume of gingival crevicular fluid and an average amount of IL-1 $\beta$  higher than the control sites (Table 2).

From the analysis of the data distribution based on percentiles, 75% of the test sites had a crevicular fluid volume  $\leq 0.29 \mu\text{L}$  vs.  $\leq 0.17 \mu\text{L}$  in control sites. Concerning IL-1 $\beta$  in the gingival crevicular fluid, 75% of the test sites showed a concentration  $\leq 25.36 \text{ pg}/350 \mu\text{L}$ ; levels of IL-1 $\beta$  were  $\leq 22.17 \text{ pg}/350 \mu\text{L}$  in 75% of the controls.

After suspending oral house hygiene for 14 d, the increase of crevicular fluid and IL-1 $\beta$  in the control sites was higher than that recorded in the test sites. Therefore, at the end of the experimental phase the difference between the two groups was no longer statistically significant (Table 2 and Figs 5 and 6).

Taken together, the data show that IL-1 $\beta$  remains at higher levels in grafted tissues 1 year after surgery, induction of experimental gingivitis associates with a comparable concentration of this cytokine in test and control sites.

## **Discussion**

In the present study, we demonstrate that the use of SCTG for the repair of gingival recession defects does not predispose the grafted tissues to plaque-related inflammation. Interestingly, the grafts developed gingivitis to a lesser extent compared to healthy gingival tissues, as revealed by clinical evaluation.

Few data regarding the healing of the areas treated with SCTG are available in the literature; specifically, there is no clear understanding as to the biological behavior of grafts in physiological conditions and in response to an inflammatory insult. To investigate these aspects, a sample for a split-mouth study was selected. The sample was composed of 19 patients treated successfully for the correction of gingival defects with SCTG. The patients were not susceptible to periodontal disease and therefore it was assumed that, after suspending oral hygiene operations, they developed an induced gingivitis where the clinical signs of inflammation were proportional to plaque accumulation. Clinical and biomolecular parameters were used to measure the level of inflammation of periodontal sites 12 mo after treatment with SCTG (test) and healthy non-treated gingivae (control) following the induction of plaque-related gingivitis. In the present study, we did not evaluate the same parameters before surgery in either test or control sites. Although this may represent a study flaw, we believe that the assessment of these values before surgery would not be relevant to our aims, i.e.

understanding the response of SCTG to plaque accumulation, and would not affect the interpretation of the data.

The results showed that each site, test and control, was clinically healthy at baseline; IL-1 $\beta$  was present in crevicular fluid of all participants, in agreement with the literature (19). IL-1 $\beta$  is physiologically present in the crevicular fluid of healthy sites (31) but there are several factors underlying the induction of IL-1 $\beta$  that may affect its production, including an inflammatory response. The regulation of IL-1 $\beta$  expression can occur at different stages of protein synthesis, from gene modulation to transcription, translation, maturation and secretion of IL-1 $\beta$  (32,33). We were particularly interested in IL-1 $\beta$  because it is a powerful proinflammatory cytokine that is known to influence the response of periodontal tissues to environmental stimuli. It is produced mainly by macrophages, but also by other cells, including neutrophils, keratinocytes and gingival fibroblasts, stimulated by immune-inducing agents such as bacterial lipopolysaccharide, endotoxins derived from gram-negative microorganisms and products of tissue degradation (34,35). It can also trigger a mechanism of amplification by inducing its own gene expression (36). IL-1 $\beta$  can activate endothelial cells to increase the diapedesis of leukocytes, stimulating the expression of intercellular adhesion molecule-1 (ICAM-1) and selectins (37). It is also directly involved in the mechanisms of periodontal destruction, whether through fibroblast stimulation to produce prostaglandin E2 (38), collagenase and matrix metalloproteinases (39), or by osteoclast proliferation and activation (40).

The sites subjected to bilaminar surgery showed an average amount of IL-1 $\beta$  significantly higher than control sites at baseline, although there were no differences regarding clinical indexes. This result shows that the grafted areas, despite having reached the criteria for

clinical and aesthetic success, had biomolecular alterations compared to untreated sites. This might be due to different histological characteristics of the grafted mucosa: for instance, vestibular gingiva is characterized by a submucosal membrane, which contains fat cells and glandular bodies, all elements that are absent in the palatal mucosa; the latter is characterized by a dense and inelastic connective that blends with the periosteum and is rich in fibroblasts (9). Therefore, it is possible that the excess of IL-1 $\beta$  originates from the grafted fibroblasts, which are able to produce IL-1 $\beta$  and are enriched in the SCTG (41,42). Additionally, the increased amount of IL-1 $\beta$  in gingival crevicular fluid may have created a greater osmotic gradient that drew fluids in the gingival sulcus (43), which could explain the higher gingival crevicular fluid volume found in the treated sites at baseline. In turn, this increase in crevicular fluid might be linked to the introduction of medium and large caliber vessels derived from palate, originally not present in the vestibular gingiva.

After oral house hygiene was suspended for 14 d, both groups showed a statistically significant increase of all parameters. The result clearly showed that, in agreement with studies conducted over the years, plaque accumulation causes the onset of clinical signs of inflammation, increased gingival crevicular fluid volume, and increase of the concentration of proinflammatory cytokines (14,44,45).

Although at baseline, the test sites were associated with higher biomolecular values regarding gingival crevicular fluid volume and the amount of IL-1 $\beta$ , at the end of the experiment control and test sites reached the same quantity of IL-1 $\beta$  (32); this might either indicate a maximum plateau of secretion linked to interleukin-dependent feedback mechanisms, or an increased responsiveness of healthy gingival to plaque accumulation, compared with grafted tissues.



At the end of experiment, the GI and AngBS appeared statistically higher in control sites. This clinical evidence, taken together with histological and immunohistochemical data that show loss of vasomotor control due to a decrease in nerve fibers in grafted tissues (13), suggest that an attenuated clinical inflammatory response in grafts may be due to an alteration of the mechanisms of “neurogenic inflammation” (46). The results can be linked to our previous data where alteration of sensation in tissue grafts was associated with an increased amount of free Merkel cells. Specifically, Merkel cells were absent in normal gingival samples but were present in the palatal donor sites, together with a reduction in nerva vasorum (13); these data came together with sensorial alteration of the patient when the grafted mucosa was challenged. We believe that these findings can be related to the differences in terms of gingival crevicular fluid and IL-1 $\beta$  observed in the present study. In other words, reduction of neurogenic inflammation may account for a compromised vasodilatation, which, in turn, limits the responsiveness to plaque accumulation in grafted tissues. In view of our recent data demonstrating the production of corticosteroids by fibroblasts (47), including those from the gingival mucosa (48), it is also possible that the grafted tissue produces higher levels of cortisol thus modulating the local immune response. Further studies are needed to address these hypotheses.

### **Conclusion**

Collectively, analysis of the data demonstrates that the sites of gingival recession treated with SCTG develop a lower degree of plaque-induced inflammation compared to healthy gingivae. It is speculated that the presence of larger amounts of connective tissue in gingival mucosa becomes a protective factor for bacterial invasion, possibly by limiting the inflammatory

response or by inducing a more effective host response. Overall, the sites treated with the bilaminar technique retain, after 12 mo, biomolecular and sensorial alterations that will deserve further investigation.

## References

1. Maynard JG Jr, Wilson RD. Physiologic dimensions of the periodontium significant to the restorative dentist. *J Periodontol* 1974;**50**:170-174.
2. Miller PD. A classification of marginal tissue recession. *Int J Periodontics Restorative Dent* 1985;**5**:8-13.
3. American Academy of periodontology. Consensus report on mucogingival therapy. Proceedings of the World Workshop on Periodontics. *Annals of Periodontology* 1996;**1**:702-706.
4. Chambrone L, Sukekava F, Araújo MG, Pustiglioni FE, Chambrone LA, Lima LA. Root-coverage procedures for the treatment of localized recession-type defects: a Cochrane systematic review. *J Periodontol* 2010;**81(4)**:452-78.
5. Langer B, Langer L. Subepithelial tissue graft technique for root coverage. *J Periodontol* 1985;**56**:715-720.
6. Bruno JF. Connective tissue graft technique assuring wide root coverage. *Int J Periodontics Restorative Dent* 1994;**14(2)**:126-37.
7. Sedon CL, Breault LG, Covington LL, Bishop BG. The Subepithelial Connective Tissue Graft: Part II. Histologic Healing and Clinical Root Coverage. *J Contemp Dent Pract* 2005;**(6)2**:139-150.

8. McGuire M, Cochran DL. Evaluation of human recession defects treated with coronally advanced flaps and either enamel matrix derivative or connective tissue. Part 2: histological evaluation. *J Periodontol* 2003;**74**:1126-1135.
9. Tonge CH, Luke DA. Dental anatomy: the palate. *Dent Update* 1985;**12(8)**:461-2, 464, 466-7.
10. Bouchard P, Malet J, Borghetti A. Decision-making in aesthetics: root coverage revisited. *Periodontology 2000* 2001;**27**:97-120.
11. Cairo F, Rotundo R, Miller PD, Pini-Prato GP. Root coverage esthetic score: a system to evaluate the esthetic outcome of the treatment of gingival recession through evaluation of clinical cases. *Journal of Clinical Periodontology* 2009;**80**:705-710.
12. Miller PD. Regenerative and reconstructive periodontal plastic surgery. *Dent Clin North Am* 1988;**32**:287-306.
13. Aimetti M, Romano F, Cricenti L, Perotto S, Gotti S, Panzica G, Graziano A. Merkel cells and permanent disesthesia in the oral mucosa after soft tissue grafts. *J Cell Physiol* 2010;**224**:205-209.
14. Loe H, Theilade E, Jensen SB. Experimental gingivitis in man. *Journal of Periodontology* 1965;**36**:177-187.
15. Greenstein G, Caton J, Polson AM. Histologic characteristics associated with bleeding after probing and visual signs of inflammation. *J Periodontol* 1981;**52**:420-425.
16. Hancock EB, Cray RJO, O'Leary TJ. The relationship between gingival crevicular fluid and gingival inflammation. A clinical and histologic study. *J Periodontol* 1979;**50**:13-19.
17. Mariotti A. Dental plaque-induced gingival diseases. *Annals of Periodontology* 1999;**4**:7-19.

18. Page RC, Schroeder HE. Pathogenesis of inflammatory periodontal disease—a summary of current work. *Lab Invest* 1976;**3**:235-239.
19. Preiss DS, Meyle J. Interleukin-1 beta concentration of gingival crevicular fluid. *J Periodontol*. 1994;**65**(5):423-8.
20. Engebretson SP, Grbic JT, Singer R, Lamster IB. IL-1beta profiles in periodontal disease *Journal of Clinical Periodontology* 2002;**29**:48-53.
21. Liu CM, Hou LT, Wong MY, Rossomando EF. Relationships between clinical parameters, interleukin 1B and histopathologic findings of gingival tissue in periodontitis patients. *Cytokine* 1996;**8**:161-167.
22. Orozco A, Gemmel E, Bickel M, Seymour GJ. Interleukin 1b, interleukin-12 and interleukin-18 levels in gingival fluid and serum of patients with gingivitis and periodontitis *Oral Microbiology Immunology* 2006;**21**:256-260.
23. Bergmann A, Deinzer R. Daytime variations of interleukin-1 $\beta$  in gingival crevicular fluid. *Eur J Oral Sci* 2008;**116**:18-22.
24. Gonzáles JR, Herrmann JM, Boedeker RH, Francz PI, Biesalski H, Meyle J. Concentration of interleukin-1b and neutrophil elastase activity in gingival crevicular fluid during experimental gingivitis. *J Clin Periodontol* 2008;**28**:544-549.
25. Trombelli L, Tatakis DN, Scapoli C, Bottega S, Orlandini E, Tosi M. Modulation of clinical expression of plaque-induced gingivitis. II. Identification of “highresponder” and “low-responder” subjects. *J Clin Periodontol* 2004;**31**:239-252.
26. Løe H, Theilade E, Jensen SB, Schiott CR. Experimental gingivitis in man. 3. Influence of antibiotics on gingival plaque development. *Journal of Periodontal Research* 1967;**2**:282-289.

27. Silness J, Løe H. Periodontal disease in pregnancy. II. Correlation between oral hygiene and periodontal condition. *Acta Odontologica Scandinavica* 1964;**22**:121-135.
28. Fransson C, Mooney J, Kinane DF, Berglundh T. Differences in the inflammatory response in young and old human subjects during the course of experimental gingivitis. *Journal of Clinical Periodontology* 1999;**26**:453-460.
29. Van der Weijden GA, Timmerman MF, Nijboer A, Reijerse E, van der Velden U. Comparison of different approaches to assess bleeding on probing as indicators of gingivitis. *Journal of Clinical Periodontology* 1994;**21**:589-594.
30. Ciantar M, Caruana DJ. Periotron 8000: calibration characteristics and reliability. *J Periodont Res* 1998;**33**:259-264.
31. Payne WA, Page RC, Ogilvie AL, Hall WB. Histopathologic features of the initial and early stages of experimental gingivitis in man. *Journal of Periodontal Research* 1975;**10**:51-64.
32. Dinarello CA. Interleukin-1. *Dig Dis Sci* 1988;**33(3 Suppl)**:25S-35S.
33. Dinarello CA. Immunological and inflammatory functions of the interleukin-1 family. Review. *Annu Rev Immunol.*2009;**27**:519-50.
34. Hanazawa S, Hirose K, Ohmori Y, Amano S, Kitano S. Bacteroides gingivalis fimbriae stimulate production of thymocyte-activating factor by human gingival fibroblasts. *Infection and Immunity* 1988;**53**:272-274.
35. Lindemann RA, Economou JS, Rothermel H. Production of interleukin-1 and tumor necrosis factor by human peripheral monocytes activated by periodontal bacteria and extracted lipopolysaccharides. *J Dent Res* 1988;**67**:1131-1135.

36. Dinarello CA, Ikejima T, Warner SJ, Orencole SF, Lonnemann G, Cannon JG. & Libby P. Interleukin 1 induces interleukin 1. I. Induction of circulating interleukin 1 in rabbits in vivo and in human mononuclear cells in vitro. *J Immunol* 1987;**139**:1902-1910
37. Bevilacqua MP, Pober JS, Wheeler ME, Cotran RS, Gimbrone MA Jr. Interleukin-1 activation of vascular endothelium: effects on procoagulant activity and leukocyte adhesion. *Am J Pathol* 1985;**121**:394-403.
38. Richards D, Rutherford RB. The effects of interleukin 1 on collagenolytic activity and prostaglandin-E secretion by human periodontal-ligament and gingival fibroblast. *Arch Oral Biol* 1988;**33**:237-243.
39. Birkedal-Hansen H. Role of matrix metalloproteinases in human periodontal diseases. *J Periodontol* 1993;**64**:474-484.
40. Tatakis DN. Interleukin-1 and bone metabolism: A review. *J Periodontol* 1993;**64**:416-431.
41. Ohmori Y, Hanazawa S, Amano S, Miyoshi T, Hirose K, Kitano S. Spontaneous production of thymocyte-activating factor by human gingival fibroblasts and its autoregulatory effect on their proliferation. *Infect Immun.* 1987;**55**(4):947-54.
42. Smith RS, Smith TJ, Blieden TM, Phipps RP. Fibroblasts as sentinel cells. Synthesis of chemokines and regulation of inflammation. Review. *Am J Pathol.* 1997;**151**(2):317-22.
43. Del Fabbro M, Galardi E, Weinstein R, Bulfamante G, Miserocchi G. Fluid dynamics of gingival tissues. *J Periodont Res* 1998;**33**:328-334
44. Heasman PA, Collins JG, Offenbacher S. Changes in crevicular fluid levels of interleukin-1 beta, leukotriene B4, prostaglandin E2, thromboxane B2 and tumour

- necrosis factor alpha in experimental gingivitis in humans. *Journal of Periodontal Research* 1993;**28**:241-247.
45. Kinane DF, Winstanley FP, Adonogianaki E, Moughal NA. Bioassay of interleukin 1 (IL-1) in human gingival crevicular fluid during experimental gingivitis. *Archives of Oral Biology* 1992;**37**:153-156.
46. Holzer P. Neurogenic vasodilatation and plasma leakage in the skin. *Gen Pharmac* 1998;**30**:5-11.
47. Cirillo N, Prime SS. Keratinocytes synthesize and activate cortisol. *J Cell Biochem* 2011;**112**:1499–1505.
48. Cirillo N, Hassona Y, Pignatelli M, Gasparoto TH, Morgan MJ, Prime SS. Characterization of a novel oral glucocorticoid system and its possible role in disease. *J Dent Res* 2012;**91**:97-103.

*Table 1.* Clinical indexes (Mean ± SD) at baseline and 14 days after experimental gingivitis in sites treated with bilaminar technique (Test) and in periodontal healthy sites (Control)

Clinical indexes	Test		Control	
	Baseline	14 days	Baseline	14 days
GI	0,00 ± 0,00	1,05 ± 0,23 <sup>a</sup>	0,00 ± 0,00	1,34 ± 0,47 <sup>a,b</sup>
PII	0,13 ± 0,33	2,42 ± 0,61 <sup>a</sup>	0,05 ± 0,16	2,42 ± 0,61 <sup>a</sup>
AngBS	0,13 ± 0,28	0,34 ± 0,37 <sup>a</sup>	0,24 ± 0,39	0,61 ± 0,39 <sup>a,b</sup>

AngBS, angulated bleeding score; GI, gingival index; PI, plaque index.

<sup>a</sup>Significantly different from baseline ( $p < 0,05$ ).

<sup>b</sup>Significantly different from test group ( $p < 0,05$ ).

*Table 2.* Biomolecular parameters (Mean ± SD) at baseline and 14 days after experimental gingivitis in sites treated with bilaminar technique (Test) and in periodontal healthy sites (Control)

Biomolecular parameters	Test		Control	
	Baseline	14 days	Baseline	14 days
GCF volume (µL)	0,24 ± 0,17	0,47 ± 0,27 <sup>a</sup>	0,18 ± 0,13 <sup>b</sup>	0,42 ± 0,21 <sup>a</sup>
IL-1β (pg/350µL)	19,87 ± 14,02	50,09 ± 26,04 <sup>a</sup>	15,53 ± 9,48 <sup>b</sup>	51,57 ± 38,73 <sup>a</sup>

<sup>a</sup>Significantly different from baseline ( $p < 0,05$ ).

<sup>b</sup>Significantly different from test group ( $p < 0,05$ ).



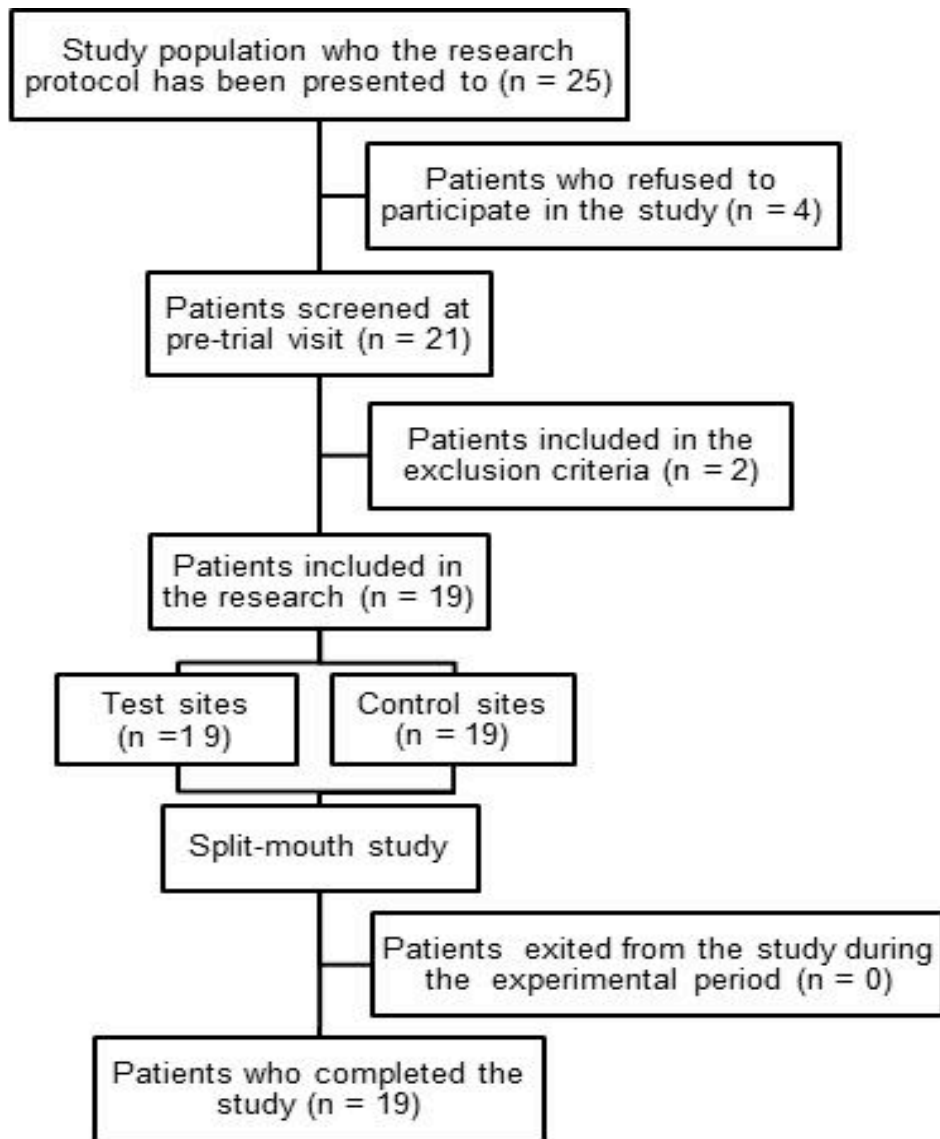
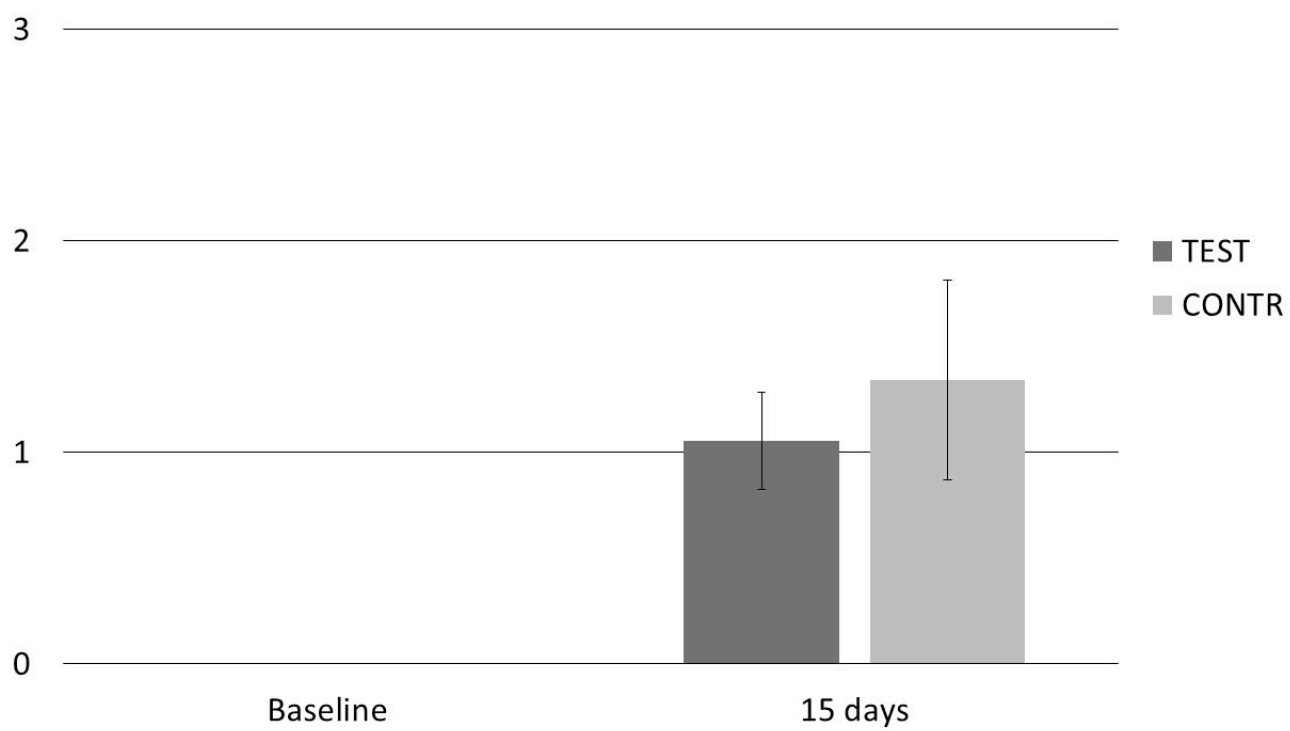
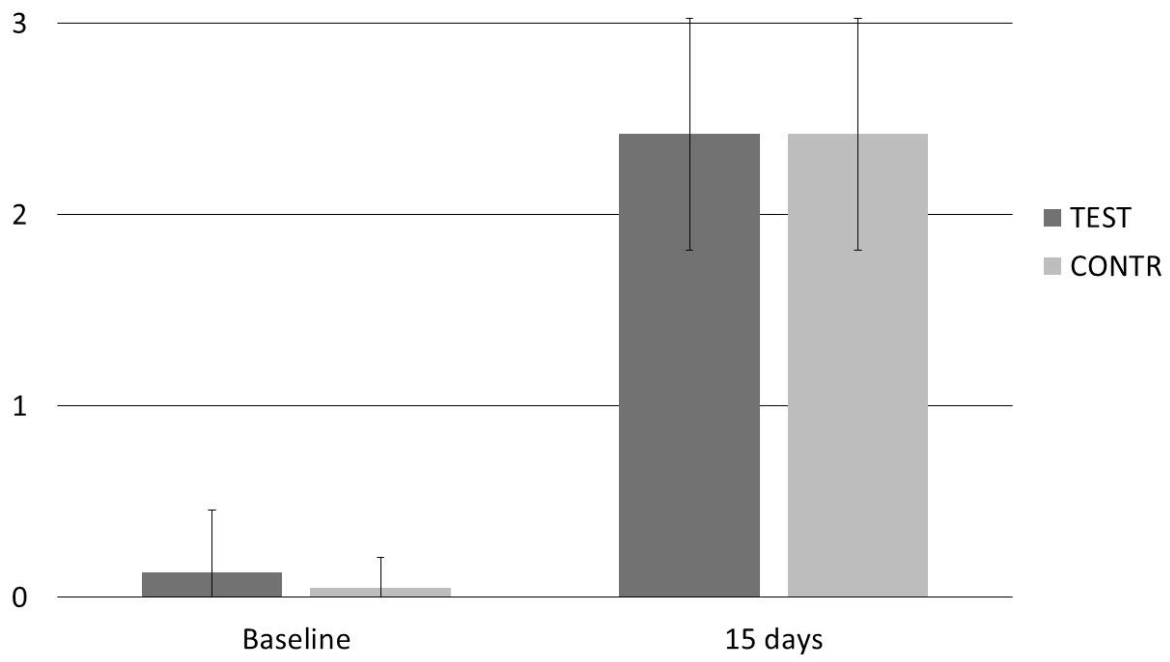


Fig. 1



*Fig. 2.*



*Fig. 3.*

2

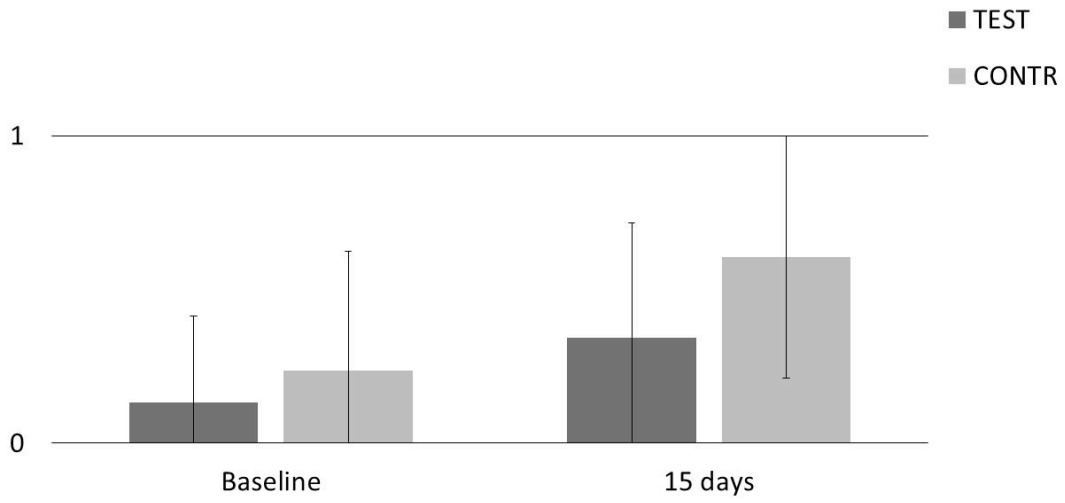


Fig. 4.

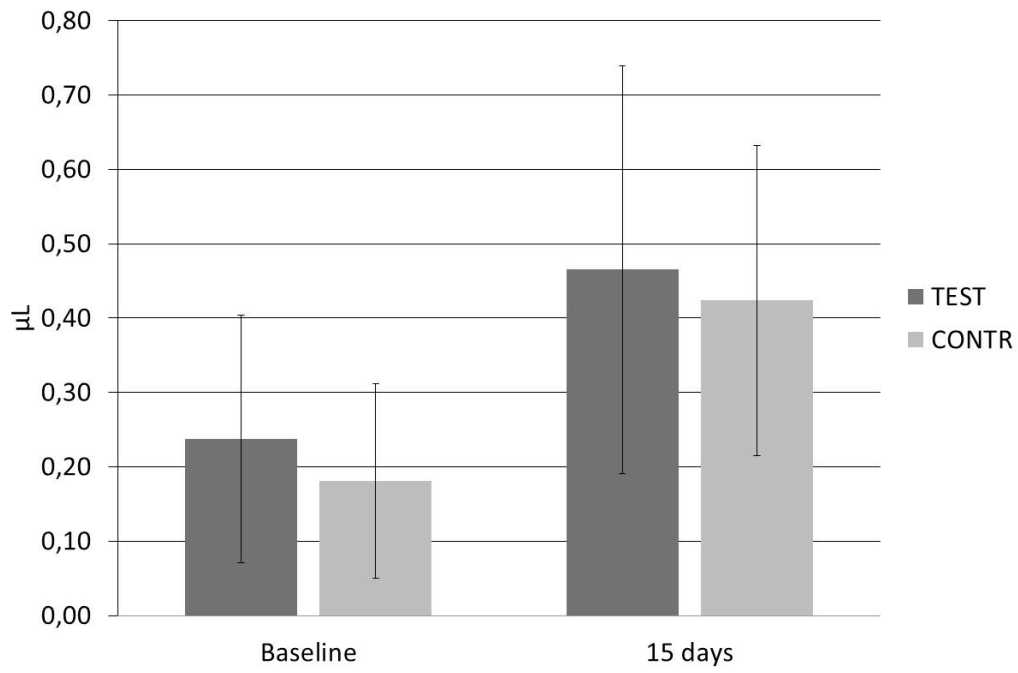


Fig. 5

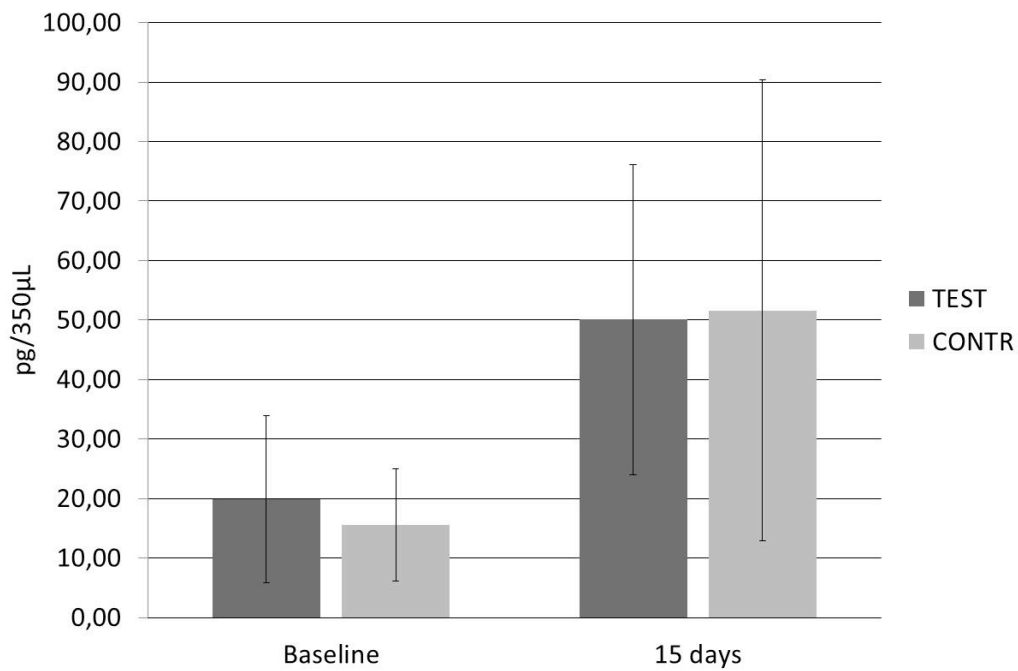


Fig. 6.

#### Legends

Figure 1: Flow chart

Figure 2: Histogram representing the trend of gingival index.

Figure 3: Histogram representing the trend of the plaque index

Figure 4: Histogram representing the trend of the angulated bleeding score

Figure 5: Histogram representing the trend of the gingival crevicular fluid volume (μL).

Figure 6: Histogram representing the trend of interleukin-1β concentration.