



# UNIVERSITÀ DEGLI STUDI DI TORINO

This is an author version of the contribution published on:

Questa è la versione dell'autore dell'opera:

[[J Cardiovasc Med \(Hagerstown\)](#). 2014 Aug;15(8):647-52. doi: 10.2459/JCM.000000000000144.]

The definitive version is available at:

La versione definitiva è disponibile alla URL:

[[http://journals.lww.com/jcardiovascularmedicine/Abstract/2014/08000/Left\\_persistent\\_superior\\_vena\\_cava\\_and\\_paroxysmal.7.aspx](http://journals.lww.com/jcardiovascularmedicine/Abstract/2014/08000/Left_persistent_superior_vena_cava_and_paroxysmal.7.aspx)]

**Left persistent superior vena cava and paroxysmal atrial fibrillation: the role of selective radiofrequency transcatheter ablation.**

Matteo Anselmino\*, MD, PhD, Federico Ferraris\*, MD, Natascia Cerrato\*, MD, Umberto Barbero\*, MD, Marco Scaglione#, MD and Fiorenzo Gaita\*, MD, Professor.

\*Division of Cardiology, Department of Medical Sciences, Città della Salute e della Scienza Hospital, University of Torino, Italy

# Division of Cardiology, Cardinal Massaia Hospital, Asti, Italy

Word count: 1,439 words, 1 table, 3 figures, and 26 references

Abstract word count: 82 words

Running title: transcatheter ablation of AF in left persistent superior vena cava

Corresponding author:

Fiorenzo Gaita, MD Professor

Cardiology Division, Department of Medical Sciences,

Città della Salute e della Scienza Hospital,

University of Turin

Corso Bramante 88, 10126 Turin, Italy

Phone: +39-011-6335570 Fax: +39-011-6966015

Email: [gaitaf@libero.it](mailto:gaitaf@libero.it); [fiorenzo.gaita@unito.it](mailto:fiorenzo.gaita@unito.it)

## **Abstract**

Persistent left superior vena cava (LPSVC) is a rare congenital anomaly of the thoracic venous system that can trigger paroxysmal atrial fibrillation (AF). The role of this venous anomaly must be carefully considered in patients undergoing conventional AF transcatheter ablation by pulmonary vein isolation to avoid unnecessary lesions, left atrium access and arrhythmia relapses. In fact, the present clinical perspective suggests sole LPSVC isolation as a safe and effective approach in patients with paroxysmal AF and arrhythmic trigger originating from a LPSVC.

## **Introduction**

Persistent left superior vena cava (LPSVC) results from the patency of the left cardinal vein which, rather than undergoing the embryological transformation into the ligament of Marshall, remains pervious and drains into a dilated coronary sinus (CS). The incidence of LPSVC has been reported between 0.1 and 3% in individuals with normal hearts<sup>1,2</sup> and candidates as the most common congenital anomaly of the thoracic venous system. In case of the presence of other congenital heart defects its prevalence raises to about 3%<sup>3</sup>. More rarely, in about 0.1% of the cases, instead, the presence of LPSVC is associated with the absence of the right SVC<sup>4</sup>.

LPSVC usually does not have direct hemodynamic significance: it is usually asymptomatic and detected when cardiovascular imaging is performed for concomitant reasons. However LPSVC has been identified as a potential trigger for paroxysmal atrial fibrillation (AF)<sup>5-6</sup>. Hsu et al.<sup>5</sup> suggested that, as a consequence of the unusual embryologic development, the LPSVC might be associated to the presence of muscular and pacemaker tissue, explaining the arrhythmogenicity originating from this vein.

Given these presumptions the role of this venous anomaly must be carefully considered in patients with paroxysmal AF and LPSVC in order to avoid arrhythmia recurrences in patients undergoing conventional AF transcatheter ablation.<sup>7</sup>

## **Clinical perspective**

Within more than 700 patients referred to our institution, between January 2010 and January 2013, for ablation of recurring episodes of paroxysmal AF refractory to antiarrhythmic drugs, two patients (A and B, clinical characteristics shown in Table 1) presented LPSVC and absence of the right SVC. Underlying structural heart disease had been ruled out through transthoracic echocardiography, except for the presence of an unusually dilated CS. Ejection fraction was

normal in both patients and left atria (LA) slightly enlarged. Pre-procedural transesophageal echocardiography also ruled out presence of LA thrombus.

Before the ablation procedure both patients underwent cardiac magnetic resonance (MRI) or computed tomography (CT) imaging, which confirmed the presence of a dilated CS due to draining of a LPSVC, the absence of the right SVC, and four separate pulmonary veins. Figure 1 illustrates the 3D-reconstruction of the LPSVC in patient A.

### *Atrial fibrillation ablation*

After written informed consent was obtained, a decapolar catheter (EzSteer, Biosense-Webster) was introduced through the inferior vena cava into the right atria and CS. An 8F circumferential decapolar catheter (Lasso, Biosense-Webster) was introduced through the CS towards the LPSVC. Electro-anatomic mapping (CARTO, Biosense-Webster) of the right atrium and LPSVC was performed by a 4 mm quadripolar catheter (NAVISTAR SF, Biosense-Webster) obtaining a 3-dimensional voltage map of the right atrium, CS and LPSVC (figure 2A) to merge with the 3D MRI/CT scans. Figure 2 illustrates the voltage-map of the right atrium, CS and LPSVC in patient A, showing voltages definitely referable to muscular tissue (high amplitude signals, above 1.5 mV) in the LPSVC portion adjacent to the LA and at the CS ostium.

In both patients, at these levels, during sinus rhythm, double potentials were recorded, composed by an initial far-field left atrial component followed by a rapid deflection due to the local LPSVC or CS potential. Clear confirmation of this signal interpretation was supported by reversing of this sequence during ectopies originating from the muscular portion within the vein (e.g. from the LPCVS of patient A in Figure 3). Advancing the circumferential mapping catheter further distally into the LPSVC, far from the left atrium far-field and in the normally low voltage vein area, obtained instead disappearance of any local potential.

In both patients ablation was performed by a 4-mm irrigated-tip catheter (flow-rate 17 mL/min). Radiofrequency (RF) was set to temperature control (maximum 45° C) and power limited to 20W, and performed at the double potential sites presenting muscular voltage values. These sites, in both patients, were found within the LPSVC at an upper level, more or less corresponding to the left atrial roof, and at a lower level, within the CS towards the connection to the LPSVC (Figure 2). Ablation was started by focal radiofrequency at the sites presenting high amplitude muscular voltages and double potentials, as those more likely representing the area of LPSVC-CS connection, and subsequently the entire LPSVC was isolated to minimize the possibility of reconnections (Figure 2, right side: ablation points indicated by red dots). During ablation, since circumflex coronary artery is closely located to the proximal part of the LPSVC, clinical symptoms and ECG were carefully monitored.

Effective disconnection was eventually demonstrated by disappearance of venous potentials on the mapping catheter and exit block (pacing 10 mA at 2.0 ms) from the LPSVC and subsequently the CS (Figure 3). No acute complications occurred during the procedures and both patients were discharged the day following the procedure without antiarrhythmic therapy, while oral anticoagulants were continued for 90 days after the ablation.

Both patients underwent 12-lead electrocardiogram and 24-hour Holter monitoring at 1, 3 and 6 months after the procedure and every 6 months thereafter. After 14 and 50 months of follow-up, respectively, both patients were asymptomatic and in sinus rhythm.

## Discussion

Since the first studies on atrial fibrillation ablation published in 1995 on an animal model,<sup>8,9</sup> and the first experiences on humans performed by the cardiac surgeons,<sup>9,10</sup> atrial fibrillation ablation has undergone an impetuous advance achieving, by percutaneous transcatheter approach,

satisfactory safety and long-term efficacy results<sup>12</sup>. Mimicking the above mentioned experiences, extensive linear lesions to modify atrial fibrillation substrate represented the goal of transcatheter atrial fibrillation ablation procedures<sup>13-16</sup> until the milestone study of Haissaguerre et al. in 1998<sup>17</sup>. In this study ectopic foci initiating AF were demonstrated within the pulmonary veins. Therefore, the ablation strategy changed from substrate modification by maze-like linear lesions in the atria to isolation of the trigger originating from the pulmonary veins, with extremely favourable results in both paroxysmal and persistent AF (respectively 15% and 32% of recurrences at 10-year follow-up) and very low complications rate (0.8%).<sup>18-20</sup>

Other triggers than the pulmonary veins cannot, however, be excluded. In fact, a more aggressive trigger elimination approach including pulmonary veins, SVC and CS isolation increased, in single experiences, success rates up to 95% after 1 year follow-up.<sup>21</sup> More recently, in a study by Corrado et al<sup>22</sup>, systematic SVC isolation significantly improved, from 77% to 90%, the efficacy of AF ablation only within patients with paroxysmal AF, confirming the theory that trigger isolation alone is mostly effective in paroxysmal AF, while it has limited incremental benefit in case of persistent or permanent AF, where remodelling has occurred requiring more extensive substrate modification<sup>23</sup>.

Given that ectopic activity from the pulmonary veins is the most common AF trigger in paroxysmal AF, pulmonary vein isolation surely stands as the primary procedural endpoint for patients undergoing transcatheter ablation<sup>17</sup>. This approach may, however, not be ideal in patients, although rare, presenting LPSVC, especially if vein potentials are demonstrated during the electrophysiology study<sup>24,25</sup>. Previous literature has, in fact, proposed LPSVC isolation in patients with this venous abnormality, however, in none of the previous experiences pulmonary vein isolation was avoided and LPSVC isolation was frequently performed only in case of unsuccessful pulmonary vein ablation<sup>5,24</sup>. **The innovative aspect of our work is, indeed, the**

different approach to this situation. In patients candidate for conventional transcatheter ablation of AF, in case the presence of a LPSVC is confirmed, at imaging performed before the procedure, and demonstrates to act as an active AF trigger, our opinion is that a limited focal ablation, aiming to isolate the LPSVC, should be considered as first choice strategy, leaving PV isolation as a second step in case of AF recurrences.

The evidence of high amplitude voltages referable to muscular tissue, associated to vein potentials detected on the mapping catheter, within the LPSVC, should guide ablation and provide procedural endpoint (vein isolation). In both our patients, the firing of the LPSVC was demonstrated by the evidence of a reversed activation sequence, as compared to sinus rhythm, during ectopies. This is illustrated in Figure 3, panel A, where the electrograms of the circumferential catheter (PV 1-10) are shown. During ectopies there is an initial rapid deflection due to the local LPSVC activation followed by a far-field left atrial component (Figure 3, black arrow). In sinus rhythm, the sequence of the potentials recorded in the same position (within the LPSVC) is an initial far-field left atrial component followed by a rapid deflection due to the local LPSVC potential (left side of figure 3, panel A). This reversed activation sequence demonstrates ectopic beat origin from LPSVC. Interestingly the areas involved within the LPSVC at an upper level, more or less corresponding to the left atrial roof, and within the CS towards the connection to the LPSVC, have been consistently described,<sup>5,6,24-26</sup> suggesting the possibility to recommend the aforementioned approach as a standard ablation protocol. Given the high possibility that patients with paroxysmal AF and LPSVC would, in our opinion, not concomitantly present triggers from the pulmonary veins, isolation of the sole LPSVC, as here successfully performed in two patients, surely holds some advantages. The lesions are limited and, besides avoiding AF relapses, the approach we suggest has the relevant potential to avoid unnecessary access to the left atrium, reducing consequent well-known transeptal puncture-related risks and embolic



**complications.** In addition, procedure duration, fluoroscopy and ablation time consequently are reduced. On the other side, delivering RF within a venous structure, although in areas with voltages referable to muscular tissue, requires cautiousness. LPSVC stenosis, to date never reported, could indeed be a serious complication being this structure the only outlet for superior systemic drainage. In addition, cardiac tamponade, left phrenic nerve paralysis, and circumflex coronary artery lesions, due to their anatomical proximity to the mid and distal portion of the LPSVC, should carefully be kept in mind<sup>24</sup>.

Eventually although a minimum period of 14 months in absence of antiarrhythmic drugs, the present follow-up may not permit conclusive results.

## **Conclusion**

LPSVC is a rare congenital anomaly of the thoracic venous system that can trigger paroxysmal AF. The role of this venous anomaly must be carefully considered in patients undergoing conventional AF transcatheter ablation by pulmonary vein isolation to avoid unnecessary lesions, left atrium access and arrhythmia relapses. In fact, the present clinical perspective suggests that sole LPSVC isolation **may be a safe and effective approach and, therefore, considered as first choice strategy**, in patients with paroxysmal AF and arrhythmic trigger originating from a LPSVC.

## References

1. Leibowitz AB, Halpern NA, Lee MH, Iberti TJ. Left-sided superior vena cava: a not-so-unusual vascular anomaly discovered during central venous and pulmonary artery catheterization. *Crit Care Med* 1992;**20**:1119-1122
2. Morgan DR, Hanratty CG, Dixon LJ, Trimble M, O’Keeffe DB. Anomalies of cardiac venous drainage associated with abnormalities of cardiac conduction system. *Europace* 2002;**4**:281-287
3. Perles Z, Nir A, Gavri S, et al. Prevalence of Persistent Superior Vena Cava and Association With Congenital Heart Anomalies. *Am J Cardiol* 2013;**112**:1214-1218
4. Pugliese P, Murzi B, Aliboni M, Eufrate S. Absent right superior vena cava and persistent left superior vena cava: Clinical and surgical considerations. *J Cardiovasc Surg (Torino)* 1984;**25**:134–137
5. Hsu LF, Jaïs P, Keane D, et al. Atrial fibrillation originating from persistent left superior vena cava. *Circulation* 2004;**109**:828-832
6. Gomez-Pulido F, Arana-Rueda E, Pedrote A. Atrial fibrillation ablation in a patient with absent right superior and persistent left superior vena cava. *Europace*; 2013 Oct 17 [Epub ahead of print]
7. Elayi CS, Fahmy TS, Wazni OM, Patel D, Saliba W, Natale A. Left superior vena cava isolation in patients undergoing pulmonary vein antrum isolation: Impact on atrial fibrillation recurrence. *Heart Rhythm* 2006;**3**:1019 –1023
8. Morillo CA, Klein GJ, Jones DL, et al. Chronic rapid atrial pacing: structural, functional, and electrophysiological characteristics of a new model of sustained atrial fibrillation. *Circulation* 1995;**91**:1588–1595
9. Elvan A, Pride HP, Eble JN, et al. Radiofrequency catheter ablation of the atria reduces

- inducibility and duration of atrial fibrillation in dogs. *Circulation* 1995;**91**:2235–2244
10. Cox JL, Schuessler RB, Lappas DG, et al. An 8 1/2-year clinical experience with surgery for atrial fibrillation. *Ann Surg* 1996;**224**:267–273
  11. Gaita F, Riccardi R, Caponi D, et al. Linear cryoablation of the left atrium versus pulmonary vein cryoisolation in patients with permanent atrial fibrillation and valvular heart disease: correlation of electroanatomic mapping and long-term clinical results. *Circulation* 2005;**111**:136–142
  12. Anselmino M, D'Ascenzo F, Amoroso G, Ferraris F, Gaita F. History of transcatheter atrial fibrillation ablation. *J Cardiovasc Med* 2012;**13**:1–8
  13. Haissaguerre M, Gencel L, Fischer B, et al. Successful catheter ablation of atrial fibrillation. *J Cardiovasc Electrophysiol* 1994; 5:1045–1052
  14. Haissaguerre M, Jais P, Shah DC, et al. Right and left atrial radiofrequency catheter therapy of paroxysmal atrial fibrillation. *J Cardiovasc Electrophysiol* 1996;**7**:1132–1144
  15. Gaita F, Riccardi R, Lamberti F, et al. Vagal atrial fibrillation: atrial mapping and effectiveness of a right atrial catheter ablation. *Circulation* 1996;**94**(Suppl I):I-675
  16. Gaita F, Riccardi R, Calò L, et al. Atrial mapping and radiofrequency catheter ablation in patients with idiopathic atrial fibrillation. Electrophysiological findings and ablation results. *Circulation* 1998;**97**:2136–2145
  17. Haissaguerre M, Jais P, Shah DC, et al. Spontaneous initiation of atrial fibrillation by ectopic beats originating in the pulmonary veins. *N Engl J Med* 1998;**339**:659–666
  18. Pappone C, Oreto G, Lamberti F, et al. Catheter ablation of paroxysmal atrial fibrillation using a 3D mapping system. *Circulation* 1999;**100**:1203–1208;
  19. Pappone C, Oreto G, Rosanio S, et al. Atrial electroanatomic remodeling after circumferential radiofrequency pulmonary vein ablation: efficacy of an anatomic approach

- in a large cohort of patients with atrial fibrillation. *Circulation* 2001;**104**:2539–2547
20. Cappato R, Calkins H, Chen SA, et al. Updated worldwide survey on the methods, efficacy, and safety of catheter ablation for human atrial fibrillation. *Circ Arrhythm Electrophysiol* 2010;**3**:32–38
21. Haissaguerre M, Hocini M, Sanders P, et al. Catheter ablation of long-lasting persistent atrial fibrillation: clinical outcome and mechanisms of subsequent arrhythmias. *J Cardiovasc Electrophysiol* 2005;**16**:1138– 1147.
22. Corrado A, Bonso A, Madalosso M, et al. Impact of systematic isolation of superior vena cava in addition to pulmonary vein antrum isolation on the outcome of paroxysmal, persistent and permanent atrial fibrillation ablation: results from a randomized study. *J Cardiovasc Electrophysiol*. 2010;**21**:1-5
23. Gaita F, Riccardi R, Caponi D, et al. Linear cryoablation of the left atrium versus pulmonary vein cryoisolation in patients with permanent atrial fibrillation and valvular heart disease: correlation of electroanatomic mapping and long-term clinical results. *Circulation* 2005;**111**:136–142
24. Wissner E, Tilz R, Konstantinidou M, et al. Catheter ablation of atrial fibrillation in patients with persistent left superior vena cava is associated with major intraprocedural complications. *Heart Rhythm* 2007;**7**:1755–1760
25. Hwang C, Wu TJ, Doshi RN, et al. Vein of Marshall cannulation for the analysis of electrical activity in patients with focal atrial fibrillation. *Circulation* 2000;**101**:1503–1505
26. O'Neill MD, Jönsson A, Takahashi Y, et al. Epicardial Tachycardia Originating From a Persistent Left Superior Vena Cava. *Circulation* 2006;**114**:569-570

**Table 1.** Baseline characteristics and procedural outcome.

	<b>Patient A</b>	<b>Patient B</b>
<b>Age</b>	38	50
<b>Gender</b>	M	F
<b>AF type; max duration</b>	Paroxysmal; 6 hours	Paroxysmal; 10 hours
<b>AF starting by ectopy</b>	yes	yes
<b>CHA<sub>2</sub>DS<sub>2</sub>-Vasc</b>	0	1
<b>Left atrium volume (ml)</b>	86	72
<b>Ineffective drugs tested</b>	propafenone	propafenone, amiodarone
<b>Follow-up (months)</b>	14	50
<b>Documented recurrences <b>after</b> <b>ablation (without AADs)</b></b>	none	none

AF= atrial fibrillation; AADs= antiarrhythmic drugs

## Figure legends

1. Cardiac CT three-dimensional reconstruction of the heart of patient A: on the left side a posterior view of the heart, showing in blue the inferior vena cava (IVC), the giant coronary sinus (CS) and the left persistent superior vena cava (LPSVC); in light blue the posterior wall of the left atrium with the pulmonary veins (PV); in yellow the left ventricle (LV) and the aorta (Ao); in green the right ventricle with the trunk of pulmonary artery (PA). On the right side, an anterior view of the anatomic reconstruction of the right atrium (RA) with the giant coronary sinus, the LPSVC, the IVC and the anatomical remnants of the right superior vena cava (C).
2. Voltage-map of the right atrium, CS and LPSVC in patient A based on the electro-anatomic mapping system showing voltages definitely referable to muscular tissue (high amplitude signals, above 1.50 mV) in the LPSVC portion adjacent to the LA and at the CS. On the right figure, red dots tag, instead, ablation's sites.
3. *Panel A*: left persistent superior vena cava (LPSVC) potentials recorded during sinus rhythm (at the level of the upper line of ablation indicated in Figure 2) with evidence of double potential composed by an initial far-field left atrial component followed by a rapid deflection due to the local LPSVC. This sequence was reversed during ectopies originating from the muscular portion within the vein (black arrow). *Panel B*: Effective LPSVC isolation, demonstrated by disappearance of venous potentials on the mapping catheter (persistence of the far-field left atrial component only).

Figure 1.

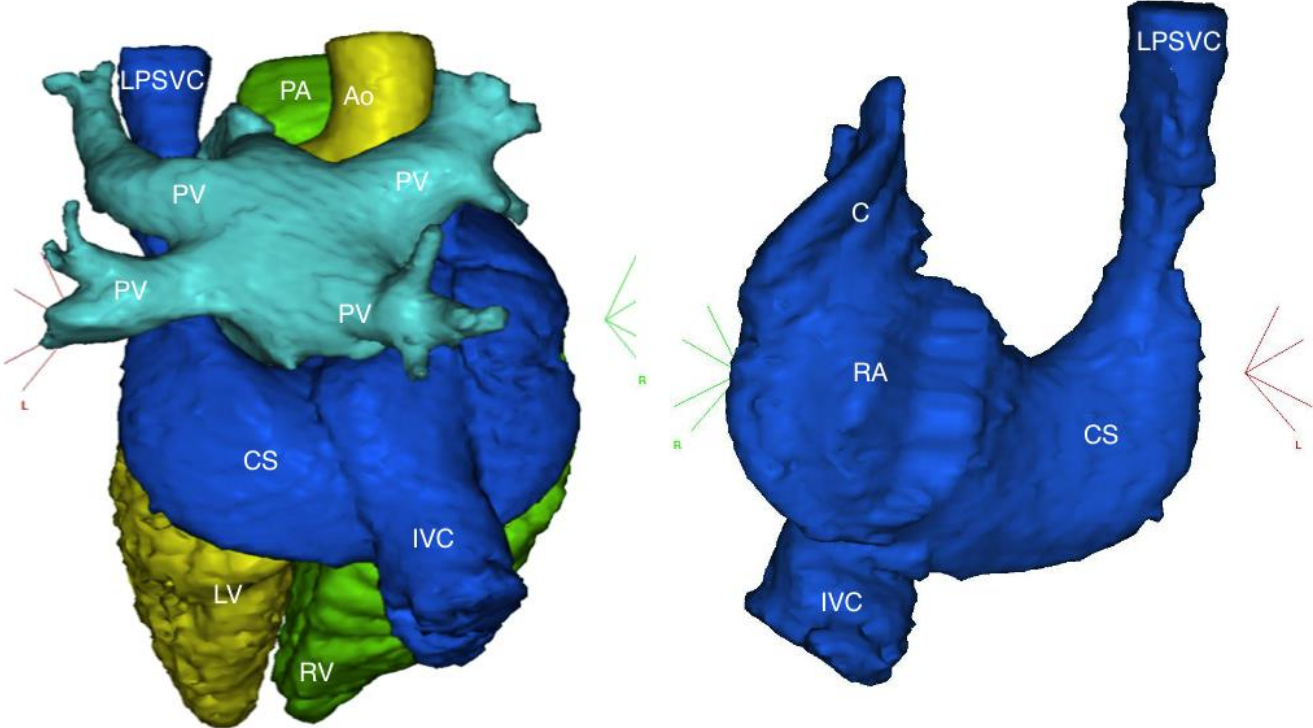


Figure 2.

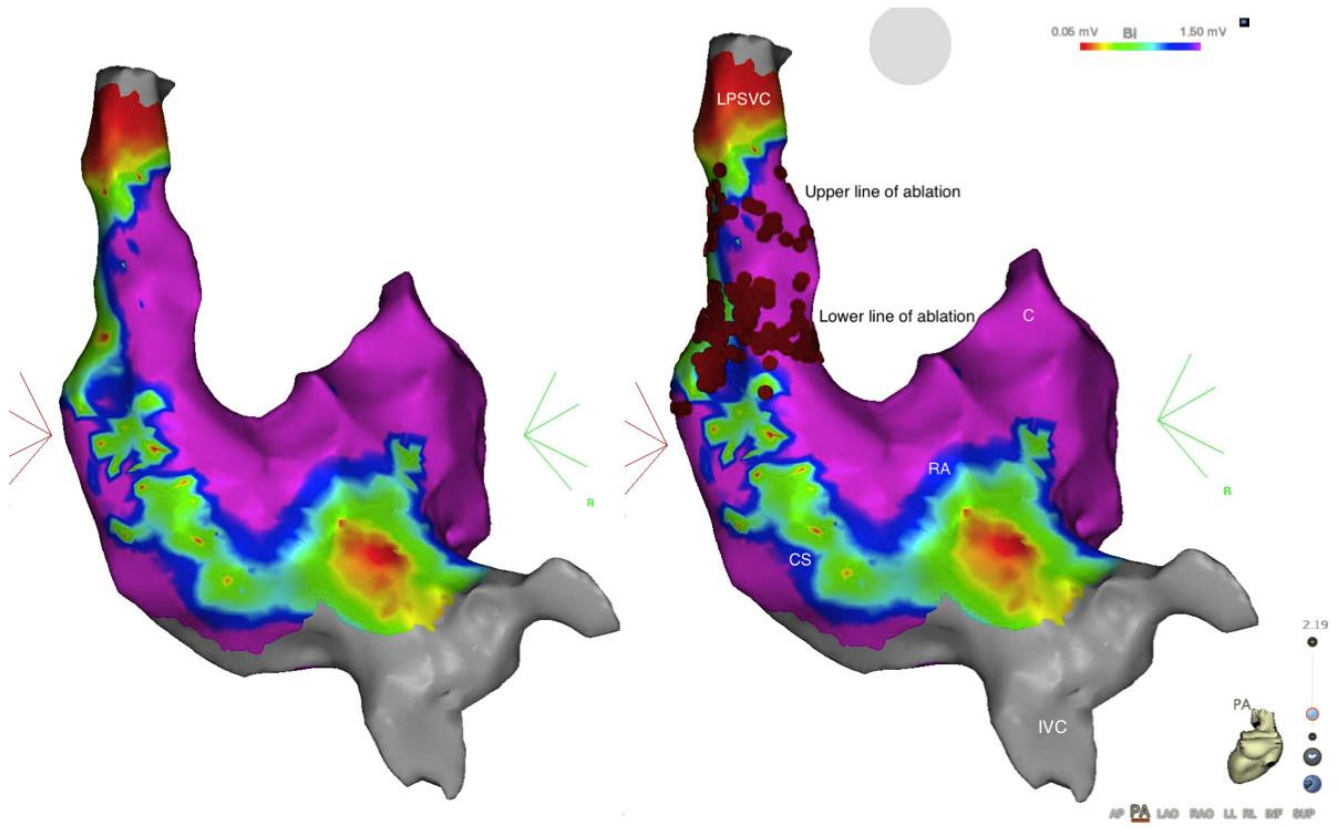




Figure 3.

