

The logo for IRIS AperTO, featuring the text "IRIS" in a large, white, serif font, "Aper" in a smaller, white, sans-serif font, and "TO" in a large, white, serif font, all set against a red rectangular background.

UNIVERSITÀ  
DEGLI STUDI  
DI TORINO

This is the author's final version of the contribution published as:

Provenzano A; Milani S; Vizzutti F; Delogu W; Navari N; Novo E; Maggiora M; Maurino V; Laffi G; Parola M; Marra F.. n-3 polyunsaturated fatty acids worsen inflammation and fibrosis in experimental nonalcoholic steatohepatitis.. LIVER INTERNATIONAL. 34 pp: 918-930.

DOI: 10.1111/liv.12500

The publisher's version is available at:

<http://doi.wiley.com/10.1111/liv.12500>

When citing, please refer to the published version.

Link to this full text:

<http://hdl.handle.net/2318/147457>

This full text was downloaded from iris - AperTO: <https://iris.unito.it/>

---

iris - AperTO

University of Turin's Institutional Research Information System and Open Access Institutional Repository

# **n-3 polyunsaturated fatty acids worsen inflammation and fibrosis in experimental nonalcoholic steatohepatitis**

Angela Provenzano<sup>1</sup>, Stefano Milani<sup>2,3</sup>, Francesco Vizzutti<sup>1</sup>, Wanda Delogu<sup>1</sup>, Nadia Navari<sup>1</sup>, Erica Novo<sup>4</sup>, Marina Maggiora<sup>4</sup>, Valter Maurino<sup>5</sup>, Giacomo Laffi<sup>1</sup>, Maurizio Parola<sup>4</sup> and Fabio Marra<sup>1,3</sup>

<sup>1</sup> Dipartimento di Medicina Sperimentale e Clinica, University of Florence, Florence, Italy

<sup>2</sup> Dipartimento di Scienze Biomediche, Cliniche e Sperimentali, University of Florence, Florence, Italy

<sup>3</sup> Center for Research, Transfer and Higher Education DenoTHE, University of Florence, Florence, Italy

<sup>4</sup> Dipartimento di Scienze Cliniche e Biologiche, University of Turin, Turin, Italy

<sup>5</sup> Dipartimento di Chimica, University of Turin, Turin, Italy

DOI: 10.1111/liv.12500

## **Abstract**

### **Background & Aims**

n-3 polyunsaturated fatty acids (PUFA) ameliorate fatty liver in experimental models, but their effects on inflammation and fibrosis during steatohepatitis are either controversial or lacking. We compared the effects of supplementation with olive oil (OO) alone or OO and n-3 PUFA on the development and progression of experimental steatohepatitis.

### **Methods**

Balb/C mice ( $\geq 5$  mice/group) were fed a methionine- and choline-deficient (MCD) diet or a control diet for 4 or 8 weeks. At the same time, mice were supplemented with n-3 PUFA (eicosapentaenoic and docosahexaenoic acid, 25 mg together with 75 mg OO), or OO alone (100 mg), two times a week by intragastric gavage.

### **Results**

After 8 weeks, mice on MCD/n-3 had higher ALT levels compared to MCD/OO and more severe scores of inflammation, including a significant increase in the number of lipogranulomas ( $26.4 \pm 8.4$  vs.  $5.1 \pm 5$  per field,  $P < 0.001$ ). Intrahepatic expression of TNF- $\alpha$  and CCL2 was higher in MCD/n-3 mice at both time points. In addition, increased expression of the profibrogenic genes TIMP-1 and TGF- $\beta$ , and more severe histological scores of fibrosis were evident in MCD/n-3 mice. After 8 week of MCD diet, portal pressure was higher in mice receiving n-3 than in those on OO

alone ( $5.1 \pm 1.4$  vs.  $7.0 \pm 0.9$  mmHg,  $P < 0.05$ ). Analysis of hepatic fatty acid profile showed that supplementation resulted in effective incorporation of n-3 PUFA.

## Conclusions

In a murine model of steatohepatitis, supplementation with n-3 PUFA and OO is associated with more severe necro-inflammation and fibrosis than in mice treated with OO only.

Nonalcoholic fatty liver disease (NAFLD) is the leading cause of chronic hepatic damage in Western countries [1]. The clinical implications of NAFLD are because of its common occurrence in the general population and its potential to progress to cirrhosis, liver failure and hepatocellular carcinoma [2]. Nonalcoholic steatohepatitis (NASH) is observed in a subset of patients with NAFLD and is characterized by lobular and portal inflammation, signs of hepatocellular damage such as ballooning, and development of fibrosis [3]. The causes of progression to steatohepatitis remain unclear, but lipotoxicity, oxidative stress and an imbalance in the pattern of pro- and anti-inflammatory cytokines are believed to play key roles [4, 5].

It is well established that excessive calorie consumption and obesity are risk factor for the development of NAFLD and its progression to fibrosis [1]. However, data on the role of different nutrients are scanty and often controversial, particularly with respect to the role of fatty acids. Studies in a population of NASH patients have shown a lower consumption of omega-3 polyunsaturated fatty acids (n-3 PUFA) compared to a control population [6]. n-3 PUFA are found naturally in fish oil, flaxseed and some nuts, and mainly occur as eicosapentaenoic acid (EPA) and docosahexaenoic acid (DHA), which generally have anti-inflammatory properties [7]. Moreover, docosahexaenoic acid (DHA) and eicosapentaenoic acid (EPA) have been associated with the prevention and treatment of cardiovascular, inflammatory and autoimmune diseases [8, 9].

Several lines of evidence support a possible beneficial role of n-3 PUFA in NAFLD (reviewed in Refs [10, 11]). On the one hand, n-3 PUFAs promote fatty acid oxidation by binding and activating peroxisome proliferator activated receptor  $\alpha$  (PPAR $\alpha$ ) [11]. On the other hand, n-3 PUFAs suppress lipogenesis by inhibiting sterol regulatory element binding protein-1c (SREBP-1c) expression [12], decrease hepatic oxidative stress [13] and suppress production of pro-inflammatory cytokines [14]. However, whether n-3 PUFA may have a positive effect on the development of NASH and fibrosis has not been fully clarified.

In this study, we analysed the effects of supplementation with two combinations of fatty acids, including OO alone or associated with n-3 PUFA, on the development of experimental nonalcoholic steatohepatitis caused by administration of a methionine- and choline-deficient (MCD) diet. Our data demonstrate that addition of n-3 PUFA results in enhanced inflammation and more severe development of fibrosis.

## Materials and methods

### Animals and protocol

Male Balb/C mice weighing between 20 and 25 g were purchased from Charles River Laboratories (Calco, Italy). All animals, 8 weeks of age at the beginning of this study, were housed four or five per cage and kept under a controlled temperature of  $22 \pm 2^\circ\text{C}$ , 50–60% relative humidity and 12 h

light/dark cycles. Mice had free access to food and water *ad libitum* and were weighed at weekly intervals throughout the experiment. Mice were fed either a high-fat diet deficient in methionine and choline (MCD diet, containing 58% of energy derived from fat, 18% from protein and 24% from carbohydrates, 5.6 kcal/g) or a control diet supplemented with methionine and choline (CD containing 5% of energy derived from fat, 18% from proteins and 77% from carbohydrates; 3.3 kcal/g). Diets were prepared by Dottori Piccioni Laboratories (Milan, Italy) and stored at 4°C until used. Experimental animals receiving the different diets were further subdivided to receive either n-3 PUFA (eicosapentenoic and docosahexaenoic acid, 25 mg, together with 75 mg OO) or 100 mg OO twice weekly by intragastric gavage. Fatty acids (Società Prodotti Antibiotici, Italy) were provided as oil in capsules. Before each administration, a new capsule was punctured with a syringe equipped with a fine needle and administered to animals. Four to eight animals were included in each experimental group (Cnt – OO, Cnt – n-3 PUFA, MCD – OO, MCD – n-3 PUFA).

Mice were euthanized at 4 or 8 weeks by exsanguination under anaesthesia with an i.p. injection of 80 mg/kg 50% tiletamine hydrochloride and 50% zolazepam hydrochloride (Virbac, Carros, France). Body weight was recorded and blood was collected from the inferior vena cava, centrifuged and serum stored for further analysis. Livers were rapidly dissected out, weighed, snap frozen in liquid nitrogen and kept at –80°C for RNA and protein extraction. A portion of the liver was immediately fixed in formalin for histological analyses. All animals received humane care, and experimental protocols were conducted according to established international guidelines (Guide for the Care and Use of Laboratory Animals, NIH publication No. 86-23) after approval by the local regulatory authorities.

### **Serum aminotransferase levels**

Blood samples were centrifuged at 1500g for 10 min at 4°C to obtain serum that was kept at –20°C until analysed. Serum amino transferase activity was determined using a commercially available kit (DiaSys Diagnostic Systems GmbH, Holzheim, Germany).

### **Liver histology**

A portion of liver tissue was fixed by immersion in 10% buffered formalin (pH 7.4) for 24 h. The fixed tissue was dehydrated in graded ethanol, paraffin embedded and sectioned at a thickness of 4 µm. Haematoxylin–eosin and Sirius Red stainings were performed as previously described [15] and liver histology was evaluated by an experienced hepatopathologist (S.M.) blinded to the type of treatment received by the animals. Necro-inflammation was graded focusing on zone 3 as 0 (absent), 1 (sparse or mild, focal), 2 (noticeable) and 3 (severe). In addition, the number of lipogranulomas was quantified separately. Quantification of fibrosis and steatosis was performed by histomorphometric analysis using a digital camera (DFC 320; Leica, Wetzlar, Germany) coupled to a bright field microscope (DM4000; Leica). Three randomly selected fields (×10 magnification) of haematoxylin–eosin or picrosirius red-stained liver slides (5 µm sections) were scored in three sections of each animal at a final magnification of ×100.

### **RNA isolation and quantitative PCR**

Total RNA from liver tissue was isolated with an RNeasy mini kit (Qiagen, Hilden, Germany), according to the manufacturer's instructions. Total RNA (5 µg) from each sample was reverse transcribed to complementary DNA (cDNA) using the SuperScript III first strand synthesis system (Invitrogen, Grand Island, NY, USA), according to the manufacturer's instructions. Hepatic mRNA gene expression was evaluated using quantitative real-time RT-PCR with glyceraldehyde-3-phosphate dehydrogenase (GAPDH) as housekeeping gene. Quantitative real-time RT-PCR and

analysis were performed using a Corbett Rotorgene 6600 analyzer (Corbett Life Science, Sydney, Australia). FAM-labelled probes and specific primers were obtained as Assays-on-Demand (Applied Biosystems, Foster City, CA, USA). Relative gene expression was calculated as  $2^{-\Delta C_t}$  ( $\Delta C_t = C_t$  of the target gene minus  $C_t$  of GAPDH). A list of the primers used in this study is reported in Table S1.

## Determination of oxidative stress in liver tissue

Intrahepatic levels of 8-hydroxy-2-deoxyguanosine (8-OHdG), a well-established marker of oxidative DNA damage [16] were determined by immunohistochemistry as previously described [17]. Morphometric assessment was performed using an optic microscope (Eclipse E600; Nikon, Tokyo, Japan) connected to a high-resolution camera (CC12 Soft-Imaging System, Münster, Germany).

## Measurement of portal pressure

After 8 weeks of treatment, the portal vein of anaesthetized mice was cannulated through an ileocolic vein with a PE-10 catheter. This catheter was connected to a highly sensitive pressure transducer, and blood pressure was registered on multichannel recorder.

## Analysis of the hepatic fatty acid profile

Liver tissue was suspended in 0.25 M sucrose, 20 mM Tris HCl, pH 7.4 (1:2.5 w/v), homogenized with a Ultra-Turrax homogenizer (IKA, Milan, Italy) and finally diluted to 10% (v:v) with the same solvent. Total lipids were recovered from homogenate aliquots containing 15 mg of protein using chloroform–methanol (2:1) with the addition of 0.01% 2,6-Di-ter-butyl-4-methylphenol as antioxidant [18].

Lipid extracts were spiked with 50 µg of margaric acid methyl ester (C 17:0) as internal standard, and fatty acid methyl esters were prepared following the method of Metcalfe *et al.* [19]. After methylation, fatty acid methyl esters were redissolved in a 1:10 (v/v) ether:chloroform solution.

Fatty acid methyl ester analysis was performed with an Agilent 6890A gas chromatograph equipped with a quadrupole mass spectrometer (Agilent 5973) and a CP-Wax 52 CB capillary column (30 metre length, 0.32 mm ID, 0.5 µm phase thickness, Agilent). Operating conditions were as follows: carrier He at 2 ml/min, Inlet 260°C, splitless injection with pulsed pressure (14 psi for 1 min), injected volume 1 µl. Column oven was at 50°C for 2 min, then to 200°C at 20°C/min, then to 230°C at 3°C/min. Mass spectrometer was operated in scan mode (29–400 Th). Peaks were identified by comparison of retention times and mass spectra with known fatty acid methyl ester standards and are expressed as percentage of total fatty acids.

## Statistical analysis

Unless stated otherwise, data are expressed as mean ± SD. Comparisons of animals treated with OO or n-3 PUFA and the effects of the MCD diet were performed by Student's *t*-test. Histological scores of inflammation and fibrosis were compared using the Mann–Whitney *U*-test. *P* values less than 0.05 were considered significant.

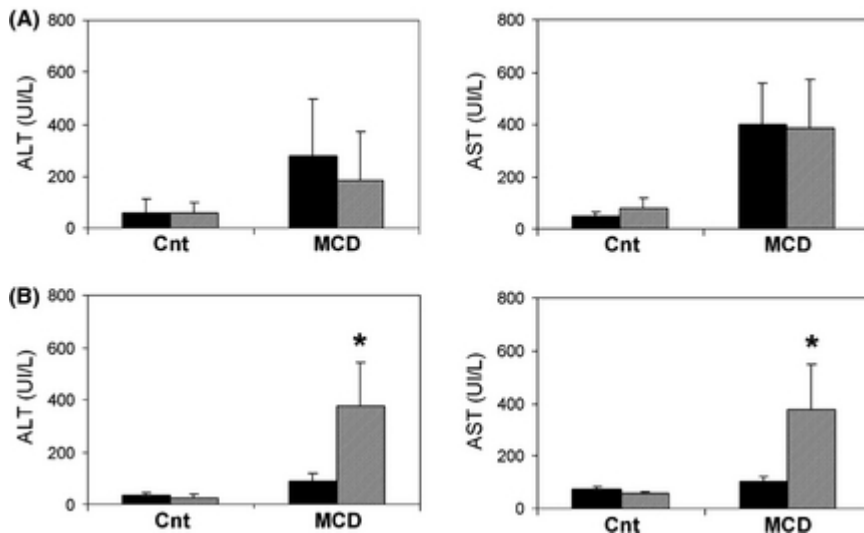
## Results

The MCD diet model is characterized by the rapid appearance (after 2-4 weeks) of steatosis, inflammation and cell death, which represent the cardinal features of steatohepatitis. After prolonged administration of the steatogenic diet (8 weeks), steatohepatitis is associated with fibrosis, which is localized predominantly in the perivenular area (zone 3 of the hepatic acinus). After 4 weeks of MCD diet administration, mice showed a marked decrease in body weight in comparison to animals fed the Cnt diet, as previously described in this model (Table 1). In mice treated with n-3 PUFA, liver weight was significantly higher than in those exposed to OO, resulting in a slight but significant increase in the liver/weight ratio. In contrast, after 8 weeks, body weight, liver weight and the liver/body weight ratio were all significantly reduced in MCD-n-3 mice as compared to MCD-OO. Only minor changes were associated with PUFA administration in mice receiving the Cnt diet.

Table 1. Body and liver weight during the experimental protocol

|  | Body weight (g)    | Liver weight (g)  | Liver/body weight (%) |
|--|--------------------|-------------------|-----------------------|
| 1. Mice were administered a methionine- and choline-deficient diet (MCD) or an identical diet supplemented with methionine and choline (CD) and treated with olive oil alone (OO) or together with an admixture of omega-3 fatty acids (n-3). At the time of sacrifice, body and liver weight were recorded. Data are mean $\pm$ SD. |                    |                   |                       |
| 2. * $P < 0.05$ vs. CD + OO; ** $P < 0.05$ vs. MCD + OO; *** $P = 0.07$ vs. MCD + OO.  |                    |                   |                       |
| 4 weeks  |                    |                   |                       |
| Cnt + OO   | 24.08 $\pm$ 2.44   | 1.65 $\pm$ 0.25   | 6.83 $\pm$ 0.39       |
| Cnt + n-3  | 23.4 $\pm$ 4.75    | 2.11 $\pm$ 0.11*  | 8.17 $\pm$ 0.15*      |
| MCD + OO   | 14.82 $\pm$ 1.52   | 1.11 $\pm$ 0.23   | 7.54 $\pm$ 1.72       |
| MCD + n-3  | 14.85 $\pm$ 0.78   | 1.28 $\pm$ 0.07** | 8.63 $\pm$ 0.62***    |
| 8 weeks  |                    |                   |                       |
| Cnt + OO   | 29.00 $\pm$ 1.73   | 1.52 $\pm$ 0.16   | 5.24 $\pm$ 0.24       |
| Cnt + n-3  | 28.67 $\pm$ 1.15   | 1.33 $\pm$ 0.06   | 4.64 $\pm$ 0.30*      |
| MCD + OO   | 16.40 $\pm$ 0.82   | 1.20 $\pm$ 0.23   | 7.28 $\pm$ 1.15       |
| MCD + n-3  | 13.29 $\pm$ 1.21** | 0.68 $\pm$ 0.12** | 5.14 $\pm$ 0.85**     |

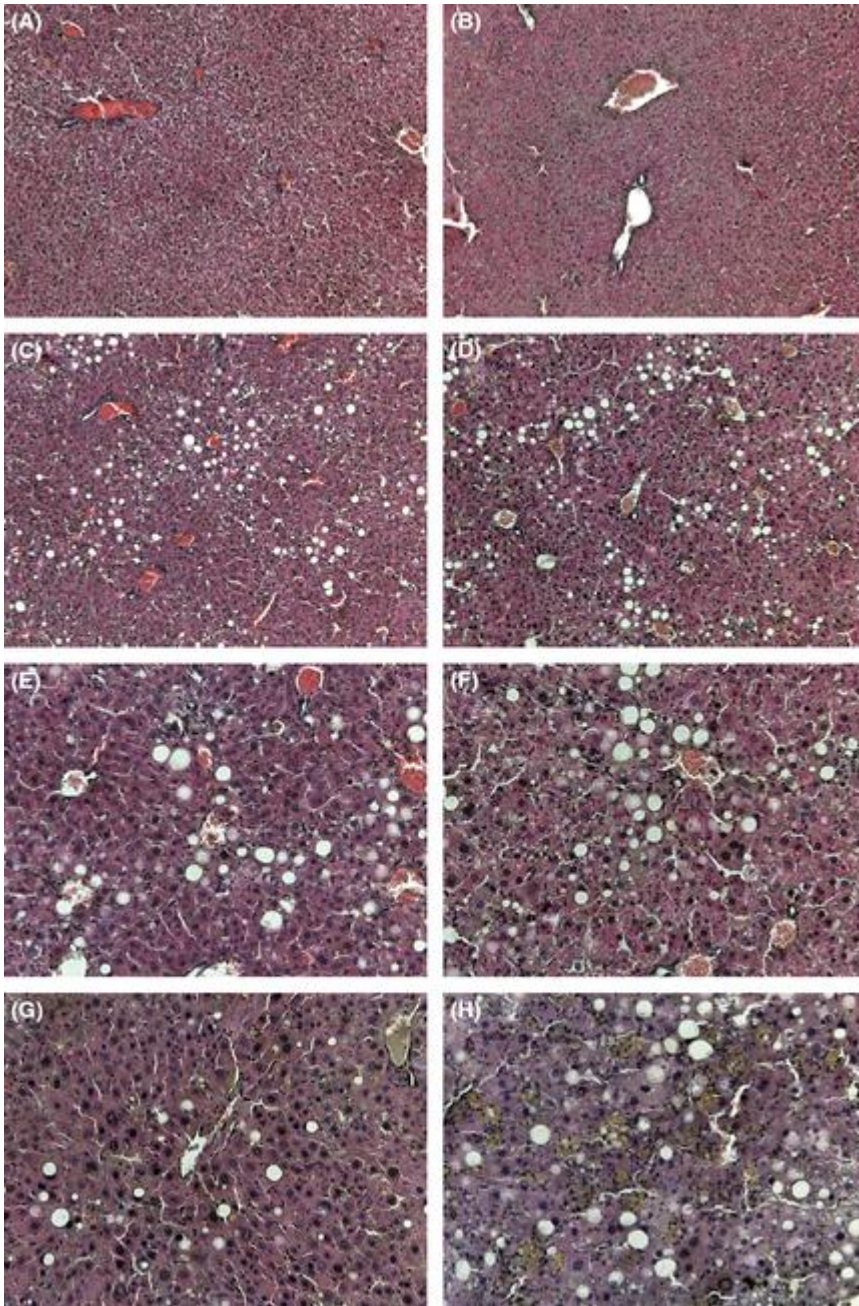
We next evaluated the effects of supplementation with the different types of fatty acids on the cardinal aspects of steatohepatitis, analysing serum biochemistry and histological damage. Administration of the MCD diet resulted in a marked elevation of serum ALT and AST compared to animals receiving the Cnt diet, with a 5- to 10-fold increase after 4 weeks (Fig. 1A). At this time point, no significant differences were observed comparing mice supplemented with n-3 PUFA OR OO. After 8 weeks, ALT and AST levels were markedly decreased in MCD-OO mice and appeared to be only modestly increased compared to mice receiving the Cnt diet. In contrast, aminotransferase levels remained markedly and significantly higher in MCD-n-3 mice, with levels similar to the ones observed after 4 weeks (Fig. 1B).



**Figure 1.**

Effects of fatty acid supplementation on aminotransferase levels in mice administered a MCD diet. Mice were administered a control diet (Cnt) or a diet without methionine and choline (MCD) for 4 weeks (panel A) or for 8 weeks. During the entire protocol, mice were administered with olive oil (black columns) or with a mixture of 25% n-3 PUFA in olive oil (cross-hatched columns). At the end of the experiment, plasma levels of ALT and AST, as indicated, were measured. \* $P < 0.05$  vs. olive oil.

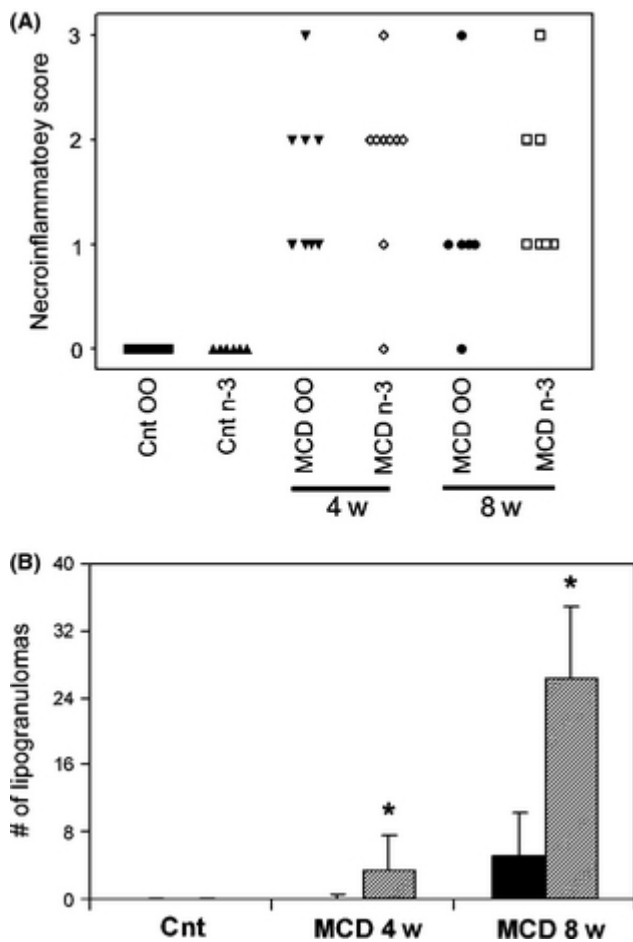
To correlate the increase in aminotransferase levels with the actual histological damage, liver sections were stained with haematoxylin and eosin and scored by an experienced pathologist (Figs. 2 and 3). At both 4 and 8 weeks, the MCD diet induced marked steatosis, mainly macrovesicular, predominantly in the perivenular area (Fig. 2). Semiquantitative scoring (Fig. 3A) demonstrated the presence of mild to moderate steatosis throughout this study protocol. However, no significant differences in the severity of steatosis were observed comparing animals supplemented with the two types of fatty acids, at both time points tested. We next evaluated the extent of inflammatory infiltration associated with the MCD diet. At both 4 and 8 weeks, the amount of inflammatory cells in the liver was markedly increased, as indicated by the histological score (Fig. 3A). In mice administered n-3 PUFA together with the MCD diet, the overall inflammatory score was higher than that of mice treated with OO at both 4 and 8 weeks, although differences did not reach statistical significance. Inflammation in the MCD model is also characterized by the appearance of lipogranulomas, where clusters of inflammatory cells surround small groups of fat-laden hepatocytes (Fig. 2). In mice fed the MCD diet together with n-3 PUFA, lipogranulomas appeared at 4 weeks and were abundantly present after 8 weeks of treatment (Figs. 2 and 3B). In contrast, mice receiving OO together with the MCD diet had no lipogranulomas at 4 weeks and their number was markedly and significantly lower than in MCD-n-3 mice at 8 weeks. These data indicate that supplementation with n-3 PUFA is associated with a more severe biochemical and histological phenotype in MCD-induced steatohepatitis.



**Figure 2.**

Effects of fatty acid supplementation on liver histology in mice administered a MCD diet. Mice were administered a control diet (panels A–B) or a diet without methionine and choline for 4 weeks (panels C–F) or 8 weeks (panels G–H). During the entire protocol, mice were administered with olive oil (panels A,C,E,G) or with a mixture of 25% n-3 PUFA in olive oil (panels B,D,F,H). Paraffin-embedded liver sections were stained with haematoxylin and eosin. Original magnification  $\times 40$  (panels A–D) or  $\times 80$  (panels E–H).



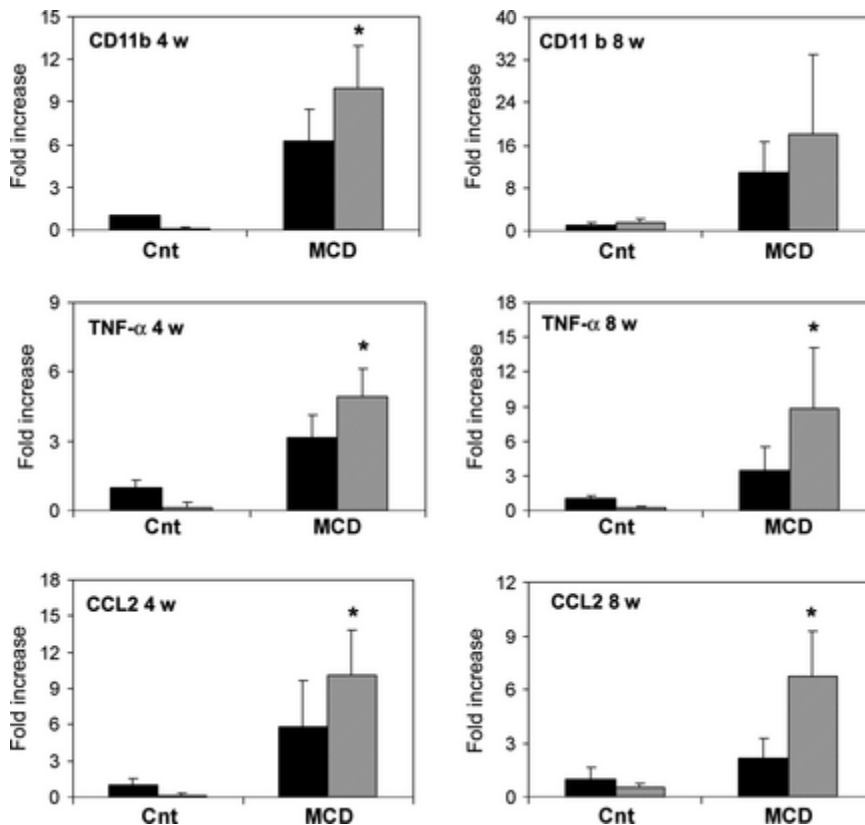


**Figure 3.**

Fatty acid supplementation differentially affects the development of inflammation in MCD-induced steatohepatitis. Mice were administered a control diet (Cnt) or a diet without methionine and choline (MCD) for 4 weeks or 8 weeks. During the entire protocol, mice were administered with olive oil (OO) or with a mixture of 25% n-3 PUFA in olive oil (n-3). Panel A: Necroinflammatory score was measured by an investigator blinded to the identity of specimens, as indicated in Materials and Methods. Each point represents an individual animal. Panel B: The number of lipogranulomas, defined as indicated in Materials and Methods, was measured in 10 high-power fields in each group of mice. Black columns: olive oil. Cross-hatched columns: n-3 PUFA. \* $P < 0.05$  vs. olive oil.

To provide a functional counterpart to the increased necroinflammatory damage observed at both biochemical and histological levels, we evaluated the intrahepatic expression of a panel of genes known to be related to liver inflammation (Fig. 4). The surface marker CD11b, that is expressed by monocytes and other activated leucocytes, increased in mice treated with MCD at both time points (Fig. 4). However, comparing the expression levels according to the type of PUFA supplementation received, mice treated with OO had consistently and significantly lower expression of CD11b. Similar results were obtained when expression of TNF-alpha, a pivotal cytokine in the pathogenesis of inflammatory damage, was assessed (Fig. 4). Finally, the transcript levels of CCL2, an inflammatory chemokine closely involved in hepatic inflammatory injury [20], were also significantly higher in MCD-n-3 mice than in the corresponding OO-fed animals (Fig. 4). Taken together, these data indicate that the inflammatory response is increased when a diet inducing

steatohepatitis is associated with supplementation with n-3 PUFA. Along these lines, it is well established that steatohepatitis is associated with generation of reactive oxygen species and other oxidative stress-related compounds. To evaluate the possible differential effects of the two supplementations on redox-related changes, we measured by immunohistochemistry the number of nuclei positive for 8-hydroxy-deoxyguanosine, as an indicator of oxidative stress-induced DNA modifications [16]. While staining was virtually absent in mice administered the Cnt diet (Fig. S1), a marked increase was observed upon administration of the MCD diet. In mice supplemented with n-3 PUFA, the percentage of positive cells was slightly, but not significantly higher than in mice receiving OO.

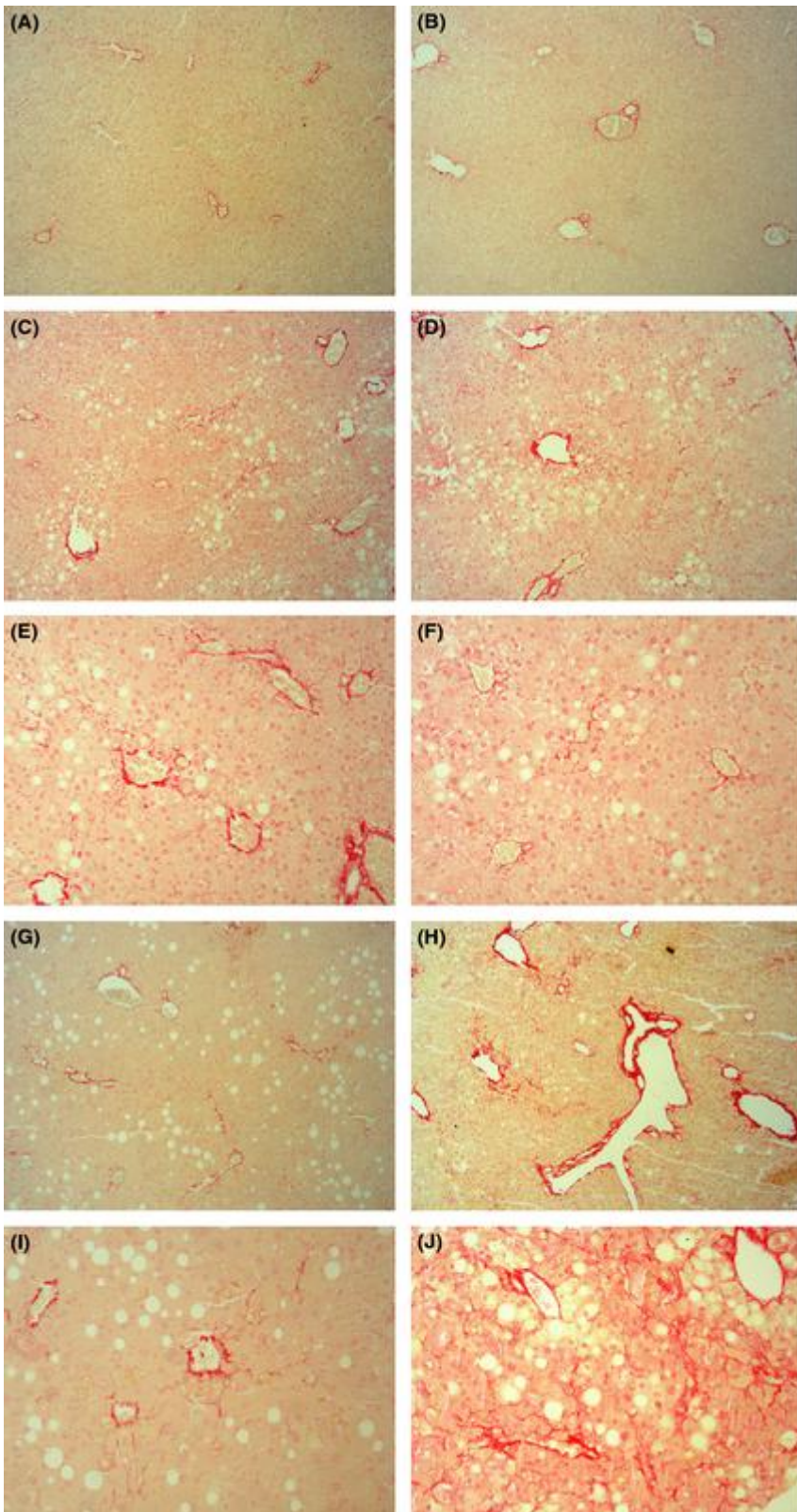


**Figure 4.**

Effects of fatty acid supplementation on hepatic expression of inflammation-related genes in mice administered a MCD diet. Mice were administered a control diet (Cnt) or a diet without methionine and choline (MCD) for 4 weeks or 8 weeks, as indicated. During the entire protocol, mice were administered with olive oil (black columns) or with a mixture of 25% n-3 PUFA in olive oil (cross-hatched columns). Expression of the indicated genes was measured by quantitative real time on liver RNA as indicated in Materials and Methods. \* $P < 0.05$  vs. olive oil.

The MCD diet model in rodents has the ability to nicely reproduce the development of perivenular fibrosis observed in human steatohepatitis, although the pathogenesis of liver injury is at least partially different. After 4 weeks of MCD diet, fibrosis was barely evident irrespectively of the type of fatty acids supplemented (Fig. 5A–F). In contrast, a clear perivenular fibrosis, with the typical ‘chickenwire’ pattern, was evident after 8 weeks (Fig. 5F–I). The extent of extracellular matrix deposition, as evidenced by Sirius red staining, was more abundant after supplementation with n-3 PUFA than with OO. To further evaluate this finding, semiquantitative histological fibrosis scores were measured. While fibrosis was found to be mild (stage 1) in nearly all MCD-OO mice, administration of n-3 PUFA together with the MCD diet resulted in a marked increase in the

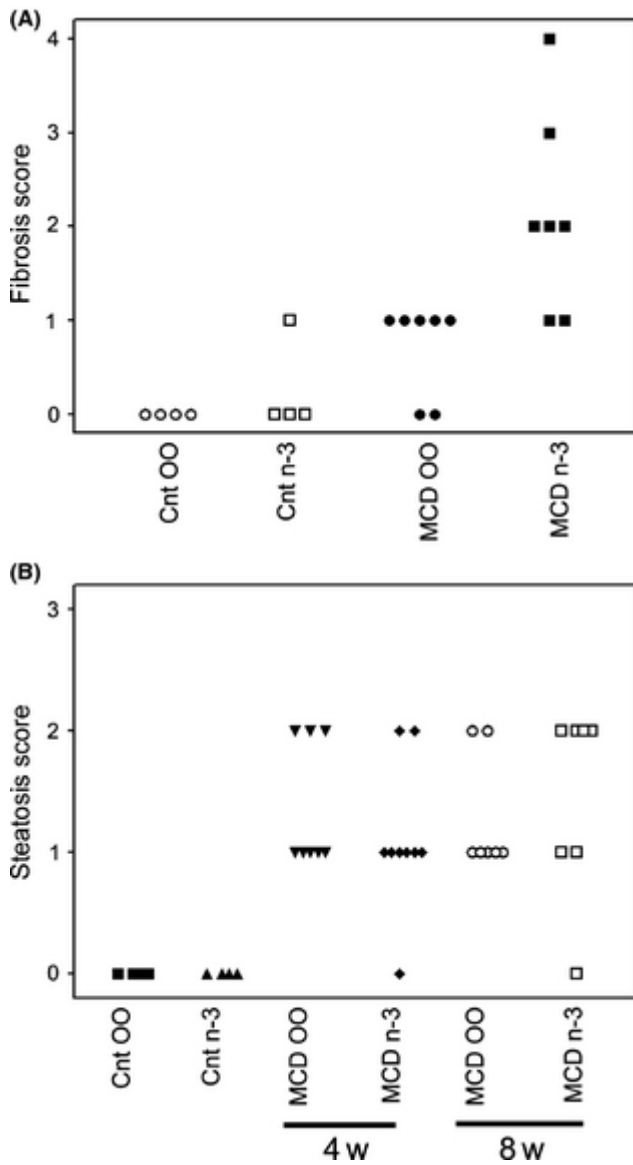
observed stage of fibrosis (Fig. 6A). In contrast, no differences in the degree of steatosis were found in mice treated with the different supplementation protocols (Fig. 6B).



**Figure 5.**

Effects of fatty acid supplementation on the development of fibrosis in mice administered a MCD diet. Mice were administered a control diet (panels A–B) or a diet without methionine and choline

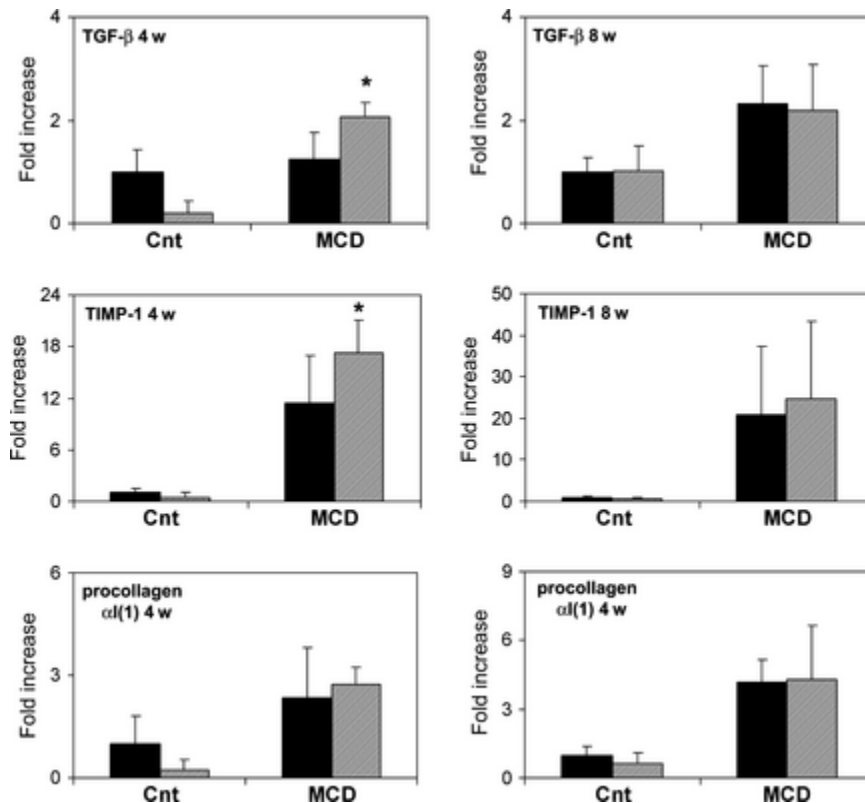
for 4 weeks (panels C–F) or 8 weeks (panels G–J). During the entire protocol, mice were administered with olive oil (panels A,C,E,G,I) or with a mixture of 25% n-3 PUFA in olive oil (panels B,D,F,H, J). Paraffin-embedded liver sections were stained with Sirius red, as described in ['Materials and methods'](#). Original magnification  $\times 40$  (panels A,B,C,D,G,H) or  $\times 80$  (panels E,F,I,J).



**Figure 6.**

Effects of fatty acid supplementation on the histological scores of fibrosis and steatosis in MCD-induced steatohepatitis. Mice were administered a control diet (Cnt) or a diet without methionine and choline (MCD) for 4 weeks or 8 weeks. During the entire protocol, mice were administered with olive oil (OO) or with a mixture of 25% n-3 PUFA in olive oil (n-3). Histological scores were measured by an investigator blinded to the identity of specimens, as indicated in Materials and Methods. Each point represents an individual animal. Panel A: Score of fibrosis after 8 weeks of Cnt or MCD diet: the score with the MCD diet was significantly different comparing OO and n-3 ( $P < 0.05$ ). Panel B: score of steatosis after 4 or 8 weeks of MCD diet, as indicated.

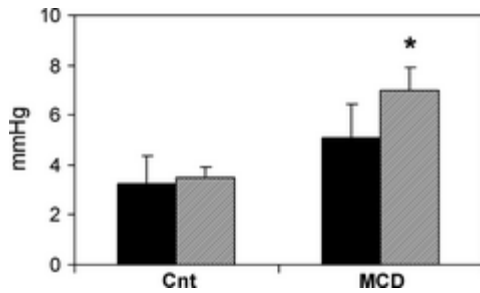
We next investigated whether the more severe fibrosis observed in MCD-n-3 mice was associated with differential expression of profibrogenic genes. MCD diet caused an increase in intrahepatic expression of transforming growth factor (TGF)- $\beta$ , tissue inhibitor of metalloproteinase (TIMP)-1 and type I procollagen, both at 4 and 8 weeks (Fig. 7). At 4 weeks, the expression levels of TGF- $\beta$  and TIMP-1 were significantly higher in MCD-n-3 mice than in the MCD-OO group. Interestingly, these differences were no longer evident at the 8-week time point, although these genes were still up-regulated with respect to the control groups.



**Figure 7.**

Effects of fatty acid supplementation on hepatic expression of fibrogenesis-related genes in mice administered a MCD diet. Mice were administered a control diet (Cnt) or a diet without methionine and choline (MCD) for 4 weeks or 8 weeks, as indicated. During the entire protocol, mice were administered with olive oil (black columns) or with a mixture of 25% n-3 PUFA in olive oil (cross-hatched columns). Expression of the indicated genes was measured by quantitative real-time on liver RNA as indicated in Materials and Methods. \* $P < 0.05$  vs. olive oil.

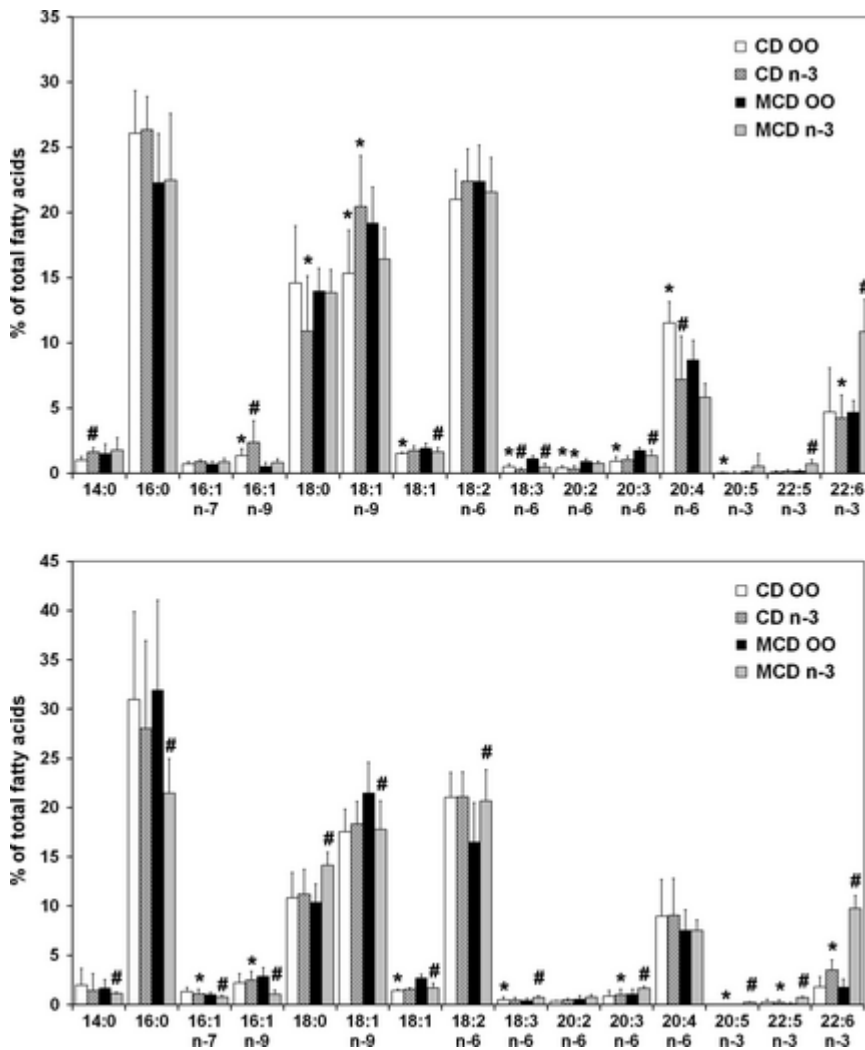
To evaluate whether changes in the fibrotic stage were paralleled by similar changes in portal pressure, this parameter was measured shortly before sacrifice at the 8-week time point of this study (Fig. 8). While portal pressure was only modestly changed in MCD-OO mice, its values were significantly more elevated in the MCD-n-3 group. In aggregate, these data demonstrate that supplementation of mice fed a MCD diet with n-3 PUFA together with olive oil results in faster hepatic fibrogenesis and disease progression compared to mice supplemented with olive oil only.



**Figure 8.**

Effects of fatty acid supplementation on portal pressure in mice administered a MCD diet. Mice were administered a control diet (Cnt) or a diet without methionine and choline (MCD) for 8 weeks. During the entire protocol, mice were administered with olive oil (black columns) or with a mixture of 25% n-3 PUFA in olive oil (cross-hatched columns). At the end of the experiments portal pressure was measured as indicated in Materials and Methods. \* $P < 0.05$  vs. olive oil.

Administration of the MCD diet is associated with weight loss and wasting, and development of steatosis is mostly related to the inadequate secretion of VLDL, rather than on an increase inflow of free fatty acids [21]. For this reason, we tested whether supplementation with the different mixtures of fatty acids was effective in modifying the intrahepatic lipid profile, analysing the fatty acid profile of the different groups of mice treated for 8 weeks (Fig. 9). In mice treated with the control diet, the fatty acid profile was remarkably stable, and only very minor differences were observed. In contrast, mice treated with the MCD diet and receiving OO had a significantly increased percentage of oleic acid (18:1 n-9) in liver lipids. Similarly, a significant increase in all fatty acids of the n-3 series was observed in mice receiving n-3 PUFA. Of note, the levels of 20:5 n-3 (eicosapentaenoic acid) and those of its elongation and desaturation products, 22:5 and 22:6 n-3 were significantly increased in the liver of mice receiving n-3 PUFA. These data indicate that the supplementation protocol was able to induce corresponding changes at the intrahepatic level, ruling out the possibility of a lack of effect because of the simultaneous administration of a MCD diet. To further demonstrate that the fatty acid supplementation was functionally effective, the expression levels of PPAR- $\alpha$ , which are up-regulated by n-3 PUFA [22], were measured (Fig. S2). Supplementation with n-3 PUFA resulted in the expected significant increase in PPAR- $\alpha$  expression, indicating that the protocol was functionally effective on the liver.



**Figure 9.**

Effects of fatty acid supplementation on the hepatic fatty acid profile in mice administered a MCD diet. Mice were administered a control diet (Cnt) or a diet without methionine and choline (MCD) for 4 weeks or 8 weeks, as indicated. During the entire protocol, mice were administered with olive oil (OO) or with a mixture of 25% n-3 PUFA in olive oil (n-3). At the end of the experiment, the fatty acid profile of hepatic lipids was analysed as described in ['Materials and methods'](#). \* $P < 0.05$  vs. control diet with the same supplement; # $P < 0.05$  vs. olive oil.

## Discussion

The effects of specific nutrients on the development of nonalcoholic steatohepatitis remain largely unknown. Recent studies have highlighted the fact that specific sugars and aminoacids are associated with modulation of inflammation and fibrogenesis in different experimental models [23]. The presence of dyslipidemia, intrahepatic triglyceride accumulation, and expansion of the liver free fatty acid pool has generated considerable interest on the role of different types of fatty acids introduced with the diet in the modulation of steatohepatitis. The results of the present study demonstrate that supplementation with two mixtures of fatty acids differentially affects inflammation and fibrogenesis in a model of murine nonalcoholic steatohepatitis. Specifically, supplementation with a 25/75% mixture of n-3 PUFA and olive oil resulted in a more severe inflammatory phenotype and worsened fibrogenesis in comparison to mice receiving an equal amount of fatty acids in the form of 100% OO. Enhanced inflammation and injury in animals

receiving n-3 PUFA is demonstrated by several lines of evidence. First, aminotransferase levels were more elevated than in mice receiving OO alone, after 8 weeks of administration of a MCD diet. These biochemical changes were accompanied by histological evidence of increased hepatic injury, as indicated by the higher necroinflammatory score. In addition, intrahepatic expression of genes related to inflammatory pathways was markedly and significantly elevated, including CD11b, expressed on activated leucocytes. A particular aspect of the inflammatory process in n-3 PUFA-treated mice was the dramatic increase in the number of lipogranulomas, inflammatory foci where clusters of leucocytes surround lipid-laden hepatocytes often undergoing apoptosis. These changes were already evident in n-3 PUFA-treated mice on a MCD diet after 4 weeks, but became almost 6-fold more abundant at the 8-week time point. Lipogranulomas may represent areas in which inflammation is more strictly associated with hepatocellular damage, and their appearance was temporally associated with a more evident elevation in ALT and higher expression of pro-inflammatory cytokines.

The interaction of n-3 PUFA with inflammation has received considerable attention in recent years, both in the liver and in other tissues. The general understanding is that this class of lipids exerts anti-inflammatory actions in a variety of conditions, acting on several signalling pathways including the newly identified metabolites collectively indicated as 'resolvins' [24, 25]. This anti-inflammatory action has been confirmed in different conditions of liver injury, including the MCD and other dietary models of steatohepatitis [26-28]. However, other studies have shown that supplementation with PUFA has detrimental effects on inflammation in models of steatohepatitis. Lee *et al.* [29] modified the content of PUFA in the MCD diet and found that an increased amount of these fatty acids is associated with increased inflammation. Of note, no worsening of hepatocellular injury was reported, indicating a selective effect of PUFA on inflammation, but not on hepatocellular damage. Moreover, no information on the possible specific role of n-3 fatty acids was provided. In another study [22], enrichment of a MCD diet with fish oil, mostly composed of n-3 PUFA, caused a more severe inflammatory phenotype than olive oil. Moreover, in alcoholic steatohepatitis, administration of PUFA, including n-3 fatty acids, has been associated with more severe hepatic damage and worsening of oxidative stress [30]. The MCD model is extremely sensitive to oxidative stress, as the lack of methionine supply limits the formation of the potent antioxidant, glutathione [31]. However, in the present study, no differences were found concerning oxidative stress when comparing mice treated with a MCD diet and receiving the two different supplementation protocols. While these data suggest that oxidative stress may not be critical in determining the more severe inflammatory phenotype of n-3 PUFA-treated mice, it is possible that other components of the oxidative stress, e.g. reactive aldehydes, were differentially regulated. Alternatively, it is possible that the already high levels of DNA oxidation could not be further and sensitively modulated by the different fatty acid formulations. Of note, in the Larter study [22], fish oil supplementation was found to markedly increase the levels of hydroperoxides, although no changes in the levels of arachidonic acid metabolites or NF- $\kappa$ B activation could be found, and the pro-inflammatory cytokine profile was not tested.

Several lines of information obtained in our study may be important to shed additional light on the controversy between studies showing protective vs. detrimental effects of n-3 PUFA on experimental steatohepatitis published in the last decade. First, unlike any other published study, fatty acid supplementation was provided by gavage, in a strictly controlled dosing and timing, and not as enrichment of a diet the consumption of which may vary with time and with the deterioration of the animal conditions. Second, we performed analysis of the fatty acid profile of hepatic lipids to establish whether the supplementation protocol was successful in modifying its composition. Enrichment in n-3 fatty acids was observed at both 4 and 8 weeks of treatment, including a greater abundance of elongation products. These data clearly argue in favour of an effective incorporation of n-3 fatty acids in the liver, as also indicated by the increased hepatic expression of PPAR- $\alpha$ .



While previous studies have indicated that PPAR- $\alpha$  limits inflammation in different models of steatohepatitis, including the MCD diet model [32-34], in the present study inflammation was actually increased in the n-3 PUFA group in spite of an effective increase in PPAR-  $\alpha$  expression.

Other possible mechanisms may contribute to increased inflammation in mice receiving n-3 PUFA. At difference with the data of Lee *et al.* [29], we observed a longer lasting and more severe elevation in aminotransferase levels in these mice. This was associated with increased levels of pro-inflammatory cytokines pivotally involved in the pathogenesis of steatohepatitis, including CCL2, which is known to play a pivotal role in the recruitment of different leucocyte populations to sites of injury [15], and TNF- $\alpha$ . This latter cytokine, considered of pivotal relevance in the pathogenesis of steatohepatitis [23], was found to be two times higher in mice receiving a MCD diet together with n-3 PUFA supplementation. These changes in cytokines implicated in the pathogenesis of liver inflammation represent a relevant mechanism by which n-3 PUFA amplify the inflammatory process in this model. Of note, the elevation of these factors and signs of more severe inflammation were already present at 4 weeks, whereas more elevated ALT were observed at 8 weeks. This time course suggests that increased inflammation was likely responsible for the maintenance of cellular injury, rather than the reverse sequence of events.

Recent data in patients with nonalcoholic steatohepatitis indicate that the presence of inflammation in the initial biopsy predicts the likelihood to progress to advanced fibrosis [35], and this clinical observation is supported by experimental studies where modulation of inflammation resulted in the down-regulation of fibrogenesis (reviewed in Refs [23]). In the present study, significantly higher fibrosis scores accompanied the remarkable increase in inflammation observed upon n-3 PUFA administration after 8 weeks of treatment. Of note, this was associated with up-regulated expression of genes involved in fibrogenesis, such as TGF- $\beta$  and TIMP-1, but not type I procollagen, suggesting a prevalent role of reduced extracellular matrix degradation, rather than increased matrix deposition in mice exposed to n-3 PUFA. To our knowledge, this is the first report indicating a modulation of the fibrogenic process by PUFA in experimental steatohepatitis, demonstrating that not only inflammatory aspects, but long-term progression may be affected by dietary manipulation. Along these lines, portal pressure was only slightly modified by the MCD diet associated with OO supplementation, whereas it markedly and significantly increased in mice receiving n-3 PUFA. While the more severe fibrosis stage observed in this latter group of mice may be a likely explanation of this finding, the possible role of inflammatory infiltration should not be overlooked, as inflammation has been recognized as a relevant mechanism leading to portal hypertension [36]. Whatever the mechanism involved, the increase in portal pressure in mice treated with a MCD diet and n-3 PUFA reinforces the concept that this combination accelerates damage and repair in mice with experimental steatohepatitis.

Several studies and meta-analyses have indicated that supplementation with n-3 fatty acids limits hepatic triglyceride accumulation and lowers ALT levels in patients with NAFLD, while no definitive evidence has been obtained supporting an anti-inflammatory action in humans with NASH [10], and larger studies are underway. However, we did not observe any change in the steatosis score, similarly to other studies [29], including one where fish oil induced only a modest albeit significant decrease in intrahepatic triglyceride accumulation, but no change in the steatosis score [22]. The pathogenesis of steatosis in the MCD model, based on reduced assembly and secretion of VLDL, is largely different from the one observed in human NAFLD, which is mostly related to excess lipolysis and *de novo* lipogenesis. Thus, it is not surprising that n-3-mediated mechanisms operating in purely metabolic steatosis were not effective in this context. On the other hand, the use of a MCD diet represents a limitation of this study, because of its poor pathophysiological similarity to human NASH.

The results of our experimental study confirm that dietary intervention with specific nutrients may effectively modulate the course and progression of steatohepatitis, although the effects of n-3 PUFA were different from those expected in therapeutic human trials. While additional data are warranted to establish the final impact of n-3 PUFA supplementation on the outcome of patients with steatohepatitis, the results of the present study suggest that careful monitoring and some extra caution should be applied when administering n-3 PUFA to subjects with active hepatic inflammation.

## Acknowledgements

This work was supported by grants from MIUR (Progetti PRIN), the European Community's Seventh Framework Programme [FP7/2007-2013] under grant agreement n° HEALTH-F2-2009-241762 for the project FLIP (to FM), and the Fondazione CARIPLO. We also thank Dr. Guerrini (Società Prodotti Antibiotici, Milan, Italy) for kindly providing the fatty acids used in this study, and Professor Claudio Galli (University of Milan, Italy) for help with protocol design.

*Conflict of interest:* The authors do not have any disclosures to report.

1. Bhala N, Jouness RI, Bugianesi E. Epidemiology and natural history of patients with NAFLD. *Curr Pharm Des* 2013;19: 5169–76.
2. Angulo P. Nonalcoholic fatty liver disease. *N Engl J Med* 2002; 346: 1221–31.
3. Brunt E. Nonalcoholic steatohepatitis. *Sem Liv Dis* 2004; 24: 3–20.
4. Neuschwander-Tetri BA. Hepatic lipotoxicity and the pathogenesis of nonalcoholic steatohepatitis: the central role of nontriglyceride fatty acid metabolites. *Hepatology* 2010; 52: 774–88.
5. Marra F, Gastaldelli A, Svegliati Baroni G, Tell G, Tiribelli C. Molecular basis and mechanisms of progression of non-alcoholic steatohepatitis. *Trends Mol Med* 2008; 14: 72–81.
6. Musso G, Gambino R, De Michieli F, et al. Dietary habits and their relations to insulin resistance and postprandial lipemia in nonalcoholic steatohepatitis. *Hepatology* 2003; 37: 909–16.
7. El-Badry AM, Graf R, Clavien PA. Omega 3 – Omega 6: What is right for the liver? *J Hepatol* 2007; 47: 718–25.
8. Mozaffarian D, Wu JH. Omega-3 fatty acids and cardiovascular disease: effects on risk factors, molecular pathways, and clinical events. *J Am Coll Cardiol* 2011; 58: 2047–67.
9. Wall R, Ross RP, Fitzgerald GF, Stanton C. Fatty acids from fish: the anti-inflammatory potential of long-chain omega-3 fatty acids. *Nutr Rev* 2010; 68: 280–9.
10. Parker HM, Johnson NA, Burdon CA, et al. Omega-3 supplementation and non-alcoholic fatty liver disease: a systematic review and meta-analysis. *J Hepatol* 2012; 56: 944–51.
11. Schmitz G, Ecker J. The opposing effects of n-3 and n-6 fatty acids. *Prog Lipid Res* 2008; 47: 147–55.

12. Sekiya M, Yahagi N, Matsuzaka T, et al. Polyunsaturated fatty acids ameliorate hepatic steatosis in obese mice by SREBP-1 suppression. *Hepatology* 2003; 38: 1529–39.
13. Demoz A, Willumsen N, Berge RK. Eicosapentaenoic acid at hypotriglyceridemic dose enhances the hepatic antioxidant defense in mice. *Lipids* 1992; 27: 968–71.
14. Zhao Y, Joshi-Barve S, Barve S, Chen LH. Eicosapentaenoic acid prevents LPS-induced TNF- $\alpha$  expression by preventing NF- $\kappa$ B activation. *J Am Coll Nutr* 2004; 23: 71–8.
15. Galastri S, Zamara E, Milani S, et al. Lack of CC chemokine ligand 2 differentially affects inflammation and fibrosis according to the genetic background in a murine model of steatohepatitis. *Clin Sci (Lond)* 2012; 123: 459–71.
16. Halliwell B, Whiteman M. Measuring reactive species and oxidative damage in vivo and in cell culture: how should you do it and what do the results mean? *Br J Pharmacol* 2004; 142: 231–55.
17. Vizzutti F, Provenzano A, Galastri S, et al. Curcumin limits the fibrogenic evolution of experimental steatohepatitis. *Lab Invest* 2010; 90: 104–15.
18. Folch J, Lees M, Sloane Stanley GH. A simple method for the isolation and purification of total lipides from animal tissues. *J Biol Chem* 1957; 226: 497–509.
19. Metcalfe LD, Schmitz AA, Pelka JR. Rapid Preparation of Fatty Acid Esters from Lipids for Gas Chromatographic Analysis. *Anal Chem* 1966; 38: 514–5.
20. Zimmermann HW, Tacke F. Modification of chemokine pathways and immune cell infiltration as a novel therapeutic approach in liver inflammation and fibrosis. *Inflamm Allergy Drug Targets* 2011; 10: 509–36.
21. Yao ZM, Vance DE. The active synthesis of phosphatidylcholine is required for very low density lipoprotein secretion from rat hepatocytes. *J Biol Chem* 1988; 263: 2998–3004.
22. Larter CZ, Yeh MM, Cheng J, et al. Activation of peroxisome proliferator-activated receptor alpha by dietary fish oil attenuates steatosis, but does not prevent experimental steatohepatitis because of hepatic lipoperoxide accumulation. *J Gastroenterol Hepatol* 2008; 23:267–75.
23. Marra F, Lotersztajn S. Pathophysiology of NASH: perspectives for A Targeted Treatment. *Curr Pharm Des* 2013; 19: 5250–69.
24. Lee S, Gura KM, Puder M. Omega-3 fatty acids and liver disease. *Hepatology* 2007; 45: 841–5.
25. Gonzalez-Periz A, Horrillo R, Ferre N, et al. Obesity-induced insulin resistance and hepatic steatosis are alleviated by omega-3 fatty acids: a role for resolvins and protectins. *FASEB J* 2009; 23: 1946–57.
26. Svegliati-Baroni G, Candelaresi C, Saccomanno S, et al. A model of insulin resistance and nonalcoholic steatohepatitis in rats: role of peroxisome proliferator-activated receptor- $\alpha$  and n-3 polyunsaturated fatty acid treatment on liver injury. *Am J Pathol* 2006; 169: 846–60.
27. Ishii H, Horie Y, Ohshima S, et al. Eicosapentaenoic acid ameliorates steatohepatitis and hepatocellular carcinoma in hepatocyte-specific Pten-deficient mice. *J Hepatol* 2009; 50: 562–71.

28. Kajikawa S, Imada K, Takeuchi T, et al. Eicosapentaenoic acid attenuates progression of hepatic fibrosis with inhibition of reactive oxygen species production in rats fed methionine- and choline-deficient diet. *Dig Dis Sci* 2011; 56: 1065–74.
29. Lee GS, Yan JS, Ng RK, Kakar S, Maher JJ. Polyunsaturated fat in the methionine-choline-deficient diet influences hepatic inflammation but not hepatocellular injury. *J Lipid Res* 2007; 48: 1885–96.
30. Nanji AA. Role of different dietary fatty acids in the pathogenesis of experimental alcoholic liver disease. *Alcohol* 2004; 34: 21–5.
31. Shapiro H, Tehilla M, Attal-Singer J, et al. The therapeutic potential of long-chain omega-3 fatty acids in nonalcoholic fatty liver disease. *Clin Nutr* 2011; 30: 6–19.
32. Tailleux A, Wouters K, Staels B. Roles of PPARs in NAFLD: potential therapeutic targets. *Biochim Biophys Acta* 2012; 1821: 809–18.
33. Ip E, Farrell GC, Robertson G, et al. Central role of PPARalpha- dependent hepatic lipid turnover in dietary steatohepatitis in mice. *Hepatology* 2003; 38: 123–32.
34. Ip E, Farrell G, Hall P, Robertson G, Leclercq I. Administration of the potent PPARalpha agonist, Wy-14,643, reverses nutritional fibrosis and steatohepatitis in mice. *Hepatology* 2004; 39: 1286–96.
35. Argo CK, Northup PG, Al-Osaimi AMS, Caldwell SH. Systematic review of risk factors for fibrosis progression in non-alcoholic steatohepatitis. *J Hepatol* 2009; 51: 371–9.
36. Seo YS, Shah VH. The role of gut-liver axis in the pathogenesis of liver cirrhosis and portal hypertension. *Clin Mol Hepatol* 2012; 18: 337–46.