

The logo for IRIS AperTO, featuring the text "IRIS AperTO" in white serif font on a red rectangular background.

UNIVERSITÀ  
DEGLI STUDI  
DI TORINO

This is the author's final version of the contribution published as:

Demaestri M;Sciascia S;Kuzenko A;Bergia R;Barberis L;Lanza MG;Bertero MT. Neonatal lupus in triplet pregnancy of a patient with undifferentiated connective tissue disease evolving to systemic lupus erythematosus.. LUPUS. 18 pp: 368-371.

DOI: 10.1177/0961203308097512

The publisher's version is available at:

<http://lup.sagepub.com/cgi/doi/10.1177/0961203308097512>

When citing, please refer to the published version.

Link to this full text:

<http://hdl.handle.net/2318/142584>

This full text was downloaded from iris - AperTO: <https://iris.unito.it/>

---

iris - AperTO

University of Turin's Institutional Research Information System and Open Access Institutional Repository

## Neonatal lupus in triplet pregnancy of a patient with undifferentiated connective tissue disease evolving to systemic lupus erythematosus

M Demaestri<sup>1,2</sup>, S Sciascia<sup>3</sup>, A Kuzenko<sup>3</sup>, R Bergia<sup>3</sup>, L Barberis<sup>4</sup>, MG Lanza<sup>5</sup> and MT Bertero<sup>1,3</sup>

<sup>1</sup>Master Malattie Rare, Università degli Studi di Torino, Turin, Italy; <sup>2</sup>Medicina d'Urgenza, Ospedale S. Lazzaro, Alba, Cuneo, Italy; <sup>3</sup>Immunologia Clinica e Allergologia, ASO Ospedale Mauriziano Umberto I, Turin, Italy; <sup>4</sup>Divisione Neonatologia Ospedaliera ASO OIRM S. Anna, Turin, Italy; and <sup>5</sup>Ginecologia Endocrinologica ASO OIRM S. Anna, Turin, Italy

Pregnancy in patients suffering from undifferentiated connective tissue disease (UCTD) represents a risk situation for both the mother and the child. SSA/SSB autoantibodies can determine neonatal lupus (NL) in the foetus, regardless of the maternal disease. Furthermore, pregnancy increases the risk of flares and evolution to differentiated connective tissue disease (CTD). We report an uncommon case in which these complications occurred in a mother and in her foetuses. A 37-year-old woman affected by UCTD developed systemic lupus erythematosus (SLE) after her triplet pregnancy.

The only manifestation of neonatal lupus we observed in the three newborns was SSA positivity associated with asymptomatic transient neutropenia.

**Key words:** antiphospholipid syndrome; pregnancy; systemic lupus erythematosus

Correspondence to: S Sciascia, Immunologia Clinica e Allergologia, ASO Ospedale Mauriziano Umberto I, Turin, Italy.  
Email: savino.sciascia@alice.it

## INTRODUCTION

Currently, the number of women affected by connective tissue diseases (CTDs) who decide to have children has increased thanks to the diagnostic improvements and to the multidisciplinary management of the patient. Pregnancies that are planned during the inactive phase of the disease do not usually result in any detrimental effects.<sup>1</sup> Patients who are affected by undifferentiated connective tissue diseases (UCTDs), which are usually benign,<sup>2,3</sup> generally have no absolute contraindications for pregnancy.<sup>4</sup> However, pregnancy in CTD patients still represents a risk situation for both the mother and the child. It is well known that maternal anti-Ro/SSA and/or anti-La/SSB autoantibodies can cross through the placenta causing possible damage to the foetus, likely leading to neonatal lupus syndrome (NL), regardless of the maternal disease. The most severe manifestation of NL is congenital complete heart block (CHB), resulting in a permanent change in the heart conduction tissue due to inflammation and fibrosis of the conducting system.<sup>5</sup> NL may also be characterised by photosensitive rash, haematological abnormalities or liver dysfunction, all of which resolve at approximately 6 months of life when maternal antibodies disappear from the neonatal circulation. On the contrary, CHB results in significant mortality (15–30%) and morbidity in the newborn. As a matter of fact, 67% of the surviving affected children require permanent pacing.<sup>5</sup> We report the case of a 37-year-old woman suffering from UCTD who developed SLE after her triplet pregnancy and whose newborns were diagnosed with neonatal lupus.

### Case report

A 37-year-old woman came to our attention during the 8th week of a trichorionic, triamniotic triplet invitro fertilisation (IVF) pregnancy. She underwent IVF because of tubal factor infertility caused by right salpingectomy and left hydrosalpinx that were the result of a previous pelvic Chlamydia infection. Her 10-year medical history included alopecia (successfully treated with prednisone), associated with positivity for antinuclear antibodies (ANA), 1:320 titre with a speckled pattern (indirect immunofluorescence in HEp-2), anti-Ro/SSA (ELISA), Lupus Anticoagulant (Stago Roche for APTT, LAC screen IL for DRVVT, home-made KCT), anticardiolipin (aCL) and anti- $\beta$ 2GPI, twice confirmed high titre in ELISA, and VDRL false positivity. Serum C3 and C4 levels were 70 mg/dL (normal 76–171) and 12 mg/dL (normal 10–40), respectively. When she came to our attention, the patient reported photosensitive rash, fatigue, Raynaud's phenomenon and recurrent urinary tract infection (UTI). The patient did not have a history of recurrent miscarriage, thrombosis, joint pain and arthritis, oral aphthosis, xerophthalmia or xerostomia. Recent laboratory tests showed positivity for ANA, SSA, aCL and anti- $\beta$ 2GPI (both IgG low titre) and negativity for anti-DNA and LA. Homocysteine, antithrombin III, C and S proteins, serum C3 and C4, complete blood count and hepato-renal function were all normal. Clinical and laboratory data supported a diagnosis of UCTD according to Mosca's criteria.<sup>2</sup> We confirmed her current therapy: hydroxychloroquine (HCQ), folic acid, low-dose aspirin (LDA) and we continued anti-coagulation prophylaxis with low-molecular weight heparin (LMWH), which had been started during IVF. During pregnancy, she gained 12 kg, her blood pressure was normal, and there were no signs/symptoms of flare. Recurrent bacterial UTI occurred. Amniocentesis was performed at the 17th week. No abnormalities were observed, and results showed one male and two female foetuses. Foetal echocardiograms were performed at the 21st, 24th, 27th and 30th week of pregnancy

and were normal. Doppler flowmetre evaluations at the 21st and 30th week were normal as well. Foetal morphologic ultrasound (US) studies performed at the 21st week showed renal pelvis dilatation in the male foetus. A caesarean section was performed at the 33rd week of pregnancy following the premature rupture of membranes (PROM). The male newborn (triplet 1) weighed 2200 g and the two females (triplets 2 and 3) weighed 1900 g and 1550 g, respectively. Triplets 1 and 3 showed mild respiratory distress that was treated with oxygen for the first 3 days of life. The babies were placed in incubators for the 1st week of life. Abdominal US study of triplet 1 confirmed mild bilateral pyelectasis and no ultrasound findings of vesicoureteral reflux. The newborn was treated with antibiotic prophylaxis and was discharged from hospital when he was 13 days old. The three newborns showed SSA positivity associated with asymptomatic transient neutropenia and negative anti-neutrophil antibodies. Figure 1 shows the neutrophil count in the newborns. Neutrophil leukocyte levels normalised following antibody seroconversion, which occurred when the babies were 50 days old. The newborns underwent ECG, and no abnormalities were found. Currently, the 3-year-old children show regular growth, and no symptoms and/or signs of any neurological pathologies have been observed. During the post-partum period, the mother remained asymptomatic and she continued LMWH prophylaxis for 8 weeks after which LDA administration was started again. Six months later, while on therapy with LDA 100 mg and HCQ 200 mg, the patient reported oral aphthosis and joint pain; diffuse erythema of the face with a butterfly configuration appeared. Because clinical findings were not specific, a biopsy was performed, which showed a histologic pattern that was suggestive of discoid lupus. She was successfully treated by increasing the dose of HCQ to 400 mg associated with topical corticosteroids and photoprotection.

#### Discussion

Two types of immunological disease related problems may develop during pregnancy in CTD patients.<sup>7</sup> One refers to the mother's risk of developing CTD flares and/or thrombotic events, whereas the other is linked to the risk of miscarriage, intrauterine growth restriction (IUGR) and neonatal lupus. We report an uncommon case in which both these immunological disease related problems occurred. However, it must be kept in mind that triplet pregnancy itself already represents a higher risk situation. Recently, important progress in the characterisation of autoantibodies and in the immunogenetics of CTD have increased our understanding of these diseases. Nonetheless, classification of many rheumatic diseases remains unclear.<sup>2</sup> Upon her first admission to our hospital, the patient showed an undifferentiated pattern (photosensitivity, alopecia, Raynaud's phenomenon) with LA and ANA, SSA, aCL autoantibodies and with false positive VDRL. She had been treated at another centre with HCQ and LDA therapy. It is well known that the end of pregnancy can interfere with the clinical course of systemic autoimmune diseases<sup>7</sup>; Mosca, et al.<sup>8</sup> actually assumed that pregnancy could represent a trigger causing UCTD to evolve to a definite CTD. In our case, UCTD evolved to systemic lupus erythematosus with articular, mucosal and skin involvement (discoid rash, oral aphthosis). The term "undifferentiated connective tissue disease" is used for conditions that are characterised by the presence of signs and symptoms suggestive of a systemic autoimmune disease, but that do not fulfil the classification criteria of any defined CTD, such as SLE, Sjogren syndrome, rheumatoid arthritis.<sup>2</sup> The term UCTD involves a heterogeneous group of diseases that are likely to remain unmodified over time, to evolve to otherwise classifiable diseases or to regress spontaneously.<sup>3</sup> UCTDs intrinsically present classification and prognostic problems due to the

overlapping clinical and laboratory features and to the lack of definitive characteristics at onset. Doria, et al. suggested that various populations may exist within the group of patients with unclassifiable CTDs: patients with incomplete SLE are the ones who will develop definite SLE, and therefore incomplete SLE could be considered an early stage of SLE, whereas UCTDs represent truly undifferentiated conditions that could potentially evolve into different types of CTDs.<sup>3</sup> About 25% of patients with an undifferentiated disease at onset will evolve to defined CTD during follow-up.<sup>2</sup> This evolution usually occurs within the first 5 years, and most often involves SLE. The factors that predict the shift from UCTD to defined CTD have been identified. The presence of anti-dsDNA, anti-Sm and anti-phospholipid antibodies, as well as serositis, alopecia, photosensitivity and discoid rash are predictive of evolution to SLE. To date, no triggering factors that might account for the progression to defined CTDs have been identified. Therefore, it is important to follow up patients closely, especially at disease onset and in conditions such as pregnancy when the risk of flare seems to be higher.<sup>9</sup> Our patient showed false positive VDRL, aCL high titre IgG, anti- $\beta$ 2GPI and LA positivity, which are laboratory criteria suggestive of the antiphospholipid syndrome (APS). Throughout gestation, we continued treating her with LMWH anticoagulation prophylaxis (which had been started during IVF) and with LDA. Despite the international APS recommendations, we decided to administer this combined treatment for several reasons, including high thrombotic risk during triplet pregnancy, advanced age, and positive anamnesis for infertility.<sup>10</sup> SSA and/or SSB positive patients may develop diffuse exocrinopathy involving the mucosal lining of the upper airways and the vagina, thus increasing their predisposition to local infections. Our patient reported suffering from recurrent UTIs for several years, and during pregnancy, she had recurrent bacterial cystitis. We think that in her case, PROM may have been related to urinary tract and vaginal infections and to the triplet pregnancy.<sup>11</sup> With regards to NL, the only manifestation we observed in all three newborns was asymptomatic neutropenia, which disappeared when the maternal SSA antibodies cleared from the babies' circulation. As is the case with twins, NL manifestations in triplets can also be discordant (Table 1). It has, therefore, been suggested that the presence of maternal SSA alone represents a necessary but not sufficient condition for developing the disease. As a matter of fact, it would appear that foetal and environmental factors may also play a role. Neonatal lupus is a disease of the foetus or of the newborn that is caused by transplacental crossing of anti-Ro/SSA, anti-La/SSB maternal auto-antibodies during pregnancy.<sup>5</sup> It is an in-vivo passive acquisition model of auto-immunity. With the exception of foetal heart block, neonatal manifestations usually disappear when the maternal antibodies clear, that is, at approximately the 6th to 8th month of life. Neonatal lupus is a rare syndrome. Many experts feel that the Brucato group in Italy has identified the most accurate incidence of NL in antibody-positive pregnancies. In their prospective study on the outcome of 100 pregnant women with anti-SSA/Ro antibodies, the incidence of CHB was 2%.<sup>14</sup> In our opinion, the incidence of neutropenia in the newborns of ENA-positive mothers may be underestimated because a complete blood count is not usually performed in asymptomatic newborns.<sup>15</sup> Given the rarity of the disease, little information concerning the management of children with neonatal lupus is available. Thus, both improving the approach to NL as well as long-term follow-up are mandatory. In fact, Martin, et al.<sup>16</sup> suggested that children with neonatal lupus require continued follow-up, especially before adolescence and if the mother herself has an autoimmune disease. Although there is no apparent increased risk of SLE, the development of

some form of autoimmune disease (systemic or organ specific) in early childhood may be of concern. In conclusion, our case shows that special care should be taken to monitor CTD patients during and after pregnancy due to the potential occurrence of disease flare and/or evolution to a definite CTD. The rarity of NL as well as the difficulty in recruiting a large enough number of patients to carry out a reliable study account for the lack of standardised protocols. Careful study of the foetus and long-term follow-up of babies are needed for several reasons, including reports of autoimmune diseases developing in patients who had NL as infants.

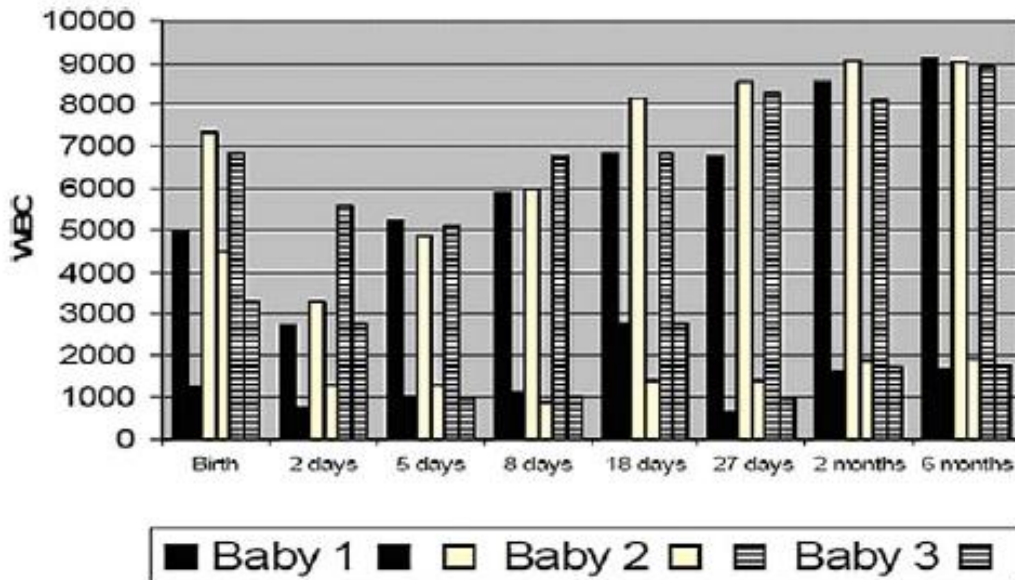
#### References

- 1 Tincani A, Danieli E, Nuzzo M, et al. Impact of in utero environment on offspring of lupus patients. *Lupus* 2006; 15: 801–807.
- 2 Mosca M, Tani C, Neri C, Baldini C, Bombardieri S. Undifferentiated connective tissue disease (UCTD). *Autoimmun Rev* 2006; 6: 1–4.
- 3 Doria A, Mosca M, Gambari PF, Bombardieri S. Defining unclassifiable connective tissue diseases: incomplete, undifferentiated, or both? *J Rheumatol* 2005; 32: 213–215.
- 4 Doria A, Iaccarino L, Ghirardello A, et al. Pregnancy in rare autoimmune rheumatic diseases: UCTD, MCTD, myositis, systemic vasculitis and Beçhet disease. *Lupus* 2004; 13: 690–695.
- 5 Izmirly PM, Rivera TL, Buyon JP. Neonatal lupus syndrome. *Rheum Dis Clin North Am* 2007; 33: 267–285.
- 6 Juul SE, Haynes JW, McPherson RJ. Evaluation of neutropenia and neutrophilia in hospitalized preterm infants. *J Perinatol* 2004; 24: 150–157.
- 7 Mecacci F, Pieralli A, Bianchi B, Paidas MJ. The impact of autoimmune disorders and adverse pregnancy outcome. *Semin Perinatol* 2007; 31: 223–226.
- 8 Mosca M, Tani C, Bombardieri S. Undifferentiated connective tissue diseases (UCTD): a new frontier for rheumatology. *Best Pract Res Clin Rheumatol* 2007; 21: 1011–1023.
- 9 Mosca M, Neri R, Strigini F, et al. Pregnancy outcome in patients with UCTD: a preliminary study on 25 pregnancies. *Lupus* 2002; 11: 304–307.
- 10 Ruiz-Irastorza G, Khamashta MA. Antiphospholipid syndrome in pregnancy. *Rheum Dis Clin North Am* 2007; 33: 287–297.
- 11 The Practice Committee of American Society for Reproductive Medicine. Multiple pregnancy associated with infertility therapy. *Fertil Steril* 2006; 86: 106–110.
- 12 Yazici Y, Onel K, Sammaritano L. Neonatal lupus erythematosus in triplets. *J Rheumatol* 2000; 27: 807–809.
- 13 Fesslova V, Mannarino S, Salice P, et al. Neonatal lupus: fetal myocarditis progressing to atrioventricular block in triplets. *Lupus* 2003; 12: 775–778.
- 14 Brucato A, Doria A, Frassi M, et al. Pregnancy outcome in 100 women with autoimmune diseases and anti-Ro/SSA antibodies: a prospective controlled study. *Lupus* 2002; 11: 716–721.
- 15 Kanagasegar S, Cimaz R, Kurien BT, Brucato A, Scofield RH. Neonatal lupus manifests as isolated neutropenia and mildly abnormal liver functions. *J Rheumatol* 2002; 29: 187–191.
- 16 Martin V, Lee LA, Askanase AD, Katholi M, Buyon JP. Long-term follow up of children with neonatal lupus and their unaffected siblings. *Arthritis Rheum* 2002; 46: 2377–2383.

**Table 1** The table shows clinical manifestations of NLE in triplets in a review of the literature

	<i>Baby 1</i>	<i>Baby 2</i>	<i>Baby 3</i>
Triplets 1 <sup>12</sup>	Thrombocytopenia photosensitivity	Thrombocytopenia photosensitivity	Thrombocytopenia photosensitivity
Triplets 2 <sup>13</sup>	CHB	Incomplete CHB	Liver enzyme abnormalities
Our case	Neutropenia	Neutropenia	Neutropenia

Abbreviations: CHB: complete heart block.



**Figure 1** The chart represents WBC counts in the three babies from birth to the 3rd month of life. Coloured columns refer to the baby, as shown in the legend. Of each couple, the first column refers to WBC count and the second to neutrophils. The WBC normal range in infants is 8000–30,000/mm<sup>3</sup>. Neutropenia usually occurs for values under 1100/mm<sup>3</sup>.<sup>6</sup>