

IRIS A<sub>per</sub>TO



UNIVERSITÀ  
DEGLI STUDI  
DI TORINO

This is the author's final version of the contribution published as:

Capobianco M; Piccoli G; Neve Vigotti F; Scapoli P; Deagostini MC; Albera C; Roccatello D; Bertolotto A. Interferon beta-related nephropathy and interstitial lung disease: a new association and a long-term warning..

MULTIPLE SCLEROSIS. 20 (7) pp: 889-891.

DOI: 10.1177/1352458513519839

The publisher's version is available at:

<http://msj.sagepub.com/cgi/doi/10.1177/1352458513519839>

When citing, please refer to the published version.

Link to this full text:

<http://hdl.handle.net/2318/147056>

This full text was downloaded from iris - AperTO: <https://iris.unito.it/>

---

iris - AperTO

University of Turin's Institutional Research Information System and Open Access Institutional Repository

## **Interferon beta-related nephropathy and interstitial lung disease: a new association and a long-term warning**

Marco Capobianco, Giorgina Piccoli, Federica Neve Vigotti, Paola Scapoli, Maria Chiara Deagostini, Carlo Albera, Dario Roccatello and Antonio Bertolotto

### **Abstract**

We report on a so-far never described association between glomerulonephritis and sarcoid-like lung disease after long-term interferon beta (IFN $\beta$ ) treatment for relapsing–remitting multiple sclerosis. The interest in this case resides in the documented remission after IFN $\beta$  discontinuation. The history of IFN $\beta$ -related adverse events is probably not yet completely written. The rapid reversal of the pathological signs in our patient underlines the importance of careful clinical and laboratory surveillance, including kidney functional parameters, for an early diagnosis of IFN $\beta$ -related diseases.

### **Keywords**

Disease-modifying therapies, adverse event, sarcoidosis, nephritis

Interferon beta (IFN $\beta$ ) is one of the first-line treatments for relapsing–remitting multiple sclerosis (RRMS). Despite its well-known efficacy and long-term tolerability, in the last decade a growing number of reports have associated long-term IFN $\beta$  therapy with the development of autoimmune diseases, ranging from systemic lupus erythematosus to sarcoidosis and glomerulonephritis. Nevertheless, the pathogenic bases of the IFN $\beta$ -related autoimmune derangements have not yet been completely elucidated (1-4).

In this context, we would like to report on a so-far never described association between glomerulonephritis and sarcoid-like lung disease after long-term IFN $\beta$  treatment for RRMS. The interest in this case also resides in the documented remission after IFN $\beta$  discontinuation.

### **Case report**

In January 1996, a 22-year-old woman developed sub-acute diplopia, and the diagnostic work-up revealed multiple T2+ lesions on brain MRI, cerebrospinal fluid positive for oligoclonal bands and altered somatosensory evoked potentials, suggesting the possibility of MS. She was treated with high-dose i.v. steroids which resulted in remission of the symptoms. After a clinical relapse in 1998 RRMS was diagnosed, and she was started on intramuscular IFN $\beta$ -1a (30 mcg per week) which was administered until March 2003, when she developed a severe clinical relapse involving the midbrain and spinal cord.

A concomitant increase in lesion load was observed at brain MRI. Steroid pulses resulted in remission (Expanded Disability Status Scale (EDSS) 1.0). She was then switched to a higher dose of subcutaneous IFN $\beta$ -1a (44 mcg three times a week), which was continued until June 2011, with complete control of disease activity (no clinical relapses, no increase in lesion load at brain MRI, EDSS 1.0). Blood tests and clinical evaluations were carried out every 6 months throughout the treatment period. Neutralizing antibodies to IFN tested negative, and in vivo MxA mRNA quantification demonstrated a good biological drug activity. In June 2011, she complained of arthralgia and peripheral oedema. Mild hypertension was observed during her clinical examination. Kidney function was normal, urinalysis showed proteinuria and microhematuria, while 24-h proteinuria ranged from 0.8–1.2 g/day. Abdominal ultrasound showed normal-sized kidneys with non-specific bilateral pyramidal hyperechogenicity. During the work-up prior to kidney biopsy, the incidental finding of non-specific derangement of the lung architecture led us to perform thorax CT scan which showed diffuse bronchial wall thickening, bronchiectasias in the lower lobes and enlarged paratracheal lymph nodes. A PET-CT scan showed bilateral pulmonary parenchymal hypercaptation, and foci in the spleen and at the hepatic hilum. Percutaneous kidney biopsy demonstrated thrombotic microangiopathy, glomerular basement membrane reduplication, signs of

mesangiolysis and podocyte hypertrophy. Interestingly, the disease appeared to be limited to the kidney as the patient was not anaemic, serum bilirubin was normal and there were no signs of haemolysis. Complete auto-Abs panel tested negative. Both the kidney and lung diseases were considered to be IFN $\beta$ -related. On account of the stable neurological picture, IFN $\beta$ -1a was discontinued. In the following 6 months the patient remained in neurological remission, proteinuria progressively decreased to 0.33 g/day and PET-CT scan showed complete clearing of the sarcoidlike pattern (Figure 1).

### Discussion

IFN $\beta$ , a type I IFN, is a central regulator of systemic immunity, inducing several genes in both innate and adaptive immune cells by binding to specific receptors and modulating several IFN-stimulated genes. The pro- and anti-inflammatory IFN $\beta$  signature should depend upon the genetic background of each patient and the disease phase. The proinflammatory effect of IFN $\beta$  may lead to the development or exacerbation of autoimmune diseases, and in particular those mediated by Th17 (5). The rising number of reports on the onset of autoimmune diseases after IFN $\beta$  therapy suggests that long-term remissions may merge into an over-activation of the immune system. This may be the case in our patient, who experienced a long-term remission of RRMS but developed a complex autoimmune systemic disease. Possibly on account of the early diagnosis, and despite the substantial morphological kidney damage and the diffuse lung involvement, our patient was only mildly symptomatic and achieved remission of proteinuria and complete clearing of the lung lesions after IFN $\beta$  discontinuation.

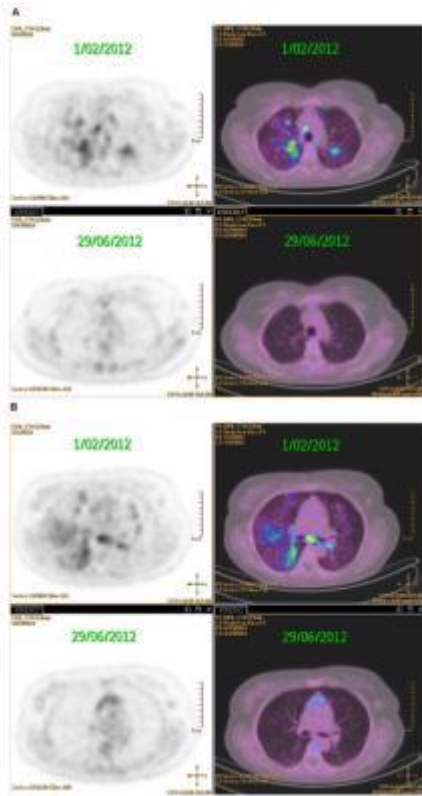
The association between sarcoidosis, glomerular and endothelial lesions and IFN $\beta$  therapy is intriguing, and to the best of our knowledge, it has never been reported before. We did not look for complement genetic abnormalities that could be involved in the pathophysiology of thrombotic microangiopathy, although this seems unlikely owing to the remission of the diseases upon IFN $\beta$  discontinuation. Our case suggests testing the hypothesis that the endothelial and podocyte injury and the lung disease share a common pathogenic factor. A potential culprit may be interleukin 17 (IL17), as sarcoidosis has recently been described as a Th1/Th17 multisystem disorder, while IL17 has been implicated in the pathogenesis of glomerular sclerosis and of autoimmune thrombocytopenia within complex cytokine and cellular derangements (5-8). The history of IFN $\beta$ -related

adverse events is probably not yet completely written. The rapid reversal of the pathological signs in our patient underlines the importance of careful clinical and laboratory surveillance, including kidney functional parameters, for an early diagnosis of IFN $\beta$ -related diseases.

### References

1. Bonaci-Nikolic B, Jeremic I, Andrejevic S, et al. Anti-double stranded DNA and lupus syndrome induced by interferonbeta therapy in a patient with multiple sclerosis. *Lupus* 2009; 18: 78–80.
2. Carbonelli C, Montepietra S, Caruso A, et al. Sarcoidosis and multiple sclerosis: Systemic toxicity associated with the use of interferon-beta therapy. *Monaldi Arch Chest Dis* 2012; 77: 29–31.
3. Markowitz GS, Nasr SH, Stokes MB, et al. Treatment with INF-a, - $\beta$  or - $\gamma$  is associated with collapsing focal segmental glomerulosclerosis. *Clin J Am Soc Nephrol* 2010; 5: 607–615.
4. Olea T, Díaz-Mancebo R, Picazo ML, et al. Thrombotic microangiopathy associated with use of interferon-beta. *Int J Nephrol Renovasc Dis* 2012; 5: 97–100.
5. Broughton A, Cosyns JP and Jadoul M. Thrombotic microangiopathy induced by long-term interferon- $\beta$  therapy for multiple sclerosis: A case report. *Clin Nephrol* 2011; 76: 396–400.
6. Axtell RC, Raman C and Steinman L. Interferon- $\beta$  exacerbates Th17-mediated inflammatory disease. *Trends Immunol* 2011; 32: 272–277.

7. Hu Y, Ma DX, Shan NN, et al. Increased number of Tc17 and correlation with Th17 cells in patients with immune thrombocytopenia. *PLoS One* 2011; 6: e26522.
8. Facco M, Cabrelle A, Teramo A, et al. Sarcoidosis is a Th1/ Th17 multisystem disorder. *Thorax* 2011; 66: 144–150.



**Figure 1.** A) multiple areas of inhomogeneous increased fluoro-dexosi glucose (FDG) uptake in both lungs (SUV max: 4.4) and increased tracer uptake in mediastinal and hilar lymph nodes; B) complete disappearance of abnormal tracer uptake in the thorax, resulting in a negative FDG PET scan. Please go to: [www.http://msj.sagepub.com/](http://msj.sagepub.com/) for colour plates.