

JOURNAL of FORENSIC ODONTO-STOMATOLOGY

VOLUME 30 Number 2 December 2012

SECTION TOOLS AND TECHNIQUE

The Development of a Colorimetric Scale as a Visual Aid for the Bruise Age Determination of Bite Marks and Blunt Trauma

E. Nuzzolese¹, G. Di Vella²

¹ DDS, PhD, Forensic Odontologist, Bari (Italy)

² MD, PhD, Forensic Pathologist, University of Bari (Italy)

Corresponding author: emilionu@tin.it

The authors declare that they have no conflict of interest.


ABSTRACT

Medical examiners and forensic odontologists are frequently asked to establish the age of a bruise or bite mark on either a living and deceased subjects. The age of bruising has an important medico-legal significance and may be relevant in the investigations related to such crimes as child abuse, domestic violence and homicide. A colorimetric scale for forensic photography based on the colors of the bruise itself, has never been proposed due to the fact that photographic reproduction of color is unreliable and depends on several factors; the camera used, lighting, printer and photo-editing color calibration.

The authors propose two colorimetric scales, both with and without linear measurements, and with 90° angulations, six bruise colors, and three circles with black and white calibrators, which are to be used for the forensic photography of injuries involving the epidermis of Caucasian subjects. The two scales could also be employed on living subjects during different stages of the healing process, or on cadavers in order to provide evidential documentation, image verification and analysis. Such an aid would provide a reliable standard condition and allow for color calibration. The colors represented on the scales would be an aid for the interpretation and objectivity required in estimating the age of the bruise, particularly when the analysis is made directly onto computer images prior to printing.

The proposed colorimetric scales do not attempt to give a definitive account of the diverse scientific methods available for the assessment of the age of bruising. The observation of a large sample of blunt trauma and bite mark injuries employing the proposed colorimetric scales would be needed in order to verify and validate the use of these scales. It should be borne in mind that bruise age estimation requires an expert opinion with several degrees of accuracy and variability involved. The age of a bruise cannot be determined by color alone.

KEYWORDS: Bruise age estimation, Bite mark analysis, Forensic odontology, Forensic pathology, Forensic science




INTRODUCTION

Forensic medicine and forensic odontology study the application of both medical and dental science related to legal issues and often employs forensic photography: the medico-legal imaging which involves photographing the relevant findings on the cadaver of victims. Medical examiners and forensic odontologists are frequently asked to establish the age of a bruise on either a living or deceased subject. Injuries may be the result of bite marks or non accidental trauma, and have great medico-legal significance in cases involving child abuse and domestic violence. The duration of bruising will be related to the severity of the trauma in terms of strength and how long force was applied for¹. Color alone is not sufficient in order to determine the age of a bruise², but the variation regarding the color changes may help in age determination and the assessment of blunt trauma injuries and bite marks. Several color changes have been identified in bruises and some, such as yellowing, may indicate that the bruise is over 18 hours old³⁻⁵.

In June of 1996, the U.S. Department of Justice distributed a pamphlet to practitioners involved with investigations concerning child abuse and neglect entitled, "Recognizing When a Child's Injury or Illness is Caused by Abuse"⁶. A specific part of the pamphlet was dedicated to the age determination of bruises and gave an exacting description regarding the color of bruises in direct relation to the age of the bruise itself; red 0-2 days, blue or purple 2-5 days, green 5-7 days, yellow 7-10 days and brown 10-14 days. The exact age of a trauma from photographic evidence alone, remains imprecise and controversial due to the fact that it is difficult to identify the precise color sequences of the healing process in each

individual¹⁻⁷. In addition, an individual may receive two bruises at the same time and exhibit different coloration and a different speed of resolution⁷. However, several attempts have been made in order to provide a color chart guideline for a qualitative evaluation of bruise imaging by visual analysis⁸⁻⁹. A colorimetric scale for forensic photography based on bruise colors has never been proposed, as photographic color reproduction is unreliable and depends on several factors such as, the camera used, lighting, printer and photo-editing color calibration. Visual assessment remains an unreliable method for the age determination of bruises and the accuracy of aging of bruises is not improved by the degree of forensic experience¹⁰. This paper proposes two prototype colorimetric scales which may be used for the forensic photography of epidermal injuries of Caucasian subjects, during different stages of the healing process. The RGB color model proved to be a reliable technique with which to assess the color of a bruise⁸⁻¹⁰. The proposed prototype scales are intended to be used by forensic photographers, crime scene police officers and forensic experts. It should be borne in mind that good quality evidence is fundamental for a more objective forensic assessment and a reduction in observer bias¹¹. Forensic odontologists may not be on the scene of the crime or present during the period of initial assistance of an abused victim and thus, are not able to directly observe bite mark lesions immediately after they have been inflicted. In these circumstances, bite mark analysis could be requested *a posteriori* by either the coroner or the medical examiner, with assessment being possible exclusively via the photographic evidence of the lesions in question. Recent research has demonstrated that the accuracy and the quality of bite mark



evidence will lead to greater disagreement or agreement in the odontologists'

conclusions¹². The evaluation of bruise color remains extremely subjective even when photographic evidence is able to accurately convey the original colors of the lesion at the time the photographs were taken.

BACKGROUND

Various methods, such as metric and angular referencing, are available in order to evaluate both the morphological and dimensional properties of a lesion. As there is no standard color reference that is reliable over time, these do not allow for the determination of the age of a bruise. The ruler type metric device, which is the basic model currently employed, is provided with both linear and angular referencing as well as black and white calibration, and was approved in 1988 in accordance with the scientific publication of Hyzer and Krauss¹³. This paper introduces two devices which are easy to use while photographing or video recording traumatic lesions. This enables additional colorimetry based information to be made available for the age determination of lesions. It is both reliable and reproducible after the images have been analyzed, thus improving the efficacy of forensic photography.

COLORIMETRIC SCALES 'NNDV'

The scales have been named according to the initials of the authors' surnames (Nuzzoleze, Neri, Di Vella). The patent of the invention belongs to the University of XX (Italy). Both scales consist of an L-shaped ruler provided with double references, both dimensional and

colorimetric. Linear references consist of a six centimetre scale per side and three circles, each measuring one inch in diameter. Each circle is divided into four black and white sectors for the black and white levels. Both scales have the same dimensions, but only scale no. 2 has the centimetre reference on both sides (Fig. 1). The colorimetric references consist of six colors pertinent to the various skin color variations of a traumatic bruise lesion; dark red, bluish, purple, greenish, yellow, light brown. The colors, based on the RGB and CMYK color models, have been chosen arbitrarily by reviewing different papers published in related literature^{6, 8-10,14,15} regarding the visual assessment of bruise age determination. CMYK and RGB color specifications: dark red (C:40 M:100 Y:100 K:0; R:168 G:25; B: 25), bluish (C:100 M:70 Y:30 K:0; R:0 G:78; B: 126), purple (C:15 M:50 Y:10 K:0; R:215 G:145; B:177), greenish (C:30 M:30 Y:70 K:0; R:194 G:168; B:92), yellow (C:8 M:8 Y:40 K:0; R:241 G:228; B:168), light brown (C:25 M:80 Y:100 K:0; R:195 G:75; B: 14).

CASE STUDY

The case described in this paper concerns a traumatic accidental injury localized on the left forearm of a young adult. The first photographic evidence was recorded eight hours post trauma using a professional digital camera, (Fig. 2). The second recording of photographic evidence was carried out five days post trauma using the same digital camera, lighting and environment, (Fig. 3). Color scale no. 1 was employed in this case.

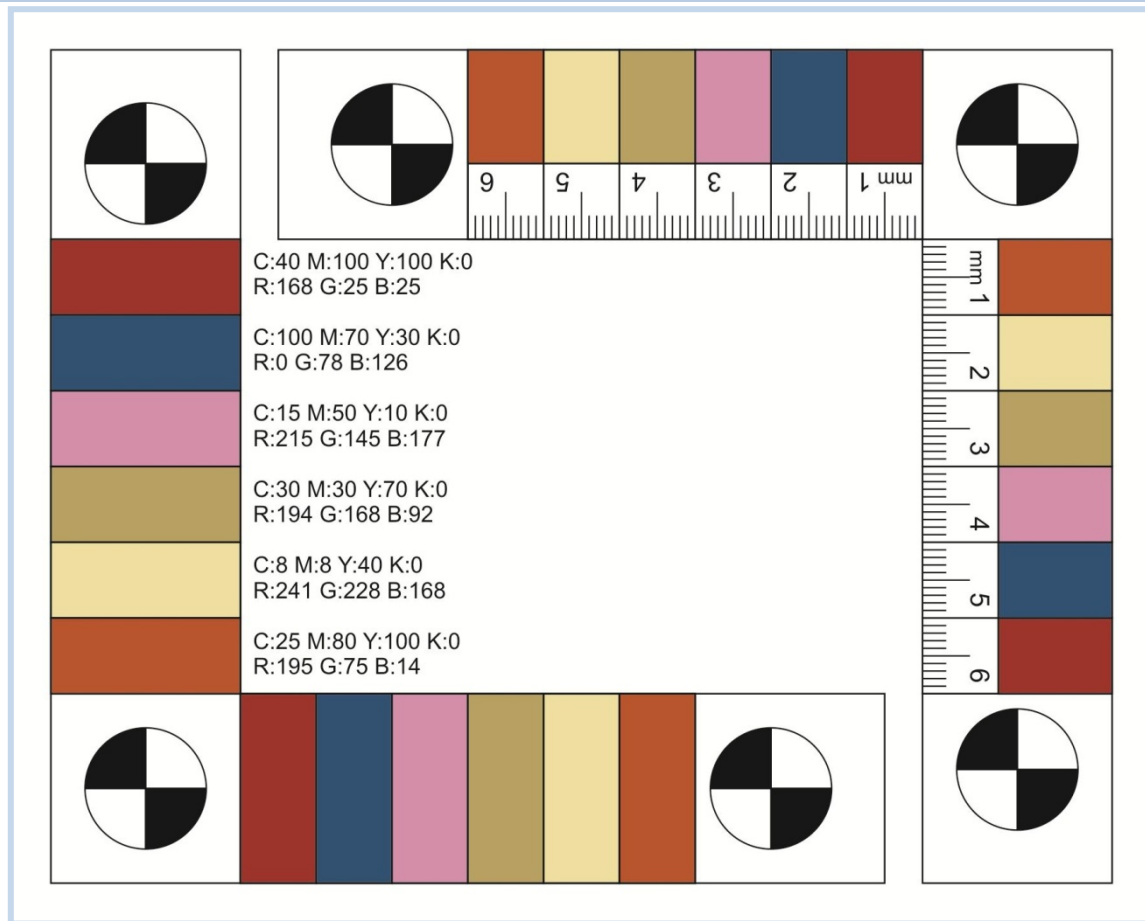


Fig. 1. Colorimetric scales © no. 1 (left) and no. 2 (right) with RGB and CMYK color values.

RESULTS

The proposed scales serve as a guide to the qualitative evaluation of bruise imaging by visual analysis. The devices find widespread use in all cases where photography must be employed for clinical, but above all medico-legal and forensic analysis. In live subjects the use of the scales at different moments in time (e.g. at a time interval of 2, 5-7 or 14-15 days) allows for a comparative evaluation of the evolving color stages of one or more traumatic lesions, and thus serves as a visual aid in the chronological evaluation of bruising. In cadavers, the scales fulfill all qualitative criteria for forensic photography with the additional benefit of supplying a standard colorimetric reference based on the CMYK and RGB

color models allowing for the black and white, and color calibration of the employed digital cameras and photo-editing software.

Figures 1 and 2 demonstrate two traumatic accidental injuries. The findings confirm the visual color aid of color scale no. 1 and color scale no. 2.

DISCUSSION

This study does not attempt to give a definitive account of the different scientific methods available for the assessment of the age of bruising. Pathologists and odontologists have additional options for an objective assessment, including microscopic examination and closer gross assessment

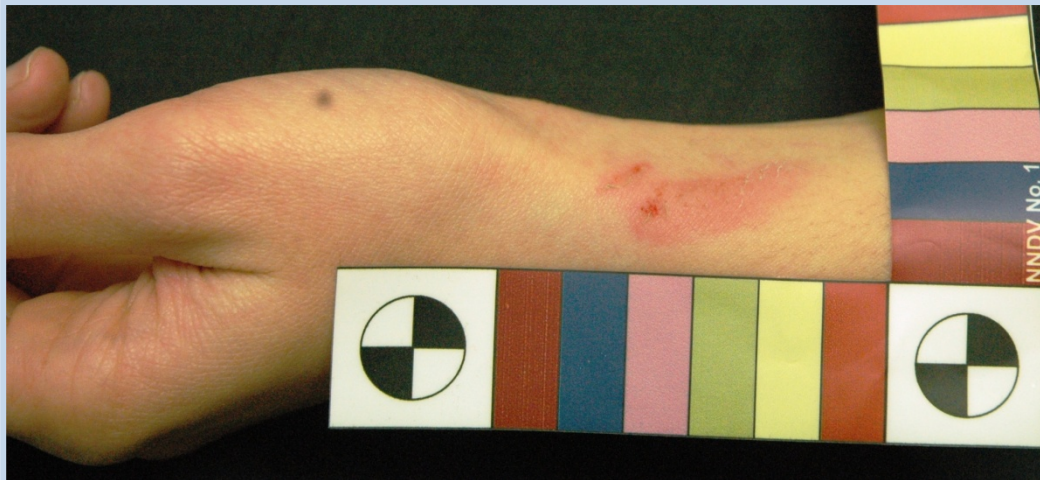
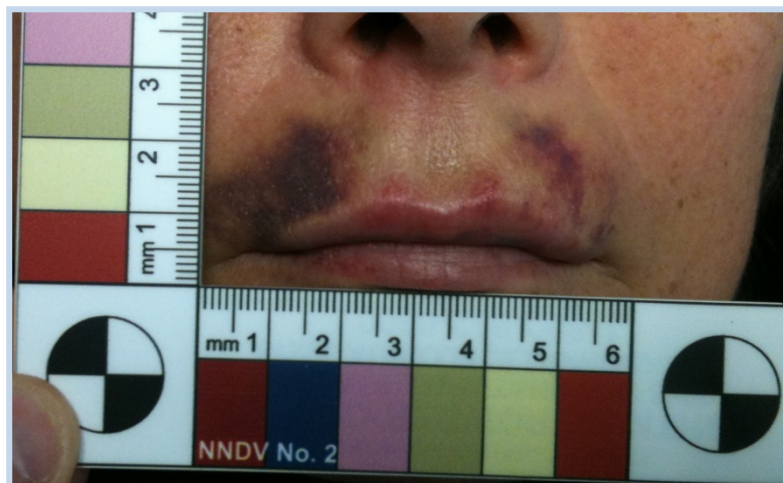
Fig. 2. Left forearm of a young adult: traumatic accidental injury. Photographic evidence was recorded eight hours post trauma, using a professional digital camera and colorimetric scales




© no. 1

Fig. 3. Upper lip of an adult: traumatic accidental injury. Photographic evidence was recorded 1 hour post trauma, using a professional digital camera and colorimetric scales © no. 2.

by dissection. Conventional and specific forensic photography represents one of several aids used to ascertain the age of a bruise¹⁴. It is the authors' opinion that a color aid could assist with the interpretation and accuracy of the determination of bruise age when analyzing photographic evidence, particularly when the analysis is made directly on computer images prior to printing. Such an aid could create a reliable standard condition and allow for colour calibration and chronological order of the trauma particularly when the bruises

pertain to the same individual¹⁵. In some bite mark cases the estimation of the time of injury may become a relevant issue in legal proceedings. This is particularly true when considered along with other lesions which may either be contemporary or prior to the death of the victim. In a live Caucasian subject the bite mark healing process may indicate a time frame, as the bruise would change color from blue to yellow-green, yellow and finally fade from view¹⁶. During court testimonials, it is advisable that the forensic odontologist together with the medical examiner, take



into account all available evidence and not just the bite mark itself¹². Different bruises and bite marks of differing ages may also be an indication of child abuse revealing continual or regular violence¹⁷. In these cases, the use of forensic photography together with the use of a colorimetric scale may provide strong evidence regarding the bruising and ensures a standard and reliable assessment.

The proposed colorimetric scales need to be validated through the observation of a large sample of blunt trauma and bite mark injuries.

Final Remarks

The applied discipline of forensic science is evolving rapidly, and may be classified as interdisciplinary. Fields such as pathology, odontology and forensic photography develop and expand incorporating new methods allowing for a

multi disciplinary involvement and approach. Bruise and bite mark age estimation requires an expert opinion with several degrees of accuracy and variability. The use of color along with all relevant findings and observations pertaining to the investigation, requires experienced and confident observers in order to prevent errors or misjudgment.

Synergy between medical examiners and odontologists is always advisable for an assessment and accurate interpretation in bite mark age evaluation.

Disclosure

The device proposed in this paper is patented "Colorimetric Scale" in the USA with the reference no. 13/225,844. The invention is the property of the University of Bari(Italy); the inventors are: Nuzzoleze Emilio, Di Vella Giancarlo, Neri Margherita.

REFERENCES

- [1] Stephenson T, Bialas Y. Estimation of the age of bruising. *Arch Dis Child*. 1996 Jan;74(1):53-5.
- [2] Maguire S, Mann MK, Sibert J, Kemp A. Can you age bruises accurately in children? A systematic review. *Arch Dis Child*. 2005 Feb;90(2):187-9.
- [3] Langlois NE, Gresham GA. The ageing of bruises: a review and study of the color changes with time. *Forensic Sci Int*. 1991 Sep;50(2):227-38.
- [4] Stephenson T. Ageing of bruising in children. *J R Soc Med* 1997;90:312-314
- [5] Hughes VK, Ellis PS, Langlois NE. The perception of yellow in bruises. *J Clin Forensic Med*. 2004 Oct;11(5):257-9.
- [6] U.S. Department of Justice. Recognizing When a Child's Injury or Illness is Caused by Abuse. Available from: www.ncjrs.gov/pdffiles1/ojdp/160938.pdf [Cited 22 June 2012].
- [7] King BR. Aging Bruises an Inexact Science. *Emergency Medicine News*. 2004 Jul; 26 (7): 10.
- [8] Georgieva L, et al. Computer-aided System for the Bruise Color's Recognition, International Conference on Computer Systems and Technologies - CompSysTech' 2005. Available from: <http://ecet.ecs.ru.acad.bg/cst05/Docs/cp/SHH/IIIA.23.pdf> [Cited 22 June 2012].
- [9] Dimitrova T, Georgieva L, Pattichis C, Neofytou M. Qualitative visual image analysis of bruise age determination: a survey. *Conf Proc IEEE Eng Med Biol Soc*. 2006;1:4840-3.
- [10] Grossman SE, Johnston A, Vanezis P, Perrett D. Can we assess the age of bruises? An attempt to develop an objective technique. *Med Sci Law*. 2011 Jul;51(3):170-6.
- [11] Page M, Taylor J, Blenkin M. Context Effects and Observer Bias-Implications for Forensic Odontology. *J Forensic Sci*. 2011 Aug 19.
- [12] Bowers CM, Pretty IA. Expert disagreement in bite mark casework. *J Forensic Sci* 2009;54:915-8.
- [13] Hyzer WG, Krauss TC. The bite mark standard reference scale ABFO No. 2. *J Forensic Sci* 1988;33(2): 498-506.
- [14] Vanezis P. Interpreting bruises at necropsy. *J Clin Pathol* 2001;54:348-355
- [15] Pilling ML, Vanezis P, Perrett D, Johnston A. Visual assessment of the timing of bruising by forensic experts. *J Forensic Leg Med*. 2010 Apr;17(3):143-9.
- [16] Davis JH. Histology and timing of injury. In: Dorion B, editor. *Bitemark evidence, 2nd edition*, Boca Raton. CRC Press, 2011. p. 197.
- [17] Mimasaka S, Ohtani M, Kuroda N, Tsunenari S. Spectrofotometric evaluation of the age of bruises in children: measuring changes in bruise color as an indicator of child physical abuse. *Tohoku J Exp Med*. 2010, 220: 171-175.
