

CASE REPORT

Focused tight dressing does not prevent cochlear implant magnet migration under 1.5 Tesla MRI

La fasciatura compressiva focalizzata non previene la dislocazione del magnete in pazienti con impianto cocleare durante risonanza magnetica nucleare (RMN) a 1,5 Tesla

D. CUDA¹, A. MURRI¹, G. SUCCO²

¹ Department of Otolaryngology, Guglielmo da Saliceto Hospital, Piacenza, Italy; ² Department of Otolaryngology, S. Luigi Hospital, Torino University, Orbassano (TO), Italy

SUMMARY

We report a retrospective case of inner magnet migration, which occurred after 1.5 Tesla MRI scanning in an adult recipient of a bilateral cochlear implant (CI) despite a focused head dressing. The patient, bilaterally implanted with Nucleus 5 CIs (Cochlear LTD, Sydney, Australia), underwent a 1.5 Tesla cholangio-MRI scan for biliary duct pathology. In subsequent days, a focal skin alteration appeared over the left inner coil. Plain skull radiographs showed partial magnet migration on the left side. Surgical exploration confirmed magnet twisting; the magnet was effectively repositioned. Left CI performance was restored to pre-migration level. The wound healed without complications. Thus, focused dressing does not prevent magnet migration in CI recipients undergoing 1.5 Tesla MRI. All patients should be counselled on this potential complication. A minor surgical procedure is required to reposition the magnet. Nevertheless, timely diagnosis is necessary to prevent skin breakdown and subsequent device contamination. Plain skull radiograph is very effective in identifying magnet twisting; it should be performed systematically after MRI or minimally on all suspected cases.

KEY WORDS: Cochlear implant • Complication • Magnet migration • Head dressing • MRI • Inner coil

RIASSUNTO

Segnaliamo il caso di un soggetto adulto con parziale migrazione del magnete dopo esecuzione di Risonanza Magnetica nucleare (RMN) a 1,5 Tesla, in un paziente adulto con impianto cocleare bilaterale nonostante le misure precauzionali adottate, quali la fasciatura compressiva in corrispondenza del magnete. Il paziente, portatore di impianto cocleare Cochlear Nucleus serie 5 (Cochlear LTD, Sydney, Australia) bilaterale, è stato sottoposto a colangio-RMN con apparecchiatura da 1,5 Tesla, poiché affetto da epatocolocolitiasi. Nei giorni seguenti è comparsa una lesione cutanea in corrispondenza dell'antenna a sinistra. La radiografia del cranio ha evidenziato una parziale migrazione del magnete. L'esplorazione chirurgica ha confermato tale reperto e il magnete è stato correttamente riposizionato nella sua sede abituale. Le abilità percettivo-uditive del paziente con l'impianto cocleare di sinistra erano sovrapponibili a quelle pre-operatorie. Non vi sono state complicanze post-operatorie. In conclusione, la medicazione compressiva in corrispondenza dell'antenna non previene la possibile migrazione di magnete in pazienti sottoposti a RMN a 1,5 Tesla. Tutti i pazienti dovrebbero essere informati sui rischi e le misure da adottare ogni qualvolta si debba eseguire un esame di risonanza magnetica nucleare, anche in presenza di device compatibili con l'esecuzione della stessa. Il riposizionamento del magnete richiede un intervento chirurgico, pur trattandosi di una complicanza minore. È necessaria una tempestiva diagnosi della migrazione del magnete per evitare complicanze cutanee e la successiva contaminazione del ricevitore-stimolatore. La radiografia del cranio consente una corretta diagnosi di migrazione del magnete e dovrebbe essere eseguita dopo RMN o almeno nei casi sospetti.

PAROLE CHIAVE: *Impianto cocleare • Complicanza • Migrazione del magnete • Medicazione compressiva del capo • RMN*

Acta Otorhinolaryngol Ital 2013;33:133-136

Introduction

Cochlear implantation (CI) is now the treatment of choice for both children and adults with severe-to-profound or profound sensorineural hearing loss. In fact, most CI recipients report enhanced quality of life and have high scores on open set speech recognition tests¹⁻³. The procedure is generally safe and well tolerated, although compli-

cations are occasionally observed. The complications are categorized as major or minor depending on the treatment required. Major complications need aggressive medical or surgical treatment, and include facial nerve palsy, incorrect electrode placement, wound infection, soft or hard device failure, middle ear infection and flap failure⁴. Minor complications usually resolve spontaneously or require minor surgical procedures. One such minor com-

plication is magnet migration. Some cochlear implant devices are designed to accommodate the inner magnet in a receiver stimulator pocket. In these cases, the magnet can be temporarily removed to allow patients to undergo high strength (3 Tesla) MRI without risks. Unfortunately, as a consequence of head trauma, the magnet can twist out of its location⁵⁻⁷. This same effect can be produced by standard 1.5 Tesla MRI; for these reasons, MRI strength limitations are imposed by manufacturers and prevention strategies like head dressing are suggested⁸.

Here we report an unusual case of magnet twisting despite device-focused head dressing after 1.5 Tesla MRI in a bilateral CI recipient.

Case report

A 72-year-old male with profound, sensorineural hearing loss due to *Streptococcus pneumoniae* meningitis underwent simultaneous bilateral cochlear implantation (Nucleus 5, CI512; Cochlear LTD, Sydney, Australia). Ten months after the operation he scored 85% on an open set disyllabic words test. This patient was a full time, satisfied, cochlear implant user. At this time, because of biliary duct pathology, a standard 1.5 Tesla cholangio-MRI was required. According to the manufacturer's recommendations, the inner magnet was not removed but a tight large compressive head dressing was used to hold it in place during scanning. The dressing was reinforced by pressure focusing points on the scalp just over the inner coils. The pressure focus was realized by an external silicone plug inserted under the dressing as suggested by Devenuve et al.⁸. The plug (Fig. 1A) was made by two overlapping reinforced silicone slices of 1 mm thickness each (Atos Medical, Hörby, Sweden). A 2 mm thick silicone sheet was shaped corresponding to the inner coil (Fig. 1B).

MRI examination was performed without complications. However, the day after the patient reported a deep pain and heating of the skin above the device on left side. The skin appearance seemed normal and the patient continued to wear his speech processor. The pain continued over 24 hours. A local skin alteration became gradually more evident in subsequent days. The patient did not complain of fever or tenderness. One week later, medical examination was required. A local, crusty, skin lesion was observed under the patient's left external coil at its centre (Fig. 2). At local palpation, the internal magnet did not appear to be displaced from its normal location. The external coil was worn normally. The magnet was found attached to the skin with more strength than usual. He scored 85% on an open set, disyllabic words test; this is consistent with the test session preceding the MRI exam. Electrode impedances were also unremarkable.

Anteroposterior and lateral plain skull radiographs were obtained. In the anteroposterior view (Fig. 3A-B), the left




Fig. 1. Silicone plug used under head dressing. (A) The plug is made with two overlapping disks of 1 mm thickness each. (B) The shape and size of plug is identical to the inner coil.



Fig. 2. Focal skin-crust lesion on left side, at the centre of the external coil position.

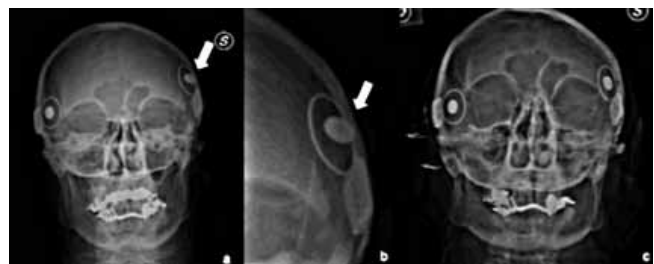


Fig. 3. Anteroposterior skull radiograph. (A) Left magnet (white arrow) migration is evident. (B) Detail of left displaced magnet. (C) Normalized position of magnet after revision surgery.

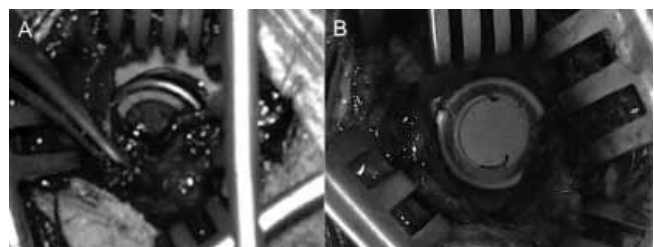


Fig. 4. (A) After partial dissection of the fibrous capsule, the cochlear implant magnet appeared partially dislodged from the silicone envelope. (B) The cochlear implant magnet was repositioned into its seat.

magnet was found to be twisted out of its central location within the inner coil. The right magnet was in its normal position.

Minor revision surgery was performed under local anaesthesia. A 2.5 cm skin incision was made superiorly to the crusted area. The subcutaneous layers were dissected. Next, a dense fibrous capsule enveloping the receiver stimulator was opened in a blunt manner over the magnet bulge, and the magnet was found to be partially twisted off its silicone envelope (Fig. 4A). About one half of the magnet was still in the silicone pocket, while the other one was out. An angle of about 45° was found between the receiver stimulator plane and the magnet. The magnet border protruded toward the skin. No purulent collection was found. A soft tissue specimen was taken for microbiological cultures. There was no evidence of bacterial growth on subsequent days. The magnet was fully restored into its pocket (Fig. 4B), and the wound was closed with absorbable material (Vicryl, Ethicon LTD, UK) and a light-pressure bandage was applied for two days. The postoperative course was uneventful. The speech processor use was temporarily interrupted. One week later, the wound had healed and the speech processor was turned on. Cochlear implant impedances and speech recognition scores were unchanged. Six months after revision surgery no local problems were apparent and functional results were stable.

Discussion

Traumatic magnet displacement is a well-known minor complication in patients who have a CI with a removable magnet such as the Nucleus 5 (Cochlear LTD, Sydney, Australia) or HiRes devices (Advanced Bionics, LLC, Valencia - CA, USA). In order to allow temporary removal when a 3 Tesla MRI examination is required, the magnet is placed in a small round silicone envelope that has a central opening and an over-hanging rim. Nevertheless, this predisposes the magnet to possible displacement following an external force such as head trauma⁷⁻⁹.

The effects of MRI on CI recipients are well known; they include heating of the skin above the receiver stimulator, image artefacts in head scan, interactions with ferromagnetic components of the CI and partial or complete CI magnet demagnetization¹⁰. Moreover, a strong MRI field can twist the magnet despite progress in device design to improve tolerance with this examination. MRI tolerance depends on strength of the field used¹⁰. According to the manufacturer's specifications, with the Nucleus 5 system there is no need to remove the magnet and no bandaging is required for strengths up to 0.2 Tesla. At levels above 0.2 and up to 1.5 Tesla the patient can undergo the exam with the magnet in place, but compressive dressing is necessary to prevent magnet twisting. Cadaver studies and clinical experiences have shown no significant demagnetiza-

tion or magnet migration in MRI levels up to 1.5 Tesla; a bulky mastoid compression dressing which provides light device pressure can prevent its migration¹¹. In cases that require 3 Tesla MRI, the magnet should be removed and reimplanted after the examination¹⁰.

Magnet displacement during MRI with compressive dressing has been previously described by Deneuve et al.⁸; these authors suggested focused compression using an external silastic plug on the device under the dressing should be used.

The patient we describe had magnet displacement using a 1.5 Tesla MRI despite focused dressing over the inner magnet as suggested. It is not clear if bilateral CI could have increased the risk of magnet twisting.

This report demonstrates that a tight, focused dressing is not an effective means to prevent CI inner magnet migration. Although are based on some evidence, the manufacturer's recommendations may reduce, but not eliminate, migration risk with MRI. The risk-benefit ratio to undergo a 1.5 Tesla MRI with a tight, focused bandage should be evaluated on a case-by-case basis. In particular, parents of implanted children must always be aware of the risk of magnet migration under MRI examination.

The recovery operation seems simple and effective. Furthermore, a more conservative approach has been recently described by Di Nardo et al.¹² consisting in manual external repositioning of displaced magnet.

In any case, regardless of the procedure used, timing is crucial. In fact, potentially severe evolution can occur in the case of delayed diagnosis because of possible skin breakdown with subsequent device contamination. High clinical suspicion index and proper counselling are therefore necessary to manage this mild, but potentially severe complication. In particular, plain skull radiographs seem to be a reliable tool to confirm magnet displacement. Since magnet twisting is asymptomatic at the beginning, one can speculate that there may be need to perform the radiograph, systematically, after all cases of 1.5 Tesla MRI rather than just on suspected cases. Unfortunately, the incidence of this complication is unknown and requires more data.

References

- 1 Waltzman SB, Fisher SG, Niparko JK, et al. *Predictors of postoperative performance with cochlear implants*. Ann Otol Rhinol Laryngol Suppl 1995;165:15-8.
- 2 Berettini S, Baggiani A, Bruschini L, et al. *Systematic review of the literature on the clinical effectiveness of the cochlear implant procedure in adult patients*. Acta Otorhinolaringol Ital 2011;31:299-310.
- 3 Turchetti G, Belelli S, Palla I, et al. *Systematic review of the scientific literature on the economic evaluation of cochlear implant in adult patients*. Acta Otorhinolaringol Ital 2011;31:319-27.
- 4 Cohen NL, Hofman RA. *Complications of cochlear implant*

- surgery in adults and children.* Ann Otol Rhinol Laryngol 1991;100:708-11.
- ⁵ Wild C, Allum A, Probst R, et al. *Magnet displacement: a rare complication following cochlear implantation.* Eur Arch Otorhinolaryngol 2010;267:57-9.
- ⁶ Storkroos RJ, van Dijk P. *Migration of cochlear implant magnets after head trauma in an adult and a child.* Ear Nose Throat J 2007;86:612-3.
- ⁷ Migirov L, Kronenberg J. *Magnet displacement following cochlear implantation.* Otol Neurotol 2005;26:646-8.
- ⁸ Deneuve S, Loundon N, Leboulanger N, et al. *Cochlear implant magnet displacement during magnetic resonance imaging.* Otol Neurotol 2008;29:789-90.
- ⁹ Wilkinson EP, Dogru S, Meyer TA, et al. *Case report: cochlear implant magnet migration.* Laryngoscope 2004;114:2009-11.
- ¹⁰ Risi F, Saldanha A, Leigh R, et al. *Magnetic resonance imaging safety of Nucleus 24 Cochlear Implants at 3.0 T.* International Congress Series 2004;1273:394-8.
- ¹¹ Gubbels SP, McMenomey SO. *Safety study of the cochlear nucleus 24 device with internal magnet in the 1.5 Tesla magnetic resonance imaging scanner.* Laryngoscope 2006;116:865-71.
- ¹² Di Nardo W, Giannantonio S, Schinaia L, et al. *Noninvasive Management of Cochlear Implant's inner magnet displacement after magnetic resonance: a case report.* Laryngoscope 2013;123:783-6.

Received: October 10, 2012 - Accepted: January 14, 2013