



UNIVERSITÀ DEGLI STUDI DI TORINO

This is an author version of the contribution published on:

Questa è la versione dell'autore dell'opera:

Acta Neurologica Belgica, 2014, 114(3), pp. 229-231.

Doi: 10.1007/s13760-013-0203-9

The definitive version is available at:

La versione definitiva è disponibile alla URL:

[<http://link.springer.com/article/10.1007%2Fs13760-013-0203-9>]

Pontine compression caused by “surgiceloma” after trigeminal decompression: case report and literature review

Davide Boeris^{1,2}, Alexander I. Evins², Michele Maria Lanotte¹, Sergio Zeme¹, Alessandro Ducati¹.

1. Department of Neurosurgery, University of Turin, Turin, Italy

2. Department of Neurological Surgery, Weill Cornell Medical College, Cornell University, New York, New York, USA.

Introduction

After microvascular decompression of cranial nerve V or VII, Surgicel[®] and Tissucol[®] were used in 200 cases at our institution. They were uneventfully inserted between the impinging artery and pons to keep the vessels away from the cranial nerves and against the tentorium or the dura covering the rocca petrosa. We report a case in which a patient developed delayed hemiparesis and packed Surgicel[®] without blood was found as the only cause of compression.

Case report

A 46-year-old female underwent a microvascular decompression of the left trigeminal nerve for relief of intractable trigeminal neuralgia. A left retrosigmoid craniotomy was performed and a conflict with the main trunk of the anterior-inferior cerebellar artery (AICA) was eliminated. The artery was dissected from its arachnoid adhesions and subsequently laid away from the nerve. As is standard at our institution, Surgicel[®] was packed between the artery and the pons to keep the vessel against the rocca petrosa, and was covered with a small amount of Tissucol[®]. No perioperative complications were noted. The patient recovered from the anesthesia without neurological deficit or trigeminal pain. Approximately 6 h after surgery, the patient developed progressive right hemiparesis that was limited with, but not reversed by, administration of corticosteroids. The patient immediately underwent a head CT, but the imaging was unremarkable and did not show any intracranial hemorrhage or other visible abnormality. A subsequent MRI showed a limited area of edema and ischemia in the left lateral pons, compressed by an adjacent small mass lesion which appeared slightly hyperintense on T1-weighted images and hypointense on T2-weighted images (Fig. 1). MR angiography was unremarkable and showed a patent left AICA. The patient underwent immediate reoperation to remove the small mass. The packed Surgicel[®] and Tissucol[®] were completely removed. The hemiparesis improved several hours postoperative and completely resolved within 72 h.

Discussion

Non-absorbable cotton or cellulose surgical sponges do not undergo regeneration or oxidation and should be removed from the patient at the conclusion of the surgical procedure. Twentieth century advances in hemostatic agents and anticoagulatory devices led to the widespread adoption of bio-absorbable Surgicel[®], which is often left in situ. Preliminary studies suggested that the hemostatic mechanism of Surgicel[®] was mechanical, promoting coagulation through physical pressure, but later studies showed that oxidation of the product causes it to have a very low pH and results in the formation of an artificial clot through a caustic process^[6, 9]. The product begins to undergo absorption within 24 h of placement, and is absorbed at a variable rate depending on the amount of the product, type of tissue involved, and degree of tissue perfusion^[6, 9]. The presence of giant cells has been reported within 1 week, disappearing with the product 1-2 months after surgery^[10].

Compression of nervous structures by packed Surgicel[®] has been reported in only a few cases after spinal surgery (Table 1). Banerjee et al. [3] reported the first case of "surgiceloma" in 1998 which manifested as cauda equine syndrome. After reoperation, swollen blood-soaked Surgicel[®] was found to be the only cause of compression. Two cases of compressive optic neuropathy were reported in 2005 by Arat et al. [1], both of which required reoperation. Four cases of spinal cord compression after thoracotomy were also found in the literature [2, 4, 5].

Fig 1: Axial FLAIR MRI showing a small well-defined round hyperintense mass occupying the left perimesencephalic cistern.

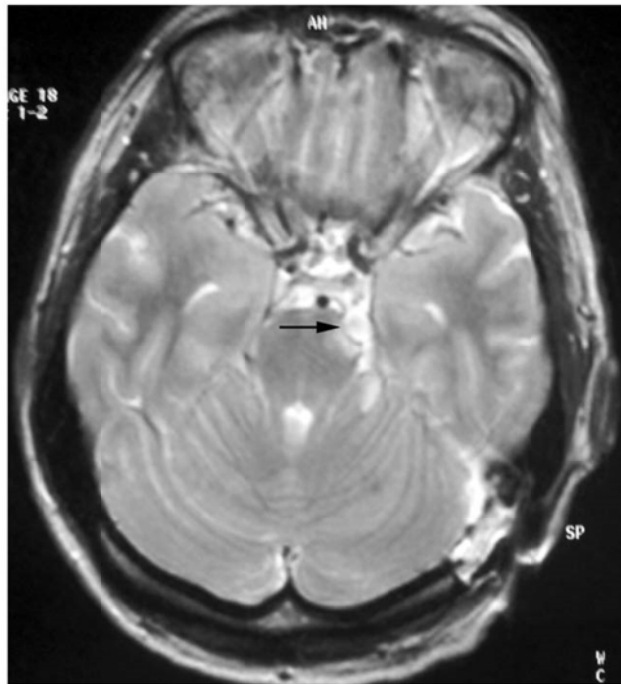


Table 1: Surgiceloma cases reported in literature.

First author	Years	No. of patients	Notes
Banerjee	1998	1	Surgiceloma presented as cauda equina syndrome
Iwabuchi	1997	1	Paraplegia after thoracotomy
Brodbelt	2002	3	Paraplegia after thoracotomy
Arat	2006	2	Compressive optic neuropathy
Boeris (present study)	2011	1	Hemiparesis due to surgiceloma

Several cases of Surgicel[®] mimicking brain abscesses and recurrent tumors are reported in the literature [7, 8, 10, 11]. According to this writing, no cases of midbrain compression inducing hemiparesis have been reported. A slow rate of fluid absorption or a late introduction of fluid to the

packed Surgicel® would be consistent with delayed onset of postoperative complications, as seen here. In this case, the early compressive effect of the packed surgical could be explained by the small volume of the subarachnoid cisterns, due to a short trigeminal root and the relatively young age of the patient.

Conclusion

During microvascular decompression of trigeminal and facial nerve, great care should be taken in dissecting arachnoid structures around the impinging vessels, so that the artery can move spontaneously away from the nerve. In patients with a small cisternal space around the pons, due to young age and/or a short trigeminal root, a minimal amount of absorbable material should be used, if at all. In cases of clinically suspected pontine ischemia, this mechanism should be considered.

Conflict of Interest

None.

References

1. Arat YO, Dorotheo EU, Tang RA, Boniuk M, Schiffman JS (2006), Compressive optic neuropathy after use of oxidized regenerated cellulose in orbital surgery: review of complications, prophylaxis, and treatment. *Ophthalmology*, 113(2), pp. 333-337.
2. Awwad EE, Smith KR Jr (1999), MRI of marked dural sac compression by surgicel in the immediately postoperative period after uncomplicated lumbar laminectomy. *J Comput Assist Tomogr*, 23, pp. 969-975.
3. Banerjee T, Goldschmidt K (1998), 'Surgiceloma' manifested as cauda equina syndrome. *South Med J*, 91(5), pp. 481-483.
4. Brodbelt AR, Miles JB, Foy PM, Broome JC (2002), Intraspinal oxidised cellulose (Surgicel) causing delayed paraplegia after thoracotomy—a report of three cases. *Ann R Coll Surg Engl*, 84, pp. 97-99.
5. Iwabuchi S, Koike K, Okabe T, Tago S, Murakami T (1997), Iatrogenic paraplegia caused by surgicel used for hemostasis during a thoracotomy: report of a case. *Surg Today*, 27, pp. 969-970.
6. Johnson and Johnson (2005), Surgicel prescribing information. http://www.ethicon360emea.com/sites/default/files/products/Surgicel%20Original_NuKnit%20IFU_1.pdf. Accessed 9 Sep 2012.
7. Kothbauer KF, Jallo GI, Siffert J, Jimenez E, Allen JC, Epstein FJ (2001). Foreign body reaction to hemostatic materials mimicking recurrent brain tumor. Report of three cases. *J Neurosurg*, 95, pp. 503-506.
8. Otenasek FJ, Otenasek RJ Jr (1968). Dangers of oxidized cellulose in chiasmal surgery. Report of two cases. *J Neurosurg*, 29, pp. 209-210.
9. Pierce AM, Wiebkin OW, Wilson DF (1984), Surgicel: its fate following implantation. *J Oral Pathol*, 13(6), pp. 661-670.
10. Sandhu GS, Elexpuru-Camiruaga JA, Buckley S (1996), Oxidized cellulose (Surgicel) granulomata mimicking tumour recurrence. *Br J Neurosurg*, 10, pp. 617-619.
11. Young ST, Paulson EK, McCann RL, Baker ME (1993), Appearance of oxidized cellulose (Surgicel) on postoperative CT scans: similarity to postoperative abscess. *Am J Roentgenol*, 160, pp. 275-277.