

CASE REPORT

Itraconazole as 'bridge therapy' to anti-IgE in a patient with severe asthma with fungal sensitisation

Stefano Pizzimenti, Claudia Bussolino, Iuliana Badiu, Giovanni Rolla

Department of Allergy and Clinical Immunology, University of Torino & AO Ordine Mauriziano, Torino, Italy

Correspondence to
Professor Giovanni Rolla,
grolla@mauriziano.it

SUMMARY

Sensitisation to fungi has been reported to play an important role in a particular phenotype of severe asthma, the so-called severe asthma with fungal sensitisation, characterised by high levels of total IgE, which may be an obstacle to anti-IgE therapy. We describe here the case of a polysensitised woman with refractory asthma, sensitised to *Aspergillus fumigatus* with high total IgE values (1793 kUA/l), but without the diagnostic criteria for allergic bronchopulmonary aspergillosis. Additional therapy with itraconazole leads to the decrease of total IgE to the limits recommended for proper omalizumab dosing (30–1500 kUA/l). Itraconazole, used as bridge therapy, provided us the opportunity to start anti-IgE treatment in a patient with high levels of total IgE, beyond the upper limits recommended for proper prescription of omalizumab.

INTRODUCTION

In patients with severe persistent allergic asthma, omalizumab has been shown to improve the quality of life by reducing asthma exacerbation and emergency visit rates.¹ Total IgE values are requested to be in the limits range from 30 to 1500 kUA/l in order to properly prescribe the drug. A few studies reported favourable effects of antifungal therapy in improving the quality of life of asthmatic patients with fungal sensitisation, in whom a significant decrease of total IgE has also been observed.

CASE PRESENTATION

A 59-year-old woman with uncontrolled severe asthma and frequent exacerbations, requiring courses of oral steroids, while on therapy with salmeterol/high-dose inhaled fluticasone and montelukast was evaluated for possible allergic bronchopulmonary aspergillosis (ABPA). She was sensitised to *Aspergillus fumigatus*, house dust mites and grass pollen.

INVESTIGATIONS

Serum total IgE level, measured during the off-pollen season, was 1793 kUA/l, with specific grass, house dust mites, *Dermatophagoides pteronyssinus* and *A fumigatus* IgE, respectively, of 15.3, 8.4 and 11.3 kUA/l. No peripheral eosinophilia was found and *Aspergillus* precipitins were absent.

Lung high-resolution CT did not show bronchiectases or lung infiltrates. Pulmonary function tests showed moderate obstruction: forced expiratory volume in 1 s/vital capacity (FEV1/VC) 57%, with FEV1 72% predicted. The concentration of fractional exhaled nitric oxide (FENO) was very high

(102 ppb, normal values <25 ppb) and Asthma Control Test (ACT) revealed a poor control (score=9, controlled=25, partially controlled \geq 20 and <25).

DIFFERENTIAL DIAGNOSIS

Our patient did not fulfil the diagnostic criteria for ABPA, while the sensitisation to *A fumigatus* in the context of severe asthma with worsened control was indicative of severe asthma with fungal sensitisation (SAFS).

TREATMENT

The patient started itraconazole therapy (200 mg twice daily) as an add-on therapy for 12 weeks. After treatment, a significant decrease of total IgE (1043 ng/ml) was found with no improvement in asthma control (ACT changed from 9 to 12). At that time, omalizumab was started at the recommended doses (300 mg every 2 weeks) and therapy with salmeterol/high dose inhaled fluticasone and montelukast was continued.

OUTCOME AND FOLLOW-UP

Table 1 shows the improvement in asthma control during 16 weeks of observation.

After 4 months of anti-IgE therapy, the patient did not report any exacerbation and the ACT score improved from 9 to 23, indicating good asthma control. The monthly prednisone cumulative dose decreased through the observation period and the days without symptoms increased (figure 1). On the other hand, the respiratory function and FENO did not change.

DISCUSSION

In patients with SAFS, a disorder closely related to ABPA, the addition of itraconazole to the maximal asthma therapy may improve the symptoms and pulmonary function and decrease the serum IgE levels.² Vicencio *et al*³ described the case of a dramatic decrease of total IgE serum levels in a child with SAFS after 6 months itraconazole therapy; they also reported a significant improvement in pulmonary function and asthmatic symptoms.

However, in our patient, the antifungal add-on treatment did not improve the symptoms and pulmonary function, while it caused the decrease of total IgE levels, providing us an opportunity to start omalizumab at the recommended doses with a favourable change in asthma control.

We cannot exclude that omalizumab, administered alone as an off-label medication, could have caused the same beneficial effects, even without

To cite: Pizzimenti S, Bussolino C, Badiu I, *et al*. *BMJ Case Rep* Published online: [please include Day Month Year] doi:10.1136/bcr-2012-008462

Table 1 Clinical data and pulmonary function during anti-IgE therapy

	0	4 weeks	8 weeks	12 weeks	16 weeks
FEV1% predicted	79	78	79	80	80
FEV1/VC (%)	57	55	58	61	60
FENO (ppb)	102	97	101	88	93
Number of exacerbations/month	2.08	2	1	1	0
Monthly Prednisone consumed (mg)	210	150	75	75	0
Consecutive days without symptoms	1.03	3	5	8	12
ACT	9	16	18	22	23

ACT, Asthma Control Test; FENO, fractional exhaled nitric oxide; FEV, forced expiratory volume in 1 s; VC, vital capacity.

itraconazole. Actually, a recent real-life study confirmed that omalizumab is very efficacious in patients with uncontrolled severe asthma, even in the subgroup of patients with IgE levels >700 IU/ml (upper limits were not indicated).⁴ In patients with ABPA and very high IgE levels, omalizumab has been used, in association with prednisone and itraconazole, both of which may decrease the total IgE levels, with reduced asthma exacerbations

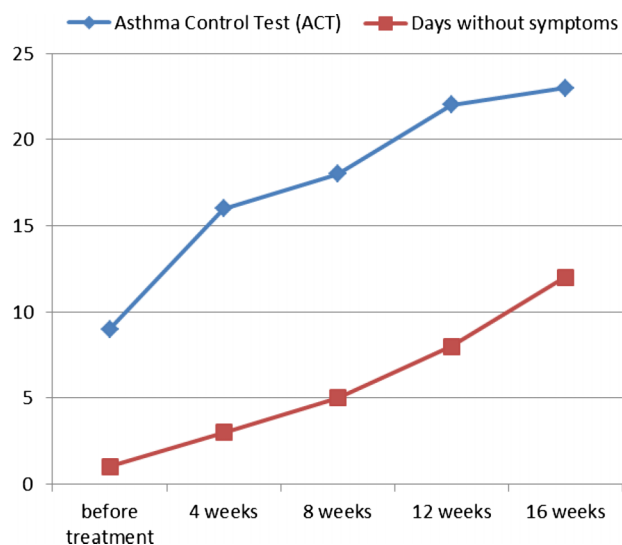


Figure 1 Improvement in asthma control during 16 weeks anti-IgE therapy.

tions and a systemic steroid burden.⁵ To date, omalizumab has not been specifically studied in SAFS. Fungal sensitisation has been reported to be associated with asthma severity,^{6,7} and in particular *A fumigatus* sensitisation and ABPA have been associated with progressive lung function decline.⁸ Additional studies are required to fully establish the role of antifungal therapy in severe asthma. Also, more data are needed to understand the relationship between sensitisation, airway colonisation and lung function.

Learning points

- ▶ Fungal sensitisation plays an important role in severe asthma.
- ▶ Omalizumab has been shown to improve the quality of life, reducing asthma exacerbations.
- ▶ Antifungal therapy, through the decrease of total IgE, may provide the opportunity to start anti-IgE therapy at the usual recommended doses in patients with SAFS.

Competing interests None.

Patient consent Obtained.

Provenance and peer review Not commissioned; externally peer reviewed.

REFERENCES

- 1 Holgate S, Buhl R, Bousquet J, *et al*. The use of omalizumab in the treatment of severe allergic asthma: a clinical experience update. *Respir Med* 2009;103:1098–113.
- 2 Denning DW, O'Driscoll BR, Powell G, *et al*. Randomized controlled trial of oral antifungal treatment for severe asthma with fungal sensitization: the Fungal Asthma Sensitization Trial (FAST) study. *Am J Respir Crit Care Med* 2009;179:11–18.
- 3 Vicencio AG, Muzumdar H, Tsirilakis K, *et al*. Severe asthma with fungal sensitisation in a child: response to itraconazole therapy. *Pediatrics* 2010;125:e1255–8.
- 4 Vennera MC, Perez DLL, Bardagi S, *et al*. Omalizumab therapy in severe asthma: experience from the Spanish registry—some new approaches. *J Asthma* 2012;49:416–22.
- 5 Moss RB. The use of biological agents for the treatment of fungal asthma and allergic bronchopulmonary aspergillosis. *Ann N Y Acad Sci* 2012;1272:49–57.
- 6 O'Driscoll BR, Powell G, Chew F, *et al*. Comparison of skin prick test with specific serum immunoglobulin E in the diagnosis of fungal sensitisation in patients with severe asthma. *Clin Exp Allergy* 2009;39:1677–83.
- 7 Zureik M, Neukirch C, Leynaert B, *et al*. Sensitization to airborne moulds and severity of asthma: cross sectional study from European community respiratory health survey. *BMJ* 2002;325:411–14.
- 8 Kraemer R, Delosea N, Ballinari P, *et al*. Effect of allergic bronchopulmonary aspergillosis on lung function in children with cystic fibrosis. *Am J Respir Crit Care Med* 2006;174:1211–20.

Copyright 2013 BMJ Publishing Group. All rights reserved. For permission to reuse any of this content visit <http://group.bmj.com/group/rights-licensing/permissions>.
BMJ Case Report Fellows may re-use this article for personal use and teaching without any further permission.

Become a Fellow of BMJ Case Reports today and you can:

- ▶ Submit as many cases as you like
- ▶ Enjoy fast sympathetic peer review and rapid publication of accepted articles
- ▶ Access all the published articles
- ▶ Re-use any of the published material for personal use and teaching without further permission

For information on Institutional Fellowships contact consortiasales@bmjgroup.com

Visit casereports.bmj.com for more articles like this and to become a Fellow