

IRIS A<sub>per</sub>TO



UNIVERSITÀ  
DEGLI STUDI  
DI TORINO

This is the author's final version of the contribution published as:

De Bellis A;Sinisi AA;Pane E;Dello Iacovo A;Bellastella G;Di Scala G;Falorni A;Giavoli C;Gasco V;Giordano R;Ambrosio MR;Colao A;Bizzarro A;Bellastella A;Italian Autoimmune Hypophysitis Network Group.  
Involvement of hypothalamus autoimmunity in patients with autoimmune hypopituitarism: role of antibodies to hypothalamic cells.. THE JOURNAL OF CLINICAL ENDOCRINOLOGY AND METABOLISM. 97 pp: 3684-3690.  
DOI: 10.1210/jc.2012-2269

The publisher's version is available at:  
<http://press.endocrine.org/doi/abs/10.1210/jc.2012-2269>

When citing, please refer to the published version.

Link to this full text:  
<http://hdl.handle.net/2318/132084>

This full text was downloaded from iris - AperTO: <https://iris.unito.it/>

---

iris - AperTO

University of Turin's Institutional Research Information System and Open Access Institutional Repository

# **INVOLVEMENT OF HYPOTHALAMUS AUTOIMMUNITY IN PATIENTS WITH AUTOIMMUNE HYPOPITUITARISM: ROLE OF ANTIBODIES TO HYPOTHALAMIC CELLS**

A. De Bellis, A. A. Sinisi, E. Pane, A. Dello Iacovo, G. Bellastella, G. Di Scala, A. Falorni, C. Giavoli, V. Gasco, R. Giordano, M. R. Ambrosio, A. Colao, A. Bizzarro, and A. Bellastella, on behalf of the Italian Autoimmune Hypophysitis Network Group

Departments of Cardiothoracic and Respiratory Sciences (A.D.B., A.A.S., E.P., A.D.I., G.B., A.Ba.) and Clinical and Experimental Medicine and Surgery “F. Magrassi, A. Lanzara” (G.D.S., A.Bi.), Second University of Naples, 80131 Naples, Italy; Department of Internal Medicine, Section of Internal Medicine and Endocrine and Metabolic Sciences (A.F.), University of Perugia, 06123 Perugia, Italy; Department of Clinical and Community Health, University of Milan, Endocrine and Diabetology Unit (C.G.), Istituto di Ricovero e Cura a Carattere Scientifico, Fondazione Ca Granda Ospedale Maggiore Policlinico, Milan, 20100 Milan, Italy; Department of Internal Medicine, Division of Endocrinology and Metabolism (V.G., R.G.), University of Turin, 10124 Turin, Italy; Department of Biomedical Sciences and Advanced Therapies, Section of Endocrinology (M.R.A.), University of Ferrara, 44121 Ferrara, Italy; and Department of Molecular and Clinical Endocrinology and Oncology, Section of Endocrinology (A.C.), University “Federico II” of Naples, 80138 Naples, Italy

Address all correspondence and requests for reprints to: Annamaria De Bellis, Ph.D., Chair of Endocrinology, Department of Cardiothoracic and Respiratory Sciences, Second University of Naples via Pansini N. 5, 80131 Napoli, Italy. E-mail: annamaria.debellis@unina2.it.

This work was supported in part by University Research Grants 2009, Second University of Naples (to A.Be.), and Young Italian Researchers Grant 2008: GR-2008-1137632 (to G.B.).

Disclosure Summary: The authors have nothing to disclose.

## **Acknowledgments**

In addition to the authors, the following members of the Italian Autoimmune Hypophysitis Network Study contributed to the collection of data and blood samples from patients with autoimmune pituitary diseases: E. Arvat (Turin), P. Beck-Peccoz (Milan), C. Betterle (Padova), S. Cannavo` (Messina), L. Chiovato (Pavia), M. Delvecchio (S. Giovanni Rotondo), L. De Marinis (Roma), E. Degli Uberti (Ferrara), R. Giordano (Turin), E. Ghigo (Turin), M. Maghnie

(Genova), F. Mantero (Padova), L. Persani (Milan), M. Rotondi (Pavia), A. Spada (Milan), and M. C. Zatelli (Ferrara). Moreover, we thank Professor F. Kelestimur and F. Tanriverdi, Department of Endocrinology, Erciyes University Medical School, Kayseri, Turkey, for their contributions of blood samples and data of patients with autoimmune pituitary diseases.

## **Abstract**

**Context:** Antipituitary antibodies (APA) but not antihypothalamus antibodies (AHA) are usually searched for in autoimmune hypopituitarism.

**Objective:** Our objective was to search for AHA and characterize their hypothalamic target in patients with autoimmune hypopituitarism to clarify, on the basis of the cells stained by these antibodies, the occurrence of autoimmune subclinical/clinical central diabetes insipidus (CDI) and/or possible joint hypothalamic contribution to their hypopituitarism.

**Design:** We conducted a cross-sectional cohort study.

**Patients:** Ninety-five APA-positive patients with autoimmune hypopituitarism, 60 without (group 1) and 35 with (group 2) lymphocytic hypophysitis, were studied in comparison with 20 patients with postsurgical hypopituitarism and 50 normal subjects.

**Main Outcome Measures:** AHA by immunofluorescence and posterior pituitary function were evaluated; then AHA-positive sera were retested by double immunofluorescence to identify the hypothalamic cells targeted by AHA.

**Results:** AHA were detected at high titer in 12 patients in group 1 and in eight patients in group 2. They immunostained arginine vasopressin (AVP)-secreting cells in nine of 12 in group 1 and in four of eight in group 2. All AVP cell antibody-positive patients presented with subclinical/clinical CDI; in contrast, four patients with GH/ACTH deficiency but with APA staining only GH-secreting cells showed AHA targeting CRH-secreting cells.

**Conclusion:** The occurrence of CDI in patients with lymphocytic hypophysitis seems due to an autoimmune hypothalamic involvement rather than an expansion of the pituitary inflammatory process. To search for AVP antibody in these patients may help to identify those of them prone to develop an autoimmune CDI. The detection of AHA targeting CRH-secreting cells in some patients with GH/ACTH deficiency but with APA targeting only GH-secreting cells indicates that an autoimmune aggression to hypothalamus is jointly responsible for their hypopituitarism.

## Introduction

The pituitary autoimmunity is a complex spectrum of defined conditions such as histologically proven or suspected lymphocytic hypophysitis (LYH) causing autoimmune hypopituitarism, associated in the majority of cases with the presence of antipituitary antibodies (APA) (1–5).

It has been also shown that central diabetes insipidus (CDI) may occur in some patients with proven/suspected LYH as a result of possible expansion of an inflammatory process from anterior to posterior lobe, with swelling of the pars tuberalis of the adenohypophysis covering the infundibulum laterally and consequent inhibition of the axonal transport of antidiuretic hormone (4, 6, 7).

However, many years ago, Scherbaum et al. (8) showed that CDI could be caused by an autoimmune process to magnocellular hypothalamic neurons secreting arginine vasopressin (AVP); in fact, antibodies against AVP-secreting cells (AVPcAb) were detected in sera of many patients with idiopathic subclinical/clinical CDI (9–11).

Furthermore, Scherbaum (12) showed that sera of some patients with idiopathic CDI and of some patients with autoimmune polyendocrine syndrome without CDI immunostained unidentified small hypothalamic non-AVP-secreting cells, suggesting that they could be hypothalamic releasing-hormone-secreting cells.

Many years later, Tanriverdi and colleagues (13, 14) showed that not only APA but also antihypothalamus antibodies (AHA) can be present in patients with hypopituitarism secondary to Sheehan's syndrome and in boxers with late hypopituitarism secondary to cranial trauma, suggesting that a hypothalamic autoimmunity could have a role in the pathogenesis of hypopituitarism.

However, the role of hypothalamus autoimmunity in patients with isolated or multiple pituitary hormone deficiencies with or without LYH and with or without CDI has been so far not investigated.

The aim of this study was to search for AHA in patients with autoimmune hypopituitarism, previously found positive for APA, evaluating in those who were AHA positive, by a four-layer double immunofluorescence, whether the cells targeted by these antibodies were AVP-secreting cells or other hypothalamic cells, such as, in particular, CRH-secreting cells. This was to clarify whether a concomitant autoimmune aggression to the hypothalamus, rather than an expansion of the inflammatory pituitary process to posterior pituitary and infundibulum, may be responsible in these patients for the occurrence of CDI and/or may contribute to their hypopituitarism.

## Patients and Methods

### Patients

From 2004–2011 in the Immunoendocrinology Laboratory of the Second University of Naples, we performed an APA screening by indirect immunofluorescence in sera of a large cohort of patients with idiopathic hypopituitarism sent to our laboratory by the Italian autoimmune hypophysitis Network Study Group and other several International Endocrinological Units. Ninety-five of these patients, found positive for APA at high titers and presenting with autoimmune hypopituitarism and single or multiple pituitary hormone deficiencies, were recruited and grouped as follows: sixty (14 males, 46 females; mean age 31.5 yr, age range 26–37 yr) without histological or magnetic resonance imaging (MRI) findings of LYH (group 1), and 35 (eight males, 27 females; mean age 32 yr, age range 25–38 yr) with biopsy-proven or MRI-suspected LYH (group 2) on the basis of the criteria previously reported in the literature (7, 15–21). Immunological and clinical findings of patients of both groups are illustrated in Table 1.

The diagnosis of hypopituitarism had been made following the criteria previously described (22, 23). In particular, ACTH deficiency (ACTH-D), in the presence of normal or low basal serum levels of ACTH, had been suspected when the 0800-h cortisol level was below 193 nmol/liter and confirmed by an impaired cortisol response to the 1- $\mu$ g tetracosactide test (<497 nmol/liter). GH-D had been diagnosed in presence of low-normal basal IGF-I and impaired GH response to the GHRH plus arginine test (GH peak <9.0  $\mu$ g/liter). Gonadotropin deficiency had been diagnosed in males when basal testosterone levels were below the normal range (total testosterone <9 nmol/liter) in the presence of normal or low gonadotropin levels. A similar diagnosis in females had been supported by serum estradiol levels lower than 40 pmol/liter associated with inappropriately low serum gonadotropin concentrations. TSH-D had been diagnosed in patients with inappropriately low serum TSH levels in the presence of subnormal serum free T4 and free T3 concentrations.

Posterior pituitary function was studied in all patients.

AHA were searched for in all patients. Moreover, the presence of antibodies to AVP-secreting cells and to CRH-secreting cells in all those positive for AHA was also investigated by four-layer double immunofluorescence. As controls, AHA were searched for in 20 patients with hypopituitarism secondary to hypophysectomy and in 50 sex- and age-matched healthy subjects. The 20 patients with postsurgical hypopituitarism and the 50 healthy subjects were the same ones that had been studied and published in a previous paper (24). All patients and controls gave their informed consent to the protocol, which was approved by the local institutional review board.

## Methods

### AHA evaluation

AHA were detected by a simple indirect immunofluorescence method on cryostat sections of young baboon hypothalamus supplied by Biomedis srl (Porto San Giorgio, Italy), as previously described (9, 13, 14). In particular, unfixed cryostat sections of young normal baboon hypothalamus were initially incubated with the sera. Then, serum samples were subsequently tested with fluorescein isothiocyanate-conjugated goat antihuman Ig. We considered AHA positive at middle titer when ranging from 1:16 to 1:32 and at high titer when over 1:32. However, taking into account the low specificity of the immunofluorescence method, we considered for our analysis only the patients positive for AHA at high titer.

Sera of all patients positive for AHA were retested by a four-layer double immunofluorescence, as previously reported (9, 10,

24) to verify whether hypothalamic cells targeted by these antibodies were AVP-secreting cells or other hypothalamic cells, in particular CRH-secreting cells. To this purpose, sera positive for AHA were retested in a second step on the same hypothalamic cryostat section, with specific rabbit anti-AVP sera (supplied by Histo-Line Laboratories srl, Milan, Italy) or anti-CRH sera (Biogenesis Ltd., Poole, UK, supplied by Histo-Line), respectively, followed by rhodamine antirabbit Ig.

The different colors of the anti-Ig conjugates against the human serum and against the animal serum, respectively, green (fluorescein isothiocyanate) and red (rhodamine), allowed direct assessment of whether the patient's serum and the animal's serum stained the same (AVP- or CRH-secreting cells, respectively) or different hypothalamic cells.

### Posterior pituitary function

The diagnosis of CDI was suspected on the basis of polyuria and polydipsia and urinary and plasma osmolality and confirmed by a dehydration plus desmopressin administration test, as previously described (9, 10, 25). An increase of urinary osmolality from 10–50% or more than 50% after desmopressin injection was taken to indicate partial or complete CDI. Moreover, in all patients, the diagnosis of complete or partial CDI was confirmed by the evaluation of plasma AVP levels after the dehydration test; an absent or subnormal AVP response to the water-deprivation test were confirmatory of complete or partial CDI, respectively (9, 26).

### Statistical analysis

Statistical analysis was performed by using the SPSS version 13.0 program. Data are expressed as mean  $\pm$  SD, unless otherwise specified. Nonparametric tests were used because of the non-Gaussian distribution of the data. Differences between the frequencies were evaluated by  $\chi^2$  test.

The differences between the groups were compared by unpaired t test, and nonnormally distributed data were compared by Mann-Whitney U test. In addition, Pearson or Spearman's correlation analysis was performed to determine whether significant correlations existed between chosen variables.  $P < 0.05$  was considered statistically significant.

## Results

On the basis of characterization of types of pituitary hormone-secreting cells targeted by APA, previously performed by four-layer double immunofluorescence, 53 patients in group 1 and 29 in group 2 had shown correlation between the kind of pituitary hormone deficiency and the type of pituitary hormone-secreting cells targeted by APA. In particular, in 43 patients in group 1 and 18 in group 2 with isolated GH-D, ACTH-D, LH-/FSH-D or TSH-D, APA had been seen targeting selectively pituitary GH-, ACTH-, LH-/FSH-, or TSH-secreting cells, respectively. Instead, among the 34 patients with combined pituitary hormone deficiencies, seven in group 1 and six in group 2 had shown APA targeting only one type of pituitary hormone-secreting cell (Table 1).

AHA were present in 34 of 95 patients with autoimmune hypopituitarism (37.8%) and in particular in 20 of 60 in group 1 (33.3%) and 14 of 35 in group 2 (40%); these antibodies were present at high titer (from 1:64 to 1:256) in 12 in group 1 and in eight in group 2 (Fig. 1) although at middle titer ( $<1:32$ ) in eight patients in group 1 and in six in group 2. AHA were absent in all patients with hypopituitarism secondary to hypophysectomy and in normal subjects.

CDI occurred in 13 of 95 patients with autoimmune hypopituitarism (13.7%), of whom nine (five in clinical and four in subclinical phase) in group 1 (15%) and four (all in clinical phase) in group 2 (11.4%); no significant difference of frequency of CDI was observed between group 1 and group 2.

All 13 patients with CDI were positive for AHA, whereas none of the AHA-negative patients showed CDI; thus, a higher significant frequency of CDI was evidenced in AHA-positive patients with respect to those negative for these antibodies ( $P < 0.001$ ). No significant difference of sex, age, type of hypopituitarism, association with other autoimmune disease, APA titer, or morphological findings on MRI were observed between AHA-positive and AHA-negative patients.

In all 13 patients with CDI, AHA were present at high titer and showed selectively or prevalently immunostaining of magnocellular hypothalamic cells (type 1 pattern, Fig. 2A).



In the remaining seven AHA-positive patients at high titer but without CDI (three in group 1 and four in group 2), these antibodies immunostained selectively small hypothalamic cells (type 2 pattern, Fig. 2B).

When considering the previously performed characterization of types of pituitary hormone-secreting cells targeted by APA, some patients with CDI (five in group 1 and two in group 2) had shown specific correspondence between the kind of pituitary hormone deficiency and the type of pituitary hormone-secreting cells stained by APA.

In other patients with CDI (four in group 1 and two in group 2) and in all patients without CDI and with combined pituitary hormone deficiencies, APA was shown targeting only one type of pituitary hormone-secreting cells.

The results of double immunofluorescence in sera of AHA-positive patients showed that in all CDI patients with type 1 pattern the magnocellular hypothalamic cells stained by AHA were AVP-secreting cells (Fig. 2C). Moreover, in four patients (two in group 1 and two in group 2) presenting with GH-D associated with ACTH-D but with APA targeting only the somatotrophs and with type 2 pattern of AHA, the double immunofluorescence showed that AHA stained mainly small hypothalamic cells, identified as CRH-secreting cells (Fig. 2D).

Instead, in the remaining two AHA-positive patients with ACTH-D, one in group 1 associated with TSH-D and one in group 2 associated with FSH-/LH-D, in whom APA had stained only ACTH-secreting cells, the double immunofluorescence showed that AHA were directed against unknown small hypothalamic cells different from CRH-secreting cells. Moreover, in none of AHA-positive patients without ACTH-D did AHA stain CRH-secreting cells. The characteristics of 20 patients with AHA at high titer and the behavior of posterior pituitary function are illustrated in Table 2.

## Discussion

The first result of our study is the finding, for the first time, of AHA in some patients with isolated or combined pituitary deficiencies with or without proven/suspected LYH and with or without CDI.

Another point emerging from our results is the occurrence of CDI exclusively in AHA-positive patients. Interestingly, CDI occurred not only in those with expansion of pituitary gland to suprasellar region but also mostly in those without significant increased volume of pituitary gland on MRI.

In particular, our study evidenced that in all CDI patients with autoimmune hypopituitarism, AHA were present at high titer (>1:64) and were directed prevalently to magno- cellular hypothalamic cells, identified as AVP-secreting cells by double immunofluorescence.

In a previous study, performed in patients with CDI with or without pituitary stalk thickening on MRI, we showed in the affected patients the presence of AVPcAb at high titer, independently from the presence of pituitary stalk thickening (27).

The occurrence of CDI in patients with proven/sus- pected LYH has been usually attributed either to direct immune destruction or to compression of the posterior lobe or the infundibulum (4, 7, 8, 16, 17); however, studies regarding the presence of subclinical/clinical CDI in pa- tients with autoimmune hypopituitarism without definite or suspected findings of LYH are lacking.

On the basis of the results of the present study, we conclude that the occurrence of CDI in patients with proven/suspected LYH can be often caused by a con- comitant autoimmune process involving hypothalamic AVP-secreting cells, even if it sometimes may be also associated with the expansion of inflammatory pro- cesses to the posterior lobe and by compression of the infundibulum. Thus, many of our APA-positive patients, found even positive for AHA identified as AVPcAb, may be considered as having an autoimmune CDI, associated with autoimmune pituitary dysfunction (28), despite apparently normal pituitary characteristics on MRI.

This also suggests that a simultaneous occurrence of subclinical/clinical autoimmune CDI in patients with au- toimmune hypophysitis may be more frequent than has been so far known and should lead to a search for AVPcAb in these patients to identify those of them prone to develop an autoimmune CDI. However, the possibility of inter- rupting the progression to a clinically overt disease in these patients is still under discussion. To tell the truth, in some other autoimmune endocrine diseases (29 –31), a treat- ment with the hormone of the gland aggressed by the im- mune process in an early stage, when the gland is not yet completely destroyed, seems to be able to interrupt the autoimmune cascade, thus allowing in some cases the re- covery of its function. However, the poor data appeared in the literature regarding an early therapy in patients with autoimmune CDI (10, 29, 32) do not allow us to draw decisive conclusions about this, because only one paper was based on a longitudinal study of a small cohort of patients with subclinical autoimmune CDI (10) and with one being a case report (32). Thus, additional longitudinal studies on a more numerous cohort of patients with po- tential/subclinical CDI associated with autoimmune hy- popituitarism are needed to clarify these aspects.

Another message emerging from our study is that in many AHA-positive patients with autoimmune hypopitu- itarism, associated or not with CDI, these antibodies im- munostained prevalently small hypothalamic non-AVP- secreting cells. Interestingly, the previously performed characterization of APA by double immunofluorescence in these patients had

shown that these antibodies targeted only one type of pituitary hormone-secreting cell despite the occurrence of combined pituitary deficiencies.

In a recent study performed in patients with idiopathic ACTH deficiency, we detected in some of them APA targeting selectively pituitary ACTH-secreting cells and in others AHA targeting small hypothalamic cells that resulted, by double immunofluorescence, mainly CRH-secreting cells, suggesting an interesting possibility to differentiate secondary from tertiary variants of autoimmune hypoadrenalism (24).

In the present study, we found that in some AHA-positive patients with GH-D associated with ACTH-D, previously found positive for APA targeting only somatotrophs but not adrenocorticotrophs, AHA immunostained prevalently small hypothalamic cells, identified by double immunofluorescence as CRH-secreting cells. These results indicate in these patients a possible association of GH-D, caused by an autoimmune aggression to pituitary GH-secreting cells, with a tertiary form of hypoadrenalism caused by autoimmune aggression to hypothalamic CRH-secreting cells. With this in mind, we can suppose that, in patients with other combined pituitary hormone deficiencies, including LH/FSH-D or TSH-D and lack of correspondence with the respective pituitary cells targeted by APA, the occurrence of their hypopituitarism could be the result of an autoimmune aggression to the corresponding releasing hormone-secreting cells. However, the lack of studies using the four-layer double immunofluorescence for the characterization of other types of hypothalamic cells targeted by AHA (which are in progress) suggests caution against a generalization of our assumption. In conclusion, our results, taken together, indicate that the occurrence of CDI in subclinical/clinical forms in our patients with LYH seems to be more frequent than that so far known. The finding of AHA immunostaining AVP-secreting cells in these patients suggests that an autoimmune process involving the hypothalamus, rather than an expansion of the pituitary inflammatory process, may be responsible for their CDI. Thus, to search for AVPcAb in these patients may be a useful tool to identify those of them

who are prone to develop a clinically overt disease. Finally, the detection of AHA targeting small hypothalamic cells identified as CRH-secreting cells in some patients with GH- ACTH-D but with APA staining only GH-secreting cells indicates that not only pituitary but also hypothalamic autoimmunity may contribute to their anterior pituitary dysfunction. Thus, these patients may be considered as falling into some types of autoimmune polyendocrine syndrome, when their hypothalamic-pituitary autoimmune dysfunctions are associated with other endocrine and/or nonendocrine autoimmune diseases.



## References

1. Mauerhoff T, Mirakian R, Bottazzo GF 1987 Autoimmunity and the pituitary. In: Doniach D, Bottazzo GF, eds. Endocrine and other organ-oriented autoimmune disorders. Bailliere's clinical immunology and allergy. Vol. 1. London: WB Saunders; 217–235
2. Cheung CC, Ezzat S, Smyth HS, Asa SL 2001 The spectrum and significance of primary hypophysitis. *J Clin Endocrinol Metab* 86: 1048–1053
3. De Bellis A, Ruocco G, Battaglia M, Conte M, Coronella C, Tirelli G, Bellastella A, Pane E, Sinisi AA, Bizzarro A, Bellastella G 2008 Immunological and clinical aspects of lymphocytic hypophysitis. *Clin Sci* 114:413–421
4. Rivera JA 2006 Lymphocytic hypophysitis: disease spectrum and approach to diagnosis and therapy. *Pituitary* 9:35–45
5. Manetti L, Lupi I, Morselli LL, Albertini S, Cosottini M, Grasso L, Genovesi M, Pinna G, Mariotti S, Bogazzi F, Bartalena L, Martino E 2007 Prevalence and functional significance of antipituitary antibodies in patients with autoimmune and non-autoimmune thyroid diseases. *J Clin Endocrinol Metab* 92:2176–2181
6. Ezzat S, Josse RG 1997 Autoimmune hypophysitis. *Trends Endocrinol Metab* 8:74–80
7. Caturegli P, Newschaffer C, Olivi A, Pomper MG, Burger PC, Rose NR 2005 Autoimmune hypophysitis. *Endocr Rev* 26:599–614
8. Scherbaum WA, Bottazzo JF, Slater JD 1983 Autoantibodies to vasopressin cells in idiopathic diabetes insipidus: evidence for an autoimmune variant. *Lancet* 1:897–901
9. De Bellis A, Bizzarro A, Amoresano Paglionico V, Di Martino S, Criscuolo T, Sinisi AA, Lombardi G, Bellastella A 1994 Detection of vasopressin cell antibodies in some patients with autoimmune endocrine diseases without overt diabetes insipidus. *Clin Endocrinol (Oxf)* 40:173–177
10. De Bellis A, Colao A, Di Salle F, Muccitelli VI, Iorio S, Perrino S, Pivonello R, Coronella C, Bizzarro A, Lombardi G, Bellastella A 1999 A longitudinal study of vasopressin cell antibodies, posterior pituitary function, and magnetic resonance imaging evaluations in subclinical autoimmune central diabetes insipidus. *J Clin Endocrinol Metab* 84:3047–3051
11. Bellastella A, Bizzarro A, Colella C, Bellastella G, Sinisi AA, De Bellis A 2012 Subclinical diabetes insipidus. *Best Pract Res Clin Endocrinol Metab* 10.1016/j.beem.2011.11.008
12. Scherbaum WA 1987 Role of autoimmunity in hypothalamic disorders. In: Doniach D, Bottazzo GF, eds. Bailliere's clinics in immunology and allergy. Vol. 1. London: WB Saunders; 237–245

13. De Bellis A, Kelestimur F, Sinisi AA, Ruocco G, Tirelli G, Battaglia M, Bellastella G, Conzo G, Tanriverdi F, Unluhizarci K, Bizzarro A, Bellastella A 2008 Anti-hypothalamus and anti-pituitary antibodies may contribute to perpetuate the hypopituitarism in patients with Sheehan's syndrome. *Eur J Endocrinol* 158:147–152
14. Tanriverdi F, De Bellis A, Bizzarro A, Sinisi AA, Bellastella G, Pane E, Bellastella A, Unluhizarci K, Selcuklu A, Casanueva FF, Kelestimur F 2008 Antipituitary antibodies after traumatic brain injury: is head trauma-induced pituitary dysfunction associated with autoimmunity? *Eur J Endocrinol* 159:7–13
15. De Bellis A, Bizzarro A, Conte M, Perrino S, Coronella C, Solimeno S, Sinisi AM, Stile LA, Pisano G, Bellastella A 2003 Antipituitary antibodies in adults with apparently idiopathic growth hormone deficiency and in adults with autoimmune endocrine diseases. *J Clin Endocrinol Metab* 88:650 – 654
16. Bellastella A, Bizzarro A, Coronella C, Bellastella G, Sinisi AA, De Bellis A 2003 Lymphocytic hypophysitis: a rare or underestimated disease? *Eur J Endocrinol* 149:363–376
17. Caturegli P, Lupi I, Landek-Salgado M, Kimura H, Rose NR 2008 Pituitary autoimmunity. 30 years later. *Autoimmun Rev* 7:631– 637
18. Crock PA 1998 Cytosolic autoantigens in lymphocytic hypophysitis. *J Clin Endocrinol Metab* 83:609 – 618
19. Tashiro T, Sano T, Xu B, Wakatsuki S, Kagawa N, Nishioka H, Yamada S, Kovacs K 2002 Spectrum of different types of hypophysitis in 31 cases. *Endocr Pathol* 13:183–195
20. Gutenberg A, Buslei R, Fahlbusch R, Buchfelder M, Brück W 2005 Immunopathology of primary hypophysitis: implications for pathogenesis. *Am J Surg Pathol* 29:329 –338
21. De Bellis A, Bizzarro A, Bellastella A 2011 Pituitary autoimmunity. In: Eisenbarth G, ed. *Immunoendocrinology: scientific and clinical aspects, contemporary endocrinology*. New York: Humana Press; 547–567
22. Bellastella G, Rotondi M, Pane E, Dello Iacovo A, Pirali B, Dalla Mora L, Falorni A, Sinisi AA, Bizzarro A, Colao A, Chiovato L, De Bellis; A Italian Autoimmune Hypophysitis Network Study 2010 Predictive role of the immunostaining pattern of immunofluorescence and the titers of antipituitary antibodies at presentation for the occurrence of autoimmune hypopituitarism in patients with autoimmune polyendocrine syndromes over a five-year follow-up. *J Clin Endocrinol Metab* 95:3750 –3757
23. De Bellis A, Bizzarro A, Perrino S, Coronella C, Conte M, Pasquali D, Sinisi AA, Betterle C, Bellastella A 2005 Characterization of antipituitary antibodies targeting pituitary hormone-secreting cells in idiopathic growth hormone deficiency and autoimmune endocrine disease. *Clin Endocrinol (Oxf)* 63:45– 49

24. De Bellis A, Pane E, Bellastella G, Sinisi AA, Colella C, Giordano R, Giavoli C, Lania A, Ambrosio MR, Di Somma C, Zatelli MC, Arvat E, Colao A, Bizzarro A, Bellastella A. Italian Autoimmune Hypophysitis Network Study 2011 Detection of antipituitary and antihypothalamus antibodies to investigate the role of pituitary or hypothalamic autoimmunity in patients with selective idiopathic hypopituitarism. *Clin Endocrinol (Oxf)* 75:361–366
25. Pivonello R, De Bellis A, Faggiano A, Di Salle F, Petretta M, Di Somma C, Perrino S, Altucci P, Bizzarro A, Bellastella A, Lombardi G, Colao A 2003 Central diabetes insipidus and autoimmunity: relationship between the occurrence of antibodies to arginine vasopressin-secreting cells and clinical, immunological, and radiological features in a large cohort of patients with central diabetes insipidus of known and unknown etiology. *J Clin Endocrinol Metab* 88: 1629–1636
26. Miller M, Dalakos T, Moses AM, Fellerman H, Streeten DH 1970 Recognition of partial defects in antidiuretic hormone secretion. *Ann Intern Med* 73:721–729
27. De Bellis A, Colao A, Bizzarro A, Di Salle F, Coronella C, Solimeno S, Vetrano A, Pivonello R, Pisano G, Lombardi G, Bellastella A 2002 Longitudinal study of vasopressin-cell antibodies and of hypothalamic-pituitary region on magnetic resonance imaging in patients with autoimmune and idiopathic complete central diabetes insipidus. *J Clin Endocrinol Metab* 87:3825–3829
28. Maghnie M, Cosi G, Genovese E, Manca-Bitti ML, Cohen A, Zecca S, Tinelli C, Gallucci M, Bernasconi S, Boscherini B, Severi F, Arico M 2000 Central diabetes insipidus in children and young adults. *N Engl J Med* 343:998–1007
29. Schloot N, Eisenbarth GS 1995 Isohormonal therapy of endocrine autoimmunity. *Immunol Today* 16:289–294
30. De Bellis A, Bizzarro A, Rossi R, Paglionico VA, Criscuolo T, Lombardi G, Bellastella A 1993 Remission of subclinical adrenocortical failure in subjects with adrenal autoantibodies. *J Clin Endocrinol Metab* 76:1002–1007
31. De Bellis A A, Falorni A, Laureti S, Perrino S, Coronella C, Forini F, Bizzarro E, Bizzarro A, Abbate G, Bellastella A 2001 Time course of 21-hydroxylase antibodies and long-term remission of subclinical autoimmune adrenalitis after corticosteroid therapy: case report. *J Clin Endocrinol Metab* 86:675–678
32. Kajiyama H, Terai C, De Bellis A, Bizzarro A, Bellastella A, Ohta S, Okamoto H, Uesato M, Hara M, Kamatani N 2004 Vasopressin cell antibodies and central diabetes insipidus in a patient with systemic lupus erythematosus and dermatomyositis. *J Rheumatol* 31:1218–1221

**TABLE 1.** Characteristics of the 95 patients with autoimmune hypopituitarism positive for APA at high titer (1:64 –1:256)

---

Isolated pituitary hormone deficiency	TPC-APA	Combined pituitary hormone deficiencies	TPC-APA
---------------------------------------	---------	---	---------



APA-positive patients	Type	n	GH	LH/FSH	TSH	ACTH	Type	n	GH	LH/FSH	TSH	ACTH
Group 1 (n = 60)												
Sex (M/F = 14/46)	GH-D	19	19	0	0	0	GH-/ACTH-D	5	5	0	0	3
Mean age = 31.5 yr	LH/FSH-D	10	0	10	0	0	GH-/LH-FSH-D	4	4	2	0	0
Age range = 26–37 yr	ACTH-D	14	0	0	0	14	GH-/TSH-D	2	2	0	2	0
Other autoimmune diseases (n = 39)							LH-FSH-/ACTH-D	3	0	3	0	3
							LH-FSH/TSH-D	1	0	1	0	0
							ACTH-D/TSH-D	1	0	0	0	1
							TSH-LH-FSH-D	1	0	0	1	0
Group 2 (n = 35)												
Sex (M/F = 8/27)	GH-D	7	7	0	0	0	GH-/ACTH-D	5	5	0	0	3
Mean age = 32 yr	LH/FSH-D	5	0	5	0	0	GH-/LH-FSH-D	4	4	2	0	0
Age range = 25–38 yr	ACTH-D	6	0	0	0	6	LH-FSH-/ACTH-D	6	0	5	0	6
Other autoimmune diseases (n = 19)							LH-FSH-/TSH-D	2	0	2	1	0

Of the 95 patients, 60 were without histological/MRI findings of LYH (group1) and 35 with biopsy proven/MRI suspected lymphocytic hypophysitis (group 2). F, Female; M, male; TPC-APA, type of pituitary-secreting cells targeted by APA.


**TABLE 2.** Characteristics of the 20 patients with autoimmune hypopituitarism positive for AHA at high titers

AHA-positive patients	IPHD	CPHD	TPC-APA	Sex	Age (yr)	AHA titers	AVP- secreting cells	AHA to other hypothalamic-secreting cells	Posterior pituitary function
Group1 (n = 12)									
1	GH-D		GH	M	27	1:256	Present	Absent	Complete CDI <sup>a</sup>
2		GH-/ACTH-D	GH	F	29	1:128	Absent	Present (CRH cells)	Normal
3		GH-/FSH-LH-D	GH	M	31	1:64	Present	Present (unknown cells)	Partial CDI <sup>b</sup>
4	GH-D		GH	F	29	1:256	Present	Absent	Complete CDI <sup>a</sup>
5		ACTH-/TSH-D	ACTH	F	33	1:64	Present	Present (unknown cells)	Partial CDI <sup>b</sup>
6		GH-/FSH-LH-D	GH/FSH-LH	F	31	1:64	Present	Absent	Complete CDI <sup>a</sup>
7		GH-/ACTH-D	GH	M	37	1:256	Absent	Present (CRH cells)	Normal
8		GH-/FSH-LH-D	GH/FSH-LH	F	30	1:128	Present	Absent	Complete CDI <sup>a</sup>
9		GH-/FSH-LH-D	GH	F	34	1:64	Present	Present (unknown cells)	Partial CDI <sup>b</sup>
10		FSH-LH-/TSH-D	FSH-LH	F	28	1:64	Present	Present (unknown cells)	Partial CDI <sup>b</sup>
11		FSH-LH-/TSH-D	TSH	F	30	1:256	Absent	Present (unknown cells)	Normal
12	GH-D		GH	F	28	1:128	Present	Absent	Complete CDI <sup>a</sup>
Group 2 (n = 8)									
1		GH-/FSH-LH-D	GH/FSH-LH	F	30	1:256	Present	Absent	Complete CDI <sup>a</sup>
2		FSH-LH-/ACTHD	ACTH	M	29	1:128	Absent	Present (unknown cells)	Normal
3		GH-/FSH-LH-D	GH/FSH-LH	F	28	1:128	Present	Present (unknown cells)	Complete CDI <sup>a</sup>
4		FSH-LH-/TSH-D	FSH-LH/TSH	M	32	1:128	Present	Present (unknown cells)	Complete CDI <sup>a</sup>
5		GH-/ACTH-D	GH	F	32	1:64	Absent	Present (CRH cells)	Normal
6		FSH-LH-/TSH-D	FSH-LH	F	33	1:64	Absent	Present (unknown cells)	Normal
7		GH-/FSH-LH-D	GH/FSH-LH	F	31	1:256	Present	Absent	Complete CDI <sup>a</sup>
8		GH-/ACTH-D	GH	F	28	1:64	Absent	Present (CRH cells)	Normal

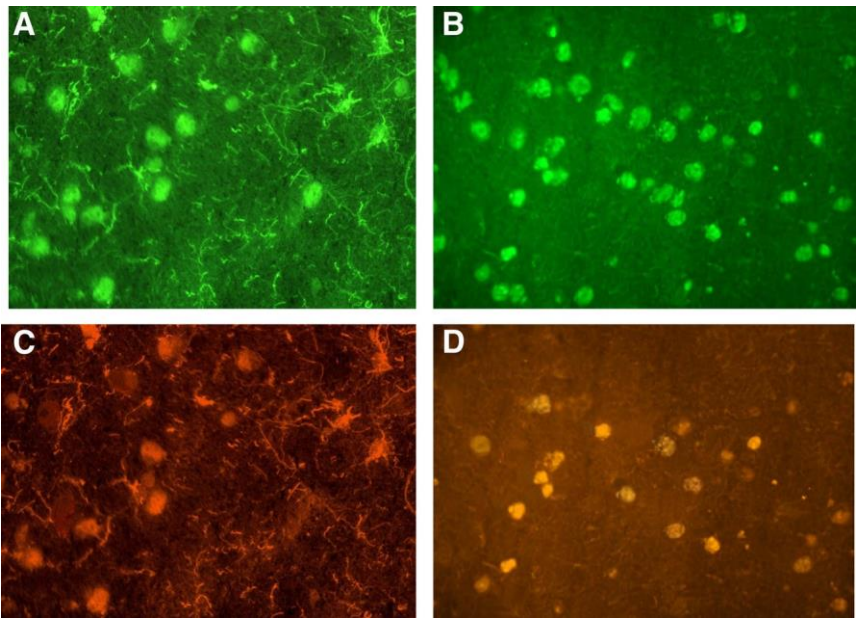
Of the 20 patients, 12 were without histological/MRI findings of LYH (group 1) and eight with biopsy-proven/MRI-suspected lymphocytic hypophysitis (group 2). CPHD, Combined pituitary hormone deficiencies; F, female; IPHD, isolated pituitary hormone deficiency; M, male; TPC-APA, type of pituitary cells targeted by APA.

<sup>a</sup> As diagnosed on the basis of basal urinary osmolarity ranging from 215–240 mOsm/kg and plasma osmolarity from 293–298 mOsm/kg and urine osmolarity after dehydration from 130–160 mOsm/kg and after ADH administration from 640–760 mOsm/kg.

<sup>b</sup> As diagnosed on the basis of basal urinary osmolarity ranging from 357–380 mOsm/kg and plasma osmolarity from 283–286 mOsm/kg and urine osmolarity after dehydration from 315–330 mOsm/kg and after ADH administration from 490–505 mOsm/kg.



**FIG. 1.** Detection of AHA in 95 patients with autoimmune hypopituitarism, 60 without histological/MRI findings of LYH (group 1) and 35 with proven/suspected LYH (group 2) positive for APA at high titer (1:64 –1:256), in 20 patients with hypopituitarism after hypophysectomy (f), and in 50 healthy subjects (D).



**FIG. 2.** Immunofluorescence pattern in cryostat sections of young baboon hypothalamus tested against serum of one patient with CDI (A and C) and serum of one patient with ACTH- D (B and D) showing evidence of AHA immunostaining in the patient with CDI selectively of magnocellular hypothalamic cells (type 1 pattern, A), identified as AVP-secreting cells by four- layer immunofluorescence (C), and in the patient with ACTH-D selectively of small hypothalamic cells (type 2 pattern, B), identified as CRH-secreting cells by four-layer immunofluorescence (D).