



UNIVERSITÀ DEGLI STUDI DI TORINO

This is an author version of the contribution published on:

Questa è la versione dell'autore dell'opera:

[Pacing Clin Electrophysiol. 2013 Dec;36(12):1460-7. doi: 10.1111/pace.12183.

Epub 2013 May 28.]

The definitive version is available at:

La versione definitiva è disponibile alla URL:

[<http://onlinelibrary.wiley.com/doi/10.1111/pace.12183/abstract>]

Single center experience of fluoroless AVNRT ablation guided by electroanatomic reconstruction in children and adolescents

Fluoroless AVNRT cryoablation in children

Scaglione Marco*, MD, Ebrille Elisa†, MD, Caponi Domenico*, MD, Blandino Alessandro†, MD, Di Donna Paolo*, MD, Siboldi Alessandra‡, MD, Bertero Giovanni‡, MD, Anselmino Matteo†, MD, Raimondo Cristina†, MD, Sardi Davide†, MD, Gabbarini Fulvio§, MD, Marasini Maurizio‡, MD, and Gaita Fiorenzo†, MD.

* Cardiology Department, Cardinal Massaia Hospital, Asti, Italy

† Cardiology Department, School of Medicine, University of Turin, San Giovanni Battista Hospital, Turin, Italy

‡ Pediatric Cardiology Department, G. Gaslini Institute, Genova, Italy

§ Cardiology Department, OIRM Pediatric Hospital, Turin, Italy

Conflicts of interest: none

Financial support: none

Corresponding author:

Marco Scaglione, MD

Cardiology Department, Cardinal G. Massaia Hospital

Corso Dante 202, 14100 Asti, Italy

Phone: +39-0141-487121 - Fax: +39-0141-487133

Email: marco.scaglione@tin.it

Author contributions:

Scaglione Marco: concept, design, ablation procedures

Ebrille Elisa: drafting article, data collection

Caponi Domenico: drafting article, ablation procedures

Blandino Alessandro: data collection, clinical follow-up

Di Donna Paolo: data collection, ablation procedures

Siboldi Alessandra: clinical follow-up, ablation procedures

Bertero Giovanni: data interpretation, ablation procedures

Anselmino Matteo: data interpretation

Raimondo Cristina: data collection, clinical follow-up

Sardi Davide: data collection, clinical follow-up

Gabbarini Fulvio: clinical follow-up

Marasini Maurizio: approval of article

Gaita Fiorenzo: approval of article

Abstract

Background. Anatomical considerations and risks related to x-ray exposure make atrio-ventricular nodal reentrant tachycardia (AVNRT) ablation in pediatric patients a concerning procedure. We aimed to evaluate the feasibility, safety and efficacy of performing fluoroless slow pathway cryoablation guided by the electroanatomic (EA) mapping in children and adolescents.

Methods. Twenty one consecutive patients (mean age 13.5 ± 2.4 years) symptomatic for AVNRT were prospectively enrolled to right atrium EA mapping and electrophysiological study prior to cryoablation. Cryoablation was guided by slow-pathway potential and performed using a 4-mm tip catheter.

Results. Sustained slow-fast AVNRT was inducible in all the patients with a dual AV nodal physiology in 95%. Acute success was achieved in 100% of the patients with a median of 2 cryo-applications. Fluoroless ablation was feasible in 19 patients, while in 2 subjects 50 and 45 seconds of x-ray were needed due to difficult progression of the catheters along the venous system. After a mean follow-up of 25 months AVNRT recurred in 5 patients. All the recurrences were successfully treated with a second procedure. In 3 patients a fluoroless cryoablation with a 6-mm tip catheter was successfully performed, while in the remaining 2 patients a single pulse of 60 s of radiofrequency energy was applied under fluoroscopic monitoring. No complications occurred.

Conclusions. Combination of EA mapping systems and cryoablation may allow to perform fluoroless slow-pathway ablation for AVNRT in children and adolescents in the majority of patients. Fluoroless slow-pathway cryoablation showed a high efficacy and safety comparable to conventional fluoroscopy guided procedures.

Keywords: AVNRT; pediatric population; fluoroscopy; cryoablation; electroanatomic mapping.

Introduction

Atrio-ventricular nodal reentrant tachycardia (AVNRT) is a common supraventricular arrhythmia in adults and children¹⁻². Catheter ablation in adulthood is a well-established treatment with a high success rate and a very low incidence of complications, the most dreadful to be the atrio-ventricular (AV) block (0.26%)²⁻⁴. This latter aspect has greater relevance especially in the pediatric population. In this subset of patients anatomic considerations such as a small triangle of Koch with the possible higher risk of AV node damage should be taken into account in AVNRT ablation⁵. Furthermore, the use of fluoroscopy exposes children to the potential harmful effects of radiations⁶⁻⁷. In fact, although AVNRT ablation is usually considered a low x-ray exposure procedure, literature reports fluoroscopy time ranging from 16 to 27 minutes⁸⁻⁹. For these reasons, many operators prefer to avoid or postpone ablation procedures to the end of childhood.

Recently, it has been shown that non fluoroscopic electroanatomic (EA) mapping systems allows to reduce X-ray exposure for ablation procedures in children¹⁰⁻¹⁴. In addition, in few reports the feasibility of fluoroless procedures in children and adolescents has been demonstrated¹⁴⁻¹⁷, with a similar success and complication rate compared to conventional standard ablation procedures.

Based on the above considerations, we decided to evaluate the feasibility, safety and effectiveness of performing fluoroless slow pathway cryoablation guided by EA mapping in children and adolescents at our institution.

Methods

Study group

Twenty-one consecutive pediatric patients suffering from AVNRT were prospectively enrolled for the study. Every patient was highly symptomatic for palpitations. Before the

procedure a cardiac work up was carried out to evaluate the presence of an underlying structural heart disease. After written informed consent was obtained, all the patients underwent a diagnostic electrophysiological study under conscious sedation or narcosis.

Electrophysiological Study

Before ablation, every patient underwent a standard electrophysiological (EP) study.

Two tetrapolar catheters and a decapolar steerable catheter were placed in His bundle region, right ventricular apex and coronary sinus respectively through a venous femoral approach.

In accordance with operator desire CARTO3 or NavX EA system, providing multiple catheters' visualization, were used to navigate the venous system and to perform a right atrium EA map in order to place all the catheters inside the heart minimizing the use of fluoroscopy.

Ventricular and atrial stimulation protocols were used to assess conduction properties and arrhythmia inducibility. After the EP study was completed, slow pathway cryoablation was performed if AVNRT was inducible.

Cardiac imaging integration

NavX: the EnSite Velocity (St. Jude Medical, St. Paul, MN, USA) is a 3D cardiac mapping system that provides visualization and navigation of conventional electrophysiological catheters. This is a methodology based on the principle of applying an electrical current across 6 surface electrodes, evaluating the interaction of catheters with the electrical field. Thus, the system reproduces and shows catheters' position reflecting their real-time motion and enables the creation of a 3D model of the cardiac chamber of interest. Using this system the cryoablation catheter may be connected and visualized also during the cryo-application.

CARTO3: the new CARTO3 system (Biosense Webster, Diamond Bar, CA, USA) allows real time 3D reconstruction of the cardiac chambers and visualization of all of the catheters as in a standard fluoroscopic view. Once the EA mapping of the chamber considered is completed

using a Navistar (Biosense Webster, Diamond Bar, CA, USA) ablation catheter, all the other diagnostic catheters that enter this chamber could be visualized including the cryoablation catheter. In our population, the reconstruction of the right atrium (RA) was obtained by the FAM algorithm. This method continuously (non gated) records movements of the Navistar catheter. Based on this volume sampling, a surface reconstruction was built in accordance with the set resolution level. The geometric reconstruction of the RA started positioning the Navistar catheter on the superior vena cava. The mapping catheter was then withdrawn from the superior vena cava through the RA down to the inferior vena cava, touching the endocardial surface of the lateral, septal, anterior and posterior walls and tagging specific anatomic landmarks such as the His bundle, the tricuspid ring and the coronary sinus os. The navigation inside the chamber was guided by the integration of the direct visualization of the mapping catheter provided by the CARTO3 system and the analysis of the electrograms recorded from the tip of the roving catheter.

With CARTO3, cryoenergy delivery interferes with the system and requires disconnection of the catheter before cryoenergy is turned on. Therefore, once the correct site is identified, it is necessary to disconnect the cryocatheter from the system, making the tip of the catheter not visualized. Few seconds are necessary to allow the adherence of the cryocatheter to the heart tissue. The lack of the visualization during these few seconds is counterbalanced by the fact that the effect created by the cryo-mapping is transient and reversible; then the repositioning of the catheter can be performed without any permanent unwanted consequences. Moreover, the lack of the visualization during the cryoenergy delivery does not affect the overall safety of the procedure because, after the first few seconds, the cryocatheter tip is adherent to the endocardial surface.

Ablation Protocol

In our institution, slow pathway ablation in children is routinely performed using cryoenergy with a 4 mm-tip catheter in order to be more selective in the ablation lesion. Cryoablation with a 6 mm-tip catheter is performed in case of recurrences. If cryoablation fails, RF energy is used.

The choice of the ablation site is guided by an electrophysiological and anatomic approach. Briefly, a 3D RA EA map is used to tag points of interest such as His bundle and slow pathway potential recording sites (Figure 1) to reproduce a detailed electroanatomy of the triangle of Koch. The target of ablation is the slow pathway potential recording¹⁸⁻¹⁹ as first choice. In case of inability to detect the abovementioned potential or ineffectiveness of previous ablation attempts, an anatomical approach is used²⁰. Once the site is identified, cryo-mapping is performed by cooling the tissue at a temperature of -30°C for a maximum of 60 seconds. Since during cryoablation of slow pathway no junctional rhythm is generally observed, programmed stimulation is performed evaluating parameters such as the disappearance of dual AV nodal physiology, the modification of the slow pathway conduction with non-inducibility of the AVNRT or the interruption of the AVNRT itself. If one or more of these criteria are present without modification of the basal AV conduction, cryoablation is carried out lowering the temperature as far as -80°C for 8 min.

In case of RF energy delivery, that implies a higher risk of AV block, the ablation catheter movements are monitored using fluoroscopy to immediately detect any catheter dislodgements.

Results

Study population

Study population included 21 pediatric patients, 9 males and 12 females, with mean age of 13.5 ± 2.4 years (range 7-16 years). All the patients had a normal heart but 2 patients: one

patient was affected by Shprintzen-Goldberg syndrome and the other one had left ventricular noncompaction. Mean cycle length during tachycardia was 300 ± 35 ms (range 422 – 250 ms). Every patient was refractory to at least one antiarrhythmic drug. The median elapsed time from symptoms to ablation was 3.4 years (range 1-10 years) (Table 1).

Procedural parameters and acute success

At baseline, in all the patients a sustained slow-fast AVNRT was inducible; a dual AV nodal physiology was present in 20/21 (95%) patients. In 13 patients RA reconstruction was performed with the CARTO3 EA mapping system, whereas 8 cases were performed with the NavX. Cryo-application was guided by slow pathway potential recording in 18 patients (13 postero-septal and 5 mid-septal sites). In the remaining 3 patients an anatomical approach was used due to the impossibility to detect the slow pathway potential. Acute success was achieved in all the 21 patients with a median of 2 cryo-applications. After the ablation only 5/21 still showed an AV nodal jump. In one patient a transient lengthening of the AH interval after 1 minute of cryoablation at -80°C was observed, but normal AV conduction immediately recovered after the interruption of cryoenergy delivery. No transient or permanent AV block as well as any other complications were observed in the acute setting. Fluoroless procedure was possible in 19 out of 21 patients, while the remaining 2 patients required 50 and 45 seconds of fluoroscopy respectively due to a difficult progression of the catheters along the venous system. Mean procedural time was 70 ± 20 minutes (range 55-120 minutes). Mean RA reconstruction time was 8 ± 3 minutes. Table 2 and 3 summarize procedural parameters in details.

Long-term follow-up results

No patient was lost at follow-up. At a mean follow-up of 25 months (range 6-86 months) AVNRT recurred in 5 patients. The mean elapsed time to recurrence was 61 days (range 1-149 days). All these 5 patients were successfully treated with a second procedure, 3 using a 6-

mm tip cryoablation catheter while 2 patients required RF energy to eliminate the slow pathway conduction because of a 6-mm tip cryoablation failure (Table 3). All the second cryoablation procedures were performed without fluoroscopy, while in the 2 patients who required RF delivery 60 seconds of X-ray were applied for each pulse in order to immediately detect any catheter dislodgement.

No complications such as AV conduction disturbances occurred in the long-term follow-up in all the patients. No other recurrences were observed during the follow-up.

Discussion

This study reports the results of fluoroless slow-pathway cryoablation combined with the use of EA mapping systems in children and adolescents. The main results are as follows:

- The use of EA mapping systems, by multiple catheters visualization, allowed no X-ray exposure in 22/24 (92%) cryoablation procedures, with a negligible fluoroscopic exposure (45 and 50 s) in 2 patients.
- Fluoroless slow pathway cryoablation showed a high acute success rate (100%). In a small percentage of patients a second successful fluoroless cryoablation was necessary, reaching an overall efficacy of 92% (24/26 fluoroless procedures). In 2 patients RF energy was used requiring fluoroscopy.
- The fluoroless cryoablation of AVNRT in children and adolescents appeared to be safe since no acute or late complications occurred.

Interventional procedures expose patients to a significant amount of radiation, with a not negligible risk of harmful effects and malignancies²¹. Children are inherently more susceptible to the risk of radiation induced carcinogenesis and therefore these concerns are even more relevant to the pediatric electrophysiologists⁶. In addition extensive fluoroscopy exposure causes significant health related problems also on medical staff²²⁻²³. In fact current

guidelines recommend all the physicians to minimize radiation injury hazard to patients, professional staff, and themselves²⁴⁻²⁵. Catheter ablation is an effective therapy for multiple arrhythmia substrates in children. Generally, this approach relies on the use of fluoroscopy. Although AVNRT ablation is usually considered a low X-ray exposure procedure, literature reports fluoroscopy time ranging from 16 to 27 minutes⁸⁻⁹.

Several studies have demonstrated the feasibility of fluoroscopy reduction using non fluoroscopic mapping systems during ablation of supraventricular tachycardia¹⁰⁻¹⁴. Very few authors have focused on the complete elimination of fluoroscopy. To our knowledge, 4 studies reported zero-fluoroscopy AVNRT ablation in children in the great majority of cases¹⁴⁻¹⁷.

Our goal was to eliminate fluoroscopy in the slow pathway ablation procedure with the aid of EA mapping systems and the use of cryoenergy to obtain a high safety procedural profile. In our pediatric population fluoroless cryoablation was feasible in the 92% of the procedures. Minimal fluoroscopy time was used in 2 patients only to manage difficult progression of the catheters along the venous system and in 2 cases to monitor RF delivery.

In our patient population either NavX or CARTO3 were used as electroanatomic mapping systems. In the literature, the non fluoroscopic EA mapping system most widely used is the NavX since it allows the real time visualization of all the catheters including the cryocatheter. No reports were found about the use of the CARTO3 system combined with cryoenergy since cryoenergy delivering interferes with the system. It is important to note that, in our experience, cryoablation with CARTO3 was feasible. This result was possible disconnecting the ablation catheter during the cryo-application. Few seconds are necessary to allow the adherence of the cryocatheter to the heart tissue. The lack of the visualization during these few seconds may be counterbalanced by the fact that the effect created by the cryo-mapping is transient and reversible. Then, the repositioning of the catheter can be performed without any

permanent unwanted consequences in case of ineffective positioning. After few seconds, the tip of the catheter is stuck to the endocardial surface and its adherence to the tissue allows to carry out the ablation procedure without the need of real time catheter visualization. On the other side, the CARTO3 system has the disadvantage of requiring a dedicated catheter for mapping and another catheter for cryoablation, making the procedure more expensive. After this preliminary experience, in our laboratory, the protocol of AVNRT ablation in children employing the CARTO3 system has been changed. In order to reduce the procedural costs, a Navistar catheter to perform the mapping and to pace from the atrium or from the ventricle is used once the right atrium mapping is completed. In such a way, the use of a diagnostic ventricular or atrial catheter can be avoided, reducing the cost of the procedure. Nevertheless, in our experience, the use of NavX or CARTO 3 system showed comparable clinical results. Literature reports acute success of AVNRT cryoablation in children ranging from 75% to 100% with a recurrence rate up to 27%^{8,26-31}. In our population acute success rate was 100% without complications. A precise 3D EA reconstruction of the RA may explain this high success rate. In fact, the detailed location of Koch's triangle combined with the use of slow pathway potential as a target allowed us to tailor the ablation upon specific patient's anatomy. In addition, we deem that the use of cryoenergy is justified by the lower incidence of AV block compared to AVNRT RF ablation in pediatric population^{4-5,32-34}, even if a higher recurrence rate is reported. It can be speculated that the detailed 3D EA reconstruction of Koch's triangle combined with the use of cryoenergy may account for the absence of any acute and long-term complications in our study population. The overall long-term success rate using fluoroles cryoablation was 92% (24/26 procedures), similar to the success rate for RF ablation³³⁻³⁶. However, this result has been achieved performing a second fluoroles cryoablation procedure in 3 patients.

Our recurrence rate with the use of cryoenergy may relate to the use of the 4 mm-tip cryocatheter. Our choice was determined by idea to be as safe as possible in order to avoid large lesions in pediatric patients. The results from the literature are conflicting about the use of 4 mm versus 6 mm-tip catheter. In fact, a recent paper by Reents et al³⁷ reports that the use of 4 mm versus 6 mm-tip catheter is not predictive for recurrences. On the other side, Rivard et al³⁸ reports a 2.5 fold increased risk of recurrences with the use of the 4 mm-tip cryocatheter. Chanani et al³⁹ observe a lower recurrence rate with the use of the 6 mm-tip catheter without reaching a statistical significance. Based on the results seen in our study, probably we may use a 6 mm-tip cryocatheter as a first choice in this cohort of patients.

In conclusion the present paper confirms that EA mapping guided cryoablation of AVNRT in children and adolescents may be performed without fluoroscopy in the great majority of patients. Fluoroless slow-pathway cryoablation showed a high efficacy and safety comparable to conventional fluoroscopy guided procedures. The consequent reduction or elimination of exposure to ionizing radiation is likely to be highly valued, especially in children.

Table 1. Study population.

PT	AGE	SEX	WEIGHT (Kg)	STRUCTURAL HEART DISEASE	AVNRT CYCLE LENGTH (msec)	ANTIARRHYTHMIC DRUGS
1	14	M	45	Shprintzen-Goldberg Syndrome	250	b-blocker, flecainide
2	13	F	43		422	Ca2+antagonist
3	13	F	46		272	b-blocker, flecainide
4	15	M	50		300	b-blocker
5	16	M	52	Left ventricular noncompaction	300	b-blocker, amiodarone, Ca2+antagonist, propafenone, flecainide
6	14	F	46		300	b-blocker
7	14	M	75		333	Ca2+antagonist
8	14	F	48		285	b-blocker
9	12	M	40		292	b-blocker
10	16	F	55		315	b-blocker
11	15	F	49		300	propafenone
12	16	F	61		260	flecainide
13	16	F	56		292	Ca2+antagonist
14	13	F	65		300	Ca2+antagonist
15	15	F	53		317	b-blocker
16	10	F	35		300	Ca2+antagonist, propafenone, digoxin
17	15	M	53		300	b-blocker
18	12	M	72		272	b-blocker
19	13	M	42		300	b-blocker
20	7	F	32		300	b-blocker
21	13	M	45		260	Ca2+antagonist

Table 2. Procedural parameters.

PT	PROCEDURAL TIME (min)	ELECTROANATOMIC MAPPING SYSTEM	DUAL AV NODAL PHYSIOLOGY BEFORE ABLATION	TARGET	N°/TIME OF APPLICATIONS	DUAL AV NODAL PHYSIOLOGY AFTER ABLATION	FLUOROSCOPY TIME (sec)
1	60	CARTO3	Yes	A (Post-s.)	1/8 min	No	0
2	45	CARTO3	Yes	S (Post-s.)	1/8 min	Yes	0
3	45	NavX	Yes	S (Post-s.)	2/16 min	Yes	0
4	65	CARTO3	No	S (Mid-s.)	2/16 min	No	0
5	60	NavX	Yes	A (Mid-s.)	3/24 min	No	45
6	75	NavX	Yes	S (Post-s.)	2/16 min	No	0
7	75	NavX	Yes	S (Mid-s.)	3/24 min	Yes	0
8	90	CARTO3	Yes	S (Post-s.)	2/16 min	No	0
9	110	CARTO3	Yes	S (Post-s.)	2/16 min	No	0
10	60	CARTO3	Yes	A (Mid-s.)	2/16 min	No	50
11	75	NavX	Yes	S (Post-s.)	1/8 min	No	0
12	60	CARTO3	Yes	S (Post-s.)	2/16 min	No	0
13	65	CARTO3	Yes	S (Post-s.)	1/8 min	No	0
14	55	NavX	Yes	S (Mid-s.)	2/16 min	Yes	0
15	90	CARTO3	Yes	S (Mid-s.)	1/8 min	No	0
16	120	CARTO3	Yes	S (Post-s.)	3/24 min	No	0
17	60	NavX	Yes	S (Post-s.)	2/16 min	No	0
18	60	NavX	Yes	S (Post-s.)	1/8 min	No	0
19	60	CARTO3	Yes	S (Post-s.)	2/8 min	No	0
20	70	CARTO3	Yes	S (Post-s.)	2/8 min	No	0
21	60	CARTO3	Yes	S (Mid-s.)	4/32 min	Yes	0

A=Anatomical; S=Slow potential; Post-s.=Postero-septal; Mid-s.=Mid-septal

Table 3. Redo procedures.

PT	PROCEDURAL TIME (min)	DUAL AV NODAL PHYSIOLOGY BEFORE ABLATION	TARGET	N°/TIME OF APPLICATIONS	DUAL AV NODAL PHYSIOLOGY AFTER ABLATION	FLUOROSCOPY TIME (sec)
1	90	Yes	A (Post-s.)	3/24 min	Yes	0
3	110	Yes	S (Post-s.)	2/16 min	No	0
5	140	Yes	A (Mid-s.)	RF	No	60
7	105	No	S (Mid-s.)	3/24 min	No	0
13	75	Yes	S (Post-s.)	RF	No	60

A=Anatomical; S=Slow potential; Post-s.=Postero-septal; Mid-s.=Mid-septal;
RF=radiofrequency.

Figure 1. 3-D reconstruction of the right atrium using CARTO3 and NavX mapping systems.

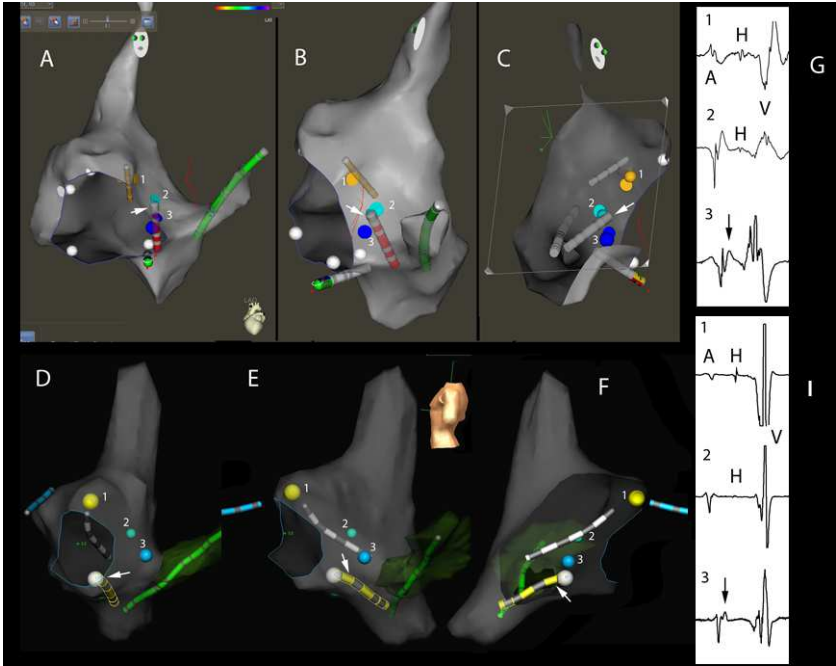


Figure legend:

Panels A, B and C: CARTO3 right atrium reconstruction.

Panels D, E and F: NavX right atrium reconstruction.

Panels A and D: Left Anterior Oblique view; Panels B and E: Left Lateral view; Panels C and F: Right Lateral view with a cutting plane allowing the visualization of the interatrial septum and the triangle of Koch.

In every Panel (A, B, C, D, E, F) it is shown a tetrapolar catheter in the His bundle region and in the right ventricle, a multipolar catheter in the coronary sinus and the cryoablation catheter (indicated by a white arrow) in the triangle of Koch.

Tag points of interest in the triangle of Koch. 1: His bundle recording in the anteroseptal area of the tricuspid annulus; 2: site with the smallest His bundle potential recording; 3: slow pathway potential recording.

Panels G and I: endocavitary recordings from the tag points of interest in the triangle of Koch. (A: atrial electrogram; V: ventricular electrogram; H: His bundle potential; black arrow indicates slow pathway potential).

References

1. Ko JK, Deal BJ, Strasburger JF, Benson DW. Supraventricular tachycardia mechanisms and their age distribution in pediatric patients. *Am J Cardiol* 1992; 69:1028-1032.
2. Blomstrom-Lundvist C, Sheinman MM, Aliot EM, Alpert JS, Calkins H, Camm AJ, Campbell WB, et al; European Society of Cardiology Committee, NASPE-Heart Rhythm Society. ACC/AHA/ESC guidelines for the management of patients with supraventricular arrhythmias--executive summary: a report of the American college of cardiology/American heart association task force on practice guidelines and the European society of cardiology committee for practice guidelines. *J Am Coll Cardiol* 2003; 42:1493-1531.
3. Calkins H, Yong P, Miller JM, Olshansky B, Carlson M, Saul JP, Huang SK, et al. Catheter ablation of accessory pathways, atrioventricular nodal reentrant tachycardia, and the atrioventricular junction: final results of a prospective, multicenter clinical trial. *Circulation* 1999; 99:262-270.
4. Gaita F, Riccardi R, Calo L. Importance and implications of the occurrence of AV block following radiofrequency ablation. *Heart* 1998; 79:534-535.
5. Schaffer MS, SilkaMJ, Ross BA, Kugler JD. Inadvertent atrioventricular block during radiofrequency catheter ablation. Results of the Pediatric Radiofrequency Ablation Registry. Pediatric Electrophysiology Society. *Circulation* 1996; 94:3214-3220.
6. Ait-Ali L, Andreassi MG, Foffa I, Spadoni I, Vano E, Picano E. Cumulative patient effective dose and acute radiation-induced chromosomal DNA damage in children with congenital heart disease. *Heart* 2010; 96:269-274.
7. Justino H: The ALARA concept in pediatric cardiac catheterization: techniques and tactics for managing radiation dose. *Pediatr Radiol* 2006; 36:146-153.

8. Van Hare GF, Javitz H, Carmelli D, Saul JP, Tanel RE, Fischbach PS, Kanter RJ, et al. Prospective assessment after pediatric cardiac ablation: demographics, medical profiles, and initial outcomes. *J Cardiovasc Electrophysiol* 2004; 15:759-770.
9. Efstathopoulos EP, Katritsis DG, Kottou S, Kalivas N, Tzanalaridou E, Giazitzoglou E, Korovesis S, et al. Patient and staff radiation dosimetry during cardiac electrophysiology studies and catheter ablation procedures: a comprehensive analysis. *Europace* 2006; 8:443-448.
10. Drago F, Silvetti MS, Di Pino A, Grutter G, Bevilacqua M, Leibovich S. Exclusion of fluoroscopy during ablation treatment of right accessory pathway in children. *J Cardiovasc Electrophysiol* 2002; 13:778-782.
11. Papagiannis J, Tsoutsinos A, Kirvassilis G, Sofianidou I, Koussi T, Laskari C, Kiaffas M, et al. Nonfluoroscopic catheter navigation for radiofrequency catheter ablation of supraventricular tachycardia in children. *Pacing Clin Electrophysiol* 2006; 29:971-978.
12. Miyake CY, Mah DY, Atallah J, Oikle HP, Melgar ML, Alexander ME, Berul CI, et al. Nonfluoroscopic imaging systems reduce radiation exposure in children undergoing ablation of supraventricular tachycardia. *Heart Rhythm* 2011; 8:519-525.
13. Kwong W, Neilson AL, Chiu CC, Gross GJ, Hamilton RM, Soucie L, Stephenson EA, et al. The effect on NavX on fluoroscopy times in pediatric catheter ablation. *J Interv Card Electrophysiol* 2012; 33:123-126.
14. Wan G, Shannon KM, Moore JP. Factors associated with fluoroscopy exposure during pediatric catheter ablation utilizing electroanatomical mapping. *J Interv Card Electrophysiol*. 2012; 35:235-242.

15. Smith G, Clark JM. Elimination of fluoroscopy use in a pediatric electrophysiology laboratory utilizing three-dimensional mapping. *Pacing Clin Electrophysiol* 2007; 30:510-518.
16. Tuzcu V. Significant reduction of fluoroscopy in pediatric catheter ablation procedures: long-term experience from a single center. *Pacing Clin Electrophysiol* 2012; 35:1067-1073.
17. Gist K, Tigges D, Smith G, Clark J. Learning curve for zero-fluoroscopy catheter ablation of AVNRT: early versus late experience. *Pacing Clin Electrophysiol* 2011; 34:264-268.
18. Haissaguerre M, Gaita F, Fisher B, Commenges D, Montserrat P, D'Ivernois C, Lemetayer P, et al. Elimination of atrioventricular nodal reentrant tachycardia using discrete slow potentials to guide application of radiofrequency energy. *Circulation* 1992; 85:2162-2175.
19. Jackman WM, Beckman KJ, McClelland JH, Wang X, Friday KJ, Roman CA, Moulton KP, et al. Treatment of supraventricular tachycardia due to atrioventricular nodal reentry, by radiofrequency catheter ablation of slow-pathway conduction. *N Engl J Med* 1992; 327:313-318.
20. Jazayeri MR, Hemple SL, Sra JS, Dhala AA, Blanck Z, Deshpande SS, Avitall B, et al. Selective transcatheter ablation of the fast and slow pathways using radiofrequency energy in patients with atrioventricular nodal reentrant tachycardia. *Circulation* 1992; 85:1318-1328.
21. Bedetti G, Botto N, Andreassi MG, Traino C, Vano E, Picano E. Cumulative patient effective dose in cardiology. *Br J Radiol* 2008; 81:699-705.
22. Bashore TM, Bates ER, Berger PB, Clark DA, Cusma JT, Dehmer GJ, Kern MJ, et al. Task Force on Clinical Expert Consensus Documents. American College of

- Cardiology/Society for Cardiac Angiography and Interventions Clinical Expert Consensus Document on cardiac catheterization laboratory standards. A report of the American College of Cardiology Task Force on Clinical Expert Consensus Documents. *J Am Coll Cardiol* 2011; 37:2170-2214.
23. Venneri L, Rossi F, Botto N, Andreassi MG, Salcone N, Emad A, Lazzeri M, et al. Cancer risk from professional exposure in staff working in cardiac catheterization laboratory: insights from the National Research Council's Biological Effects of Ionizing Radiation VII Report. *Am Heart J* 2009; 157:118-124.
24. Strauss KJ, Kaste S. ALARA in pediatric interventional and fluoroscopic imaging: striving to keep radiation doses as low as possible during fluoroscopy of pediatric patients – a white paper executive summary. *J Am Coll Radiol* 2006; 3:686-688.
25. Gerber TC, Carr JJ, Arai AE, Dixon RL, Ferrari VA, Gomes AS, Heller GV, et al. Ionizing radiation in cardiac imaging: a science advisory from the American Heart Association Committee on Cardiac Imaging of the Council on Clinical Cardiology and Committee on Cardiovascular Imaging and Intervention of the Council on Cardiovascular Radiology and Intervention. *Circulation* 2009; 119:1056-1065.
26. Kriebel T, Broistedt C, Kroll M, Sigler M, Paul T. Efficacy and safety of cryoenergy in the ablation of atrioventricular reentrant tachycardia substrates in children and adolescents. *J Cardiovasc Electrophysiol* 2005; 16:960-966.
27. Kirsh JA, Gross GJ, O'Connor S, Hamilton RM. Cryocath International Patient Registry. Transcatheter cryoablation of tachyarrhythmias in children: initial experience from an international registry. *J Am Coll Cardiol* 2005; 45:133-136.
28. Drago F, Russo MS, Silvetti MS, De Santis A, Iodice F, Naso Onofrio MT. Cryoablation of typical atrioventricular nodal reentrant tachycardia in children: six

- years' experience and follow-up in a single center. *Pacing Clin Electrophysiol* 2010; 33:475-481.
29. LaPage MJ, Saul JP, Reed JH. Long-term outcomes for cryoablation of pediatric patients with atrioventricular nodal reentrant tachycardia. *Am J Cardiol* 2010; 105:1118-1121.
30. Reents T, Springer B, Ammar S, Wu J, Fichtner S, Jilek C, Kolb C, et al. Long-term follow-up after cryoablation for adolescent atrioventricular nodal reentrant tachycardia: recurrence is not predictable. *Europace* 2012; 14:1629-1633.
31. Das S, Law IH, Von Bergen NH, Bradley DJ, Dick M 2nd, Etheridge SP, Saarel EV, et al. Cryoablation therapy for atrioventricular nodal reentrant tachycardia in children: a multicenter experience of efficacy. *Pediatr Cardiol* 2012; 33:1147-1153.
32. Kimman GP, Theuns DA, Szili-Torok T, Scholten MF, Res JC, Jordaens LJ. CRAVT: a prospective, randomized study comparing transvenous cryothermal and radiofrequency ablation in atrioventricular nodal re-entrant tachycardia. *Eur Heart J* 2004; 25:2232-2237.
33. Zrenner B, Dong J, Schreieck J, Deisenhofer I, Estner H, Luani B, Karch M, et al. Transvenous cryoablation versus radiofrequency ablation of the slow pathway for the treatment of atrioventricular nodal re-entrant tachycardia: a prospective randomized pilot study. *Eur Heart J* 2004; 25:2226-2231.
34. Skanes AC, Klein G, Krahn A, Yee R. Cryoablation: potentials and pitfalls. *J Cardiovasc Electrophysiol* 2004; 15:S28-34.
35. Schwagten B, Knops P, Janse P, Kimman G, Van Belle Y, Szili-Torok T, Jordaens L. Long-term follow-up after catheter ablation for atrioventricular nodal reentrant tachycardia: a comparison of cryothermal and radiofrequency energy in a large series of patients. *J Interv Card Electrophysiol* 2011; 30:55-61.

36. Buddhe S, Singh H, Du W, Karpawich PP. Radiofrequency and cryoablation therapies for supraventricular arrhythmias in the young: five-year review of efficacies. *Pacing Clin Electrophysiol* 2012; 35:711-717.
37. Reents T, Springer B, Ammar S, Wu J, Fichtner S, Jilej C, Kolb C, et al. Long-term follow-up after cryoablation for adolescent atrioventricular nodal reentrant tachycardia: recurrence is not predictable. *Europace* 2012; 14:1629-1633.
38. Rivard L, Dubuc M, Guerra PG, Novak P, Roy D, Macle L, Thibault B, et al. Cryoablation outcomes for AV nodal reentrant tachycardia comparing 4-mm versus 6-mm electrode-tip catheters. *Heart Rhythm* 2008; 5:230-234.
39. Chanani NK, Chiesa NA, Dubin AM, Avasarala K, Van Hare GF, Collins KK. Cryoablation for atrioventricular nodal reentrant tachycardia in young patients: predictors of recurrence. *Pacing Clin Electrophysiol* 2008; 31:1152-1159.