

AperTO - Archivio Istituzionale Open Access dell'Università di Torino

**Soft tissue changes after orthodontic surgical correction of jaws asymmetry evaluated by three-dimensional surface laser scanner**

**This is a pre print version of the following article:**

*Original Citation:*

*Availability:*

This version is available <http://hdl.handle.net/2318/120738> since

*Published version:*

DOI:10.1097/SCS.0b013e31824e25fc

*Terms of use:*

Open Access

Anyone can freely access the full text of works made available as "Open Access". Works made available under a Creative Commons license can be used according to the terms and conditions of said license. Use of all other works requires consent of the right holder (author or publisher) if not exempted from copyright protection by the applicable law.

(Article begins on next page)



# UNIVERSITÀ DEGLI STUDI DI TORINO

***This is an author version of the contribution published on:  
[The Journal of craniofacial surgery, Vol. 23, issue 5 ,2012,***

***DOI: 10.1097/SCS.0b013e31824e25fc]***

***The definitive version is available at:***

***[[http://ovidsp.tx.ovid.com/sp-](http://ovidsp.tx.ovid.com/sp-3.17.0a/ovidweb.cgi?QS2=434f4e1a73d37e8c6114a63cc85fea091569733d724da3fe0e09b9c2bbc7e63127c372de8f16893437a995ee2847a70aab4bcc695afb0ea95d47c7e70addfdb16fddf4f08609e462b5c2c992f1d625988038f74defef28dccf4283c34a1b9537d50e0bc177d7d072186d8f542a219c19bb1481dc210350e17ade49f449dce934a88661693bf8639835246ea77d3a82c31d708dedfc23a78dde5dec40beb86dbabb2bf0740046004485b51209be20e5e34287296a3b81f0338c3661196040fec799b13e958f83f80e0939545ea568738e29b5dd9deea3a4c78e794d3f4abbda2e581490c4cc834455a9c5261818f5d381133921be10259dd4a0413797133077141416388125ea713ca00ab49774d9c2853413f615db171fed5e9a5af7eb3683390f4e8bf17584eb64a835271741f14af00f2e27837497e94cad4053f71aa97aebc4b4073a3fc10140c7e58617e5b2681)***

***[3.17.0a/ovidweb.cgi?QS2=434f4e1a73d37e8c6114a63cc85fea091569733d724da3fe0e09b9c2bbc7e63127c372de8f16893437a995ee2847a70aab4bcc695afb0ea95d47c7e70addfdb16fddf4f08609e462b5c2c992f1d625988038f74defef28dccf4283c34a1b9537d50e0bc177d7d072186d8f542a219c19bb1481dc210350e17ade49f449dce934a88661693bf8639835246ea77d3a82c31d708dedfc23a78dde5dec40beb86dbabb2bf0740046004485b51209be20e5e34287296a3b81f0338c3661196040fec799b13e958f83f80e0939545ea568738e29b5dd9deea3a4c78e794d3f4abbda2e581490c4cc834455a9c5261818f5d381133921be10259dd4a0413797133077141416388125ea713ca00ab49774d9c2853413f615db171fed5e9a5af7eb3683390f4e8bf17584eb64a835271741f14af00f2e27837497e94cad4053f71aa97aebc4b4073a3fc10140c7e58617e5b2681](http://ovidsp.tx.ovid.com/sp-3.17.0a/ovidweb.cgi?QS2=434f4e1a73d37e8c6114a63cc85fea091569733d724da3fe0e09b9c2bbc7e63127c372de8f16893437a995ee2847a70aab4bcc695afb0ea95d47c7e70addfdb16fddf4f08609e462b5c2c992f1d625988038f74defef28dccf4283c34a1b9537d50e0bc177d7d072186d8f542a219c19bb1481dc210350e17ade49f449dce934a88661693bf8639835246ea77d3a82c31d708dedfc23a78dde5dec40beb86dbabb2bf0740046004485b51209be20e5e34287296a3b81f0338c3661196040fec799b13e958f83f80e0939545ea568738e29b5dd9deea3a4c78e794d3f4abbda2e581490c4cc834455a9c5261818f5d381133921be10259dd4a0413797133077141416388125ea713ca00ab49774d9c2853413f615db171fed5e9a5af7eb3683390f4e8bf17584eb64a835271741f14af00f2e27837497e94cad4053f71aa97aebc4b4073a3fc10140c7e58617e5b2681)***

# Journal of Craniofacial Surgery

## Soft tissue changes after orthodontic-surgical correction of jaws asymmetry evaluated by 3D surface laser scanner --Manuscript Draft--

<b>Manuscript Number:</b>	
<b>Full Title:</b>	Soft tissue changes after orthodontic-surgical correction of jaws asymmetry evaluated by 3D surface laser scanner
<b>Short Title:</b>	orthodontic-surgical correction of jaws asymmetry and 3D surface laser scanner
<b>Article Type:</b>	Anatomical Studies
<b>Keywords:</b>	orthognathic surgery, jaws asymmetry, 3D surface laser scanner
<b>Corresponding Author:</b>	Laura Verzé, M.D. Università di Torino Turin, ITALY
<b>Corresponding Author Secondary Information:</b>	
<b>Corresponding Author's Institution:</b>	Università di Torino
<b>Corresponding Author's Secondary Institution:</b>	
<b>First Author:</b>	Laura Verzé, M.D.
<b>First Author Secondary Information:</b>	
<b>All Authors:</b>	Laura Verzé, M.D. Francesca Antonella Bianchi, M.D. Eleonora Schellino, M.D. Guglielmo Ramieri, M.D.
<b>All Authors Secondary Information:</b>	
<b>Manuscript Region of Origin:</b>	ITALY
<b>Abstract:</b>	<p>Aesthetic improvement is an essential goal of treatment of facial asymmetry and it is often difficult to achieve. Reliable three-dimensional (3D) measurements are required to support outcome studies.</p> <p>In this study, 15 Caucasian adult subject, 9 females and 6 males, with maxillo-mandibular asymmetry and malocclusion were studied. The patients were treated with orthodontics and different surgical procedures in single or multiple steps. All patients received double jaw surgery, except one patient who underwent only maxillary osteotomy. Nine out of the 15 patients received additional procedures (genioplasty and rynoplasty) to achieve better symmetry. Posterior-anterior and lateral cephalometry and 3D facial surface data were obtained before (T0) and one year (T1) after surgery. Scan data at T0 and T1 were pooled by electronic surface averaging to obtain the mean pre- and post-treatment facial model. A symmetric model was constructed by averaging the actual T0 scans and their mirrored models to obtain the virtual optimal symmetric face. Different linear and angular measurements were then calculated for comparison of the mean T0 and T1 models. The normalization of facial proportion and a high increase of symmetry were evident. Residual defects were documented in the post-operative symmetry of the chin. Treatment of facial asymmetry, combined with dental occlusion problems, is still a challenge for maxillofacial surgeons. Orthognathic surgery provides an important improvement of symmetry, but further refinements of technique are still required. 3D evaluation results an effective method to support outcome studies on the surgical correction of complex facial deformities.</p>
<b>Suggested Reviewers:</b>	

**Journal of Craniofacial Surgery**  
**Editor-in-Chief**  
**Mutaz B. Habal MD, FRCSC**  
**Tampa Bay Craniofacial Center, Inc.**  
**Tampa, Florida**

### **Manuscript submission**

We have enclosed our manuscript entitled: “Soft tissue changes after orthodontic-surgical correction of jaws asymmetry evaluated by 3D surface laser scanner” for publication on the *Journal of Craniofacial Surgery*.

The present prospective study performed a 3D analysis of the soft tissue changes after surgical treatment of facial asymmetry in order to assess the amount of correction achieved. This study showed the benefits of 3D face analysis systems in investigating the effects of orthodontic and orthognathic surgery treatment of the facial asymmetry and that the 3D laser scanning technology is able to investigate even small post-treatment changes. Orthognathic surgery can give an important improvement of the facial asymmetry. However, the improved possibility to evaluate in details the efficacy of treatment on the soft tissues disclosed some less than optimal outcomes. Precise correction of facial asimmetry still appears a challenging task in maxillofacial surgery, and further technical improvements are still possible.

This paper is unpublished and it is not under current consideration elsewhere.

Best regards.

Laura Verzé

November 12, 2011

Laura Verzé, MD  
Dipartimento di Anatomia, Farmacologia e Medicina Legale - Sede Medicina Legale  
C.so Galileo Galilei 22 10126, Torino, Italy  
Tel. (39) 011 6705684, Fax (39) 011 6705934  
e-mail: [laura.verze@unito.it](mailto:laura.verze@unito.it)

**SOFT TISSUE CHANGES AFTER ORTHODONTIC-SURGICAL CORRECTION OF JAWS ASYMMETRY  
EVALUATED BY 3D SURFACE LASER SCANNER**

Verzé L. M.D.\*, Bianchi F.A. M.D.<sup>°</sup>, Schellino E. M.D.<sup>°</sup>, Ramieri G. M.D. D.D.S.<sup>°</sup>

\*Department of Anatomy, Pharmacology and Legal Medicine, University of Turin; <sup>°</sup>Department of Maxillofacial Surgery, University of Turin, Turin, Italy.

Address correspondence and reprint requests to Laura Verzé, MD, Department of Anatomy, Pharmacology and Legal Medicine, University of Turin, Corso Galileo Galilei 22, 10126 Turin, Italy.

fax: 00390116705934; telephone: 00390116705684; E-mail: laura.verze@unito.it

**Abstract**

Aesthetic improvement is an essential goal of treatment of facial asymmetry and it is often difficult to achieve. Reliable three-dimensional (3D) measurements are required to support outcome studies. In this study, 15 Caucasian adult subject, 9 females and 6 males, with maxillo-mandibular asymmetry and malocclusion were studied. The patients were treated with orthodontics and different surgical procedures in single or multiple steps. All patients received double jaw surgery, except one patient who underwent only maxillary osteotomy. Nine out of the 15 patients received additional procedures (genioplasty and rhyoplasty) to achieve better symmetry. Posterior-anterior and lateral cephalometry and 3D facial surface data were obtained before (T0) and one year (T1) after surgery. Scan data at T0 and T1 were pooled by electronic surface averaging to obtain the mean pre- and post-treatment facial model. A symmetric model was constructed by averaging the actual T0 scans and their mirrored models to obtain the virtual optimal symmetric face. Different

linear and angular measurements were then calculated for comparison of the mean T0 and T1 models. The normalization of facial proportion and a high increase of symmetry were evident. Residual defects were documented in the post-operative symmetry of the chin. Treatment of facial asymmetry, combined with dental occlusion problems, is still a challenge for maxillofacial surgeons. Orthognathic surgery provides an important improvement of symmetry, but further refinements of technique are still required. 3D evaluation results an effective method to support outcome studies on the surgical correction of complex facial deformities.

**Key words:** orthognathic surgery, jaws asymmetry, 3D surface laser scanner

## Introduction

Facial form has an important role not only in physiological activities, like mastication, breathing and speech, but also in communication and interpersonal relationship. Alteration of facial morphology may thus cause disturbances in mastication and self perception.

Limited discrepancies in the position and size of the two sides of the face are a common finding in the healthy population, and considered as normal (1). Facial asymmetries, instead, are those complex deformities that feature relevant differences in the location of anatomical landmarks, in the size and spatial orientation of anatomical structures and in the dimension and curvature of facial surfaces. The lower third of the face deviates more frequently and with greater amount of asymmetry than the upper and middle thirds (2).

On the basis of the anatomical structures involved, facial asymmetry can be classified into dental, skeletal, soft tissue and functional problems. However, a combination of these aspects is often present. Maxillary displacement can result in a dental midline discrepancy and/or a combination of yaw and roll of the maxilla which causes canting of both the occlusal plane and the lips (3, 4). Mandibular lateral displacement is characterized by deviation of the chin from the facial midline, asymmetry of the cheeks and lower facial contour, posterior cross bite and dental and skeletal midline discrepancies (5). Important jaws asymmetry is considered a functional and psychological problem, which requires correction.

The goals of orthodontic-surgical correction of facial asymmetry should consist in both occlusal correction and alignment of dental midlines and chin to the facial midline, leveling of oral commissures and lips and symmetric appearance during smiling (6).

In order to investigate and measure the facial morphology, in the past two dimensional (2D) techniques such as direct measurement, photograph or x-rays have been used, but these techniques are inadequate to describe three-dimensional (3D) surfaces. To overcome these limits, 3D surface facial scanning has been introduced. 3D analysis of soft tissues changes after bimaxillary surgery

has been proposed in skeletal Class I, II and III patients (7, 8, 9, 10). 3D analysis based on laser surface scanning has been also used for investigating facial asymmetry (11).

The present prospective study performed a 3D analysis of the soft tissue changes after surgical treatment of facial asymmetry in order to assess the amount of correction achieved.

## **Patients and methods**

Fifteen Caucasian adult subjects (mean age 20.9, range 16-44, 9 females and 6 males), with serious asymmetry, were recruited for the study. They did not present a history of cranio-facial injury or operation and required facial asymmetry correction. Informed consent was obtained from all participants.

Patients presented asymmetry with right (3 patients) or left (12) lateral deviation. Sagittal and vertical jaws discrepancies, and malocclusion were variably associated (Tables I, II).

Different surgical procedures were performed, in a single or in multiple steps (Table I). Two patients required transverse palatal distraction (TPD) to correct the maxillary defect and three mandibular distractions to correct mandibular hypoplasia. All patients received double jaw surgery, except one (patient n° 3) who was treated exclusively with maxillary advancement. Nine out of the 15 patients received also contemporary adjunctive procedures (genioplasty and rhynoplasty).

Postero-anterior (PA) and lateral (L) cephalometry and 3D facial surface data were obtained before (T0) and one year (T1) after surgery.

### *Cephalometric measurements*

PA and L cephalograms were traced by one examiner using the software Dolphin 11.0 Premium (Dolphin Imaging, Chatsworth, CA, USA). The following measurements were obtained to assess sagittal, vertical and transversal skeletal and dental movements: Posterior Facial Height (Go-CF), Ramus Position, Maxillary Depth (FH-NA)N, Facial Angle (FH-NPo), Facial Axis-Ricketts (NaBa-PtGn), Convexity (A-NPo), U-Incisor Protusion (U1-Apo), U1-FH, U-Incisor Inclination



(U1-APo), L1 Protrusion (L1-APo), L1 to A-Po, Mandibular Incisor Extrusion, Overjet, Overbite, Dental Midline Discrepancy, Maxillo-Mandibular Midline, Occlusal Plane Tilt, Postural Symmetry, Maxillary Width, Mandibular Width, Facial Width, A-Me-MSR.

Open Source Epidemiologic Statistics for Public Health, (Version 2.3.1. [www.OpenEpi.com](http://www.OpenEpi.com)),) was used for the statistical analyses. Descriptive statistics including the mean and standard deviation were calculated for the measurements obtain on the cephalograms. The t test for paired groups was used to assess differences between T0 and T1. The levels of significance were set at  $P < 0.05$ ,  $P < 0.01$  and  $P < 0.001$  (Table II).

A subsample of 20 randomly selected radiographs were retraced and digitized 1 month later to calculate the systematic errors. All the angular and linear measurements were compared between the two time sets by paired t test. All the measurements presented no significant difference at retracing.

#### *Facial scan and data processing*

Facial surface data were acquired using a Head and Face Color 3D Scanner (3030RGB; Cyberware, Inc., Monterey, California). All subjects were registered with the head in natural position (nhp), the eyes closed and teeth in occlusion. The scanning method took into consideration previous observations concerning the positioning of the subject and environmental conditions. The detailed protocol to reduce the artifacts was previously described (12).

The acquired data were transferred to a graphics workstation for viewing and elaboration with Cyberware Echo software (Cyberware Inc., Monterey, California). Scanned data sets were first restricted to the facial area and then reduced from around 160.000 to 30.000 points. Facial surface reconstruction, multiple scan alignment and measurements were carried out using Rapid Form 2004 software (INUS Technologies Inc., Seoul, South Korea).

For the purpose of constructing an averaged facial model, all 3D reconstructions were oriented with deviation of the face to the left side, by mirroring the models of the 3 patients with right facial deviation.

Facial scans at T0 and T1 were pooled together by electronic surface averaging to obtain the mean facial model before (T0) and after treatment (T1). For each patient, a virtual symmetric facial model was constructed by averaging the actual T0 laser scan and its mirroring, and all these models were then averaged to obtain the virtual optimal symmetric face (S). 3D average surfaces were constructed using the software Morphostudio (Biomodelling Solutions, UK) and a mesh framework algorithm based on nine anatomical landmarks.

T0-T1, T0-S, T1-S were registered on homologous points. Face angle plot was then represented for the images at T0, T1 and S (Fig. 1).

Reference vertical (midline through glabella) and horizontal (through right and left endocanthion) planes were constructed on the S model (Fig.1).

Different linear and angular measurements were calculated for comparison of the T0 and T1 models using 13 landmarks taken from classical anthropometry. The landmarks were: enr, right endocanthion; enl, left endocanthion; zyr, right zygion; zyl, left zygion; alr, right alar crest point; all, left alar crest point; sn, subnasale; chr, right cheilion; chl, left cheilion; ls, labialis superior; li, labialis inferior; pg, pogonion, me, menton (Table III).

## **Results**

Treatment was completed in all the patients involved in this study.

Cephalometric changes and clinical outcomes are summarized in Tables II and IV.

The L measurements showed a significant increase of the posterior facial height, and of facial convexity, and the improvement of the upper incisors axis, of the lower incisors extrusion, of the overjet and overbite. The PA measurements revealed the significant improvement of dental midlines alignment, of the occlusal plane tilt and of the A-Me-MSR values (Table II).

The comparison of facial surface at T0 and T1 showed an overall increase of symmetry. Normalization of the vertical and transversal position of the labial commissures and of the nasal alae were evident. Increase of the sagittal projection of the lips and of the chin was also noticed. Reduced, but still noticeable deviation of the chin on the symmetry axis was however observed (Fig. 1, Table III).

Cross sections through zy, sn, ls, ch, li, and pg clearly demonstrated an improvement of symmetry of surface profiles at T1(Fig. 2).

Measurements at T0 and T1 documented that the major post surgical changes were in the lower area of the face. After treatment, the distance of the lips from endocantion (en-ch) and from the columella (sn-ch) were increased, demonstrating lengthening of the upper lip, as well as the alar base width. At T0, the Al and the Ch points of the two sides demonstrated both vertical and horizontal asymmetry, particularly noticeable concerning the lips position. Symmetry of these measurements was significantly improved at T1; the difference of the distance of Ch from the reference plane on the two sides changed from around 4 mm to below 1 mm on the vertical axis, and from around 9 mm to 1.2 mm transversally (Table III).

Increase sustain of the lips was also evident, with enlargement of the inter-commissural distance (Ch-Ch).

## **Discussion**

Increasing attention is paid by patients and professionals to the aesthetic effects of orthodontic and maxillofacial surgical treatment so that the precise knowledge of the facial effects of any treatment is required (13, 14).

Limited information is at present available on the aesthetic outcome after the correction of facial asymmetry. Ko et al. (2009) (6) studied the characteristics of facial asymmetry before surgery and evaluated the facial skeletal changes and stability after two-jaw orthognathic surgery by means of posterior-anterior and lateral cephalometry, and of measurements on frontal facial photographs.

Jung YJ et al. (2009) (15) described the hard and soft tissue changes after correction of mandibular prognathism and facial asymmetry by mandibular setback surgery using 3D computerized tomography. Hajeer MY et al. (2004) (16) developed an original 3D method of analysis of facial asymmetry based on landmarks application in 44 patients treated by bimaxillary osteotomy or by maxillary advancement alone. All these Authors demonstrated a general improvement of skeletal symmetry, as evaluated on single landmarks position, documenting the limits of treatment especially in class II patients.

In the present report preoperative and postoperative PA and L cephalograms and 3D facial surface data were studied to assess hard and soft tissue changes after correction of facial asymmetry and malocclusion by one or two jaws surgery and contemporary adjunctive procedures.

In L cephalograms an increase of posterior facial height and a normalization of overjet and overbite were observed. These effects were likely due to the mandibular vertical lengthening on the deficient side and to sagittal maxillo-mandibular repositioning. Comparing the PA measurements between T0 and T1, normalization of maxillo-mandibular dental midline alignment and of occlusal plane tilt, and a great improvement of lateral deviation of the chin were observed. These effects may be attributed to the surgical maxillo-mandibular complex roll which restore mouth and chin skeletal symmetry.

In order to evaluate the efficacy of treatment on the soft tissues symmetry, in the present study a mean pre-surgical and post-surgical face were created and compared with a virtual optimal symmetric face (S). The comparison of measurements of the cutaneous landmark distances on T0 and T1 revealed no modification in the upper region of the face and that the major post surgical changes were in the lower face. In the frontal view an improvement of symmetry of the nasal base and an important correction of the lips, both vertically and horizontally, were observed. Increased support of the lips and increase of the inter-commissural distance were also shown. Though a significant normalization of soft tissue profiles was generally observed, residual defects were documented in the post-operative symmetry of the chin, as previously evidenced by other Authors

(6). The comparison of cephalometric skeletal measurements and scanner soft tissues data evidenced incomplete cutaneous symmetry achievement in spite of acceptable bone repositioning.

## **Conclusions**

This study showed the benefits of 3D face analysis systems in investigating the effects of orthodontic and orthognathic surgery treatment of the facial asymmetry and that the 3D laser scanning technology is able to investigate even small post-treatment changes.

Orthognathic surgery can give an important improvement of the facial asymmetry. However, the improved possibility to evaluate in details the efficacy of treatment on the soft tissues disclosed some less than optimal outcomes. Precise correction of facial asimmetry still appears a challenging task in maxillofacial surgery, and further technical improvements are still possible.

## Bibliography

1. Farkas L. *Antropometry of the head and face*. New York: Raven Press 1994
2. Severt TR, Profitt WR. The prevalence of facial asymmetry in the dentofacial deformities population at the University of North Carolina. *Int J Adult Orthodon Orthognath Surg* 1997;12:171-6
3. Cheong YW, Lo LJ. Facial asymmetry: etiology, evaluation and management. *Chang Gung Med J* 2011;34:341-51
4. Bergeron L, Tu CC, Chen YR. Single-split technique for correction of severe facial asymmetry: correlation between intraoperative maxillomandibular complex roll and restoration of mouth symmetry. *Plast Reconstr Surg* 2008;122:1535
5. Ishizaki K, Suzuki K, Mito T, et al. Morphologic, functional, and occlusal characterization of mandibular lateral displacement malocclusion. *Am J Orthod Dentofacial Orthop*. 2010;137:454.e1-9; discussion 454-5
6. Ko EW, Huang CS, Chen YR. Characteristics and corrective outcome of face asymmetry by orthognathic surgery. *J Oral Maxillofac Surg* 2009;67:2201-9
7. McCance AM, Moss JP, Fright WR, et al. A three dimensional analysis of soft and hard tissue changes following bimaxillary orthognathic surgery in skeletal III patients. *J Oral Maxillofac Surg* 1992;30:305-12
8. Moss JP, McCance AM, Fright WR, et al. A three-dimensional soft tissue analysis of fifteen patients with Class II, Division 1 malocclusions after bimaxillary surgery. *Am J Orthod Dentofacial Orthop* 1994;105:430-7
9. Ramieri GA, Nasi A, Dell'acqua A, et al. Facial soft tissue changes after transverse palatal distraction in adult patients. *Int J Oral Maxillofac Surg* 2008;37:810-8
10. Baik HS, Kim SY. Facial soft-tissue changes in skeletal Class III orthognathic surgery patients analyzed with 3-dimensional laser scanning. *Am J Orthod Dentofacial Orthop* 2010;138:167-78

11. O'Grady KF, Antonyshyn OM Facial asymmetry: three-dimensional analysis using laser surface scanning. *Plast Reconstr Surg* 1999;104:928-37
12. Ramieri GA, Spada MC, Nasi A, et al. Reconstruction of facial morphology from laser scanned data. Part I: reliability of the technique. *Dentomaxillofac Radiol* 2006;35:158-64
13. Proffitt WR, Fields HW Jr, Sarver DM. *Contemporary Orthodontics*. St Louis: Mosby Elsevier 2007
14. Proffit WR, White RP Jr, Sarver DM. *Contemporary Treatment of Dentofacial Deformity*. St Louis: Mosby Elsevier 2003
15. Jung YJ, Kim MJ, Baek SH. Hard and soft tissue changes after correction of mandibular prognathism and facial asymmetry by mandibular setback surgery: three-dimensional analysis using computerized tomography. *Oral Surg Oral Med Oral Pathol Oral Radiol Endod* 2009;107:763-771e8
16. Hajeer MY, Ayoub AF, Millett D. Three-dimensional assessment of facial soft-tissue asymmetry before and after orthognathic surgery. *Br J Oral Maxillofac Surg* 2004;42:396-404

## Legends to figure

**Fig. 1** - Top: averaged faces at  $T_0$ ,  $T_1$  and S with horizontal and vertical reference planes. Bottom: face angle plot. Note the different localization of the medial area of the face at  $T_0$ ,  $T_1$  and S.

**Fig. 2** -  $T_0$  blue,  $T_1$  green, S red. Axial sections of the three superimposed shells at different levels passing through zy (A), sn (B), ls (C), ch (D), li (E), pg (F). It is evident the correction of the cutaneous profile symmetry at the different levels.



**Table. I.** Patient's pathology description and problems concerning their occlusion and surgical treatment. OVB: overbite; OVJ: overjet; MD: mandible (intra- or extra-oral) distraction; C: combined maxilla-mandible surgery; RSP: rhino-septoplasty; LF1: Le Fort I; TPD: trans-palatal distraction; G: genioplasty; CLP: cleft lip and palate; front block: mandibular anterior segmental osteotomy.

Patients	Angle	Pathology										Surgery
		Anterior cross bite	Posterior cross bite	Mandible lateral deviation (mm)	Direction of mandible lateral deviation	Maxilla superior rotation	Inclination of the occlusal plane	Trasversal palatal deficit	Vertical problems	OVB (mm)	OVJ (mm)	
1	III	-	-	11	Left (left mandibular hypoplasia)	yes	yes	-	-	2	2	Left MD; C; G+front block+ RSP
2	III	yes	yes	11	Left (right mandibular elongation)	-	-	yes	Open bite	-25	-10	TPD+ front block; C
3	III	-	-	8	Left	-	yes	-	Deep bite	3	4	LF1+ G
4	III	yes	yes	6	Left	-	-	-	Open bite, maxillary hypoplasia	-8	-3	C
5	III	yes	yes	4	Right	-	-	-	Open bite, maxillary hypoplasia	-3	-4	C+ G
6	III	-	yes	5	Left	-	-	yes	Open bite	-2	0	TPD; C
7	II	-	-	11	Left (left mandibular hypoplasia)	yes	yes	-	Deep bite	2	10	Left MD;C + G
8	III	yes	-	6	Left	yes	-	-	Open bite	1	1	C+ RSP
9	III	-	yes	10	Left	yes	yes	-	Deep bite, CLP, maxillary hypoplasia	3	3	C+RSP; grafts+ G
10	III	yes	yes	12	Left	yes	yes	-	Open bite	-3	-3	C + RSP
11	III	yes	-	2	Left	-	-	-	Open bite	-4	1	C
12	III	-	-	9	Left	-	yes	-	-	3	1	C + G
13	II	-	-	6	Right(right mandibular hypoplasia)	yes	yes	-	Deep bite	3	3	MD extra-oral + MD intra-oral/ C+G+RSP
14	III	yes	yes	7	Right	yes	-	-	Open bite	-2	-15	C
15	III	yes	yes	5	Right	-	yes	-	Open bite, maxillary hypoplasia	2	-4	C

**Table II.** Measurements of lateral (L) and posterior-anterior (PA) cephalograms. Mean and standard deviation [SD]. \*: P < .05, \*\*: P < .01, \*\*\*: P < .001

		<i>Normal values</i>	<i>T0</i>	<i>T1</i>	<i>p-value</i>
<b>L</b>	Posterior Facial Height (Go-CF)(mm)	60.1 [3.3]	61.03 [7.93]	68.06 [13.82]	<b>0.0462*</b>
	Ramus Position (°)	76 [3]	73.08 [11.06]	77.2 [8.27]	
	Maxillary Depth (FH-NA)N(°)	90 [3]	87.17 [6.2]	90.74 [6.76]	
	Facial Angle (FH-NPo) (°)	88.6 [3]	86.74 [10.13]	88.4 [8.73]	
	Facial Axis-Ricketts (NaBa-PtGn) (°)	90 [3.5]	87.25 [6.63]	87.3 [5.39]	
	Convexity (A-NPo) (mm)	0.7 [2]	0.2 [3.51]	2.89 [6.38]	<b>0.0326*</b>
	U-Incisor Protusion (U1-APo) (mm)	3.5 [2.3]	5.24 [4.91]	4.54 [3.37]	
	U1-FH (°)	111 [6]	113.47 [10.62]	100.65 [27.05]	<b>0.0012**</b>
	U-Incisor Inclination (U1-APo) (°)	28 [4]	26.15 [10.8]	22.01 [8.65]	
	L1 Protrusion (L1-APo) (mm)	1 [2.3]	3.22 [2.68]	1.13 [2.23]	
	L1 to A-Po (°)	22 [4]	24.31 [5.46]	23.49 [5.73]	
	Mandibular Incisor Extrusion (mm)	1.2 [2]	-0.02 [1.88]	0.69 [0.7]	<b>0.0006***</b>
	Overjet (mm)	2.5 [2.5]	1.05 [6.18]	3.84 [1.53]	<b>0.000005***</b>
	Overbite (mm)	2.5 [2]	0.06 [3.78]	1.35 [1.37]	<b>0.0005***</b>
<b>P A</b>	Dental Midline Discrepancy (mm)	0 [1.5]	0.02 [1.66]	0.1 [0.71]	<b>0.0030**</b>
	Maxillo-Mandibular Midline (mm)	0 [2]	5.53 [5.87]	0.63 [2.81]	<b>0.0093**</b>
	Occlusal Plane Tilt (°)	0 [2]	-3.31 [4.11]	-1.20 [2.19]	<b>0.0247*</b>
	Postural Symmetry (°)	0 [2]	-1.27 [2.51]	0.88 [3.58]	
	Maxillary Width (mm)		64.07 [8.28]	59.3 [6.52]	
	Mandibular Width (mm)		87.85 [12.01]	89.69 [8.23]	
	Facial Width (mm)		132.23 [11.73]	123.16 [10.42]	
	A-Me-MSR (°)	0 [2]	6.12 [5.78]	0.84 [2.38]	<b>0.0020**</b>

**Table III.** Point to point distances of the landmarks considered. Values in mm. (X= horizontal reference plane; Y= vertical reference plane, see fig.1)

<b>Distances</b>		<b>S</b>	<b>T0</b>	<b>T1</b>
<b>Symmetry</b>	en r-al r	40.96	40.22	42.16
	en l-al l	41.45	40.96	42.57
	en r-ch r	66.89	66.64	67.72
	en l-ch l	67.16	65.54	68.35
	al r-ch r	28.37	26.64	27.92
	al l-ch l	28.40	26.59	27.30
	sn-ch r	36.70	35.08	37.99
	sn-ch l	36.25	35.95	39.08
<b>Vertical</b>	al r-X	40.67	40.30	41.62
	al l-X	40.78	38.91	41.28
	ch r-X	64.09	66.09	67.39
	ch l-X	64.17	62.27	66.75
	sn-ul	13.15	15.00	13.19
	ls-li	18.56	19.21	18.58
	li-pg	20.63	22.04	20.50
	pg-me	12.43	16.68	13.93
	sn-pg	52.92	55.23	52.61
	sn-me	64.74	73.27	66.18
	me-X	110.67	113.03	110.14
<b>Transversal</b>	ch r-sn-ch l	91.01	85.00	92.29
	ch r-pg-ch l	78.59	77.54	83.14
	al r-Y	15.88	15.70	18.45
	al l-Y	15.99	16.84	17.71
	ch r-Y	23.43	19.82	26.97
	ch l-Y	23.44	28.96	25.73
	pg-Y	0	9.71	3.55
<b>Angles</b>	naso-labial angle	11667	11750	10214
	labial-mental angle	14410	14087	14020

**Table IV.** Results of surgical treatment: absence (-) or persistence (\*) of defects . OVB: overbite; OVJ: overjet.

Patients	Pathology							
	Anterior cross bite	Posterior cross bite	Mandible lateral deviation (mm)	Maxilla superior rotation	Inclination of the occlusal plane	Trasversal palatal defect	OVB	OVJ
1	-	-	* 5	-	-	-	2	*3
2	-	-	-	-	-	-	2	2
3	-	-	* 1	-	-	-	2	2
4	*cross 22-23	-	-	-	-	-	2	2
5	-	-	-	-	-	-	2	*5
6	-	-	-	-	-	-	2	2
7	-	-	*2	-	-	-	* 3 slight deep	*5
8	-	-	-	-	-	-	2	2
9	-	-	-	-	-	-	* 3 slight deep	2
10	-	-	*2	-	-	-	* 1	15
11	-	-	-	-	-	-	2	2
12	-	-	-	-	-	-	2	2
13	-	-	*3	-	-	-	2	2
14	-	* bilateral	*1	-	-	*yes	*3	2
15	-	-	*1	-	-	-	2	2

Figure  
[Click here to download high resolution image](#)

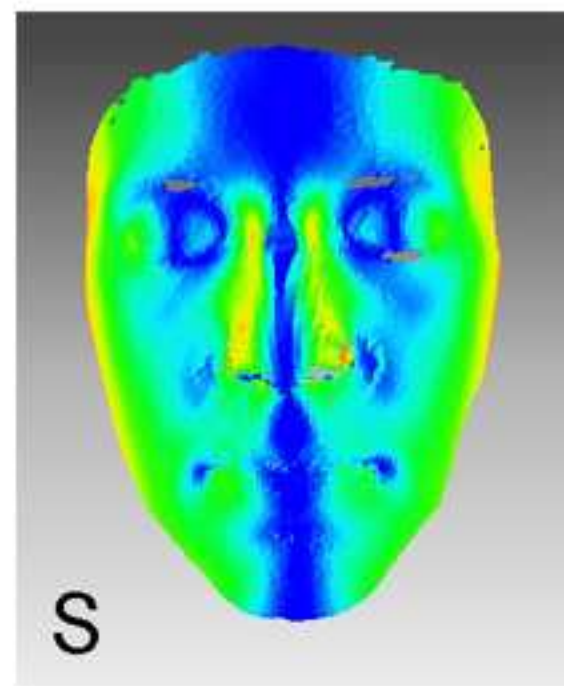
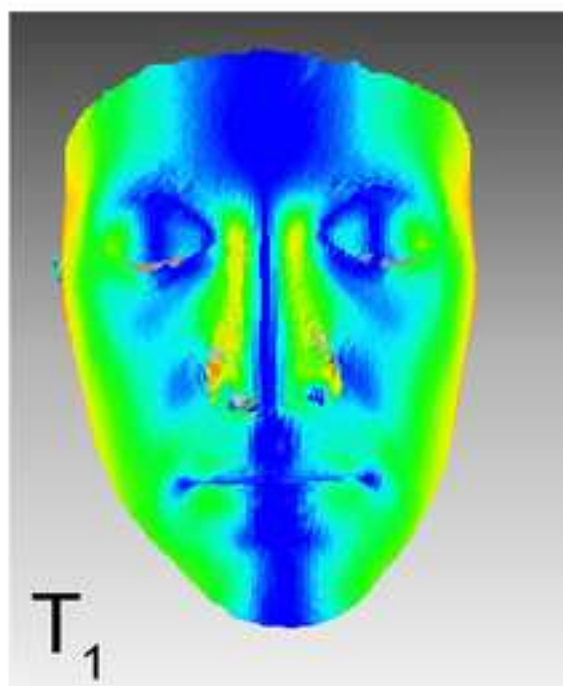
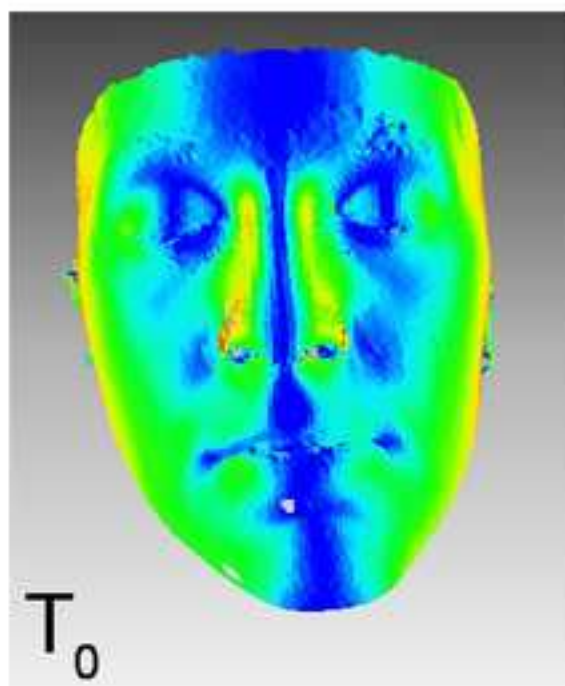





Figure  
[Click here to download high resolution image](#)

