

IRIS A_{per}TO



UNIVERSITÀ
DEGLI STUDI
DI TORINO

This is the author's final version of the contribution published as:

Rolle L; Ceruti C; Timpano M; Sedigh O; Destefanis P; Galletto E; Falcone M; Fontana D.. A New, Innovative, Lengthening Surgical Procedure for Peyronie's Disease by Penile Prosthesis Implantation with Double Dorsal-Ventral Patch Graft: The "Sliding Technique". JOURNAL OF SEXUAL MEDICINE. 9 (9) pp: 2389-2395.
DOI: 10.1111/j.1743-6109.2012.02675.x.

When citing, please refer to the published version.

Link to this full text:

<http://hdl.handle.net/2318/107751>

This full text was downloaded from iris - AperTO: <https://iris.unito.it/>

iris - AperTO

University of Turin's Institutional Research Information System and Open Access Institutional Repository

A New, Innovative, Lengthening Surgical Procedure for Peyronie's Disease by Penile Prosthesis Implantation with Double Dorsal-Ventral Patch Graft: The “Sliding Technique”

Luigi Rolle MD, PhD, Carlo Ceruti MD, PhD, Massimiliano Timpano MD, Omidreza Sedigh MD, Paolo Destefanis MD, Elisa Galletto MD, Marco Falcone MD, Dario Fontana MD

Corresponding author: Luigi Rolle, MD, Ospedale “San Giovanni Battista—Molinette,” Divisione Universitaria di Urologia 2, Corso Bramante 88, 10126 Torino, Italy. Tel: +390116336527; Fax: +390116335707; E-mail: luigi.rolle@unito.it

ABSTRACT

Introduction. Peyronie's disease is the result of the formation of fibrous plaques in the tunica albuginea of the penis; typical presentations of the disease are represented by pain during erection, erectile dysfunction, and penile deformities, such as curvature, narrowing, and penile shortening. The most complex treatment is related to penile shortening.

Aim. To find a safe procedure in penile shortening due to Peyronie's disease providing a satisfactory lengthening, allowing an early stabilization of the penis, and preventing axial tension on the neurovascular bundles during dilation.

Methods. We describe a new lengthening surgical procedure based on a ventro-dorsal incision of the tunica albuginea, penile prosthesis implantation, and double dorsal-ventral patch grafting with porcine small intestinal submucosa. Three patients, affected by Peyronie's disease with penile shortening and erectile dysfunction, underwent this procedure with approval of our local ethical committee.

We evaluated the penis lengthening, intraoperative and postoperative complications, patient's preoperative and postoperative sexual life satisfaction (International Index of Erectile Function [IIEF] questionnaire).

Results. The average operative time was 2 hours and 50 minutes. No major intraoperative nor postoperative complications occurred. No significant bleedings were recorded. Patients were discharged after 48–72 hours.

The average increase in length obtained was 3.2 cm. All patients resumed sexual intercourses with satisfaction; no significant loss of sensitivity or any sign of vascular distress of the glans was recorded. The follow-up is 13 months. The average IIEF score is 60.

Conclusions. The lengthening of the penis by a double dorsal-ventral patch graft is an innovative procedure that is based on current techniques of plaque incision and grafting, and that can easily resolve severe shortening of the penis due to Peyronie's disease. In the cases presented, this procedure resulted easily, effectively, and safely. Nevertheless, the technique proposed in this article shall be validated through prospective studies with larger samples

Introduction

Peyronie's disease is the result of the formation of fibrous plaques in the tunica albuginea of the penis; typical presentations of the disease are represented by pain during erection, erectile dysfunction, and penile deformities [1,2].

The pain, an early and unsteady sign, usually regresses spontaneously and sometimes is improved by medical therapy [3]; thus, in very few cases, it represents a clinical problem.

Erectile dysfunction can be treated pharmacologically (usually by phosphodiesterase-5 inhibitors, less frequently using intracavernous injection) only when axial deviation and penile deformity is mild or not so severe to impair penetration. In patients who are not responders to medical therapy, or in the case of erectile dysfunction associated with significant penile bending, the placement of a penile implant, with or without plaque surgery, can be adopted [4].

Penile deformities include curvature, narrowing, and penile shortening. Indeed in some patients, the fibrous plaque is extensive and involves the whole circumference of the penis and the septum, resulting in penile shortening rather than angulation during erection. The surgical intervention is usually adopted for the treatment of severe penile deformities.

Penile curvatures, without erectile dysfunction, can be corrected through plaque surgery [5–11] or using Nesbit technique [12–15].

The most complex treatment is related to penile shortening. Recently, the use of penile extenders, employed to stretch the penis under a gentle tension, has been introduced in the clinical practice, recording in some cases an increase in penile length [16,17].

Among the surgical strategies, the division of the suspensory ligament can result in a lengthening of the free portion of the shaft, without a real lengthening of the corpora cavernosa and with a low rate of satisfaction for the patients. This technique should be considered if associated with other surgical procedures [18].

Since the first report of Rigaud and Berger in 1995, circular relaxing incision, apposition of one or more patches of various materials and positioning of a penile implant has been widely employed and accepted for the treatment of severe shortening with erectile dysfunction [19,20].

Other authors suggested the use of a variable geometry prosthesis (AMS 700 LGX, Minnetonka, MN, USA), in patients needing prosthetic surgery or an implantation of a temporary intra-cavernous expander (Apollo Prosthesis, Giant Medical Corporation, Cremona, Italy), to be replaced by a definitive prosthetic implant [21].

Aims

We propose a personal, new, safe procedure in penile shortening due to Peyronie's disease, with an original ventro-dorsal incision of the tunica albuginea, providing a satisfactory lengthening and an early stabilization of the penis, preventing axial tension on the neurovascular bundles during the procedure.

Methods

A prospective study concerning three patients, aged 50, 61, and 67 years, complaining of shortened penis without major curvatures, erectile dysfunction, inability to satisfy the sexual partner, and strong dissatisfaction about their shortened penis is presented in this article. A diagnosis of Peyronie's disease was made in all the three cases. The patients asked us to correct both erectile dysfunction and penile shortening, deemed excessive for a satisfying sex life. The average flaccid stretched penis length, measured from the pubo-penile angle to the tip, was 7.5–8 and 9.5 cm, respectively.

Patients were then proposed for penile grafting, according to our procedure, and prosthesis implantation. Two of them underwent an implantation of a non-inflatable penile prosthesis, and the last one of an inflatable three-component penile prosthesis.

All patients were extensively informed about the procedure and provided a written consent for plaque incision, grafting, and penile prosthesis implantation.

The surgical procedure was performed according to the ethical standards of the Helsinki Declaration and with the approval of our local ethical committee.

Surgical Technique

The procedure is performed under spinal anesthesia. Antibiotic prophylaxis is performed with piperacillin and amikacin. A first circumferential subcoronal incision is made, and the penis is degloved to the penile root. The penis is extracted from the skin through a second penoscrotal incision. The Buck's fascia is then longitudinally incised at the sides of the corpora cavernosa, and the dorsal neurovascular bundle is isolated in centripetal direction, for almost the entire length of the penis to be able to get the maximum elongation. Then the corpus spongiosum of the urethra is separated from the corpora cavernosa. Two longitudinal incisions of the tunica albuginea are then carried out on the sides of the two corpora cavernosa; the first incision at 3 o'clock on the left ($a_l \rightarrow b_l$), the second incision at 9 o'clock on the right ($a_r \rightarrow b_r$). The length of the incision should be adapted to the possible stretching of the neurovascular bundle. In all the three cases, a 4-cm lateral incision was obtained. A dorsal semicircular incision is made to connect the upper ends of the lateral incisions ($a_l \rightarrow a_r$) and a second semicircular ventral incision is made to connect point b_l to point b_r (Figures 1A and 2).

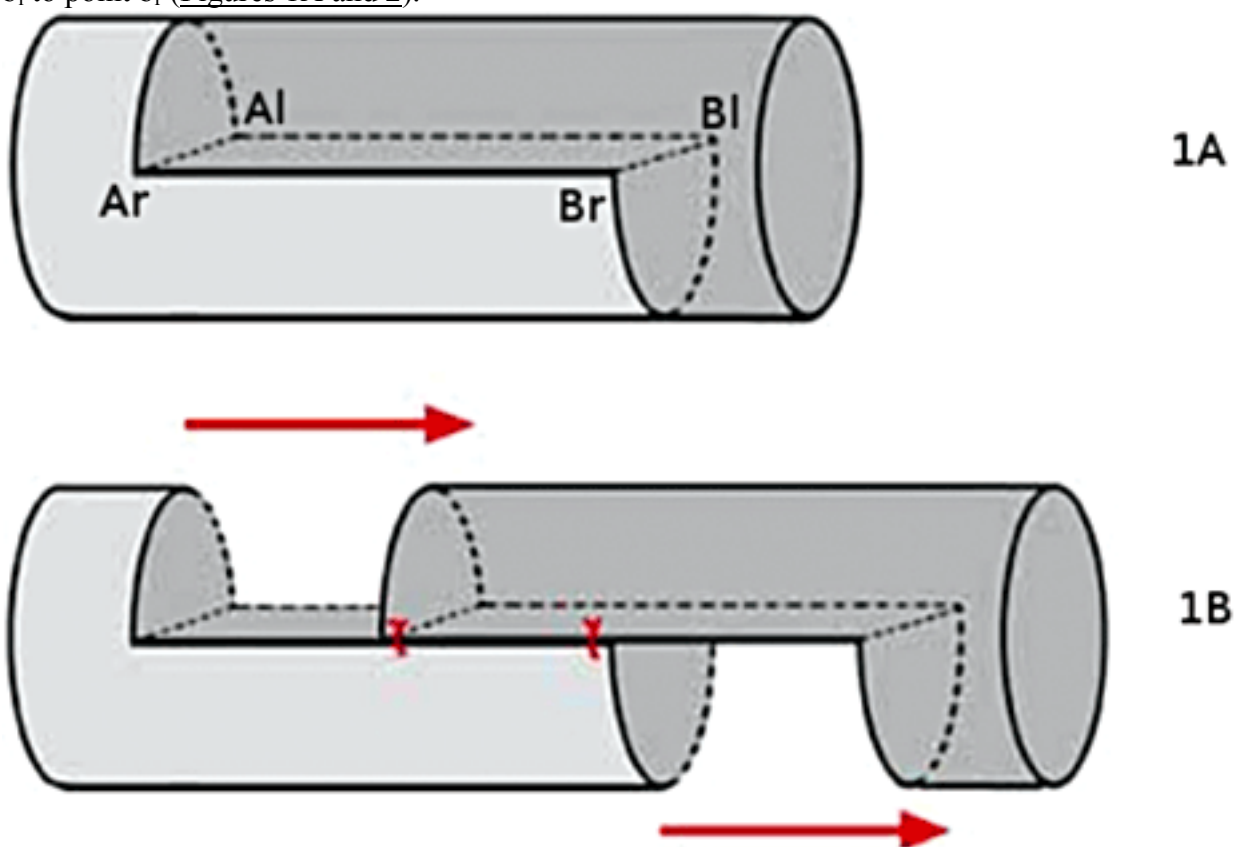


Figure 1.

A schematic view of the procedure. 1A: 4-cm longitudinal incisions of the tunica albuginea are then carried out on the sides of the two corpora cavernosa; the first incision at 3 o'clock on the left side ($a_l \rightarrow b_l$), the second incision at 9 o'clock on the right side ($a_r \rightarrow b_r$). A dorsal semicircular incision

is made to connect the upper ends of the lateral incisions (al → ar) and a second semicircular ventral incision is made to connect the point bl to point br. 1B: Incision and dissection of the tunica albuginea from the cavernous tissue and from the septum, a gentle traction is exerted on the glans, thus obtaining a real lengthening of the distal part of the penis from the proximal one. The stretching is arrested when the neurovascular bundle reached the maximum length. Finally, two 3/0 polyglycolic sutures are applied between the two lateral portions of the albuginea still mated.

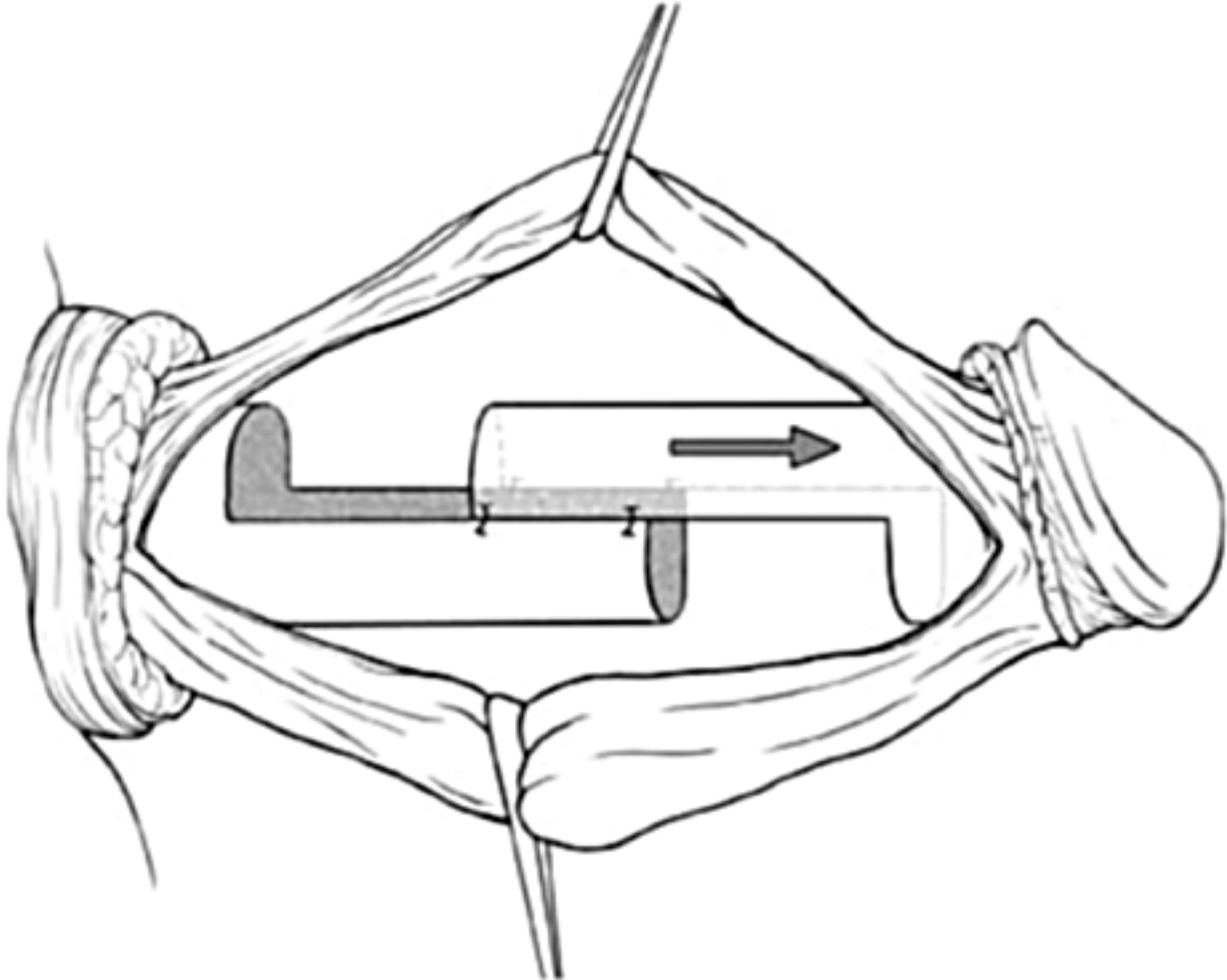


Figure 2.

The stretching is arrested when the neurovascular bundle reached the maximum length. View of the right side of the penis.

After incision and dissection of the tunica albuginea from the cavernous tissue and from the septum, a gentle traction is exerted on the glans, thus obtaining a sliding of the distal part of the penis from the proximal one (Figures 1B and 3). The stretching is arrested when the neurovascular bundle reached the maximum length. Two 3/0 polyglycolic sutures are applied between the two lateral portions of the albuginea still mated. Two rectangular and bow-shaped defects of tunica albuginea remain: the first one, dorsal and proximal and the second one, distal and ventral. From the proximal part, dilation of both corpora cavernosa and the measurement of their length are performed with Subrini's dilators. This dilation can be easily performed without the risk of longitudinal traction on the neurovascular bundle or urethra, as the distal and proximal part of the penis are well established by the sutures on the two longitudinal incisions previously applied. The two cylinders of the prosthesis are easily inserted in the two corpora cavernosa. The two losses of substance were then covered with two rectangular grafts of porcine small intestinal submucosa (Figure 4). In the case of an inflatable penile prosthesis implantation, we suggest to place the double dorsal-ventral patch graft before inserting the two cylinders in the corpora cavernosa, in order to prevent the risk of damaging them. The operation ends with circumcision, leaving a small drainage tube.

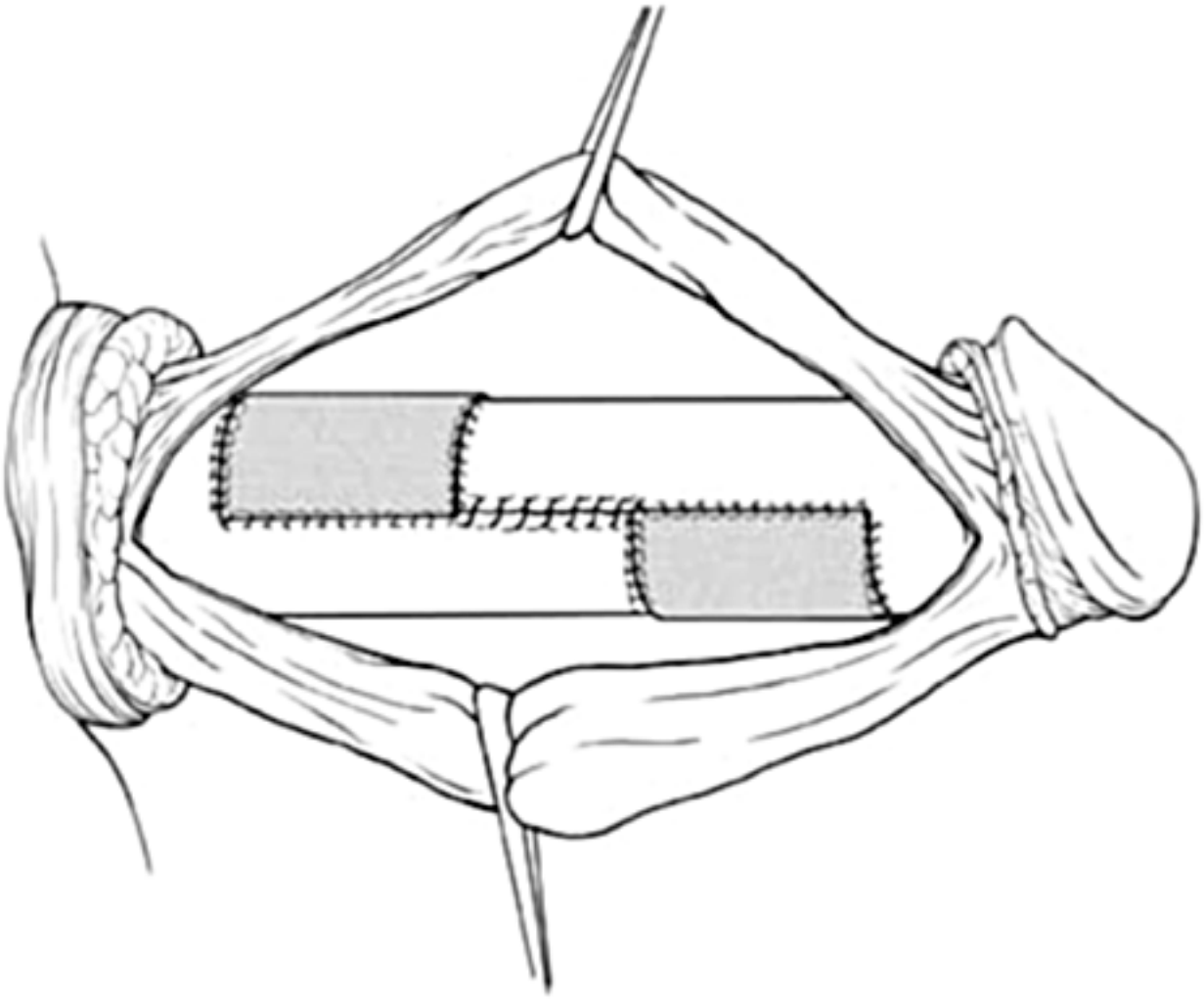


Figure 3.

The final result after the two losses of substance are covered with two rectangular grafts of 3.5×4 cm of porcine small intestinal submucosa.

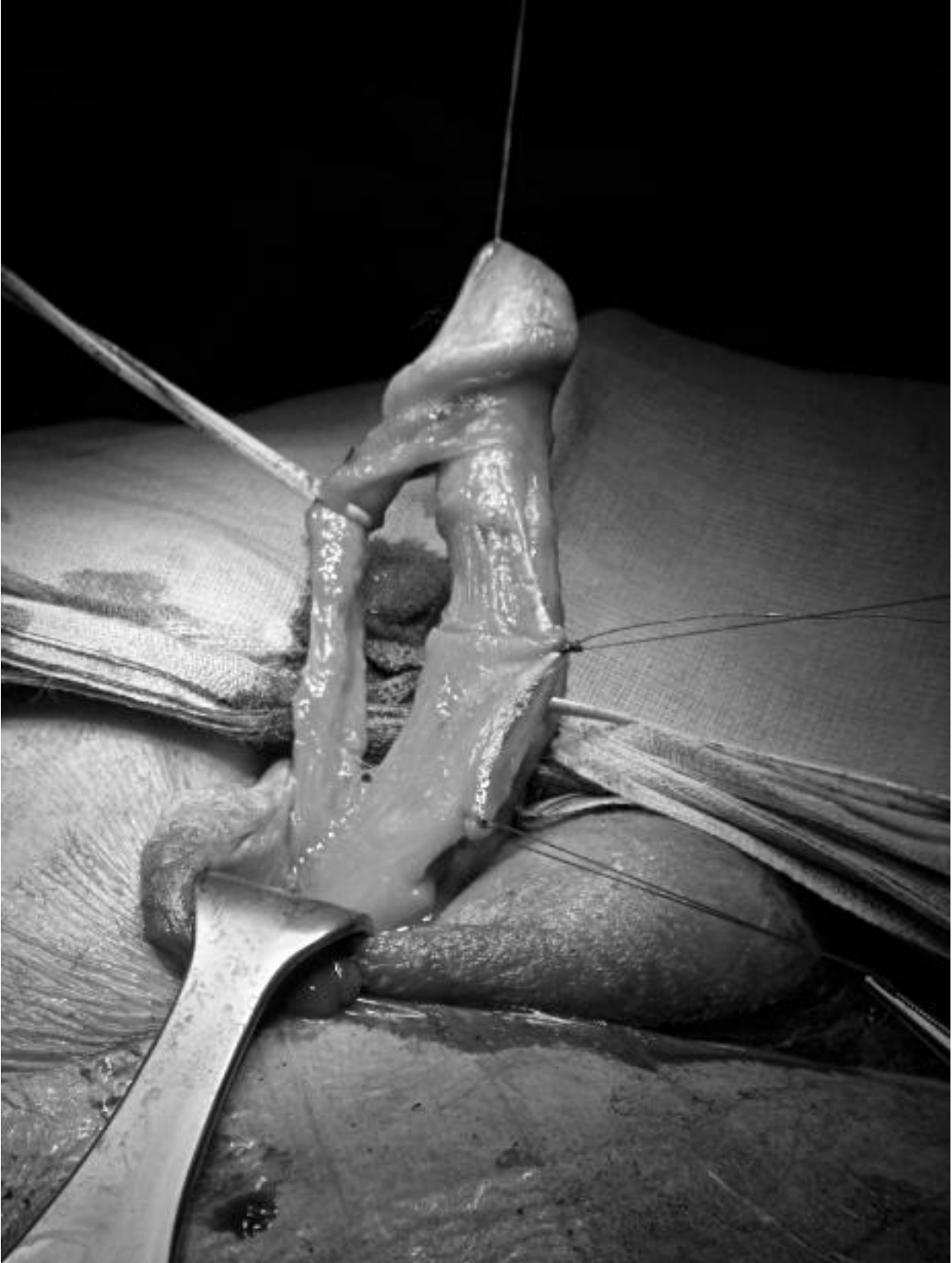

Figure 4.

Lateral intraoperative view of the penis: the stretching of the penis shows two defects of tunica albuginea, one on the dorsal side and the other on the ventral one; the neurovascular bundle reaches the maximum extension.

Main Outcome Measures

We evaluated postoperative penile lengthening, intraoperative and postoperative complications, patient's preoperative and postoperative sexual life satisfaction (International Index of Erectile Function [IIEF] questionnaire) [22].

Results

The average operative time was 2 hours and 50 minutes. No major intraoperative nor postoperative complications occurred. No significant bleedings were recorded. Patients were discharged after 48–72 hours.

The increase in length obtained in patients 1, 2, and 3 was 4, 2.5, and 3 cm, respectively. All patients resumed sexual intercourses with satisfaction; no significant loss of sensitivity nor any sign of vascular distress of the glans was recorded. The follow-up is 13 months. The IIEF questionnaire was completed by the three patients preoperatively, and 3.6 and 12 months postoperatively. The average score passed from 24 preoperative baseline (including both erectile function and satisfaction domain) to 44 at 3 months, 50 at 6 months, and finally 60 at 12 months. No complications were recorded.

Discussion

Peyronie's disease refers to acquired penile deformities during erection such as curvature, indentation, hour-glass effect or shortening. The curvature of the penis is the most frequent one, and sometimes, in the case of a major deformity, it can lead to the impossibility to have sexual intercourses.

Many therapeutic solutions have been proposed for severe curvature in Peyronie's disease.

Penile curvatures can be corrected through Nesbit technique [12–15] or through plaque surgery [5–11].

The surgical technique proposed by Nesbit in 1993 consists in an albuginea plication on the longer side of the corpora cavernosa associated to a small albuginea excision. This procedure leads to the straightening but results also in a significant shortening of the phallus [12].

Many procedures based on plaque surgery have been proposed by different authors.

In 1974, Horton and Devine devised a procedure using a dermal skin graft after excision of the Peyronie's plaque to fill the corporal defect. The success of this procedure has been widely reported and adequate patient selection produces excellent results in most of these patients [23].

Lue proposed in 1998 an H-shaped tunica albuginea incision on the plaque in order to release the contracture with a venous path graft [24].

Egydio suggested a plaque surgery characterized by plaque section with the application of geometrical principles to define the precise site and size of tunica albuginea incision and grafting procedure [5].

Shaeer suggested a trans-corporal incision, a minimally invasive endoscopic approach for plaque incision from within the corpora cavernosa, restoring straightness and length to the penis, before calibration of the corpora cavernosa, allowing implantation of a longer prosthesis in a straight penis, with neither mobilizing the neurovascular bundle nor a secondary incision [11]. Finally, Austoni suggested a soft prosthesis implant and relaxing albugineal incision with saphenous grafting with very high rates of patient satisfaction [25].

In some patients, the fibrous plaque is extensive and involves the whole circumference of the penis, and the septum results in penile shortening rather than angulation during erection [20].

Several therapeutic solutions have been proposed for severe penile shortening without major curvature in Peyronie's disease.

Stretching of the penis, with special external medical extenders, can lead in some cases to a moderate extension.

Levine and Gontero have recently raised the use of a new medical device, developed for the treatment of Peyronie's disease, utilizing controlled periodic stretching of the penis. The device works by holding the penis in a cradle and subjecting it to gentle stretching, the tension being provided by small metal extensions that are added to the cradle frame to provide traction against internal springs [16,17].

Among the surgical procedures, Alter proposed the division of suspensory ligament that provides a lengthening of the free portion of the shaft. But while this procedure can give a useful additional benefit in terms of shaft lengthening if associated with other surgical procedures, it does not provide any satisfactory result if it is performed as a single procedure [26]. Recently, Li reported that the division of the penile suspensory ligament may increase penile length, but usually does not lead to a degree that satisfies the patient [18].

A little gain in patients undergoing prosthetic surgery can be achieved using a variable geometry prosthesis (AMS 700 LGX). This three-piece inflatable implant is characterized by expandable cylinders, and it can lead up to 2 cm length expansion [27]. Nevertheless, one should note that the use of these kind of prostheses is safe only in patients with retraction but without curvature, because when the implant is activated in a bended shaft there is a risk of aneurysm and/or fissuration of the corpus cavernosum and even of the extrusion of the prosthesis on the convex side of the curvature. L. Subrini thought up the implantation of a temporary intra-cavernous expander ("Apollo") to be changed by a definitive prosthetic implant, after a satisfactory enhancement has been achieved; this solution is applicable also in the presence of an axial deviation and usually provides good results, but requires a good compliance of the patient and requires a second procedure to place the definitive prosthesis [21].

Many authors described lengthening techniques based on relaxing incision of albuginea in patients affected by Peyronie's disease without a major curvature of the penis.

Rigaud proposed, in patients with inadequate preoperative rigidity and severe penile shortening, to fit the corpora cavernosa with an appropriately sized nonlengthening inflatable prosthesis. Multiple bilateral transverse incisions on the tunica albuginea were then performed to lengthen the penis. A rear tip extender was then added to the prosthesis after lengthening to ensure proper fit. The corporal defect was left uncovered, and the penile skin was pulled back over the shaft [19].

Montorsi experienced a multiple relaxing incision of the tunica albuginea and subsequently positioning a three-piece inflatable penile implant with a 3 cm gain in length [28].

Rigaud, in 1995, proposed, after the insertion of an appropriately sized prosthesis, to perform a circular incision of the tunica albuginea around the penis, including the septum, which allowed the distal shaft to be thereby telescoped forward. Rear tip extenders were then added onto the prosthesis to ensure proper fit. The corporal defect was then covered with polytetrafluoroethylene patch [19].

T.F. Lue evaluated the results of chronic intermittent stretching with a vacuum erection device after the same circumferential tunical incision and circular venous grafting with satisfactory results [20].

Sansalone et al. have recently evaluated the results of a circumferential tunical incision during penile prosthesis implantation in patients with Peyronie's disease and severe penile shortening in a multicenter prospective study with high satisfactory results (29).

Our double dorsal-ventral patch graft procedure ("sliding technique"), compared with the division of the suspensory ligament, which changes the relationship between the free part and fixed part of the penis, provides a real lengthening of the corpora cavernosa.

The multiple incision technique has the advantage of extending the corpora cavernosa but reduces the diameter and the girth of the penis [19,28].

When a 360° circular incision is performed, a gentle traction can result in a significant lengthening of the penis, until the neurovascular bundle reaches a state of tension [19,20]. According to our experience, every procedure performed after a complete circular incision of the tunica albuginea can be dangerous, providing a stressing axial traction on the neurovascular bundle and the urethra.

Our proposed “sliding technique” combines the effectiveness of “classic” circular incision in terms of length gain with a higher safety level, because the sutures early placed on the two transverse incision (Figure 1B) allow to stabilize the structure of the penis at the maximal obtainable length, thus the dilatation of the corpora cavernosa and the insertion of the prosthesis can be performed without the risk of dangerous longitudinal traction on the neurovascular bundle and the urethra. Moreover, it is not necessary to make further corporotomies for the dilatation of the corpora cavernosa to insert the prosthetic cylinders, as this is easily done through the semicircular proximal incision. The suture of the two grafts that are prepared and placed with the usual technique adopted in plaque surgery is extremely easy. Furthermore, no major preoperative nor postoperative complications were detected in our study. Finally, no loss of sensibility nor ischemic lesions of the glans were detected, thanks to the safe axial tension exerted on the neurovascular bundle during the sliding of the penis.

Conclusions

Our “sliding technique” is an innovative procedure that is based on current techniques of plaque incision and grafting and that can easily resolve severe shortening of the penis due to Peyronie's disease. In the three cases presented, this procedure resulted easily, effectively, and safely. Nevertheless, the technique proposed in this article is characterized by a significant dissection of the penis and an important incision of the tunica albuginea. Therefore, in order to analyze the possible risk of glans ischemia and penile prosthesis distal erosion, the safety of this procedure shall be validated through prospective studies with larger samples.

References

1. Smith JF, Walsh TJ, Lue TF. Peyronie's disease: A critical appraisal of current diagnosis and treatment. *Int J Impot Res* 2008;20:445–59.
2. Briganti A, Salonia A, Deho F, Zanni G, Rokkas K, Rigatti P, Montorsi F. Peyronie's disease: A review. *Curr Opin Urol* 2003;13:417–22.
3. Hellstrom WJG. Medical management of Peyronie's disease. *J Androl* 2009;30:397–405.
4. Montorsi F, Adaikan G, Becher E, Giuliano F, Khoury S, Lue TF, Sharlip I, Althof SE, Andersson KE, Brock G, Broderick G, Burnett A, Buvat J, Dean J, Donatucci C, Eardley I, Fugl-Meyer KS, Goldstein I, Hackett G, Hatzichristou D, Hellstrom W, Incrocci L, Jackson G, Kadioglu A, Levine L, Lewis RW, Maggi M, McCabe M, McMahon CG, Montague D, Montorsi P, Mulhall J, Pfaus J, Porst H, Ralph D, Rosen R, Rowland D, Sadeghi-Nejad H, Shabsigh R, Stief C, Vardi Y, Wallen K, Wasserman M. Summary of the recommendations on sexual dysfunctions in men. *J Sex Med* 2010;7:3572–88.
5. Egydio PH, Sansalone S. Peyronie's reconstruction for maximum length and girth gain: Geometrical principles. *Adv Urol* 2008:205739. Epub 2008 Dec 3. doi: 10.1155/2008/205739.
6. Brant WO, Bella AJ, Garcia MM. Correction of Peyronie's disease: Plaque incision and grafting. *BJU Int* 2006;97:1353–60.
7. Ralph D, Gonzalez-Cadavid N, Mirone V, Perovic S, Sohn M, Usta M, Levine L. The management of Peyronie's disease: Evidence-based 2010 guidelines. *J Sex Med* 2010;7:2359–74.
8. Levine LA. Partial plaque excision and grafting (PEG) for Peyronie's disease. *J Sex Med* 2011;8:1842–5.
9. Flores S, Choi J, Alex B, Mulhall JP. Erectile dysfunction after plaque incision and grafting: Short-term assessment of incidence and predictors. *J Sex Med* 2011;8:2031–7.
10. Chung E, Clendinning E, Lessard L, Brock G. Five-year follow-up of Peyronie's graft surgery: Outcomes and patient satisfaction. *J Sex Med* 2011;8:594–600.
11. Shaer O. Trans-corporal incision of Peyronie's plaque. *J Sex Med* 2011;8:589–93.
12. Nesbit RM. Congenital curvature of the phallus: Report of three cases with description of corrective operation. *J Urol* 1965;93:230–2.
13. Yachia D. Modified corporoplasty for the treatment of penile curvature. *J Urol* 1990;143:80–2.
14. Rolle L, Tamagnone A, Timpano M, Destefanis P, Fiori C, Ceruti C, Fontana D. The Nesbit operation for penile curvature: An easy and effective technical modification. *J Urol* 2005;173:171–3.

15. Langston JP, Carson CC. Peyronie disease: Plication or grafting. *Urol Clin North Am* 2011;38:207–16.
16. Levine LA, Newell MM. FastSize™ Medical Extender for the treatment of Peyronie's disease. *Expert Rev Med Devices* 2008;5:305–10.
17. Gontero P, Di Marco M, Giubilei G, Pappagallo G, Tizzani A, Mondaini N. Use of penile extender device in the treatment of penile curvature as a result of Peyronie's disease. Results of a phase II prospective study. *J Sex Med* 2009;6:558–66.
18. Li CY, Kayes O, Kell PD, Christopher N, Minhas S, Ralph DJ. Penile suspensory ligament division for penile augmentation: Indications and results. *Eur Urol* 2006;49:729–33.
19. Rigaud G, Berger RE. Corrective procedures for penile shortening due to Peyronie's disease. *J Urol* 1995;153:368–70.
20. Lue TF, El-Sakka AI. Lengthening shortened penis caused by Peyronie's disease using circular venous grafting and daily stretching with a vacuum erection device. *J Urol* 1999;161:1141–4.
21. Rolle L, Ceruti C, Tamagnone A, Fontana D. The “Apollo” tissue expander: A novel approach to penile shortening due to fibrosis. *Sexologies* 2008;17(suppl 1):S88.
22. Rosen RC, Riley A, Wagner G, Osterloh IH, Kirkpatrick J, Mishra A. The international index of erectile function (IIEF): A multidimensional scale for assessment of erectile dysfunction. *Urology* 1997;49:822–30.
23. Devine CJ Jr, Horton CE. Surgical treatment of Peyronie's disease with dermal graft. *J Urol* 1974;111:44–6.
24. Lue TF, El-Sakka AI. Venous patch graft for Peyronie's disease. Part I: Technique. *J Urol* 1998;160(6 Pt 1):2047–9.
25. Austoni E, Colombo F, Romanò AL, Guarneri A, Kartalas Goumas I, Cazzaniga A. Soft prosthesis implant and relaxing albugineal incision with saphenous grafting for surgical therapy of Peyronie's disease: A 5-year experience and long-term follow-up on 145 operated patients. *Eur Urol* 2005;47:223–9.
26. Alter GJ. Augmentation phalloplasty. *Urol Clin North Am* 1995;22:887–902.
27. Montorsi F, Rigatti P, Carmignani G, Corbu C, Campo B, Ordesi G, Breda G, Silvestre P, Giammusso B, Morgia G, Graziottin A. AMS three-piece inflatable implants for erectile dysfunction: A long-term multi-institutional study in 200 consecutive patients. *Eur Urol* 2000;37:50–5.
28. Montorsi F, Salonia A, Maga T, Colombo R, Cestari A, Guazzoni G, Rigatti P. Reconfiguration of the severely fibrotic penis with a penile implant. *J Urol* 2001;166:1782–6.

29. Sansalone S, Garaffa G, Djinovic R, Egydio P, Vespasiani G, Miano R, Loreto C, Ralph DJ. Simultaneous penile lengthening and penile prosthesis implantation in patients with Peyronie's disease, refractory erectile dysfunction, and severe penile shortening. *J Sex Med* 2012;9:316–21.