



## UNIVERSITÀ DEGLI STUDI DI TORINO

This is an author version of the contribution published on:

Piccoli GB, Attini R, Vigotti FN, Naretto C, Fassio F, Randone O, Restagno G, Todros T, Roccatello D.

Nemo syndrome (incontinentia pigmenti) and systemic lupus erythematosus:  
a new disease association.

LUPUS (2012) 21

DOI: 10.1177/0961203311433140

The definitive version is available at:

<http://lup.sagepub.com/cgi/doi/10.1177/0961203311433140>

## **NEMO syndrome (incontinentia pigmenti) and systemic lupus erythematosus: A new disease association.**

GB Piccoli<sup>1</sup>, R Attini<sup>2</sup>, FN Vigotti<sup>1</sup>, C Naretto<sup>3</sup>, F Fassio<sup>1</sup>, O Randone<sup>1</sup>, G Restagno<sup>4</sup>, T Todros<sup>2</sup> and D Roccatello<sup>3</sup>

<sup>1</sup> Nephrology Unit, Department of Clinical and Biological Sciences, San Luigi Hospital, Orbassano, University of Turin, Turin, Italy;

<sup>2</sup> Materno-Foetal Medicine Unit, Sant'Anna Hospital, University of Turin, Turin, Italy;

<sup>3</sup> Department of Genetics, Sant'Anna Hospital, University of Turin, Turin, Italy;

<sup>4</sup> CMID, Centre for rare diseases, University of Turin, Turin Italy.

### **Correspondence to:**

Giorgina Barbara Piccoli, MD, Nephrology Unit, San Luigi Hospital, University of Turin, Regione Gonzole 10, Orbassano, Torino, Italy

Email: gbpiccoli@yahoo.it or giorgina.piccoli@unito.it

### **Conflict of interest statement**

The authors declare no conflicts of interest in preparing this article.

**Key words:** incontinentia pigmenti; lupus nephropathy; multiple malformations; NEMO syndrome; pregnancy; systemic lupus erythematosus

### **Abstract**

Congenital diseases are increasingly being recognised in adults because of clinical mimicry, variable clinical picture or rarity of the disease; pregnancy is a valuable diagnostic occasion. The present case is the first report of an association report between NEMO syndrome (an acronym of the mutated, non-functioning gene, NF- $\kappa$ B essential modulator), a rare X-linked disease, characterised by developmental anomalies, immunodepression and skin lesions, and systemic lupus erythematosus (SLE). A 35-year-old patient affected by SLE sought clinical advice in the 8th week of gestation. The diagnosis of SLE dated back to the age of 24, when multisystemic manifestations (pleuropericarditis, weight loss, alopecia, skin involvement, joint pain, kidney involvement) were observed. She had been treated with steroids since 1999; immunosuppressive drugs had been added for short periods. Developmental anomalies were present, including oligodontia, retinal problems, anomalies of the corpus callosum and pes planovalgus. Family history included multiple miscarriages, dental malformations and oligodontia and skin blistering in the first months of life. On these bases, incontinentia pigmenti (IP; or NEMO syndrome) was diagnosed and confirmed by genetic testing. The NEMO gene is implicated in immune deficiencies as well as in autoimmune diseases. This report may suggest a role for NF- $\kappa$ B essential modulator in the pathogenesis of SLE, in the context of the complex immunologic deficiencies increasingly associated with autoimmune diseases.

## Introduction

The increased life expectancy of patients affected by multisystemic diseases and the growing awareness of the importance of genetic syndromes have increased the occasions in which genetic diseases are encountered in adults.<sup>1,2</sup> In non-typical presentations, or in new associations, diagnosis may escape until adulthood, as is exemplified by the present case. This paper reports the association between incontinentia pigmenti (IP; also called NEMO syndrome, an acronym of the involved gene: NF- $\kappa$ B essential modulator), and systemic lupus erythematosus (SLE), in a patient referred to an outpatient clinic dedicated to pregnancy in kidney diseases. NEMO syndrome is an X-linked multisystemic disorder affecting the skin, teeth, nails, hair and the central nervous system. The disease has protean manifestations and variable expressivity. Its predominant form is generally lethal to males in utero (80% of cases: deletion that removes exons 4 through 10 of the NEMO gene); thus adult patients are mainly females. A history of recurrent miscarriages is frequently observed.<sup>3-5</sup> Once considered a rare genodermatosis, associated with neurological impairment, NEMO syndrome has recently been defined as a primary immunodeficiency with immune and non-immune manifestations.<sup>6</sup> The immunodeficiency is particularly severe in surviving males who are usually affected by rare types of NEMO mutations that differ from the more common deletion.<sup>7-11</sup>

The nuclear factor kappa-B (NF- $\kappa$ B) is a family of transcription factors found in virtually all cell types. It plays a key role in the response to a variety of pathogens and different types of cancer, and is implied in the development of autoimmune diseases, being central to both innate and adaptive immune response.<sup>12,13</sup> The system is intricate and complex, and is mainly regulated by a multimeric IkappaB kinase (IKK) complex made up of two catalytic subunits, called inhibitors of kappa kinase alpha and beta (IKK alpha and IKK beta) and of a regulatory unit (IKK gamma), also called NF- $\kappa$ B essential modulator, or NEMO.<sup>12,13</sup> Among its functions, IKK phosphorylates I $\kappa$ B proteins, thus allowing the release and nuclear translocation of NF- $\kappa$ B which can then act as a transcription factor. There are at least three different genetic diseases with both X-linked and autosomal inheritance that impair the functioning of the system; NEMO syndrome is probably the best-characterised disease in the NF- $\kappa$ B pathway.<sup>8,14</sup> Indeed, recent clinical data have been published reporting the involvement of the NEMO syndrome in inflammatory and autoimmune diseases, including atypical enterocolitis, Behc, et's syndrome and rheumatoid arthritis.<sup>6,15-17</sup> This is, to the best of the authors' knowledge, the first report of an association between NEMO syndrome and SLE.

## Case report

A 35-year-old female patient affected by SLE with chronic kidney disease was referred to our multidisciplinary unit for pregnancy and CKD in the 8th week of gestation. She is a strong-willed, intelligent and lively young woman, who ironically started reporting her clinical story by saying, 'I'm a collection of diseases'. She was born post-term (41st week). Dystocic birth and birth trauma were reported and were initially considered the cause of both pyramidal left hemi-syndrome with seizures and of brachial palsy, which were evident shortly after birth. In retrospect, however, these two diseases are presumably due to the genetic syndrome and not to the traumatic event. She also presented dysmorphic hands (Figure 1) and pes planovalgus, for which she later underwent surgery (left Achilles tendon extension and realignment of the left knee extensors). As of the first weeks of life she presented with skin blistering and lesions that healed, although with hyperpigmentation, which progressively improved after the 6th month of life, and disappeared after the first year of life. Mild growth delay, frequent infections and agenesis of permanent dentition were also present (Figure 2). Partial agenesis of the corpus callosum (Figure 3) and an arachnoid cyst were diagnosed at age 4, following severe seizures that occurred in the context of a febrile illness (Figure 3). Family history reveals that the patient's mother had had multiple miscarriages (six miscarriages

of male fetuses). She has two living children, a daughter (the patient described herein) and a son in good health who is 2 years younger. She also had dental malformations and reported skin blistering in infancy. The patient's grandmother had dental malformations and hypodontia, and had given birth to five children (two females with oligodontia and dental malformations). Miscarriages were also reported in the great-grandmother (four miscarriages). The full pedigree is reported in Figure 4. In 1999 (at age 24) SLE was diagnosed in the context of a clinical picture of pleuropericarditis, severe arthralgia, most likely worsened by the presence of the skeletal malformations mentioned above, fever and anemia. At diagnosis of SLE, photosensibilisation and dyschromic areas were evident (Figure 5a, b). The main biochemical data at diagnosis were: anti-dsDNA 150–200 IU/ml (normal: < 10 IU/ml), whose titres remained persistently elevated over the following 5 years, high antinuclear antibodies (1/640 at diagnosis and during follow-up), low complement levels (C3 60 mg/dl; normal: 80–185 mg/dl; C4 10 mg/dl; normal 15–45 mg/dl at diagnosis). Serum electrophoresis and immunoglobulin levels were normal and Coomb's test was negative. Lupus-like anticoagulant (LLAC) was positive at diagnosis and was occasionally positive over the following years. Clinical remission was obtained by administering oral steroids (1 mg/kg/day with rapid tapering to 0.5 mg/kg/day, and subsequently to 0.25 mg/kg/day), while all attempts to add immunosuppressive or immunomodulating drugs were unsuccessful, mainly because of various side effects (leukopenia with azathioprine; severe infections and neurological toxicity on cyclosporine A, including brucellosis and respiratory infections; gastrointestinal intolerance with hydroxychloroquine). In 2007, the patient developed recurrent urinary tract infections, for which she underwent a first renal evaluation. Moderate renal functional impairment (serum creatine [sCr] 1 mg/dl with estimated glomerular filtration rate [eGFR] 60 ml/min) with microhematuria and low-grade proteinuria were found (proteinuria 0.3 g/day) in the context of clinical remission on prednisone 15 mg/day with negative anti-dsDNA antibodies. Two years later, in January 2009, upon referral to the Materno-foetal Medicine Unit dedicated to kidney diseases, in her 8th week of pregnancy, proteinuria was 0.8–1 g/day, sCr was 1 mg/dL, microhematuria was present, creatinine clearance was 60 ml/min. The patient was being treated with prednisone alone (15 mg/day). Following miscarriage in February 2009, the patient underwent an extensive clinical re-evaluation. On account of the clinical and family history, genetic consultation was carried out and a diagnosis of NEMO syndrome was suspected, which was later confirmed by genetic testing (NEMO gene (Xq28): deletion of exons 4–10 in heterozygosity; test performed at the Genetic Laboratory of the Hospital Necker, Paris). Following extensive questioning, the patient's mother reported that her daughter had been diagnosed with IP which had been completely overlooked thereafter. Our patient's skin lesions were thus re-evaluated and typical hypopigmented striae, along with papular lesions were found. These lesions correspond to the adult phase of IP or NEMO syndrome (Figures 5 and 6). Since the patient wanted to attempt another pregnancy, a kidney biopsy was performed in the context of the extensive re-evaluation. It revealed 18 glomeruli, including 5 with global ischaemic sclerosis, while the remainder were normal. Mild interstitial fibrosis with areas of tubular atrophy, as well as normal small vessels and intimal fibrosis in one medium sized arteriole were present. Immunohistochemistry staining was negative. Owing to the histological picture and to the lack of major signs of immunological reactivity (negative anti-dsDNA antibodies, normal complement level, negative LLAC, no anaemia), the patient restarted low-dose hydroxychloroquine in order to progressively decrease the steroid dose. She is presently in clinical and laboratory remission on prednisone 5–7.5 mg/day, and hydroxychloroquine 100–200 mg on alternate days. After extensive genetic counselling, she decided to attempt a new pregnancy.

## Discussion

The case reported herein may be of interest for both clinical and pathophysiological reasons. From the clinical point of view, it exemplifies why a complex congenital syndrome may escape diagnosis up to

adulthood: clinical mimicry, not taking genetic diseases into consideration in adults, and the over-specialised habit of analysing diseases of different organs and apparatuses separately. The opportunity to reassess our patient's diagnosis presented itself when she became pregnant: she presented the main features both of NEMO syndrome and of SLE (serositis, arthritis, positive autoantibodies, including dsDNA antibodies, antinuclear factor and LLAC).<sup>18,19</sup> The presence of skin lesions averted attention from the underlying genetic disease, while calling attention to SLE. However, in NEMO syndrome the lesions develop through four phases starting in early childhood: blistering, wart-like rash, swirling macular hyperpigmentation and linear hypopigmentation, while alopecia is typically at the vertex, unlike the typical 'lupus hair' (Figures 5a, b).<sup>3-5,18,19</sup> Likewise, a history of recurrent miscarriages may be shared by both diseases, even though miscarriages in patients with NEMO syndrome are typically of male foetuses (Figures 5a, b). Furthermore, the patient's dystocic birth averted attention from the genetic origin of the seizures and of the peripheral palsy since they were ascribed to hypoxia and birth trauma.<sup>3-5,18</sup> Frequent infections were present in the patient's history prior to the development of SLE. Again, sensitivity to infections may be a sign of a predisposition to SLE and is common in NEMO patients in whom non-typical pathogens, including mycobacteria and other intracellular bacteria, are often observed (our patient had a history of Brucella infection).<sup>3-6</sup> The patient also presented with at least two elements that do not overlap with SLE, i.e. complex dental anomalies (present in up to 80% of patients with NEMO) and seizures in infancy (dysgenesis of the corpus callosum, typical of NEMO syndrome). These manifestations were the initial clues for reevaluating her history, pointing to a genetic origin of the clinical picture. The derangement of the immune response is the second point of interest: this is, to the best of the authors' knowledge, the first report of an association of SLE and NEMO syndrome. The affected gene is the NEMO/IKK $\gamma$  essential regulator, which is central to both innate and adaptive immune responses to a variety of pathogens; this should point towards immunodeficiency more than to an increase in immune response. Indeed, both common and rare infections are frequently observed in children.<sup>3-5</sup> The relationship with the development of autoimmune diseases has two main facets: the generic hypothesis which states that repeated infective challenges may trigger the immune response, a mechanism that has long been postulated in SLE, and the more specific hypothesis regarding the role of the NF- $\kappa$ B complex in starting and blunting the immune response.<sup>6,15,20-23</sup> In fact, inhibition of NF- $\kappa$ B during the resolution of inflammation was found to prolong inflammatory response and to inhibit apoptosis. NF- $\kappa$ B plays a role in cancer in maintaining the immunosuppressive phenotype of tumour-associated macrophages.<sup>23</sup> An apparently paradoxical anti-inflammatory role was described in sepsis, together with a pro-apoptotic effect of the NF- $\kappa$ B complex in neutrophils. Prolonged pharmacological inhibition of IKK $\beta$  augments IL-1 $\beta$  secretion upon endotoxin challenge. Thus, a note of caution was recently published regarding long-term IKK $\beta$  inhibition that could, in contrast, induce persistence of inflammation.<sup>22</sup> These observations are in agreement with the development of autoimmunity in patients with NEMO mutations.<sup>6,16,17</sup> Thus, while no general law can be drawn by a single case, our report supports the importance of chronic NEMO inhibition in the development of complex immunological diseases, of which SLE is often considered the prototype, and calls for further attention to the risk of autoimmune diseases in patients with IP or NEMO syndrome.

## Conclusion

Increased awareness of the importance of rare genetic diseases should encourage the search for a common origin and a genetic nature in the case of an association between malformations and immunological derangement in young patients, as in the case of uncommon infections in childhood. Our case, which reports an association between NEMO syndrome and SLE, may highlight the importance of the NF- $\kappa$ B complex in down-regulating the immune response.

## Acknowledgement

This paper is dedicated to Virginia, for her patience, endurance and sense of humour.

## Funding

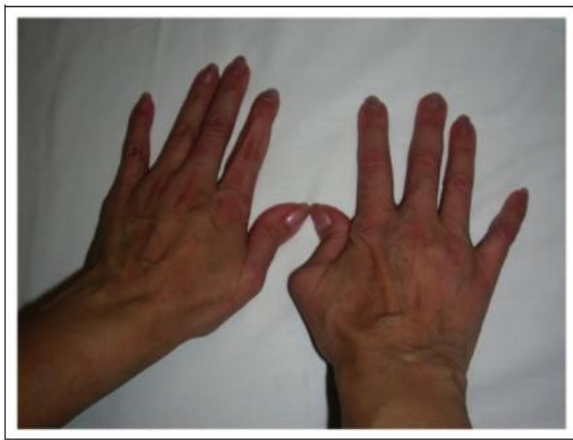This research received no specific grant from any funding agency in the public, commercial, or notfor-profit sectors.

## References

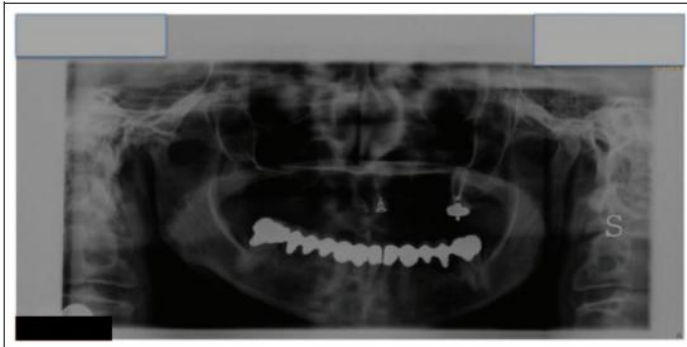
- 1 Hildebrandt F. Genetic kidney diseases. *Lancet* 2010; 375: 1287–1295.
- 2 Drawz PE, Sedor JR. Translating associations between common kidney diseases and genetic variation into the clinic. *Semin Nephrol* 2010; 30: 195–202.
- 3 Scheuerle A, Nelson DL. Incontinentia Pigmenti. In: Pagon RA, Bird TC, Dolan CR, Stephens K (eds), *GeneReviews*, Seattle, WA: University of Washington, Seattle, June 2008.
- 4 Ehrenreich M, Tarlow MM, Godlewska-Janusz E, Schwartz RA. Incontinentia pigmenti (Bloch–Sulzberger syndrome): a systemic disorder. *Cutis* 2007; 79: 355–362.
- 5 Hadj-Rabia S, Froidevaux D, Bodak N, et al. Clinical Study of 40 cases of incontinentia pigmenti. *Arch Dermatol* 2003; 139: 1163–1170.
- 6 Cheng LE, Kanwar B, Tcheurekdjian H, et al. Persistent systemic inflammation and atypical enterocolitis in patients with NEMO syndrome. *Clin Immunol* 2009; 132: 124–131.
- 7 Doeffinger R, Smahi A, Bessia C, et al. X-linked anhidrotic ectodermal dysplasia with immunodeficiency is caused by impaired NF-kappaB signaling. *Nat Genet* 2001; 27: 277–285.
- 8 Orange JS, Jain A, Ballas ZK, Schneider LC, Geha RS, Bonilla FA. The presentation and natural history of immunodeficiency caused by nuclear factor kappaB essential modulator mutation. *J Allergy Clin Immunol* 2004; 113: 725–733.
- 9 Mancini AJ, Lawley LP, Uzel G. X-linked ectodermal dysplasia with immunodeficiency caused by NEMO mutation: early recognition and diagnosis. *Arch Dermatol* 2008; 144: 342–346.
- 10 Permaul P, Narla A, Hornick JL, Pai SY. Allogeneic hematopoietic stem cell transplantation for X-linked ectodermal dysplasia and immunodeficiency: case report and review of outcomes. *Immunol Res* 2009; 44: 89–98.
- 11 Ardlean D, Pope E. Incontinentia pigmenti in boys: a series and review of the literature. *Pediatr Dermatol* 2006; 23: 523–527.
- 12 Karin M, Ben-Neriah Y. Phosphorylation meets ubiquitination: the control of NF-kB activity. *Annu Rev Immunol* 2000; 18: 621–663.
- 13 Li Q, Verma IM. NF-kappaB regulation in the immune system. *Nat Rev Immunol* 2002; 2: 725–734.
- 14 Puel A, Picard C, Ku CL, Smahi A, Casanova JL. Inherited disorders of NF-kappaB-mediated immunity in man. *Curr Opin Immunol* 2004; 16: 34–41.
- 15 Sanz AB, Sanchez-Nin˜o MD, Ramos AM, et al. NF-kappaB in renal inflammation. *J Am Soc Nephrol* 2010; 21: 1254–1262.
- 16 Takada H, Nomura A, Ishimura M, Ichiyama M, Ohga S, Hara T. NEMO mutation as a cause of familial occurrence of Behc, et’s disease in female patients. *Clin Genet* 2010; 78: 575-579, DOI: 10.1111/j.1399-0004.2010.01432.x.
- 17 Brown KD, Claudio E, Siebenlist U. The roles of the classical and alternative nuclear factor-kappaB pathways: potential implications for autoimmunity and rheumatoid arthritis. *Arthritis Res Ther* 2008; 10: 212.
- 18 Hochberg MC. Updating the American College of Rheumatology revised criteria for the classification of systemic lupus erythematosus. *Arthritis Rheum* 1997; 40: 1725.

- 19 Petri M. Review of classification criteria for systemic lupus erythematosus. *Rheum Dis Clin North Am* 2005; 31: 245–254, vi.
- 20 Lawrence T, Gilroy DW, Colville Nash PR, Willoughby DA. Possible role of NF kappa B in the resolution of inflammation. *Nat Med* 2001; 7: 1291–1297.
- 21 Lawrence T, Fong C. The resolution of inflammation. Anti-inflammatory roles for NF kappaB. *Int J Biochem Cell Biol* 2010; 42: 519–524.
- 22 Greten FR, Arkan MC, Bollrath J, et al. NF-[kappa]B is a negative regulator of IL-1[beta] secretion as revealed by genetic and pharmacological inhibition of IKK[beta]. *Cell* 2007; 130: 918–931.
- 23 Hagemann T, Lawrence T, McNeish I, et al. “Re-educating” tumor-associated macrophages by targeting NF-{kappa}B. *J Exp Med* 2008; 205: 1261–1268.

**Figure 1** The patient’s hands.



**Figure 2** Hypodontia.



**Figure 3** Partial agenesis of the corpus callosum.

