

IRIS A_{per}TO



UNIVERSITÀ
DEGLI STUDI
DI TORINO

This is the author's final version of the contribution published as:

Mozzati M; Arata V; Gallesio G; Mussano F; Carossa S.. Immediate Postextractive Dental Implant Placement with Immediate Loading on Four Implants for Mandibular-Full-Arch Rehabilitation: A Retrospective Analysis.. CLINICAL IMPLANT DENTISTRY AND RELATED RESEARCH. 15 (3) pp: 332-340.
DOI: 10.1111/j.1708-8208.2011.00412.x

The publisher's version is available at:
<http://doi.wiley.com/10.1111/j.1708-8208.2011.00412.x>

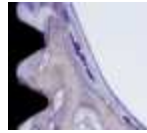
When citing, please refer to the published version.

Link to this full text:
<http://hdl.handle.net/2318/115585>

This full text was downloaded from iris - AperTO: <https://iris.unito.it/>

iris - AperTO

University of Turin's Institutional Research Information System and Open Access Institutional Repository



CLINICAL IMPLANT DENTISTRY and Related Research

Immediate post-extractive dental implant placement with immediate loading on four implants for mandibular-full-arch rehabilitation: a retrospective analysis.

Journal:	<i>Clinical Implant Dentistry and Related Research</i>
Manuscript ID:	CID-10-544.R4
Manuscript Type:	Original Article
Date Submitted by the Author:	n/a
Complete List of Authors:	Mozzati, Marco; San Giovanni Battista Hospital, Dental School Arata, Valentina; San Giovanni Battista Hospital, Dental School Gallesio, Giorgia; San Giovanni Battista Hospital, Dental School Mussano, Federico; Università di Torino, Scienze Biomediche ed Oncologia Umana, Dental School Carossa, Stefano; Università di Torino, Scienze Biomediche ed Oncologia Umana, Dental School
Keywords:	immediate loading, full-arch prosthesis, dental implants

1
2
3 **Immediate post-extractive dental implant placement with immediate loading on four implants**
4
5 **for mandibular-full-arch rehabilitation: a retrospective analysis.**
6
7
8
9

10
11
12 Mozzati Marco¹, DDS; Arata Valentina¹, DDS; Gallesio Giorgia¹, DDS; Mussano Federico^{1,2},
13
14 PhD; Carossa Stefano^{1,2}, DDS.
15
16
17

18
19 1. Dental School, San Giovanni Battista Hospital Molinette, Turin, Italy
20

21 2. Department of Biomedical Sciences and Human Oncology, Università di Torino, Turin, Italy
22
23
24
25
26
27
28
29
30

31 **Running title:** Immediate loading of immediate post-extractive dental implants for full arch
32 rehabilitations
33
34

35 Corresponding author:
36

37 Stefano Carossa
38

39 via Nizza 230
40

41 10126 Turin, Italy
42

43 Tel: +39 0116708362
44

45 Fax: +39 0116705655
46

47 e-mail: stefano.carossa@unito.it
48
49
50
51
52
53
54
55
56
57
58
59
60

ABSTRACT

Background: To date, only few studies have reported on the clinical outcomes of immediate post-extraction implant placement and immediate loading.

Purpose: The purpose of this retrospective study was to report the results of immediately loading of four implants placed in fresh extraction sockets in the mandible after a follow-up of 24 months.

Materials and Methods: Between January 2001 and January 2009, 50 patients (28 women and 22 men, average age 54 years) had 347 teeth extracted and a total of 200 dental implants placed in the mandible. The patients received a provisional fixed bridge the same day and a permanent one 3 months later. Clinical check-ups were performed after 1, 2, 3, 6, 12 and 24 months. Marginal bone measurements were made in intraoral radiographs taken one day after surgery and after one year. A questionnaire was used to evaluate self-perceived factors related to comfort, aesthetics and function.

Results: All bridges were stable and no implant failures were recorded during the follow-up, giving a survival rate of 100%, at two years. The marginal bone loss amounted to 1.33 ± 0.36 mm after one year and 1.48 ± 0.39 mm after two years. Ten patients showed prosthetic complications with the provisional bridge, but all the definitive prostheses remained stable throughout the study period without any complications. The patients reported satisfaction with the treatment.

Conclusions: The present retrospective study showed that immediate loading of four implants immediately placed in extraction sockets is a valid treatment modality for the totally edentulous mandible.

INTRODUCTION

Due to a better understanding of biological and biomechanical features together with the notable progress in dental implant morphology and surface characteristics, immediate loading has become an attractive alternative to conventionally loaded implants¹. Despite the fact that numerous studies on immediate, or early loading have been published^{1,2,3}, over the last few years^{4,5,6,7}, scientific literature contains several different definitions and evaluation criteria as to the *immediate loading* concept. Indeed, authors refer to immediate loading even when dealing with a 20⁸ or even 30-day period⁹ between surgery and actual loading. In the fourth ITI Consensus Conference, *immediate loading* was defined as a prosthesis that is placed in occlusion with the opposing dentition within 48 hours of implant placement¹⁰.

The concept of immediate loading was first applied to the loading of multiple implants in both the maxilla and mandible¹¹ for full arch restorations^{11,12,13,14}, with predictable results. Currently, the survival rates for implants subjected to immediate loading in mature mandible bone vary between 80% and 100%^{15,16,17,18,19}. However, most of the studies published on immediate loading in the mandible have examined mature bone in edentulous patients^{5,8,17,20,21,22}. As only a few studies, with a limited number of patients^{6,7,23}, have described immediate loading of post-extractive immediate implants, no definitive evidence has yet been provided on survival rate.

Among these studies, Peñarrocha²³ reported a 100% survival rate in eleven patients treated with immediate full-arch implants. Only two randomized controlled clinical trials compared immediate versus delayed implants^{24,25}: when prosthesis and implant failures were analyzed no statistical significant difference was found between the two types of implant loading. Thanks to immediate full-arch loading of the jaw, partially edentulous patients need no longer to wear a conventional removable denture during the osseointegration waiting period (2-3 months) and the time required to make their definitive prostheses (2-4 months)^{26,27,28}, resulting in an improvement in both comfort and function, during the implant healing period.

1
2
3 The purpose of this retrospective study was to report the results of immediately loading of
4
5 four implants placed in fresh extraction sockets in the mandible after a follow-up of two years.
6
7
8
9
10
11
12
13
14
15
16
17
18
19
20
21
22
23
24
25
26
27
28
29
30
31
32
33
34
35
36
37
38
39
40
41
42
43
44
45
46
47
48
49
50
51
52
53
54
55
56
57
58
59
60

For Review Only

1
2
3
4
5
6
7
8
9
10
11
12
13
14
15
16
17
18
19
20
21
22
23
24
25
26
27
28
29
30
31
32
33
34
35
36
37
38
39
40
41
42
43
44
45
46
47
48
49
50
51
52
53
54
55
56
57
58
59
60

MATERIALS AND METHODS

Patients

The study included 50 patients, 28 females and 22 males, average age 54.3 years (range, 45-65), with partially edentulous mandibles in need of tooth extractions due to severe periodontal disease and/or caries. The patients had been treated by one surgeon between January 2001 and January 2009 according to an immediate loading protocol using four implants and delivery of a fixed bridge the same day. The local ethical committee approved the study protocol. All subjects included in the study gave written informed consent to the treatment and agreed to be available for follow-up clinical visits including postoperative radiographs all of which was carefully detailed.

Inclusion criteria

- age > 18 years;
- partially edentulous mandible requiring extraction of the remaining teeth;
- minimum bone height of 10 mm in the interforaminal area and 8.5 mm in the distal area with a minimum bone width of 4 mm;
- insertion torque value of ≥ 30 Ncm.

Exclusion criteria.

- Any systemic or local disease or condition (haematologic diseases, uncontrolled diabetes, serious coagulopathies, history of intravenous therapy with bisphosphonates and/or diseases of the immune system) that preclude an oral surgical intervention,
- immunosuppression,
- current corticosteroid use,
- pregnancy,
- irradiation to the head or neck region within 12 months before surgery,
- severe parafunctional habits,

- a poor bone quantity (Type IV),
- more than 10 cigarettes per day,
- poor oral hygiene.

Pre- and post-surgical preparation

The pre-surgical evaluation included clinical examinations and Orthopantomograms (OPT) and Computed Tomography Scans (CTs). Prior to surgery the patients underwent debridement and root scaling. The patients received 1 g of amoxicillin and clavulanic acid (Augmentin, Roche S.p.A., Milan, Italy) every 8 hours from the day before surgery to the sixth post-surgical day. Oral rinses with chlorhexidine digluconate 0.2% mouthwash (Curasepts, Curaden HealthCare s.r.l., Saronno, Italy) were prescribed starting 3 days before surgery, followed by 7 daily post-surgical sessions.

Surgical procedure

Surgery was performed under local anesthesia with articaine chlorhydrate at 4% and epinephrine 1:100,000 (Alfacaina N, Weimer Pharma, Rastat, Germany). The tooth extractions were done using a piezoelectric device to preserve bone tissue (Mectron Piezosurgery® Device, Mectron Medical Technology, Carasco, Italy). The extraction sockets were thoroughly and carefully cleaned and left empty. Any granulation tissue present was removed. A periodontal probe was used to verify the integrity of the fresh socket bony walls. A crestal incision was made from the first molar region to the contralateral side. After which a full-thickness flap was raised to enhance the visibility of the surgical field. The dental implant sites and depth were identified along with the ideal angulations as dictated by a surgical guide in transparent heat-cured acrylic resin. After mucoperiosteal flap reflection and identification of the mental foramina, of paramount importance for positioning the tilted implant in a distal position, bone remodeling was performed. Post-

1
2
3 extractive sockets were treated so as to ensure oxygenation by Piezosurgery® during the
4
5 osteoplasty^{29,30}. The length of the mental nerve loop and the shape of the bone were gently assessed
6
7
8 by a round-tip probe to determine the ideal angulations of the posterior implants after bone ridge
9
10 preparation. Implant site preparation was adapted to bone quality to obtain sufficient primary
11
12 implant stability. Bone density was assessed by the clinician during the early phase of drilling and
13
14 scored according to the Lekholm and Zarb classification³¹. The implant sites were underprepared, to
15
16 obtain the best possible implant stability. A torque controller (Osseocare®, Nobel Biocare AB) with
17
18 a torque limit of 50Ncm was used during implant placement. A manual wrench was also used when
19
20 incomplete fixture seating occurred³². All patients received four implants (Brånemark System®
21
22 MKIII or NobelSpeedy™ Groovy, Nobel Biocare AB, Göteborg, Sweden). Firstly, the distal tilted
23
24 fixture was placed. The drill was inserted crestally in correspondence to the first molar and tilted
25
26 about 30° to the occlusal plane over the alveolar nerve foramen. The mesial fixtures were then
27
28 inserted. The implants were placed 1mm under the buccal level of the alveolar crest to improve
29
30 their primary stability. To facilitate gap closure between implants and the surrounding bone, any
31
32 bone defects larger than 2mm were filled with an injectable nanocrystalline paste (Ostim®, Osartis,
33
34 Obernburg, Germany)³³. The same bone graft material was used to treat any fenestrations resulting
35
36 from the implant insertion.
37
38
39
40
41
42

43
44 Abutments (MUA®, Nobel Biocare AB) were connected to the implants. Abutments with an
45
46 inclination of 30° relative to the fixture axis were placed onto the distal fixtures to allow for an
47
48 optimal prosthetic screw access. Standard 1mm or 2mm high MUA, or abutments with 17° of
49
50 inclination when necessary, were placed onto mesial fixtures. A torque controller (Osseocare®,
51
52 Nobel Biocare AB) was used to tighten tilted abutment screws at 20Ncm and standard abutment
53
54 screws at 30Ncm. Piezosurgery® was used to remodel the bone ridge around the emergence of the
55
56 implants to allow for the multi-units to be screwed on.
57
58
59
60

1
2
3 A total of 347 teeth were extracted and 200 implants (20 NobelSpeedy™ Groovy, 4 mm in
4 diameter, 180 Brånemark System® MKIII), 3.75 mm in diameter were placed according to an
5 immediate loading protocol between January 2001 and January 2009 (Fig.1A-C). Implant lengths
6 ranged from 13 to 18mm depending on the bone height available and were placed with a torque of
7 $\geq 30\text{Ncm}$ (Fig.2A). One hundred and twenty-one implants were placed directly in post-extraction
8 sockets, while 79 were placed into healed edentulous sites.
9
10
11
12
13
14
15
16

17
18 After positioning the temporary 15 mm high titanium prosthesis cylinders (Nobel Biocare
19 AB) (Fig.2B), the soft tissues were gently adapted to the abutments and sutured with a 4-0
20 resorbable suture (Vicryl, Johnson & Johnson Intl., St Stevens, Woluwe, Belgium). Sutures were
21 removed at 14 post-operative days (Fig.2C). An impression of the implant position was made with
22 the aid of a light-curing acrylic resin (Triad® Gel, Densply Trubyte) following the implant surgery
23 to connect the temporary titanium prosthesis cylinders to the impression tray. Polyether elastomeric
24 material was used to take the soft tissue impression. The occlusion was checked and the impression
25 removed. Lastly, healing caps were placed onto the multi-unit abutments and left in place
26 throughout the provisional restoration waiting period.
27
28
29
30
31
32
33
34
35
36
37
38
39
40
41

42 **Prosthetic procedure**

43
44 A 12-unit provisional bridge was manufactured in the dental laboratory. The acrylic
45 provisional prostheses were delivered within three hours after surgery (Fig.2D). A cast metal bar
46 was included in the resin whenever needed, to prevent fracture of provisional restorations. The
47 cantilevers were eliminated to minimize fracture risk and excessive stress over the distal implants.
48 The prostheses had acrylic occlusal surfaces with narrow platforms and flat cusps; the occlusal
49 contact was light, while centric and lateral contacts were limited to the intercanine zone. The
50 patients were also instructed to eat only soft food for the first month and were given instructions for
51
52
53
54
55
56
57
58
59
60

1
2
3 correct oral hygiene, including the use of toothbrushes and flossing technique. The definitive
4
5
6 prostheses were made starting three months after surgery (Fig.2E, F).
7
8
9

10 11 12 13 14 **Survival criteria**

15
16 Implant and prosthesis survival were evaluated in this study. The definition of implant
17
18 survival was based on the clinical and radiologic criteria of Albrektsson and colleagues³⁴:
19

- 20
21 1) absence of clinically detectable implant mobility;
- 22
23 2) no evidence of peri-implant radiolucency;
- 24
25 3) radiographic vertical bone loss less than 0.2 mm per annum;
- 26
27 4) absence of pain, infections, neuropathy or paresthesia;
- 28
29
30
31
32
33
34
35
36

37 **Clinical follow-up**

38
39 Weekly post-operative check-ups were made during the first post-surgical month to evaluate
40
41 tissue healing and prosthesis function; wounds were examined at 14 days and sutures removed.
42
43 Further visits were scheduled at 1, 2, 3, 6 and 12 months and every 6 months thereafter when
44
45 implant and prosthesis stability as well as occlusion was checked.
46
47
48

49 A questionnaire was used to evaluate self-perceived factors related to comfort, aesthetics
50
51 and function.
52
53
54
55
56

57 **Radiographic follow-up**

58
59 OPTs (Orthophos, Sirona, Bensheim, Germany; at 69-71 kV and 15 mA for 14.2 s) and,
60
when necessary, standardized periapical intraoral films (Oralix 65 S, Gendex Dental Systems S.r.l.,

1
2
3 Milano, Italy) were taken preoperatively, within 1 day after surgery (baseline) and also at 1, 3 and 6
4 months post surgery and 1 and 2 years after final prosthesis delivery (Fig.3A-J). Periapical films
5 were used to evaluate the marginal bone-level. Particular attention was paid so as to position the
6 radiographic film parallel to the implant and to align the X-ray beam perpendicular to the implant
7 axis, thus obtaining an optimal, minimally distorted image of the implant threads. The image size
8 was standardized at 750 d.p.i. with a resulting size on average of 1890×1220 pixels at 8 bytes per
9 plane and 256 values of gray. Two independent examiners (M.M. and G.G.) measured the distance
10 in 0.1 mm increments between the implant shoulder, as the reference point, and the most coronal
11 bone to implant contact mesially and distally of the implants. The known distance between three
12 implant threads was used for calibration purpose and to determine the image magnification. If there
13 was a differences superior to 0.5 mm, then the radiographs were re-examined by both examiners
14 and the results discussed until arriving at a consensus, according to previous protocols³⁵.
15
16
17
18
19
20
21
22
23
24
25
26
27
28
29
30
31
32
33
34
35
36
37
38
39
40
41
42
43
44
45
46
47
48
49
50
51
52
53
54
55
56
57
58
59
60

1
2
3
4
5
6
7
8
9
10
11
12
13
14
15
16
17
18
19
20
21
22
23
24
25
26
27
28
29
30
31
32
33
34
35
36
37
38
39
40
41
42
43
44
45
46
47
48
49
50
51
52
53
54
55
56
57
58
59
60

RESULTS

Apart from expected post-operative swelling and pain, there were no other immediate postsurgical complications. Loosening of the 30° angled multi-units was observed in five patients, most likely due to occlusal overload. Consequently, the abutments were fixed and the prosthesis cylinder reattached directly in the oral cavity with resin. There was a fracture in the provisional screw-retained fixed bridges in another five patients, probably due to the small quantity of acrylic resin. Therefore, a total of ten patients showed complications while wearing the provisional fixed prostheses.

All permanent bridges and implants remained stable of the 24 months follow-up period, giving a survival rate of 100% for bridges and implants. The marginal bone level measured 0.54 ± 0.28 mm baseline (200 periapical intraoral films, one per implant) and 1.87 ± 0.48 mm after one year (200 periapical intraoral films, one per implant). The marginal bone loss (Table 1) after one year (Fig.4) amounted to 1.33 ± 0.36 and 1.48 ± 0.39 mm after two years. The data from the questionnaire showed high satisfaction with the treatment, in particular with eating comfort, aesthetics and phonetics.

DISCUSSION

This retrospective study aimed at evaluating the possibility to rehabilitate completely edentulous mandibles by immediate loading of post-extractive immediate implants. As poor bone quality and limited bone quantity often hinder the rehabilitation of the mandibular posterior region with axial implants, tilted implants have frequently been used to improve bone anchorage³⁶. Malò et al demonstrated the efficacy of this technique in 2003, by proposing a protocol for edentulous mandibles called “all-on-4”²⁰. This protocol makes use of four dental implants: two in the anterior part of the mandible and two in the posterior part. The two posterior implants are tilted to reduce the extensions (cantilever) of the fixed prostheses. The mandibles of 44 patients were rehabilitated by a total of 176 immediately loaded dental implants: the survival rate was 98.2% at 12 months²⁰.

Our study reported an implant and prostheses survival rate of 100%, which is consistent with previous retrospective^{13,20} and prospective single cohort studies^{37,38,39,40,41}. Thus, the survival rate of implants placed in fresh extraction sites equal to that of implants placed into healed edentulous sites. It should be remarked that one prerequisite for this immediate loading protocol was high initial implant stability as the implants were placed with an insertion torque of ≥ 30 Ncm. Indeed, adequate primary implant stability is a fundamental requisite for immediate loading^{42,43}. Traditionally, implant stability is achieved by osseointegration during a period of undisturbed healing, while primary stability is achieved immediately via mechanical fixation. Implant surface characteristics are important⁴⁴ so as to obtain a successful bone healing and therefore a long term implant stability (secondary stability). The use of medium-rough surface implants may have contributed to the favorable results obtained in this study. TiUnite™ is a highly crystalline and phosphate enriched titanium oxide characterized by a microstructured surface with open pores in the low micrometer range⁴⁵. This implant surface has repeatedly proven to give a more rapid bone formation and greater amount of bone-to-implant contact compared to machined implant

1
2
3 surfaces^{46,47,48}. Also, when placed in soft bone and immediately loaded, TiUnite™ surfaces resulted
4
5 in higher success rates compared to machined implants.⁴⁹
6
7

8
9 Although the immediate implant loading technique avoids many of the traditional implant
10 surgery drawbacks i.e. healing stages and the use of temporary prostheses, it is prone to other types
11 of possible complications, prosthesis fracture being one of the most common. The fact that the
12 temporary fixed prostheses have to be made and loaded during the surgical session increases the
13 number of variables that may lead to problems, i.e. mis-fit and fracture. However, if properly
14 handled by careful planning and standardized procedures, problems can be avoided. The incidence
15 of fractures of the acrylic prostheses in the present study (10% of the total cases) is consistent with
16 that reported in literature^{38,39,40}.
17
18
19
20
21
22
23
24
25
26
27
28
29
30
31
32
33
34
35
36
37
38
39
40
41
42
43
44
45
46
47
48
49
50
51
52
53
54
55
56
57
58
59
60

CONCLUSIONS

In conclusion, the present study showed successful results when using an immediate loading/immediate post-extractive placement protocol for full-arch rehabilitation of completely or partially edentulous mandibles. The technique eliminates the use of a temporary removable prosthesis and reduces treatment times in implant cases where multiple extractions are necessary.

For Review Only

REFERENCES

- [1] Nkenke E, Fenner M. Indications for immediate loading of implants and implant survival. *Clin Oral Implants Res* 2006; 17 Suppl 2: 19-34.
- [2] Malò P, Nobre Mde A, Petersson U, Wigren S. A pilot study of complete edentulous rehabilitation with immediate function using a new implant design: case series. *Clin Implant Dent Relat Res* 2006; 8: 223-232.
- [3] Glauser R, Lundgren AK, Gottlow J, Sennerby L, Portmann M, Ruhstaller P, Hammerle CH. Immediate occlusal loading of Brånemark TiUnite implants placed predominantly in soft bone: 1-year results of a prospective clinical study. *Clin Implant Dent Relat Res* 2003; 5 Suppl 1: 47-56.
- [4] Vanden Bogaerde L, Pedretti G, Dellacasa P, Mozzati M, Rangert B. Early function of splinted implants in maxillas and posterior mandibles using Brånemark System® machined-surface implants: an 18-month prospective clinical multicenter study. *Clin Implant Dent Relat Res* 2003; 5 Suppl 1: 21-28.
- [5] Vanden Bogaerde L, Pedretti G, Dellacasa P, Mozzati M, Rangert B, Wendelhag I. Early function of splinted implants in maxillas and posterior mandibles, using Brånemark System® Tiunite implants: an 18-month prospective clinical multicenter study. *Clin Implant Dent Relat Res* 2004; 6: 121-129.
- [6] Villa R, Rangert B. Immediate and early function of implants placed in extraction sockets of maxillary infected teeth: a pilot study. *J Prosthet Dent*. 2007;97: S96-S108.
- [7] Villa R, Rangert B. Early loading of interforaminal implants immediately installed after extraction of teeth presenting endodontic and periodontal lesions. *Clin Implant Dent Relat Res*. 2005;7:S28-35.
- [8] Randow K, Ericsson I, Nilner K, Petersson A, Glantz PO. Immediate functional loading of Brånemark dental implants. An 18-month clinical follow-up study. *Clin Oral Implants Res* 1999; 10: 8-15.

- 1
2
3 [9] Cooper LF, Rahman A, Moriarty J, Chaffee N, Sacco D. Immediate mandibular
4 rehabilitation with endosseous implants: simultaneous extraction, implant placement, and loading.
5 Int J Oral Maxillofacial Implants 2002; 17: 517-525.
6
7
8
9
10 [10] Proceedings of the 4th International Team for Implantology (ITI) Consensus Conference,
11 August 2008, Stuttgart, Germany. Int J Oral Maxillofac Implants. 2009; 24 Suppl:7-278.
12
13
14
15 [11] Ibanez JC, Tahhan MJ, Zamar JA, Menendez AB, Juaneda AM, Zamar NJ, Monqaut JL.
16 Immediate occlusal loading of double acid-etched surface titanium implants in 41 consecutive full-
17 arch cases in the mandible and maxilla: 6- to 74-month results. J Periodontol 2005; 76: 1972-1981.
18
19
20
21
22 [12] Mozzati M, Monfrin SB, Pedretti G, Schierano G, Bassi F. Immediate loading of maxillary
23 fixed prostheses retained by zygomatic and conventional implants: 24-month preliminary data for a
24 series of clinical case reports. Int J Oral Maxillofacial Implants 2008; 23: 308-314.
25
26
27
28
29 [13] Pieri F, Aldini NN, Fini M, Corinaldesi G. Immediate occlusal loading of immediately
30 placed implants supporting fixed restorations in completely edentulous arches: a 1-year prospective
31 pilot study. J Periodontol 2009; 80: 411-421.
32
33
34
35
36 [14] Li W, Chow J, Hui E, Lee PK, Chow R. Retrospective study on immediate functional
37 loading of edentulous maxillas and mandibles with 690 implants, up to 71 months of follow-up. J
38 Oral Maxillofac Surg 2009; 67: 2653-2662.
39
40
41
42
43 [15] Morton D, Jaffin R, Weber HP. Immediate restoration and loading of dental implants:
44 clinical considerations and protocols. Int J Oral Maxillofacial Implants 2004; 19 Suppl: 103-108.
45
46
47
48
49 [16] Gallucci GO, Bernard JP, Bertosa M, Belser UC. Immediate loading with fixed screw-
50 retained provisional restorations in edentulous jaws: the pickup technique. Int J Oral Maxillofac
51 Implants 2004; 19: 524-533.
52
53
54
55
56
57
58
59
60

1
2
3
4
5
6
7
8
9
10
11
12
13
14
15
16
17
18
19
20
21
22
23
24
25
26
27
28
29
30
31
32
33
34
35
36
37
38
39
40
41
42
43
44
45
46
47
48
49
50
51
52
53
54
55
56
57
58
59
60

- [17] Ganeles J, Rosenberg MM, Holt RL, Reichman LH. Immediate loading of implants with fixed restorations in the completely edentulous mandible: report of 27 patients from a private practice. *Int J Oral Maxillofacial Implants* 2001; 16: 418-426.
- [18] Chiapasco M. Early and immediate restoration and loading of implants in completely edentulous patients. *Int J Oral Maxillofacial Implants* 2004; 19 Suppl: 76-91.
- [19] Castellon P, Blatz MB, Block MS, Finger IM, Rogers B. Immediate loading of dental implants in the edentulous mandible. *J Am Dent Assoc* 2004; 135: 1543-1549; quiz 1621-1542.
- [20] Malo P, Rangert B, Nobre M. "All-on-Four" immediate-function concept with Brånemark System implants for completely edentulous mandibles: a retrospective clinical study. *Clin Implant Dent Relat Res* 2003; 5 Suppl 1: 2-9.
- [21] Glauser R, Ree A, Lundgren A, Gottlow J, Hammerle CH, Scharer P. Immediate occlusal loading of Brånemark implants applied in various jawbone regions: a prospective, 1-year clinical study. *Clin Implant Dent Relat Res* 2001; 3: 204-213.
- [22] Van de Velde T, Collaert B, De Bruyn H. Immediate loading in the completely edentulous mandible: technical procedure and clinical results up to 3 years of functional loading. *Clin Oral Implants Res* 2007; 18: 295-303.
- [23] Peñarrocha M, Boronat A, Garcia B. Immediate loading of immediate mandibular implants with a full-arch fixed prosthesis: a preliminary study. *J Oral Maxillofac Surg* 2009; 67: 1286-1293.
- [24] Lindeboom JA, Tjiook Y, Kroon FH. Immediate placement of implants in periapical infected sites: a prospective randomized study in 50 patients. *Oral Surgery, Oral Medicine, Oral Pathology, Oral Radiology, and Endodontics* 2006;101:705–10.
- [25] Block MS, Mercante DE, Lirette D, Mohamed W, Ryser M, Castellon P. Prospective evaluation of immediate and delayed provisional single tooth restorations. *Journal of Oral and Maxillofacial Surgery* 2009;67(11 Suppl):89–107.

- 1
2
3 [26] Misch CM. Immediate loading of definitive implants in the edentulous mandible using a
4 fixed provisional prosthesis: The denture conversion technique. *J Oral Maxillofac Surg* 2004; 62:
5 106-115.
6
7
8
9
10 [27] Drago CJ, Lazzara RJ. Immediate occlusal loading of Osseotite implants in mandibular
11 edentulous patients: a prospective observational report with 18-month data. *J Prosthodont* 2006; 15:
12 187-19.
13
14
15
16
17 [28] Agliardi E, Panigatti S, Clerico M, Villa C, Malo P. Immediate rehabilitation of the
18 edentulous jaws with full fixed prostheses supported by four implants: interim results of a single
19 cohort prospective study. *Clin Oral Implants Res* 2010; 21: 459-465.
20
21
22
23
24 [29] Huber P, Debus J, Jöchle K, Simiantonakis I, Jenne J, Rastert R, Spoo J, Lorenz WJ,
25 Wannemacher M. Control of cavitation activity by different shockwave pulsing regimes. *Phys*
26 *Med Biol* 1999;44:1427-37.
27
28
29
30 [30] Clayman RV, Long S, Marcus M. High-energy shock waves: in vitro effects. *Am J Kidney*
31 *Dis* 1991;17:436-44.
32
33
34 [31] Lekholm U, Zarb G. Patient selection and preparation. In: Brånemark PI, Zarb G,
35 Albrektsson T. *Tissue-Integrated Prostheses: Osseointegration in Clinical Dentistry*. Chicago:
36 Quintessence, 1985: 199-209.
37
38
39 [32] Arvidson K, Esselin O, Felle-Persson E, Jonsson G, Smedberg JI, Soderstrom U. Early
40 loading of mandibular full-arch bridges screw retained after 1 week to four to five Monotype
41 implants: 3-year results from a prospective multicentre study. *Clin Oral Implants Res* 2008; 19:
42 693-703.
43
44
45 [33] Paolantonio M, Dolci M, Scarano A, d'Archivio D, di Placido G, Tumini V, Piattelli A.
46 Immediate implantation in fresh extraction sockets. A controlled clinical and histological study in
47 man. *J Periodontol* 2001; 72: 1560-1571.
48
49
50
51
52
53
54
55
56
57
58
59
60

1
2
3
4
5
6
7
8
9
10
11
12
13
14
15
16
17
18
19
20
21
22
23
24
25
26
27
28
29
30
31
32
33
34
35
36
37
38
39
40
41
42
43
44
45
46
47
48
49
50
51
52
53
54
55
56
57
58
59
60

- [34] Albrektsson T, Zarb G, Worthington P, Eriksson AR. The long-term efficacy of currently used dental implants: a review and proposed criteria of success. *Int J Oral Maxillofac Implants*. 1986;1:11-25.
- [35] Rodoni LR, Glauser R, Feloutzis A, Hämmerle CH. Implants in the posterior maxilla: a comparative clinical and radiologic study. *Int J Oral Maxillofacial Implants*. 2005; 20:231-237.
- [36] Weinstein R, Agliardi E, Fabbro MD, Romeo D, Francetti L. Immediate Rehabilitation of the Extremely Atrophic Mandible with Fixed Full-Prosthesis Supported by Four Implants. *Clin Implant Dent Relat Res* 2010 Feb 11. [Epub ahead of print].
- [37] Capelli M, Zuffetti F, Del Fabbro M, Testori T. Immediate rehabilitation of the completely edentulous jaw with fixed prostheses supported by either upright or tilted implants: a multicenter clinical study. *Int J Oral Maxillofac Implants* 2007; 22: 639-644.
- [38] Agliardi EL, Francetti L, Romeo D, Del Fabbro M. Immediate rehabilitation of the edentulous maxilla: preliminary results of a single-cohort prospective study. *Int J Oral Maxillofac Implants* 2009; 24: 887-895.
- [39] Agliardi EL, Francetti L, Romeo D, Taschieri S, Del Fabbro M. Immediate loading in the fully edentulous maxilla without bone grafting: the V-II-V technique. *Minerva Stomatol* 2008; 57: 251-259, 259-263.
- [40] Francetti L, Agliardi E, Testori T, Romeo D, Taschieri S, Fabbro MD. Immediate rehabilitation of the mandible with fixed full prosthesis supported by axial and tilted implants: interim results of a single cohort prospective study. *Clin Implant Dent Relat Res* 2008; 10: 255-263.
- [41] Testori T, Del Fabbro M, Capelli M, Zuffetti F, Francetti L, Weinstein RL. Immediate occlusal loading and tilted implants for the rehabilitation of the atrophic edentulous maxilla: 1-year interim results of a multicenter prospective study. *Clin Oral Implants Res* 2008; 19: 227-232.

- 1
2
3 [42] Szmukler-Moncler S, Piattelli A, Favero GA, Dubruille JH. Considerations preliminary to
4 the application of early and immediate loading protocols in dental implantology. Clin Oral Implants
5 Res 2000; 11: 12-25.
6
7
8
9
10 [43] Brunski JB. Biomechanical factors affecting the bone-dental implant interface. Clin Mater
11 1992; 10: 153-201.
12
13
14
15 [44] Mendonça G, Mendonça DBS, Aragão FJL, Cooper LF. Advancing dental implant surface
16 technology –from micron- to nanotopography. Biomaterials 2008; 29:3822-35.
17
18
19
20 [45] Hall J, Lausmaa J. Properties of a new porous oxide surface on titanium implants. Appl
21 Osseointegration Res 2000;1:5-8.
22
23
24
25 [46] Degidi M, Petrone G, Iezzi G, Piattelli A. Histologic evaluation of a human immediately
26 loaded titanium implant with a porous anodized surface. Clin Implant Dent Relat Res 2002;4:110-
27 114.
28
29
30
31
32 [47] Rocci A, Martignoni M, Burgos P, Gottlow J, Sennerby L. Histology of retrieved
33 immediately and early loaded oxidized implants. Light microscopic observations after 5 to 9 months
34 of loading in the posterior mandible of 5 cases. Clin Implant Dent Relat Res 2003;12:88-98.
35
36
37
38 [48] Schüpbach P, Glauser R, Rocci A, Martignoni M, Sennerby L, Lundgren AK, *et al.* The
39 human bone-oxidized titanium implant interface: a microscopic, scanning electron microscopic,
40 back-scatter electron microscopic, and energy-dispersive X-ray study of clinically retrieved
41 implants. Clin Implant Dent Relat Res 2005;7:36-43.
42
43
44
45 [49] Glauser R, Ruhstaller P, Windisch S, Zembic A, Lundgren AK, Gottlow J, *et al.*
46 Immediate occlusal loading of Brånemark System TiUnite implants placed in predominantly soft
47 bone: 4-year results of a prospective clinical study. Clin Implant Dent Relat Res 2005;7:52-59.
48
49
50
51
52
53
54
55
56
57
58
59
60

1
2
3
4
5
6
7
8
9
10
11
12
13
14
15
16
17
18
19
20
21
22
23
24
25
26
27
28
29
30
31
32
33
34
35
36
37
38
39
40
41
42
43
44
45
46
47
48
49
50
51
52
53
54
55
56
57
58
59
60

ACKNOWLEDGEMENTS

The Authors would like to thank Ms Barbara Wade for her linguistic advice.

For Review Only

1
2
3 **FIGURE LEGENDS**
4

5
6 **Figure 1.** Showing (A) the number of teeth extracted per patient, (B) types of axial implants and the
7
8 (C) types of tilted implants per patient.
9

10
11 **Figure 2.** Clinical photograph showing: (A) the placement of an implant in an extraction socket; (B)
12
13 four implants placed in extraction sockets with abutments and temporary titanium cylinders; (C)
14
15 sutures about to be removed at 14 post-operative days; (D) the provisional bridge connected to the
16
17 four implants; (E) the oral mucosa healing at 3 months; (F) the definitive prosthesis.
18
19

20
21 **Figure 3.** Orthopantomograms showing: (A) the preoperative condition of the patient; (B) the
22
23 patient at 3 months; (C) the patient at 1 year postoperative; (D) the follow-up visit at 2 years.
24
25 Periapical intraoral films showing: the implants placed in the third (E) and fourth quadrant (F)
26
27 immediately after surgery; the implants placed in the third (G) and fourth quadrant (H) one year
28
29 after surgery; the implants placed in the third (I) and fourth quadrant (J) two years after surgery.
30
31
32

33 **Figure 4.** Showing frequency distribution of the bone loss at one year.
34
35
36
37
38
39
40
41
42
43
44
45
46
47
48
49
50
51
52
53
54
55
56
57
58
59
60

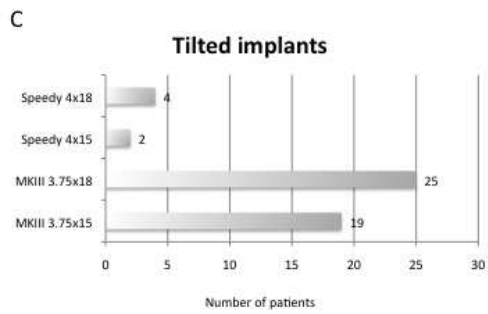
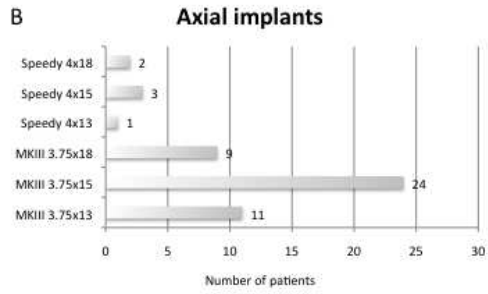
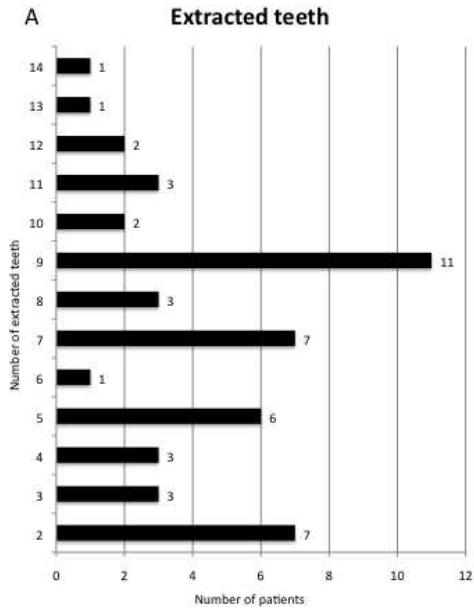
1
2
3
4
5
6
7
8
9
10
11
12
13
14
15
16
17
18
19
20
21
22
23
24
25
26
27
28
29
30
31
32
33
34
35
36
37
38
39
40
41
42
43
44
45
46
47
48
49
50
51
52
53
54
55
56
57
58
59
60

Table 1. Results from marginal bone measurements.

	Bone level mm \pm SD	Radiographs used for measurements
Marginal bone level, baseline	0.54 \pm 0.28	200
Marginal bone level, one year	1.87 \pm 0.48	200
Marginal bone level, two years	2.03 \pm 0.51	200
Bone loss baseline to one year	1.33 \pm 0.36	200
Bone loss baseline to two years	1.48 \pm 0.39	200

For Review Only

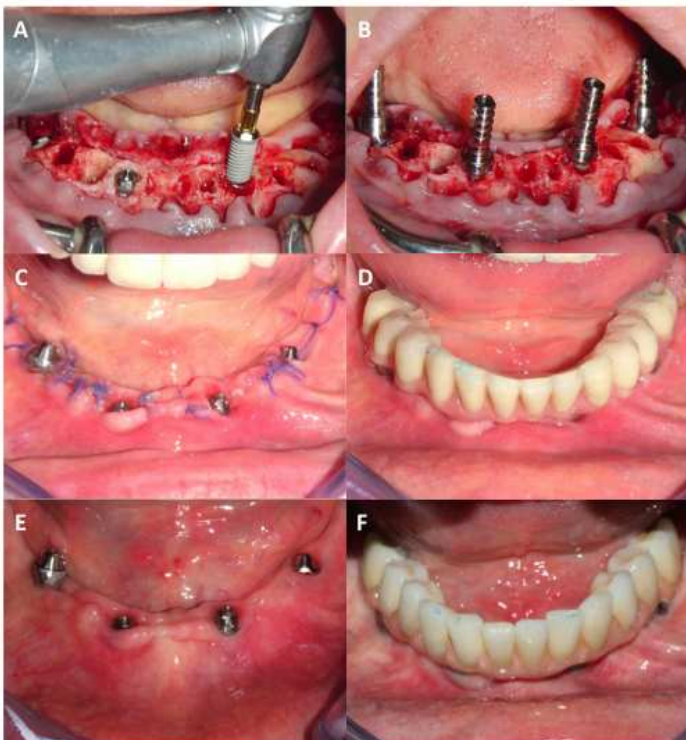
1
2
3
4
5
6
7
8
9
10
11
12
13
14
15
16
17
18
19
20
21
22
23
24
25
26
27
28
29
30
31
32
33
34
35
36
37
38
39
40
41
42
43
44
45
46
47
48
49
50
51
52
53
54
55
56
57
58
59
60



254x190mm (72 x 72 DPI)

View Only

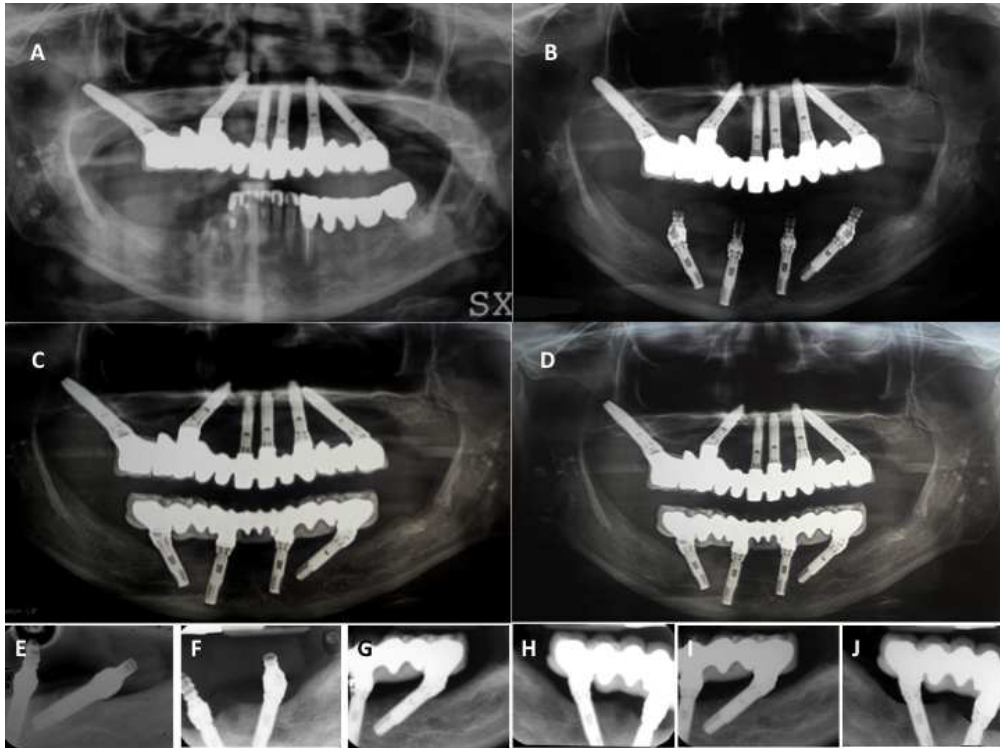
1
2
3
4
5
6
7
8
9
10
11
12
13
14
15
16
17
18
19
20
21
22
23
24
25
26
27
28
29
30
31
32
33
34
35
36
37
38
39
40
41
42
43
44
45
46
47
48
49
50
51
52
53
54
55
56
57
58
59
60



254x190mm (72 x 72 DPI)

View Only

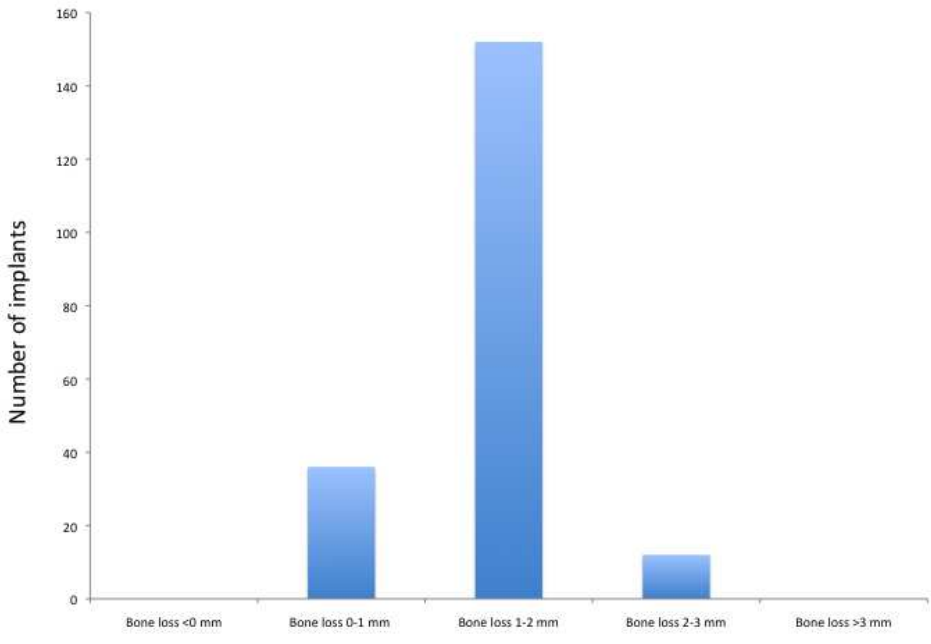
1
2
3
4
5
6
7
8
9
10
11
12
13
14
15
16
17
18
19
20
21
22
23
24
25
26
27
28
29
30
31
32
33
34
35
36
37
38
39
40
41
42
43
44
45
46
47
48
49
50
51
52
53
54
55
56
57
58
59
60



254x190mm (72 x 72 DPI)

View Only

1
2
3
4
5
6
7
8
9
10
11
12
13
14
15
16
17
18
19
20
21
22
23
24
25
26
27
28
29
30
31
32
33
34
35
36
37
38
39
40
41
42
43
44
45
46
47
48
49
50
51
52
53
54
55
56
57
58
59
60



254x190mm (72 x 72 DPI)

View Only