



# UNIVERSITÀ DEGLI STUDI DI TORINO

*This is an author version of the contribution published on:  
Questa è la versione dell'autore dell'opera:*

PARASITOLOGY RESEARCH  
**Volume:** 109, **Issue:** 3, **Pages:** 963-966, 2011, **DOI:** 10.1007/s00436-011-2375-7

*The definitive version is available at:  
La versione definitiva è disponibile alla URL:*  
<http://link.springer.com/journal/436>

# First report of *Obeliscoides cuniculi* in European brown hare (*Lepus europaeus*)

Paolo Tizzani • Arianna Menzano • Stefano Catalano Luca Rossi • Pier Giuseppe Meneguz

P. Tizzani, A. Menzano, S. Catalano, L. Rossi, P. G. Meneguz. Department of Animal Production, Epidemiology and Ecology, University of Turin, V. Leonardo da Vinci 44, 10095 Grugliasco, TO, Italy.

**Abstract** *Obeliscoides cuniculi* is a New World nematode parasite of the *Trichostrongylidae* family infecting the gastric tract of different domestic and wild Lagomorph species. This parasite is reported for the first time from a European brown hare (*Lepus europaeus*). The nematodes isolated from the gastro-intestinal tract were identified using the primary characteristics used to differentiate the species of this genus as adults morphology (length and thickness) and other characteristics of spicules, cervical papillae, cuticular ridges and striations. In the Italian study area, the European brown hare lives in sympatry with the eastern cottontail (*Sylvilagus floridanus*), species in which the nematode was previously isolated; therefore, the possibility of a cross-infestation must be considered.

The expansion of an animal or plant species out of its natural environment due to human intervention represents one of the greatest threats to bio-diversity (Simberloff et al. 2000). In some cases, the impact of the invasion by non-indigenous animal species on the environment is particularly severe for animal health, especially when mediated by the introduction of "new" pathogens (Stebbins 1992; Dobson 1996). A well-known example of this possibility is represented by the squirrel poxvirus, which played a clear role in the severe competition between the introduced invading grey squirrel (*Sciurus carolinensis*) and the native red squirrel (*Sciurus vulgaris*) in Europe (Sainsbury et al. 2008).

In Italy, one of the allochthonous invaders is the eastern cottontail (*Sylvilagus floridanus*) which was introduced illegally as game in France (1953), Italy (1966), Spain (1980) and Switzerland (1982). Northwest Italy is the only region, in Europe, where this rabbit has become naturalised (Spagnesi and Toso 1999) and is still expanding its distribution area (Spagnesi and Toso 1999; Silvano et al. 2000). In the plain and hills of this region, eastern cottontail populations have reached high densities, and in the areas of sympatry, have largely outnumbered the native European brown hare (*Lepus europaeus*) (Bertolino 2003). Presence of *S. floridanus* is an obvious matter of concern for conservation of *L. europaeus* since the potential exists for both ecological (Vidus-Rosin et al. 2010) and sanitary (Tizzani et al. 2002) competition between the two Leporids. Remarkably, four macroparasites so far exotic to the European parasitic fauna have been reported in eastern cottontails naturalised in Northwestern Italy: three are nematodes (*Obeliscoides cuniculi*, *Trichostrongylus calcaratus*, *Passalurus nonannulatus*) and one is a flea (*Euhoplopsyllus glacialis*) (Meneguz and Tizzani 2002).

In December 2009, an adult European brown hare found dead beside a road in the Alessandria Province (44°54' N; 8°37' E) was submitted to our Laboratory. It was a female in poor body condition, weighing only 952 g. The necropsy confirmed the traumatic origin of the death, probably due to collision with a vehicle. Serum was harvested and examined for EBHS (European Brown Hare Syndrome) and tularaemia, with negative results.

The digestive tract was opened longitudinally and all helminths were collected following examination of diluted aliquots of the content under a stereomicroscope (Georgi and Georgi 1990). Nematodes were fixed in 70% alcohol, then clarified in lactophenol for easier identification according to keys in Skrjabin et al. (1954). Measurements were taken of the spicules length and the reproductive tract of females was inspected for the presence of eggs. For comparison, the same measures were taken of 20 *O. cuniculi* specimens (10 males and 10 females) collected from four eastern cottontails of sympatric naturalised northwestern Italian population. These animals were part of a shooting plan made in January 2010 in the same area.

The aforementioned measures were also assumed as fitness parameters, according to Poulin (2007), that speak about life history strategies in nematodes: to a greater size of male reproductive organs and increased fertility in females corresponds a higher fitness of the parasite.

There were 59 specimens from the stomach and were red in color. Males ( $N=15$ ) were 9.6 to 11.7 mm long and 0.2 to 0.5 mm wide, whereas females ( $7V=44$ ) were 13.6 to 20.6 long and 0.3 to 0.5 mm wide. All were identified as adult *O. cuniculi* (Graybill 1924). In particular, body size, the length and shape of spicules, the absence of mouth cavity, the presence of neck papillae and the presence of longitudinal cuticular ridges and a fine transversal line pattern were consistent with the original

description (Graybill 1924). Male specimens had a bursa with two large lateral lobes, a small dorsal lobe and ventro-ventral rays diverging from the lateral ventral ones though reconverging at tips. Large externo-lateral rays extend separately from the other lateral ribs, which are smaller and closely approximated. The externodorsal ray, small and somewhat bent, is dorsally split into two branches, from each of which emerges a bifid tip. Spicules were  $567 \pm 29 \mu\text{m}$  long (median  $570 \mu\text{m}$ , range  $520\text{--}620 \mu\text{m}$ ,  $N=15$ ) distal end bifurcated, each bifurcation ends in a hook (Fig. 1). All females had eggs in the uterus. The vulva was located distally, in the posterior quarter of the body.

To the best of our knowledge, this is the first report of *O. cuniculi* in *L. europaeus*, and the first report of this helminth species in a native European host. In our samples we observed: (1) all females were pregnant, confirming that the hare is a competent host for the reproduction of *O. cuniculi*; (2) biometric measures of male reproductive organs (spicules) when compared with similar measurements obtained from a sample of *O. cuniculi* parasitizing *S. floridanus*, are significantly higher (Mann-Whitney  $U$  test  $-Z=-4.09$ ,  $p<0.05$ ), suggesting that fitness of *O. cuniculi* in *L. europaeus* is not at all compromised.

Other 60 nematodes (15 males and 45 females) were collected in the small intestine. They were identified as adult *Trichostrongylus retortaeformis* (Zeder 1800), which is typical in *L. europaeus* (Canestri-Trotti et al. 1988). No nematode was found in the large intestine.

The Trichostrongylid *O. cuniculi* is known to infect the stomach of a range of tame and wild (native and allochthonous) Lagomorphs in the New World, including the snowshoe hare *Lepus americanus* (MacLulich 1937; Gibbs et al. 1977; Measures and Anderson 1983), the Black-tailed jackrabbit *Lepus californicus* (Ward 1934), the eastern cottontail *S. floridanus* (Alicata 1932; Jacobson et al. 1978; Andrews and Davidson 1980; Wiggins et al. 1980; Measures and Anderson 1983), the Marsh rabbit *Sylvilagus palustris* (Tomkins 1935; Stringer et al. 1969), the Swamp rabbit *Sylvilagus aquaticus* (Ward 1934; Smith 1940) and the tame rabbit *Oryctolagus cuniculus* (Jensen et al. 1980). Occasionally, it has been signalled as a "capture" in rodents and ungulates, namely in *Marmota monax* (Twichell 1939; Rausch and Tiner 1946; Fleming et al. 1979; Measures and Anderson 1983) and *Odocoileus virginianus* (Maples and Jordan 1966; Prestwood et al. 1973).

In Europe, *O. cuniculi* was signalled for the first time at the turn of this century, as a dominant species in naturalised eastern cottontails in Italy (Meneguz and Tizzani 2002), and this invader is the obvious origin of the infection which is object of the present note. Notwithstanding, fitness parameters suggest that *O. cuniculi* found a favourable "niche" in the stomach of the examined *L. europaeus* and apparently became adapted to the new host. More hares from northwestern Italy will need to be surveyed to confirm if the present finding is an occasional "capture" as occur in Saulai and Cabaret (1998) for parasite nematodes of ruminants or the first evidence of the ongoing adaptation of an exotic nematode to a new native host. It is worth signalling that representatives of the genus *Lepus* are amongst the usual hosts of *O. cuniculi* in the New World (see above), and that the nematode has been reported in an African hare (*Lepus capensis*) introduced in the United States in sympatry with *L. americanus* (Measures and Anderson 1983).

The larger size of spicules and body size may even be evidence of increased fitness acquired by the nematode in the change of host and therefore its possible greater evolutionary success (Combes 1997; Poulin 2007).

The consequences of possible adaptation of *O. cuniculi* to the European brown hare are unknown. Tompkins and Begon (1999) reported a reduced survival in naturally infected snowshoe hares (*L. americanus*), and pathogenic effects (haemorrhagic gastritis, reduced weight gain, anaemia and scour) were demonstrated in experimentally infected tame rabbits (Solod et al. 1968). The stomach of *L. europaeus* is, *de facto*, a sort of "empty ecological niche" (Hudson and Greenman 1998), the only exception being the presence of the nematode, *Graphidium strigosum*, in hares sympatric with wild rabbits (*O. cuniculus*) (Boag 1987; Bordes et al. 2007). Though well tolerated by the original rabbit host, *G. strigosum* is associated with severe stomach lesions in hares (Broekhuizen and Kemmers 1976). In this particular multi-host model, apparent parasite-mediated competition (Holt 1977) to the detriment of hares has been postulated (Hudson and Greenman 1998). An interesting hypothesis to be tested is that *O. cuniculi* may play a similar role, favouring the spread of the eastern cottontail in the typical European brown hare biotopes.

## References

- Alicata JE (1932) Life history of the rabbit stomach worm, *Obeliscoides cuniculi*. J Agric Res 44:401-419.  
Andrews CL, Davidson WR (1980) Endoparasites of selected populations of cottontail rabbits (*Sylvilagus floridanus*)

in the southeastern United States. *J Wildl Dis* 16:395-401

Bertolino S (2003) Densità di Lepre (*Lepus europaeus*) e Silvilago (*Sylvilagus floridanus*) in ambienti pianiziali. *Hystrix* 14:110

Boag B (1987) The helminth parasites of the wild rabbit *Oryctolagus cuniculus* and the brown hare *Lepus capensis* from the Isle of Coll. *J Zool* 212:352-355

Bordes F, Langand J, Feliu C, Morand S (2007) Helminth communities of an introduced hare (*Lepus granatensis*) and a native hare (*Lepus europaeus*) in southern France. *J Wildl Dis* 43:747-751

Broekhuizen S, Kemmers R (1976) The stomach worm, *Graphidium strigosum* (Dujardin) Railliet and Henry, in the European Hare, *Lepus europaeus* Pallas. In: Pielowski Z, Pucek Z (eds) Ecology and Management of European Hare Populations, the proceedings of an international symposium, Poznan, December 23-24, 1974. Polish Hunting Association, Warsaw, pp 157—171

Canestri-Trotti G, Corradini L, Bassi S (1988) Osservazioni sulle elmintiasi gastro-intestinali di lepri delle province di Ferrara e Modena e lepri di importazione. *Proc I Conv Naz Biologi Selvaggina* 14:317-321

Combes C (1997) Fitness of parasites: pathology and selection, *Int J Parasitol* 27:1-10

Dobson AP (1996) Conservation and biodiversity. Scientific American Libraries, New York.

Fleming WJ, Georgi JR, Caslick JW (1979) Parasite of the woodchuck (*Marmota monax*) in Central New York State. *Proc Helminthol Soc Wash* 46:115-127.

Georgi JR, Georgi ME (1990) Parasitology for veterinarians. Saunders, Philadelphia

Gibbs HC, Crenshaw WJ, Mowatt M (1977) Seasonal changes in stomach worms (*Obeliscooides cuniculi*) in snowshoe hares in Maine. *J Wildl Dis* 13:327-332.

Graybill HW (1924) *Obeliscooides*, a new name for the nematode genus *Obeliscus*. *Parasitol* 16:317.

Holt RD (1977) Predation, apparent competition, and the structure of prey communities. *Theor Popul Biol* 12:197—229.

Hudson P, Greenman J (1998) Competition mediated by parasites: biological and theoretical progress. *Trends Ecol Evol* 13:387-390.

Jacobson HA, Kirkpatrick RL, McGinnes BS (1978) Disease and physiologic characteristics of two cottontail populations in Virginia. Washington, The Wildlife Society. *Wildl Monogr* 60:1-53.

Jensen LJ, Fox JG, Murphy JC, Shalev M (1980) Natural infection of *Obeliscooides cuniculi* in a domestic rabbit. *Lab Anim Sci* 30:231-233.

Mac Lulich DA (1937) Fluctuations in the numbers of the varvinghare (*Lepus americanus*). *Univ Toronto Studies, Biol Series* 43, pp 136.

Maples WP, Jordan HE (1966) A new host record for *Obeliscooides cuniculi*. *J Parasitol* 52:49.

Measures LN, Anderson RC (1983) Characteristics of natural infections of the stomach worm, *Obeliscooides cuniculi*, in lagomorphs and woodchucks in Canada. *J Wildl Dis* 19:219-224.

Meneguz PG, Tizzani P (2002) Metazoan parasites of the eastern cottontail (*Sylvilagus floridanus*) in the Province of Alessandria. XXII Congr. Naz. Soc. Italiana Parassitologia 111.

Poulin R (2007) Evolutionary ecology of parasites. Princeton University Press, Princeton.

Prestwood AK, Hayes FA, Eve JH, Smith JF (1973) Abomasal helminths of white-tailed deer in southeastern United States, Texas and the Virgin Islands. *J Am Vet Med Assoc* 163:556-561.

Rausch R, Tiner J (1946) *Obeliscooides cuniculi* from the woodchuck in Ohio and Michigan. *J Mammal* 27:177—178.

Sainsbury AW, Deaville R, Lawson B, Cooley WA, Farelly SSJ, Stack MJ, Duff P, McInnes CJ, Gurnell J, Russell PH, Rushton SP, Pfeiffer DU, Nettleton P, Lurz PWW (2008) Poxviral disease in red squirrels *Sciurus vulgaris* in the UK: spatial and temporal trends of an emerging threat. *EcoHealth* 5:305-316.

Saulai M, Cabaret J (1998) Limited role of lagomorphs (*Oryctolagus cuniculus* and *Lepus capensis*) in the dispersion of parasite nematodes of ruminants. *Vet Parasitol* 77:301—304.

Silvano F, Acquarone C, Cucco M (2000) Distribution of the eastern cottontail *Sylvilagus floridanus* in the province of Alessandria. *Hystrix* 11:75-78.

Simberloff D, Mack RN, Lonsdale WM, Evans H, Clout M, Bazzaz F (2000) Biotic invasions: causes, epidemiology, global consequences and control. *Issues Ecol* 5, Ecological Society of America.

Skrjabin KI, Shikhobalova NP, Schulz RS (1954) Trichostrongylids of animals and man. In: Skrjabin KI (ed) *Essential of Nematodology*, vol. 3. Israel program for scientific translations, Jerusalem, pp 704.

Smith CC (1940) Notes on the food and parasites of the rabbits of a lowland area in Oklahoma. *J Wildl Manage* 4:429-431.

Sollod AE, Hayes TJ, Soulsby EJJ (1968) Parasitic development of *Obeliscooides cuniculi* in rabbits. *J Parasitol* 54:129-132.

Spagnesi M, Toso S (1999) *Iconografia dei mammiferi d'Italia*. Istituto Nazionale per la Fauna Selvatica "Alessandro Ghigi" (ed). Bologna.

Stebbins GL (1992) Why should we conserve species and wildlands? In: Fiedler PL, Jain SK (eds) *Conservation biology: the theory and practice of nature conservation, preservation and management*. Chapman and Hall, New York, pp 453—470

Stringer RP, Harkema R, Miller GC (1969) Parasites of rabbits in North Carolina. *J Parasitol* 55:328.

Tizzani P, Lavazza A, Capucci L, Meneguz PG (2002) Presence of infectious agents and parasites in wild population of cottontail (*Sylvilagus floridanus*) and consideration on its role in the diffusion of pathogens infecting hares. European Association of Zoo and Wildlife Veterinarians 4th scientific meeting, Heidelberg, Germany.

Tomkins IR (1935) The marsh rabbit: an incomplete life history. *J Mammal* 16:201—205.

Tompkins DM, Begon M (1999) Parasites can regulate wildlife populations. *Parasitol Today* 15:311—313.

Twitchell AR (1939) Notes on the southern woodchuck in Missouri. *J Mammal* 20:71—74.

Vidus-Rosin A, Meriggi A, Cardarelli E, Serrano-Perez S, Mariani MC, Corradelli C, Barba A (2010) Habitat overlap between sympatric European hares (*Lepus europaeus*) and Eastern cottontails (*Sylvilagus floridanus*) in northern Italy. *Acta Theriol*. doi:10.1007/s13364-010-0005.

Ward JW (1934) A study of some parasites of rabbits of Central Oklahoma. *Proc Okla Acad Sci* 14:31—32.

Wiggins JP, Cosgrove M, Rothenbacher H (1980) Gastrointestinal parasites of the eastern cottontail (*Sylvilagus floridanus*) in central Pennsylvania. *J Wildl Dis* 16:541—544.

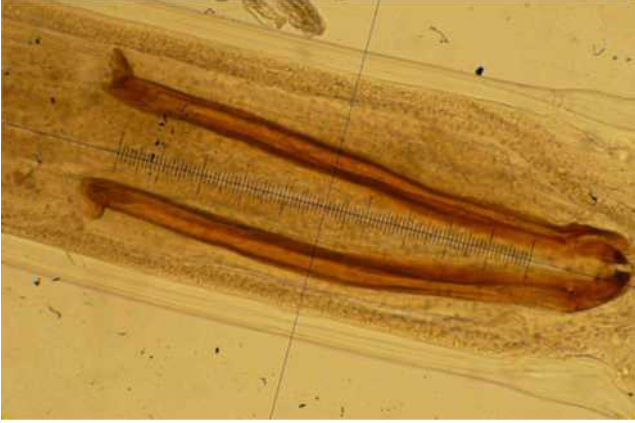


Fig. 1 Male of *Obeliscoides cuniculi*: spicules detail (x250).