



UNIVERSITÀ DEGLI STUDI DI TORINO

This is an author version of the contribution published on:

Questa è la versione dell'autore dell'opera:

Annals of Surgery

Issue: Volume 255(2), February 2012, p 334–342, DOI

10.1097/SLA.0b013e31823000ed

The definitive version is available at:

La versione definitiva è disponibile alla

*URL[[http://journals.lww.com/annalsofsurgery/pages/articleviewer.aspx?year=2012
&issue=02000&article=00022&type=abstract](http://journals.lww.com/annalsofsurgery/pages/articleviewer.aspx?year=2012&issue=02000&article=00022&type=abstract)]*

Reliability of Whole Sentinel Lymph Node Analysis by One-Step Nucleic Acid Amplification for Intraoperative Diagnosis of Breast Cancer Metastases

Castellano, Isabella MD^{1,2}; Macri, Luigia MD^{1,2}; Deambrogio, Cristina MD¹; Balmativola, Davide MD¹; Bussone, Riccardo MD^{2,3}; Ala, Ada MD^{2,3}; Coluccia, Claudio MD^{2,3}; Sapino, Anna MD^{1,2}

¹Department of Biomedical Sciences and Human Oncology, University of Turin, Turin, Italy,

²Division of Surgery,

³Breast Unit, Azienda Ospedaliera-Universitaria San Giovanni Battista, Molinette Hospital, Turin, Italy.

Disclosure: The authors declare no conflicts of interest.

Supported by Rete Oncologica Piemonte-Valle d'Aosta, PRIN 2008, AIRC 2011, Compagnia San Paolo, Cassa di Risparmio di Torino and Progetto Ricerca Sanitaria Finalizzata DD204/2009.

ABSTRACT

Objective: To assess the reliability of using the One-Step Nucleic Acid Amplification (OSNA) assay as a single test on whole sentinel lymph nodes (SLN) as a method of intraoperative diagnosis and staging of SLNs in breast cancer.

Background: Combining histological and molecular assessment of metastasis on the same SLN may not fully reproduce the actual load of cancer cells present in the SLN and create problems in decisions regarding axillary dissection.

Methods: Selection criteria for the whole SLN OSNA test required that the primary tumor expressed CK19 in more than 80% of tumor cells. Imprint cytology analysis of SLNs was performed together with the OSNA.

Results: Of the 279 patients enrolled for SLN evaluation, 123 gave consent to the OSNA protocol and 156 to the standard histology. Thirteen patients were excluded from OSNA evaluation because of low CK19 gene expression in the primary tumor; only 2.3% were truly negative. The kappa of concordance between the imprint cytology and OSNA results was 0.52. The rate of macrometastases determined by OSNA was 11% versus 20% determined by histology, whereas the rate of OSNA-micrometastases (18%) was significantly higher than that determined by histology (8%). The rate of SLN-negative cases was similar between the 2 protocols. Macrometastases correlated with the presence of vascular invasion in both protocols. The rate of axillary lymph node metastases was consistent with SLN tumor load.

Conclusions: Intraoperative OSNA assay performed on the whole SLN gave objective and reproducible results that were useful for directing decisions regarding axillary dissection and for accurately defining the SLN stage.

In recent years, sentinel lymph node (SLN) biopsy has replaced traditional axillary lymph node (ALN) dissection and has become the standard technique for node staging in patients with clinically negative axilla.¹⁻⁴ The SLN is thoroughly examined to insure that metastasis is not overlooked. However, the lack of universally accepted guidelines for SLN analysis results in a wide heterogeneity in gross- and microsectioning procedures and variability in the use of immunohistochemistry for detecting minimal tumor load.⁵ Another problem is the inconsistency in the diagnoses of isolated tumor cells (ITCs) and micrometastases, which are based solely on the size of the SLN tumor seed.^{6,7} Recently, Turner et al.⁸ showed that the consistency in diagnosis was highly improved when not only the size but also the arrangement (single, confluent or clustered) of the metastatic cells was taken into account. However, the European Working Group for Breast Screening Pathology found that the Turner et al.⁸ system was less reliable when determining the involvement of SLNs in lobular carcinoma, which metastasizes as dispersed cells and thus can easily be underscored.⁹ Taken together, these data suggest that the morphological evaluation of SLNs is not a reliable method for determining the actual tumor load in breast cancer patients.

Another challenge relates to the intraoperative assessment of SLNs; specifically, whether and how the pathological assessment is to be performed (for example, using frozen sections or imprint cytology and with or without rapid immunohistochemistry to detect epithelial markers).⁵ Although intraoperative diagnosis allows for immediate axillary dissection and avoids a second surgery, its sensitivity varies from 44% to 75% regardless

of the method used.¹⁰⁻¹³ Thus, many institutions avoid intraoperative SLN analysis and postpone the diagnosis by formalin-fixing and paraffin-embedding tissues.

With this complex background, molecular tests based on the identification of tumor-specific mRNA markers have been developed.¹⁴⁻¹⁶ Several studies have demonstrated that molecular approaches, such as real-time PCR, show a high sensitivity and specificity when compared to traditional histopathological examination of SLNs.^{17, 18} Comparing quantitative PCR with extensive histological sectioning under laboratory conditions the sensitivity of molecular methods varies from 91% to 97% and the specificity may be equal to 97%.¹⁹ However, samples from the same node used partly for molecular analysis and partly for morphological analysis generate obvious discrepancies because of uneven tissue distribution.^{20, 21} For example in a previous study, using a fixation procedure that preserved both morphology and high-quality mRNA, we demonstrated, for example, that when metastases >2 mm were located at a pole of a lymph node they might be missed by either hematoxylin & eosin (H&E), immunostaining or RT-PCR applied to samples obtained from the opposite pole of the same lymph node.²¹ This data is in line with a previous geometrical model, which showed that incomplete sectioning of the SLNs in extreme situations would almost completely miss metastases >2 mm which would be identified at best as ITC.²²

Thus, herein, we tested the One-Step Nucleic Acid Amplification (OSNA) molecular assay (Sysmex) on whole SLNs for intraoperative diagnosis. The OSNA assay quantitatively measures the presence of cytokeratin-19 (CK19) mRNA, which distinguishes the absence of metastases from the presence of either micro- or macrometastases in the SLN.²³⁻²⁶ The aim of our study was to assess the reliability of OSNA analysis of whole SLNs as compared to standard histological diagnoses of the SLN, taking into account the biological features of primary breast cancer and the non-SLN status when axillary dissection was performed.

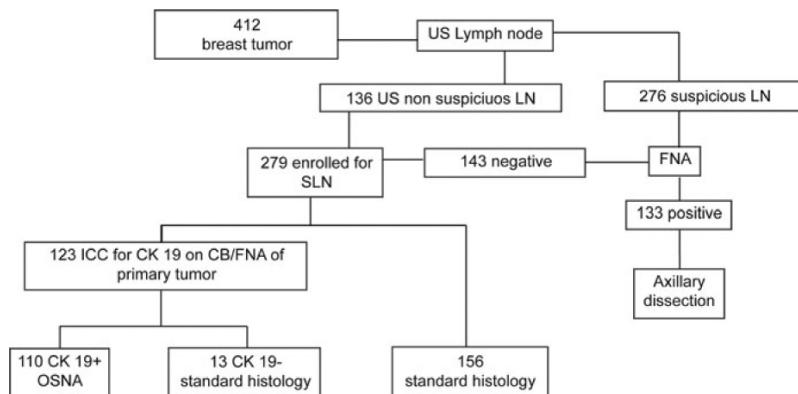
METHODS

Case Series

From January to October 2010, 412 patients with breast cancer underwent surgery at the Breast Unit of the Azienda Ospedaliera Universitaria San Giovanni Battista of Turin. Following a standard protocol for presurgical staging, patients underwent ultrasound (US) examination of the axilla.²⁷ Two hundred seventy-six patients had fine needle aspiration (FNA) of

ALNs deemed to be suspicious by US and 133 showed presence of cancer cells on the cytological smears. Two hundred seventy-nine patients who did not have suspicious ALNs upon US examination nor positive cytological smears were eligible for SLN biopsies (Fig. 1). SLNs were identified using a combination of blue dye and radioactive isotopes.^{28,29} Blue-stained nodes and nodes with high radioactive counts were considered SLNs. The mean number of SLNs per patient was 1.2. To avoid any contamination of the tissue specimens during tumor manipulation, SLNs were excised before primary tumor surgery and immediately sent to the pathology laboratory for examination.

Fig.1 Study flowchart shows the process of patient selection. LN, lymph node; ICC, immunocytochemistry; CB, core biopsy.



Patient Selection for Whole SLN Examination by OSNA

The protocol for the whole SLN examination by OSNA was approved by the local ethical committee. Informed consent was obtained from all patients before inclusion in the current study. To be enrolled for whole SLN evaluation by OSNA, the primary tumor had to express CK19 in >80% of tumor cells, as the OSNA assay evaluates CK19 mRNA copy number, and the lack of CK19 protein expression has been reported in approximately 2% of breast cancer patients.³⁰ The expression of CK19 (clone RCK108, Dako, Denmark A/S DK 2600 Glostrup, diluted 1:100) in primary tumors was determined by immunocytochemical (ICC) analysis of either histological sections of the core biopsy or H&E-stained smears obtained by FNA.

Intraoperative Procedure for OSNA Analysis

The fresh SLN was cleared from fat tissue, weighed and cut along the short axis to obtain gross sections of 2.0 mm in thickness and processed as illustrated in Fig. 2(A). Imprint cytology was performed by touching the 2 sides of the cut surfaces of each gross section onto clean slides. Two of these slides were then fixed in 95% ethanol and stained with rapid H&E, and 2 others were fixed in neutral buffered formalin for 5 minutes and subjected to rapid ICC through incubation with an anticytokeratin mouse monoclonal antibody (clone AE1/AE3, Ventana-Diaphat, Tucson, AZ, USA, prediluted) for 5 minutes at 37°C. After washing with PBS, the sections were incubated with EnVision, DakoCytomation (Dako, Denmark, Glostrup) for 9 minutes at 37°C. Sections were then treated with diaminobenzidine tetrahydrochloride and counter-stained with hematoxylin. In the meantime the imprint cytology smears were stained, the SLNs were processed for OSNA. The minimum weight of the SLN for 1 OSNA reaction was 50 mg and the maximum was 600 mg. For SLNs exceeding 600 mg, 2 OSNA reactions were performed. SLNs were homogenized in 4 ml lysis buffer (Lynorhag, Sysmex, Kobe, Japan) for 90 seconds on ice with a Politron PT1200-E homogenizer (Kinematica, Lucerne, Switzerland). The homogenate was centrifuged at 10,000g at room temperature for 1 minute, and 20-µL aliquots were used as a template for the reverse transcription loop-mediated isothermal amplification (RT-LAMP) reaction. To determine CK19 mRNA levels RT-LAMP was performed on an RD-100i automated mRNA amplification instrument (Sysmex, Kobe, Japan) with a ready-to-use reagent kit (Lynoamp, Sysmex) consisting of the enzyme,

primers, nucleotides, buffer necessary for CK19 mRNA amplification and components for assay validation (calibrators, positive and negative controls).

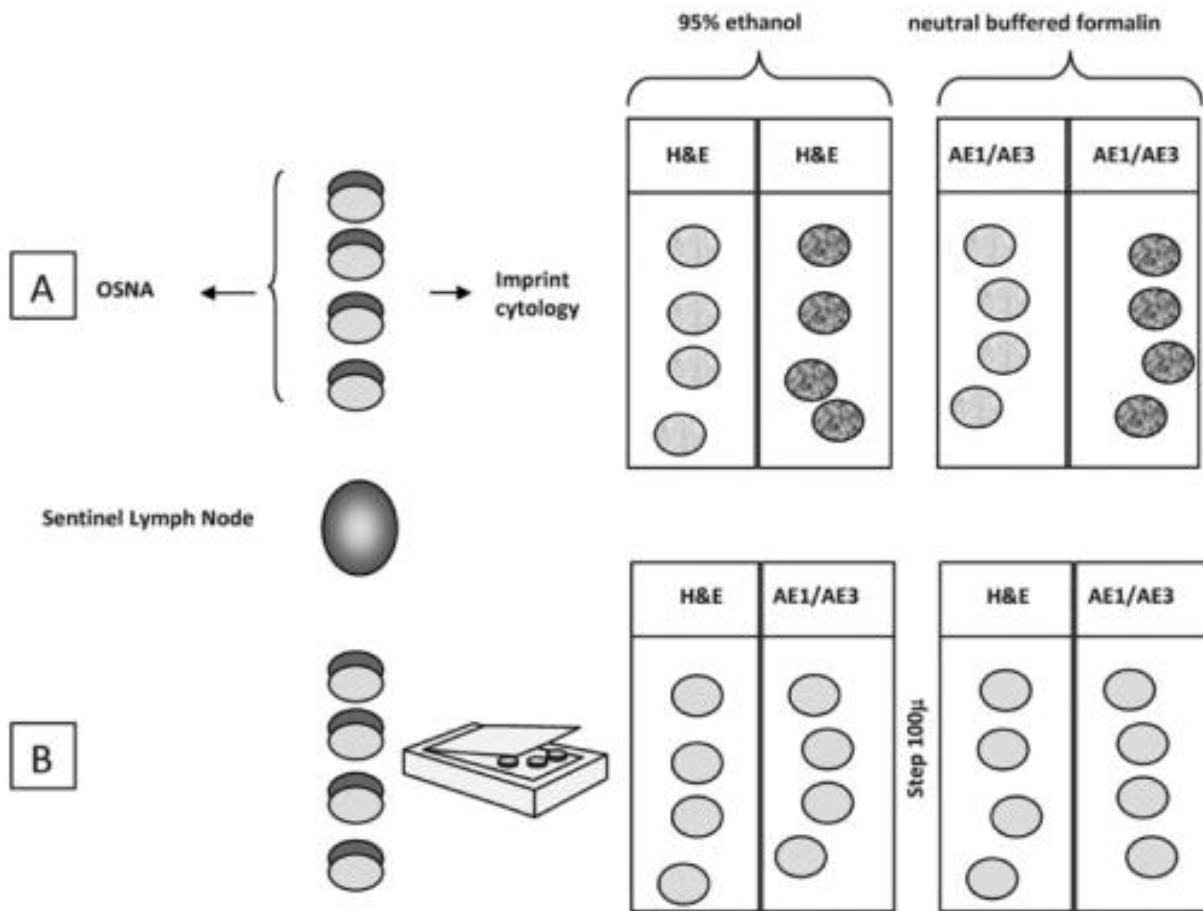


Fig.2 Preparation of the sentinel lymph node (SNL) for evaluation by OSNA and imprint cytology (A) and standard histopathological techniques (B). The SNL was cut along the short axis to obtain gross sections of 2.0 mm in thickness. (A) Imprint cytology was performed by touching the 2 sides of the cut surfaces of each gross section onto slides. Two of these slides were then fixed in 95% ethanol and stained with rapid hematoxylin and eosin (H&E), and 2 were fixed in neutral buffered formalin and tested by rapid immunocytochemistry with anti-AE1/AE3 antibodies. The whole SNL was examined by OSNA. (B) The gross sections were placed in bioboxes, formalin-fixed and paraffin-embedded. Each SNL was then step-sectioned at 100-μm intervals until the extinction of the wax blocks. The first 2 consecutive sections for each step were used for H&E staining and immunohistochemistry with anti-AE1/AE3 antibodies.

Results were expressed as the number of CK19 mRNA copies per microliters, and metastatic load was assessed in accordance with the cut-off levels defined by Tsujimoto et al.²⁶ On the basis of the values obtained using the standard curve, the (+) symbol corresponded to 250 to 5000 CK19 mRNA copies/μL and was defined as “micrometastases,” and the (++) symbol corresponded to >5000 CK19 mRNA copies/μL and was defined as “metastases.” A negative result (–) had less than 250 CK19 mRNA copies/μL and reflected the absence of cancer cells or the presence of ITC. The OSNA instrument software displayed (ND) in samples with no CK19 mRNA and (L) when the CK19 mRNA copy number was between 100 and 250 copies/μL. The symbol (I) appeared when the analysis was being performed on a sample previously diluted 1:10 in lynch solution. These diluted samples were prepared for each case to limit the activity of substances that could inhibit the amplification, such as an excess of adipose tissue.

Management of Patients after OSNA Examination

The surgical management of the patients with regard to ALN dissection after whole SLN examination by OSNA was discussed and approved by the surgeons and oncologists of the breast unit (Fig. 3). For the study purposes, patients with macrometastases (determined by OSNA and non-OSNA) or micrometastases determined by OSNA and associated with a positive imprint cytological analysis underwent immediate ALN dissection. In the other cases of micrometastases ALN dissection was postponed until evaluation of the biological features of the primary tumor (diameter, grade, vascular invasion) at multidisciplinary discussions. Finally, ALN dissection was not recommended for patients with AE1/AE3-positive cells as determined by imprint cytology, patients that had negative SLN results by OSNA or patients with ITCs detected by standard histological examination.

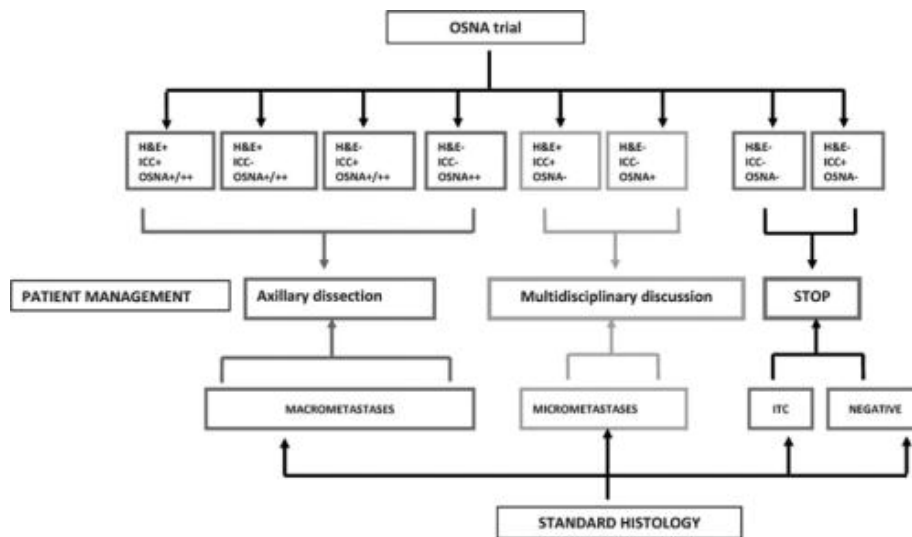


Fig.3

Surgical management of patients after diagnosis by OSNA or with standard histology. Patients with macrometastases (determined by OSNA and non-OSNA) or micrometastases determined by OSNA and a positive imprint cytological analysis underwent immediate axillary dissection. For patients with micrometastases (determined by OSNA and non-OSNA) or a positive imprint cytological analysis (hematoxylin and eosin [H&E]+ immunocytochemistry (ICC), axillary dissection was postponed after multidisciplinary discussions. Patients with OSNA-negative SLNs or Isolated Tumor cells (ITCs) detected by standard histological analysis were not recommended to undergo axillary dissection.

Real Time-PCR of Discordant Cases

Total RNA was extracted from samples with discordant results between imprint cytology and OSNA analyses with the RNeasy mini-kit (Qiagen, Hilden, Germany) according to the manufacturer's instructions. Quantitative RT-PCR was performed using the breast cancer markers, CK19 and SPDEF (SAM pointed domain containing Ets transcription factor), and beta-actin as a control as described in detail elsewhere.^{24–26} The cut-off levels previously suggested and expressed in threshold cycles (Ct) were as follows: 31.5 for CK19 and 31.6 for SPDEF. Cases with a Ct value 2 times lower than the cut-off were considered as positive, cases with value 2 times higher than the Ct were considered as negative; cases in between were considered as borderline.

Standard SLN Processing

Following a protocol proposed by the regional section of the Italian Society of Pathology, 31 no intraoperative diagnosis was performed, and the SLN was processed for standard histological examination (Fig. 2B). Fresh SLNs were sliced at 2.0 mm as reported above. The gross sections were placed in bioboxes and formalin-fixed. When embedding the samples in paraffin wax, care was taken to preserve the original sequence of slices so that the top cut surface of a gross section and the bottom surface of the next section represented contiguous areas of the SLN. Each SLN was then step-sectioned at 100- μ m intervals until the extinction of the wax blocks. The first 2 consecutive sections were used for H&E staining and ICC analysis with AE1/AE3 anti-cytokeratin antibodies (clones AE1/AE3 & PCK26, Ventana-Diapath, prediluted) using the BenchMark AutoStainer (Ventana Medical Systems).

Metastatic deposits were measured in 2 dimensions and categorized based on the staging system established by the American Joint Committee on Cancer.⁷ The categories were as follows: pN0(i+), malignant cells <0.2 mm, single tumor cells or a cluster of <200 cells in a single histologic cross-section (including ITCs); pN1mi, micrometastases >0.2 mm and/or >200 cells, but not >2.0 mm and pN1a, metastases in 1 to 3 ALNs or at least 1 metastasis >2.0 mm.

ALNs were isolated from the fat tissue and grossly sliced at 2.0 mm intervals if larger than 0.5 cm similarly to the SLNs. Two H&E stained sections were produced for each block.

Data Analysis

The concordance between cytological analysis on imprint, considered as the “gold standard,” and the OSNA analysis was calculated using the Cohen's K statistic (for that purpose, to compare the same number of categories within the cytological imprint diagnosis and the OSNA assay results, macrometastases and micrometastases cases were merged into a single positive category). Sensitivity, specificity and positive and negative predictive values of OSNA were calculated.

The primary tumor variables listed in Table 1 and the ALN status were compared with the OSNA and non-OSNA results using the [chi]² test. P values <0.05 were considered statistically significant.

Pathological Parameters	OSNA 110 (%)	Non-OSNA 169 (%)	P
Age (yr)			
Median (range)	66.7 (38-82)	61.2 (23-86)	NS
≤45	5 (5)	17 (10)	
46-55	30 (27)	35 (21)	
56-65	32 (29)	45 (26)	
≥65	43 (39)	72 (43)	
Tumor size (mm)			
<10	33 (30)	41 (24)	NS
1.1-1.5	19 (17)	45 (27)	
>1.5	58 (53)	83 (49)	
Histological grade			
1	46 (42)	65 (38)	NS
2	48 (44)	79 (47)	
3	16 (14)	25 (15)	
Histological type			
Ductal	81 (74)	109 (64)	NS
Lobular	16 (14)	29 (17)	
Special type	13 (12)	31 (18)	
Vascular invasion			
Absent	80 (73)	118 (70)	NS
Present	30 (27)	51 (30)	
Estrogen receptor			
0-10%	10 (9)	14 (8)	NS
>10%	100 (91)	155 (92)	
Progesterone receptor			
0-10%	22 (20)	38 (22)	NS
>10%	88 (80)	131 (78)	
HER2			
Negative	108 (98)	144 (85)	NS
Positive	2 (2)	25 (15)	
Ki67			
0-10%	35 (32)	55 (33)	NS
>10%	75 (68)	114 (67)	

HER2 indicates human epidermal growth factor receptor 2; Ns, not significant.

TABLE 1. Comparison of Primary Tumor Features of the 2 Series of Patients

RESULTS

Of 279 patients enrolled for SLN procedure, 123 patients gave their consent to participate in OSNA analysis (44%). Of these, 13 patients were excluded because the primary tumor was either negative for (3 cases) or expressed low levels of (10 cases) CK19 and the SLN was thus evaluated by traditional histology (Fig. 1). The remaining 156 (56%) patients were evaluated using standard histological examination of SLNs (Fig. 1). The histopathological parameters of the tumors of patients participating and nonparticipating to the OSNA analysis were compared (Table 1). Although the patient and tumor characteristics did not differ statistically between the 2 groups, the patients were not selected randomly and the numbers were too small to exclude that differences not represented by the statistics may exist.

Correlation of OSNA with Imprint Cytology

A total of 131 SLNs from 110 patients were examined by OSNA. Three patients had bilateral disease and the SLNs on each side were studied. The H&E diagnosis matched perfectly with the ICC diagnosis on imprint cytology. The concordance between imprint cytology and OSNA analyses gave a Cohen's K statistic of 0.52 (Table 2). The OSNA procedure showed 93.75% sensitivity, 83.47% specificity, 0.44 positive predictive value and 0.99 negative predictive value.

OSNA Assay	Imprint Cytology (H&E/ICC)		
	Positive (%)	Negative (%)	Total
Macrometastases (+ +)	10 (83)	2 (17)	12 (9)
Micrometastases (+)	5 (23)	17 (77)	22 (17)
Negative	1 (1)	96 (99)	97 (74)
Total	16 (12)	115 (88)	131 (100)
K 0.52			
H&E indicates hematoxyline and eosin; ICC, immunocytochemistry.			

TABLE 2. Contingency Table and Concordance Between OSNA Assay Results and Cytological Imprint Diagnosis of 131 SLN Examined

Of the 20 discordant cases, the 2 OSNA-diagnosed macro-metastases and 9 micrometastases, which were negative by imprint cytology, were positive for CK19 and/or SPDEF by real-time PCR (Table 3); 8 samples with micrometastases had “borderline” Ct. One single sample (L71), which was H&E/ICC-positive and OSNA-negative, was positive by real-time PCR. This case was designated by the OSNA instrument software as (L), meaning that the CK19 mRNA copy number was not 0 but between 100 and 250 copies/ μ L. The ALNs of sample L71 were not metastatic.

Cases	Imprint Cytology	OSNA		SYBR-Green RT-PCR			ALN (positive LN/Total LN)
		CK19 Copy number/ μ L	Result	CK19 Cut-off 31.5 Ct	SPDEF Cut-off 31.6 Ct	Result	
L2	-	4.6×10^3	+	32	32.6	Borderline	Yes (0/20)
L32	-	4.9×10^3	+	27.1	27.5	Positive	Yes (0/8)
L12	-	4.7×10^3	+	25.8	25.7	Positive	No
L26	-	6.6×10^2	+	32.8	32.9	Borderline	No
L13	-	2.0×10^3	+	28.1	27.7	Positive	Yes (0/23)
L38	-	3.4×10^3	+	30	32.3	Borderline	No
L35	-	1.4×10^3	+	25.4	24.7	Positive	Yes (0/13)
L28	-	2.7×10^2	+	26.4	25.4	Positive	Yes (2/18)
L75	-	2.9×10^2	+	31.8	32	Borderline	No
L35 b	-	6.9×10^2	+	26.3	26.1	Positive	Yes (0/13)
L50	-	2.8×10^2	+	31.3	32.9	Borderline	No
L31	-	3.4×10^2	+(I)	21	21.6	Positive	No
L6	-	4.1×10^3	+(I)	33.2	34	Borderline	No
L26	-	4.9×10^2	+(I)	32	34	Borderline	No
L2b	-	3.3×10^2	+(I)	25.1	24.8	Positive	Yes (0/19)
L31b	-	1.0×10^3	+(I)	30.8	31.5	Borderline	No
L33	-	1.3×10^3	+(I)	31.1	25.1	Positive	No
L3	-	1.6×10^4	++	23.3	25.0	Positive	Yes (0/19)
L52	-	2.3×10^4	++	25.1	25.4	Positive	Yes (0/14)
L71	+	<250	-(L)	27.3	28.9	Positive	Yes (0/12)

(+) indicates micrometastases; (+ +), macrometastases; (I), data obtained using a sample previously diluted 1:10 in Lysorbag solution; Ct: threshold cycles.

TABLE 3. SYBR-Green Real-Time PCR Analyses of the 20 Samples that Showed Discordant Results Between Imprint Cytology and OSNA

Comparison between OSNA and Standard Histology Techniques

As shown in Table 4, the rate of negative cases determined by standard histology (negative + ITC) (73%) was highly comparable with the rate of negative SLNs determined by OSNA (71%). The percentage of micrometastases detected by OSNA was instead significantly higher (18%) than that determined by the standard procedure (8%; [chi]2 7.03; P < 0.01), on the contrary the rate of macrometastases detected by OSNA was lower (11%) but was not significantly different from that determined by standard histology (20%). The presence of macrometastases significantly correlated with vascular invasion ([chi]2 21.34; P < 0.01 and [chi]2 21.79; P < 0.01), and similarly, the absence of metastases correlated with the absence of vascular invasion in both protocols ([chi]2 15.21; P < 0.01 and [chi]2 20.82; P < 0.01). No significant difference was observed in the rate of metastatic ALNs after the diagnoses of micro- and macrometastases in SLNs either by OSNA or standard procedure (Table 5).

Pathological Parameters	Total Cases		Negative and ITC				Micrometastases		Macrometastases	
	OSNA (%)	Non-OSNA (%)	OSNA		Non-OSNA		OSNA (%)	Non-OSNA (%)	OSNA (%)	Non-OSNA (%)
			Negative (%)	ITC (%)	Negative + ITC (%)	Negative (%)				
Number of cases	110 (100)	169 (100)	78 (71)	112 (66)	11 (7)	123 (73)	20 (18)	13 (8)	12 (11)	33 (20)
Tumor size (mm)										
< 10	33	41	24 (73)	32 (78)	3 (7)	35 (85)	7 (21)	2 (5)	2 (6)	4 (12)
11-15	19	45	14 (74)	32 (71)	2 (5)	34 (76)	4 (21)	4 (9)	1 (5)	7 (15)
> 15	58	83	40 (69)	48 (58)	6 (7)	54 (65)	9 (15.5)	7 (8)	9 (15.5)	22 (26)
Histological grade										
1	46	65	32 (70)	50 (76)	3 (5)	53 (81)	12 (26)	3 (5)	2 (4)	9 (14)
2	48	79	35 (73)	45 (57)	8 (10)	53 (67)	5 (10)	9 (11)	8 (17)	17 (21)
3	16	25	11 (69)	17 (68)	0	17 (68)	3 (19)	1 (4)	2 (12)	7 (43)
Histological type										
Ductal	81	109	58 (72)	67 (62)	9 (8)	76 (70)	12 (15)	11 (10)	11 (13)	22 (26)
Lobular	16	29	11 (69)	18 (62)	2 (7)	20 (69)	4 (25)	2 (7)	1 (6)	7 (43)
Special type	13	31	9 (69)	27 (87)	0	27 (87)	4 (31)	0	0	4 (13)
Vascular invasion										
Absent	80	118	65 (81)	92 (78)	6 (5)	98 (83)	13 (16)	8 (7)	2 (3)	12 (14)
Present	30	51	13 (43)	20 (39)	5 (10)	25 (49)	7 (23)	5 (10)	10 (33)	21 (41)
Estrogen receptor										
0-10%	10	14	8 (80)	10 (71)	1 (7)	11 (79)	2 (20)	1 (7)	0	2 (14)
> 10%	100	155	70 (70)	102 (66)	10 (6)	112 (72)	18 (18)	12 (8)	12 (12)	31 (20)
Progesterone receptor										
0-10%	22	38	17 (77)	24 (63)	3 (8)	27 (71)	4 (18)	3 (8)	1 (5)	8 (21)
> 10%	88	131	61 (69)	88 (67)	8 (6)	96 (73)	16 (18)	10 (8)	11 (13)	25 (20)
HER2										
Negative	108	144	77 (71)	96 (67)	9 (6)	105 (73)	20 (19)	12 (8)	11 (10)	27 (20)
Positive	2	25	1 (50)	16 (64)	2 (8)	18 (72)	0 (0)	1 (4)	1 (50)	6 (24)
Ki67										
0-10%	35	55	27 (77)	37 (67)	5 (9)	42 (76)	7 (20)	7 (13)	1 (3)	6 (11)
> 10%	75	114	51 (68)	75 (66)	6 (5)	81 (71)	13 (17)	6 (5)	11 (15)	27 (31)

TABLE 4. Comparison of Histopathological Parameters of Primary Breast Cancer of Patients Enrolled to OSNA and to Standard Histopathology Examination of Sentinel Lymph Node

Positive axillary status	OSNA	Standard Histology
Macrometastases	5/12 (42%)	15/33 (45%)
Micrometastases	2/9 (22%)	2/9 (22%)

TABLE 5. Comparison Between OSNA Assay Results and Standard Histology in the Involvement of Non-Sentinel Lymph Node

DISCUSSION

This work demonstrated that the OSNA assay may be reliably used for intraoperative diagnosis of patients with breast cancer using the whole SLN for analysis. The OSNA protocol was discussed with surgeons, as well as with oncologists, because the SLN could be the only lymph node with metastases, and thus, the use of the OSNA procedure influenced not only the surgical but also the medical management acting on the patient risk category.³² In recent years, several studies have proposed procedures for molecular-based detection of metastasis with proper calibration for intraoperative diagnosis of the SLN in breast cancer.^{33–36} In particular, the OSNA assay evaluates the number of mRNA copies of CK19, an epithelial marker highly expressed in the majority of breast cancers. Different protocols have been designed to determine the sensitivity and specificity of the OSNA assay for the detection of metastasis in comparison with histological examination.^{20, 23–26} These protocols recommend subdividing the single SLN into gross sections to be used for both molecular and histological diagnosis.^{20, 23–26} Previously, we have shown the technical limits of histological- and of molecular-based diagnoses performed on microsections of the same SLN. These limits depend not only on the diameter but also on the location of metastases.²¹ The tissue allocation bias has been regarded as one of the main causes of discordance when comparing the 2 procedures.^{20, 21} However, it has never been discussed whether the micrometastases detected on a sample by molecular assay should be added, for example, to the micrometastases diagnosed by standard histology on the parallel sample of the same SLN to obtain a final evaluation of the tumor burden. These variables may impact heavily on nodal staging of the SLN, because variations in the dimension of the metastasis in the range of microns or a tenth of cells may move a patient from the pN0 (absence of metastases) to the pN1 (presence of metastases) stage and vice versa. This study proposes that the molecular analysis of the whole SLN would avoid these biases and allow a less subjective evaluation of the metastatic tumor load. In fact, the OSNA assay is a system for rapid and quantitative detection of CK19 mRNA,²⁶ which guarantees a high specificity with a low false-positive rate. The rate of micrometastases detected by OSNA in this study was significantly higher than that detected by standard histology, whereas the rate of OSNA-determined macrometastases was lower. The difference of micro- versus macrometastases between the 2 groups may be a reflection of different patient populations rather than a reflection of the different techniques of analysis of the SLN. However, because the percentage of negative cases was similar between the 2 protocols our data may suggest the hypothesis that the morphological evaluation of the diameter of metastases does not perfectly correlate with the tumor load as evaluated by mRNA copies of CK19, and that, at least in our series, there could be either an overestimation of the macro- versus micrometastases by histology or an underestimation of the macro- versus

micrometastases by OSNA. This is quite important because recent studies show that ALN dissection is not mandatory in the presence of micrometastases at difference with the presence of macrometastases.^{37–39} Up to now the volume of metastatic disease evaluated by molecular analysis that would require an axillary dissection has not been established and only recurrence and survival data will clarify it. In addition, the OSNA assay does not provide any data about the presence of ITCs, however follow-up studies have shown that patients with ITCs have locoregional recurrence rates very similar to SLN-negative cases.⁴⁰

A major problem associated with the analysis of the whole SLN by OSNA may be the risk of false negative results due to the presence of metastases from breast cancers that do not express CK19. For this reason, we required that the expression of CK19 by the primary tumor be a prerequisite for patients participating in the OSNA analysis, although the ICC pre-test added minimal cost to the procedure. The lack of CK19 protein expression has been reported in approximately 2% of breast cancers.³⁰ We confirmed this result, finding that 2.8% of the cases in our series were truly negative. Cases that showed <20% of cells positive for CK19 were probably the result of poor-quality ICC performed on smears that had been previously stained with H&E, as indicated by the high level of CK19 expression subsequently observed on surgical samples of the primary tumors (data not shown). Furthermore, to verify the OSNA results, we performed touch imprint cytology for every SLN. Imprint cytology failed to show metastatic involvement in 58% of OSNA-positive SLNs. This result is in agreement with those reported by Layfiel MD and colleagues¹⁹ in a recent review. The authors concluded that “pathological techniques of intraoperative SLNB analysis such as touch imprint cytology and frozen section have a high specificity, but a lower and more variably reported sensitivity. Molecular techniques are potentially able to sample a greater proportion of the sentinel node, and could have higher sensitivity.”¹⁹ A possible justification of the result we obtained is that 90% of discordant cases were diagnosed as micrometastasis by the OSNA assay, suggesting that imprint cytology may under diagnose low tumor burden in the SLN.^{41–44} Nevertheless, imprint cytology is useful in conjunction with the whole SLN-OSNA assay to check for other diseases, such as lymphomas, or to determine the presence of metastases of other tumors, such as melanomas.

The rate of metastases in ALNs excised after a positive SLN was not significantly different between patients in the OSNA group and in the standard histology group, and this rate was consistent with that reported in previous studies.⁴⁰

Finally, a cost analysis assessment of the OSNA technique was performed at a large UK district general hospital and indicated that there was an implicit savings in reducing the number of secondary surgeries, such as reduced bed occupancy, and this savings may comfortably offset the expense of intraoperative molecular analysis.⁴⁵ Another way to allow intraoperative axillary dissection to proceed would be to improve on the intraoperative, cryostat section diagnosis; however frozen sections, have a sensitivity that range from 17% to 92% for micrometastases and from 84% to 94% for macrometastases¹⁹ and do require well trained laboratory technicians.

In conclusion, an intraoperative OSNA assay performed on the whole SLN gives objective and reproducible results that can be used for proceeding for axillary dissection in a single surgical session. In addition, the more accurate evaluation of tumor load in the SLN provides a valuable tool for assessing the risk category of patients with breast cancer and in turn for defining the oncological therapy.

ACKNOWLEDGMENTS

Authors would like to thank all the staff working in the Breast Unit of the AOU San Giovanni Battista Molinette Hospital of Turin, including surgeons (Dr. Roberto Cianci, Dr. Simona Bevilacqua, Dr. Roberto Giani), oncologists (Dr. Michela Donadio, Dr. Silvia Beatrice and Dr. Mario Airoidi) and other support staff. The authors thank Rosanna Lupo and Andrea Marazzi and the laboratory technicians of the Pathological Section of the Department of Biomedical Sciences and Human Oncology, University of Turin. The authors gratefully thank Dr. Elisabeth Breit, Dr. Monica Zaenkert and Dr. Elena Bergatto for their contribution to implement the technology. Authors are grateful to Dr. Francesca Pennechi for her valuable assistance in statistical data management.

REFERENCES

1. Veronesi U, Paganelli G, Viale G, et al. Sentinel lymph node biopsy as a staging procedure in breast cancer: update of a randomized controlled study. *Lancet Oncol.* 2006;7:983–990.
2. Veronesi U, Paganelli G, Galimberti V, et al. Sentinel-node biopsy to avoid axillary dissection in breast cancer with clinically negative lymph-nodes. *Lancet.* 1997;349:1864–1867.
3. Benson JR, della Rovere GQ. Management of the axilla in women with breast cancer. *Lancet Oncol.* 2007;8:331–348.
4. Lyman GH, Giuliano AE, Somerfield MR, et al. American Society of Clinical Oncology guideline recommendations for sentinel lymph node biopsy in early-stage breast cancer. *J Clin Oncol.* 2005;23:7703–7720.
5. Cserni G, Amendoeira I, Apostolikas N, et al. Discrepancies in current practice of pathological evaluation of sentinel lymph nodes in breast cancer. Results of a questionnaire based survey by the European Working Group for Breast Screening Pathology. *J Clin Pathol.* 2004;57:695–701.
6. Cserni G, Bianchi S, Boecker W, et al. Improving the reproducibility of diagnosing micrometastases and isolated tumor cells. *Cancer.* 2005;103:358–367.
7. Edge SB, Byrd DR, Compton CC, et al. (Eds.) (2009). *AJCC Cancer Staging Manual.* 7th ed. New York, NY: Springer.

8. Turner RR, Weaver DL, Cserni G, et al. Nodal stage classification for breast carcinoma: improving interobserver reproducibility through standardized histologic criteria and image-based training. *J Clin Oncol*. 2008;26:258–263.
9. van Deurzen CH, Cserni G, Bianchi S, et al. Nodal-stage classification in invasive lobular breast carcinoma: influence of different interpretations of the pTNM classification. *J Clin Oncol*. 2010;28:999–1004.
10. Layfield DM, Agrawal A, Roche H, et al. Intraoperative assessment of sentinel lymph nodes in breast cancer. *Br J Surg*. 2011;98:4–17.
11. Aihara T, Munakata S, Morino H, et al. Comparison of frozen section and touch imprint cytology for evaluation of sentinel lymph node metastasis in breast cancer. *Ann Surg Oncol*. 2004;11:747–750.
12. Beach RA, Lawson D, Waldrop SM, et al. Rapid immunohistochemistry for cytokeratin in the intraoperative evaluation of sentinel lymph nodes for metastatic breast carcinoma. *Appl Immunohistochem Mol Morphol*. 2003;11:45–50.
13. Leikola JP, Toivonen TS, Krogerus LA, et al. Rapid immunohistochemistry enhances the intraoperative diagnosis of sentinel lymph node metastases in invasive lobular breast carcinoma. *Cancer*. 2005;104:14–19.
14. Bostick PJ, Chatterjee S, Chi DD, et al. Limitations of specific reverse-transcriptase polymerase chain reaction markers in the detection of metastases in the lymph nodes and blood of breast cancer patients. *J Clin Oncol*. 1998;16:2632–2640.
15. Manzotti M, Dell'Orto P, Maisonneuve P, et al. Reverse transcription–polymerase chain reaction assay for multiple mRNA markers in the detection of breast cancer metastases in sentinel lymph nodes. *Int J Cancer*. 2001;95:307–312.
16. Sakaguchi M, Virmani A, Dudak MW, et al. Clinical relevance of reverse transcriptase–polymerase chain reaction for the detection of axillary lymph node metastasis in breast cancer. *Ann Surg Oncol*. 2003;10:117–125.
17. Nissan A, Jager D, Roystacher M, et al. Multimarker RT-PCR assay for the detection of minimal residual disease in sentinel lymph nodes of breast cancer patients. *Br J Cancer*. 2006;94:681–685.
18. Schoenfeld AY, Luqmani D, Smith OR, et al. Detection of breast cancer micrometastases in axillary lymph nodes by using polymerase chain reaction. *Cancer Res*. 1994;54:2986–2990.
19. Layfield DM, Agrawal A, Roche H, et al. Intraoperative assessment of sentinel lymph nodes in breast cancer. *Br J Surg*. 2011;98:4–17.

20. Snook KL, Layer GT, Jackson PA, et al. Multicentre evaluation of intraoperative molecular analysis of sentinel lymph nodes in breast carcinoma. *Br J Surg*. 2010 Dec 23. Available at: <http://onlinelibrary.wiley.com/doi/10.1002/bjs.7347/pdf>.
21. Daniele L, Annaratone L, Allia E, et al. Technical limits of comparison of step-sectioning, immunohistochemistry and RT-PCR on breast cancer sentinel nodes: a study on methacarn-fixed tissue. *J Cell Mol Med*. 2009;13:4042–4050.
22. Cserni G. A model for determining the optimum histology of sentinel lymph nodes in breast cancer. *J Clin Pathol*. 2004;57:467–471.
23. Tamaki Y, Akiyama F, Iwase T, et al. Molecular detection of lymph node metastases in breast cancer patients: results of a multicenter trial using the one-step nucleic acid amplification assay. *Clin Cancer Res*. 2009;15:2879–2884.
24. Schem C, Maass N, Bauerschlag DO, et al. One-step nucleic acid amplification—a molecular method for the detection of lymph node metastases in breast cancer patients; results of the German study group. *Virchows Arch*. 2009;454:203–210.
25. Visser M, Jiwa M, Horstman A, et al. Intra-operative rapid diagnostic method based on CK19 mRNA expression for the detection of lymph node metastases in breast cancer. *Int J Cancer*. 2008;122:2562–2567.
26. Tsujimoto M, Nakabayashi K, Yoshidome K, et al. One-step nucleic acid amplification for intraoperative detection of lymph node metastasis in breast cancer patients. *Clin Cancer Res*. 2007;13:4807–4816.
27. Sapino A, Cassoni P, Zanon E, et al. Ultrasonographically-guided fine-needle aspiration of axillary lymph nodes: role in breast cancer management. *Br J Cancer*. 2003;88:702–706.
28. Giuliano AE, Kirgan DM, Guenther JM, et al. Lymphatic mapping and sentinel lymphadenectomy for breast cancer. *Ann Surg*. 1994;220:391–398.
29. Boolbol SK, Fey JV, Borgen PI, et al. Intradermal isotope injection: a highly accurate method of lymphatic mapping in breast carcinoma. *Ann Surg Oncol*. 2001;8:20–24.
30. Chu PG, Weiss LM. Keratin expression in human tissues and neoplasms. *Histopathology*. 2002;40:403–439.
31. Pietribiasi F, De Rosa G, Arisio R, et al. Protocol for diagnostic assessment of sentinel lymph node in breast pathology: a proposal of SIAPEC-IAP, Piemonte Region, Italy. *Pathologica*. 2006;98:167–170.

32. Goldhirsch A, Ingle JN, Gelber RD, et al. Thresholds for therapies: highlights of the St Gallen International Expert Consensus on the primary therapy of early breast cancer 2009. *Ann Oncol.* 2009;20:1319–1329.
33. Blumencranz P, Whitworth PW, Deck K, et al. Sentinel node staging for breast cancer: intraoperative molecular pathology overcomes conventional histologic sampling errors. *Am J Surg.* 2007;194:426–432.
34. Viale G, Dell'Orto P, Biasi MO, et al. Comparative evaluation of an extensive histopathologic examination and a real-time reverse-transcription-polymerase chain reaction assay for mammaglobin and cytokeratin 19 on axillary sentinel lymph nodes of breast carcinoma patients. *Ann Surg.* 2008;247:136–142.
35. Julian TB, Blumencranz P, Deck K, et al. Novel intraoperative molecular test for sentinel lymph node metastases in patients with early-stage breast cancer. *J Clin Oncol.* 2008;26:3338–3345.
36. Mansel RE, Goyal A, Douglas-Jones A, et al. Detection of breast cancer metastasis in sentinel lymph nodes using intra-operative real time GeneSearch BLN Assay in the operating room: results of the Cardiff study. *Breast Cancer Res Treat.* 2009;115:595–600.
37. Rayhanabad J, Yegiyants S, Putchakayala K, et al. Axillary recurrence is low in patients with breast cancer who do not undergo completion axillary lymph node dissection for micrometastases in sentinel lymph nodes. *Am Surg.* 2010;76:1088–1091.
38. Onishi T, Jinno H, Takahashi M, et al. Non-sentinel lymph node status and prognosis of breast cancer patients with micrometastatic sentinel lymph nodes. *Eur Surg Res.* 2010;45:344–349.
39. Rovera F, Frattini F, Chiappa C, et al. The role of micrometastatic disease in sentinel lymph node in breast cancer. *Breast J.* 2010;16(Suppl 1):S26–S28.
40. Reed J, Rosman M, Verbanac KM, et al. Prognostic implications of isolated tumor cells and micrometastases in sentinel nodes of patients with invasive breast cancer: 10-year analysis of patients enrolled in the prospective East Carolina University/Anne Arundel Medical Center Sentinel Node Multicenter Study. *J Am Coll Surg.* 2009;208:333–340.
41. Cox C, Centeno B, Dickson D, et al. Accuracy of intraoperative imprint cytology for sentinel lymph node evaluation in the treatment of breast carcinoma. *Cancer.* 2005;105:13–20.
42. Tew K, Irwig L, Matthews A, et al. Meta-analysis of sentinel node imprint cytology in breast cancer. *Br J Surg.* 2005;92:1068–1080.
43. Upender S, Mohan H, Handa U, et al. Intraoperative evaluation of sentinel lymph nodes in breast carcinoma by imprint cytology, frozen section and rapid immunohistochemistry. *Diagn Cytopathol.* 2009;37:871–875.

44. Hamidian Jahromi A, Narayanan S, MacNeill F, et al. Testing the feasibility of intra-operative sentinel lymph node touch imprint cytology. *Ann R Coll Surg Engl.* 2009;91:336–339.

45. Cutress RI, McDowell A, Gabriel FG, et al. Observational and cost analysis of the implementation of breast cancer sentinel node intraoperative molecular diagnosis. *J Clin Pathol.* 2010;63:522–529.