



UNIVERSITÀ DEGLI STUDI DI TORINO

This is an author version of the contribution published on:

Questa è la versione dell'autore dell'opera:

*[American journal of surgical pathology, 34 (7), 2010, DOI
10.1097/PAS.0b013e3181e2b726]*

*ovvero [Papotti M, Volante M, Duregon E, Delsedime L, Terzolo M, Berruti A, Rosai
J., 34 (7), [Lippincott, Williams & Wilkins](http://www.lww.com/journals/ajsp/pages/articleviewer.aspx?year=2010&issue=07000&article=00009&type=abstract), 2010, pagg.973-983]*

The definitive version is available at:

La versione definitiva è disponibile alla URL:

*[[http://journals.lww.com/ajsp/pages/articleviewer.aspx?year=2010&issue=07000&
article=00009&type=abstract](http://journals.lww.com/ajsp/pages/articleviewer.aspx?year=2010&issue=07000&article=00009&type=abstract)]*

**ADRENOCORTICAL TUMORS WITH MYXOID FEATURES:
A DISTINCT MORPHOLOGICAL AND PHENOTYPICAL VARIANT EXHIBITING
MALIGNANT BEHAVIOR**

**Mauro Papotti MD, Marco Volante MD, Eleonora Duregon MS, Luisa Delsedime MD*,
Massimo Terzolo MD, Alfredo Berruti MD, Juan Rosai MD§**

Department of Clinical & Biological Sciences, University of Turin at St Luigi Hospital, Orbassano,
Torino, *Division of Pathology, St Giovanni Hospital, Torino; §Genzyme Genetics, New York,
USA and Centro Diagnostico Italiano, Milan, Italy

Short title: Myxoid adrenocortical tumors

Grants: Work partially supported by grants from the Ministry of University, Rome (ex-60% and PRIN to MV, MT and AB) and from the Regione Piemonte (Progetto Ricerca Sanitaria Finalizzata, D.G.R. n. 35-4231, 06.11.2006 to MV).

Address correspondence to:

Mauro Papotti, MD Department of Clinical & Biological Sciences

University of Turin at St Luigi Hospital, Regione Gonzole 10, I-10043 Orbassano, Torino, Italy

Phone/ fax: +390116705432 Email address: mauro.papotti@unito.it

ABSTRACT

Myxoid changes have been rarely reported both in adrenocortical adenomas and carcinomas. The recent observation by our group of an adrenal myxoid tumor with morphologically borderline features but aggressive clinical behavior prompted us to review a series of 196 adrenocortical lesions, comprising 122 carcinomas and 74 adenomas, to define the morphological, phenotypical and clinical characteristics of adrenocortical tumors with myxoid features. Fourteen cases, including 12 carcinomas and 2 borderline tumors, formed the basis of this report, and were characterized by a variably abundant myxoid component (from 5% to 90% of tumor) and two distinct cellular growth patterns: the first (10 cases), mostly associated with a predominant myxoid stromal component, was made of small cells with mild atypia arranged in cords and microcysts; the second (4 cases) was characterized by focal myxoid changes in tumors otherwise similar to conventional adrenocortical carcinoma, with large atypical cells having an eosinophilic cytoplasm and a diffuse or nodular architecture. The above mentioned patterns were absent in all adenomas reviewed. A peculiar reactivity to neurofilaments was seen, mostly associated to the presence of predominant rather than focal myxoid stromal changes, as well as in 40% of conventional adrenocortical carcinomas, thus representing an undescribed potential pitfall in the differential diagnosis of adrenal lesions. Myxoid adrenocortical tumors probably represent a rare but histologically and phenotypically distinct entity and, although rare cases of benign lesions are on record, they seem to be generally associated to morphological and clinical features of malignancy.

KEY WORDS: Adrenal cortex, carcinoma, myxoid, neurofilaments, chemotherapy, mitotane

INTRODUCTION

Varying degrees of myxoid change have been reported in adrenocortical tumors (ACT), either as focal cell aggregates in an alcianophilic material of an otherwise conventional adrenocortical adenoma (ACA) or carcinoma (ACC), or - much more rarely - as pure myxoid tumors made of small-sized cell cords or pseudoglands embedded in an abundant extracellular myxoid matrix. Following the original report by Tang and coworkers (26), 32 functioning or non-functioning myxoid ACT have been described, including 18 adenomas, 13 carcinomas and one borderline case (3,4,6,7,9,10,13-17,19,23,25,30). Myxoid changes may also be present in pediatric ACT, judging from the images (Fig. 1D) shown in a recent review article (5).

While the overall immunoprofile of these tumors does not differ from that of conventional ACT (melan A, α -inhibin, synaptophysin and vimentin being generally expressed), the morphology of myxoid ACT is challenging, since several other tumor entities may enter in the differential diagnosis, and the application of the so-called Weiss criteria (28,29) may not be easy to apply to pure myxoid tumors due to the limited degree of atypia, lack of diffuse growth, and hard-to-assess sinusoidal invasion. To date, the treatment of these neoplasms is not different from that of conventional ACA and ACC, but the real nature of these myxoid variants is far from being understood. Indeed, it is not well established whether the myxoid changes represent a variant of either ACA or ACC, or if the myxoid changes by themselves point to a specific tumor type with a distinct biological behavior within the group of primary ACT.

A few years ago, some of us (MP, MT) reported a myxoid ACT lacking morphological signs of malignancy (Weiss score 1) that was interpreted as a myxoid ACA (3). Four years later, the patient developed a diffuse abdominal neoplastic spread which could not be resected. A fine needle aspiration biopsy of the mass showed a diffuse growth of small-medium size cells with hyperchromatic nuclei and no myxoid background. Originally this tumor was tentatively interpreted as a primary abdominal small round cell tumor (11), based on the focal expression of CD99 and

neurofilaments. However, the finding of adrenocortical marker expression (including melan A and α -inhibin) led to a revised diagnosis of metastatic ACT.

This prompted a review of all ACT filed at the San Luigi Hospital and University of Turin Medical School, which serves as a national referral center for ACC, with the aims of: a) identifying other pure or combined myxoid ACT; b) evaluating the immunoprofile of these neoplasms, with special reference to the expression of neural markers, in comparison with the expression profiles of normal adult and fetal adrenal glands; c) analyzing the clinical and pathological features of myxoid ACT, as compared to conventional ACA and ACC.

MATERIAL AND METHODS

Sample case (case #1) – In 2002, a 58-year-old male patient underwent resection of a well circumscribed right adrenal mass (55 g; 5 cm). Microscopically, a myxoid tumor with trabecular, microcystic and pseudoglandular growth patterns was found having a low Ki-67 proliferation index and an immune profile consistent with an adrenocortical origin. Based on the tumor size and the final Weiss score (28,29) of 1 (clear cell cytoplasm in less than 25% of tumor), a diagnosis of ACT of uncertain malignant potential with myxoid changes was made, and no additional treatment was administered. Two years later, this case was reported as an example of myxoid ACA (3). The patient was temporarily lost to follow up, but on December 2007 he reappeared complaining of abdominal pain. Imaging procedures revealed a large abdominal tumor partially engulfing the small intestine, with diffuse peritoneal carcinomatosis. A fine needle aspiration biopsy revealed a small round cell tumor devoid of myxoid material. The limited immunocytochemical panel performed at the time on the cell block was as follows: pancytokeratin negative, CD99 and neurofilaments positive (initially thought to support a diagnosis of intra-abdominal small round cell tumor), melan A and α -inhibin positive. The clinical and pathological findings were thought to be consistent with

abdominal spread of the myxoid ACT and the patient was treated with mitotane, but eventually died of his tumor in 2008, 68 months after the original diagnosis.

Myxoid ACT series (cases # 2 to 14) - From 1990 to 2009, 122 consecutive ACC were found in the pathology files of the University of Turin at San Luigi hospital, for which either glass slides or paraffin blocks were available for review. This series included 35 ACC resected at our hospital, 63 cases received in consultation from different Italian hospitals, and 24 ACC originally collected by one of us (MP) at the St Giovanni Hospital of Turin in years 1993-2003. The majority of these cases were treated at our Institution, which serves as a referral center for adrenocortical carcinoma in Italy. The group of ACA included 74 consecutive tumors diagnosed at our Institution during the same time-period. Twenty of them were characterized by the presence of either large size (> 5 cm) or a Weiss score of 1 or 2 (i.e. still in the benign range). The histopathological features of 92 ACC and of 47 ACA belonging to this data set have recently been reported (27).

Case review – All cases of ACC and ACA were reviewed by two of us (MP and MV) using a mean of 5.2 hematoxylin-eosin-stained slides per case (range 1-30) for the carcinomas and a mean of 3.2 slides per case for the adenomas (range 1-8). Before review, all tissue blocks were de-identified and coded by a pathology staff member not involved in the study, so that all cases were made anonymous to the investigators. In the group of ACA, no myxoid changes were identified, except for one case (case #2) represented by a 4 cm non-functioning tumor with a Weiss score of 1, which was diagnosed as a borderline ACT. In the group of ACCs, myxoid changes, either focal or extensive, were found in 12 cases (10%), which - together with the above described case #1 and the borderline case (case #2) – form the basis for this study. From all cases, clinico-pathological data (including information on treatment and outcome) were obtained and analysed. The study was approved by the local Review Board of our Institution.

Normal adrenal glands – In addition to the adrenal gland tissue present in the peritumoral peripheral areas of most cases, two apparently normal adrenal glands from adult patients operated

for renal cell carcinoma, one ectopic adrenal tissue incidentally found in the spermatic cord of a patient operated for testicular seminoma and 8 fetal adrenal glands (10-26 weeks of gestation from cases of spontaneous or therapeutic abortions) were also investigated, using the same markers applied to the tumors, as listed below. All tissue blocks were coded by a pathology staff member not involved in the study, so that all normal adrenal gland cases were made anonymous to the investigators.

Immunohistochemistry – Sections serial to those used for conventional hematoxylin-eosin and histochemical stains (Alcian blue and reticulin stains) were obtained from one or two representative tissue blocks of most cases (only the immunoprofile of cases # 6 and 8 could not be completely investigated). The following antibodies were employed: pan-cytokeratin (DakoCytomation, Glostrup, Denmark, clone AE1/AE3, diluted 1/100), vimentin (Dako, clone V9, diluted 1/350), melan A (Dako, clone A103, diluted 1/350), α -inhibin (Diamedix, Miami, USA, clone R1, diluted 1/75), synaptophysin (Dako, clone SY38, diluted 1/100), chromogranin A (Abcam, Cambridge, USA, clone LK2H10, diluted 1/500), Ki67 (Dako, clone MIB-1, diluted 1/150), neuron specific enolase (NSE; Neomarkers, Fremont, USA, clone E27, diluted 1/600), CD56 (Novocastra-Leica, Milan, Italy, clone 1B6, diluted 1/150), CD57 (Zymed, San Francisco, USA, clone NK-1, diluted 1/50), CD99 (Dako, clone MIC-2, diluted 1/100), synapsin (Novocastra, clone A10C, diluted 1/150), hASH1 (BD Pharmingen, San Diego, USA, clone 24BD72D11.1, diluted 1/150). Finally, total neurofilament proteins were tested either as a pool, including 68 kDa, 160 kDa, 200 kDa subunits, or as each single neurofilament subunit (subunit 68 kDa, Neomarkers, clone NR4, diluted 1/500; subunit 160 kDa, Progen, Ancona, Italy, clone NN18, diluted 1/100; subunit 200 kDa, Progen, clone NE14, diluted 1/500). Antigen retrieval procedure using microwave heating (3 five min passages at 750 Watt) in citrate buffer solution (pH 6.0) was performed for all antibodies. A biotin-free, dextran chain detection system (EnVysion, Dako) was used according to a standard procedure, and diaminobenzidine was employed as a chromogen. In case #2 and in a fetal adrenal

sample, a double immunohistochemical stain was performed to reveal melan A and neurofilaments in the same section, using sequential immunoperoxidase and immunoalkaline phosphatase detection systems, and 3-amino,9-ethylcarbazole and nitroblue tetrazolium salts, as chromogens, respectively.

The immunophenotype (namely neurofilaments) of myxoid tumors was compared to that of conventional ACC in a control group of 47 randomly selected ACC cases, using a tissue microarray (TMA).

RESULTS

Clinical data (Table 1) – The 14 tumors affected 5 males and 9 females, with a median age of 53 years (range 43-72). The tumors were located in the right adrenal gland in five cases and in the left gland in nine. The hormonal status was known for all patients, and a functioning tumor was found in 10 cases (71%). Cortisol production was the most common event (nine patients), while androgen production was observed in three patients (two of them had concomitant hypercortisolism). The tumors were generally large, ranging from 4 to 30 cm in largest diameter (mean 12.5 cm). The mean weight of the 12 tumors in which this information was available was 848 g, ranging from 20 to 3200 g.

The clinical history of case #1 case was reported above. The other borderline case (case #2) was a 52-year-old female patient who was recently found to be affected by a 4 cm non-functioning tumor of her left adrenal gland. The patient had no additional therapies after surgery and is under close follow up, being currently free of disease nine months after operation.

At the time of diagnosis, five patients had an early stage tumor, while seven had locally advanced or metastatic disease. All but two patients had surgery as primary treatment, attaining a radical resection in nine cases, who became disease-free. Surgery was also performed after diagnosis in four patients with metastatic disease: one of these had a radical resection of either primary or

metastatic disease, while in the remaining patients surgery was performed for tumor debulking purposes, in order to control the endocrine syndrome and/or favor the subsequent systemic therapy.

Except for the borderline tumors, a systemic antineoplastic treatment was administered to 11 of 12 patients (excluding case #11). Single agent mitotane was administered orally to five patients (3 of them had metastatic disease), tailoring the dose in each patient to attain and maintain circulating drug levels within the therapeutic range (14-20 ng/ml). Patients with metastatic ACC had disease progression despite mitotane therapy and did not receive concomitant chemotherapy because of their poor clinical conditions. Six other patients with metastatic disease received mitotane in combination with an etoposide, adriamycin and cisplatin (EDP-M) chemotherapy regimen (1). After six chemotherapy cycles, three patients showed a partial response (i.e. tumor shrinkage greater than 30%), one obtained a short lived (2 months) disease stabilization and one progressed. The remaining patient interrupted the treatment after 3 cycles due to disease progression. She was then addressed to a second line chemotherapy with gemcitabine, capecitabine and mitotane combination regimen, showing a clinical complete response of liver metastases and local recurrence at CT scan. She is presently disease-free after 22 months from the start of the second line treatment (case #13).

Among the five patients with early stage ACC who had radical surgery, one developed lung metastases (case #5) and one (case # 12) had a local recurrence after 6 months and 16 years, respectively. Patient #12 underwent a radical removal of her recurrence and commenced adjuvant mitotane treatment. At the last follow-up examination (January 2010), six patients are alive, while 6 patients died of disease; the median overall survival was 30 months (range 5-204).

Pathological features (Table 1) – The gross features of myxoid ACT were not significantly different from those of conventional ACC, except that in the pure forms there were translucent grey or white areas visible on gross inspection (**Figure 1**). Histologically, all 14 tumors exhibited a more or less abundant myxoid component, ranging from focal areas (approximately 5% of the tumor) to virtually the entire neoplasm. Within the myxoid background, two different cellular growth patterns were

recognized (**Figure 2**). The first was peculiar and was seen in ten cases, mostly associated with prominent myxoid changes. It was characterized by an homogeneous growth of small regular cells arranged in cords and microcysts, in some areas very reminiscent of adenoid cystic carcinoma. The second pattern, present in the remaining cases (all of which had a focal myxoid background) was characterized by a cellular growth similar and indeed merging with that of the conventional ACC component in terms of cell size (large), cell appearance (atypia, eosinophilic cytoplasm) and cell arrangement (lack of trabeculae and microcysts).

In summary, trabecular structure, cell type and tumor size (small *versus* large) distinguished two groups, as follows:

Myxoid ACC - Group 1 (cases #1 to #10) – Case #1 and #2 had small pseudoglandular structures or slightly larger microcysts containing an amorphous myxoid material. A trabecular architecture was focally recognized in both cases (10-15% of the tumor). Myxoid lakes were prominent in case #1, only. The tumor cells were mostly uniform and homogeneous, with scant lightly eosinophilic cytoplasm and lack of nuclear atypia, more reminiscent of *zona glomerulosa* cells than the large foamy cells of the other fasciculate layer. The mitotic index was very low. No necrosis was present in either case. All of the unfavorable morphological parameters of the Weiss scoring system were absent, except for the fact that clear cell cytoplasm was present in less than 25% of the tumor cells. Of the ACC present in this group (cases #3 to #10), a pure or predominant (>70%) myxoid pattern was seen in 4 cases (cases #3 to #6), while in the other four tumors (cases #7 to #10), only a limited amount (5-25%) of myxoid background was detected. In all cases, the myxoid background was associated to a trabecular, pseudoglandular or cribriform growth of small lightly eosinophilic cells. The extent of the myxoid background was highly variable, with extracellular material being abundant in some areas, where the cells were arranged in thin cords or isolated in the myxoid material. In some cases (such as case #3), a more solid growth was found, with an organoid (carcinoid-like) pattern and scant myxoid material surrounding the tumor nests. In another case

(case #8), a peculiar arrangement of cells in festoon-like structures surrounded by myxoid material was observed. Cell atypia was remarkably scant and cell size was small to medium, with the exception of one case (case #4) that, despite a similar architecture and prominent myxoid background, was huge (over 30 cm, 3200 g), aggressive (Weiss score 7), and characterized by atypical and deeply eosinophilic cells arranged in cords or small clusters or even isolated in a myxoid background. These features were also detected in the areas of tumor invasion of the perirenal adipose tissue. The extent of pleomorphism raised the alternative possibility of a sarcomatous tumor, such as myxoid chondrosarcoma, but the immunophenotype proved the adrenocortical origin of the tumor.

Conventional ACC with focal myxoid degenerative changes - Group 2 (#11 to #14) - This group of tumors was characterized by a myxoid component which never exceeded 20% of the lesion. It contained much larger cells with the eosinophilic cytoplasm and the nuclear atypias that one sees in conventional ACC, with which this myxoid component was actually intermingling. All of these cases were in the malignant category, with a Weiss score ranging from 4 to 9. As outlined in **Table 2**, except for the presence of focal stromal myxoid changes, tumors in Group 2 are very similar to conventional ACCs and more likely represent the result of degenerative myxoid changes rather than belong to the distinctive myxoid variant of ACTs described in Group 1 tumors.

Histochemical and immunohistochemical features - The myxoid areas were positive with the Alcian blue staining. In all malignant cases and in the morphologically borderline case (# 1), reticulin stain confirmed the stromal framework disruption, as recently reported by our group (27), while case #2 had an intact reticulin network. All tumors in this series shared the expression of the known markers of the adrenal cortex, namely melan A, α -inhibin, vimentin, and synaptophysin. Cytokeratin was expressed in 5/14 cases, always focally, except for case #2, in which there was a diffuse and strong immunoreactivity. The mean Ki-67 proliferation index was 31.8% in malignant cases (# 3-14) and only 3 and 4% in the borderline cases # 1 and 2, respectively. A peculiar expression of

neurofilaments (as diffuse cytoplasmic, or small paranuclear dots) was observed in 50% of the cases, and was associated more to the extent of myxoid changes (all but one positive cases with predominant myxoid features) (**Figure 3**), rather than to the cellular subgroups (Group 1 vs Group 2 tumors). Such reactivity was observed using an antibody to total neurofilament proteins, and it was confirmed using antibodies selective for the different neurofilament subunits. In particular, while no signal was found for the 200 kDa neurofilament subunit and only rare tumor cells reacted for the 160 kDa subunit, all cases expressed the 68 kDa subunit protein, with a pattern similar to that above described. As revealed with the double immunostaining procedure, neurofilaments were co-expressed with the adrenocortical marker melan A in the tumor cells (**Figure 3**). In the control cases, 17 of 47 conventional ACCs (40.4%) were found to express neurofilaments, with a focal paranuclear dot-like reactivity in 12 (25.2%) tumors and a granular cytoplasmic positivity in up to 25% of tumor cells of the remaining seven neoplasms. By contrast, no neurofilament reactivity was seen in ACA. As described above, CD99 was positive in the recurrent lesion of case #1 but not in the corresponding primary lesion nor in any other case of the series tested, including the control ACC TMA cases.

The unexpected expression of a neural and neuroendocrine marker in a mesodermally derived tumor, paralleled by the known expression of synaptophysin by ACC, prompted the investigation of further neural or neuroendocrine markers. Of these, only CD56 was intensely expressed in all cases (although it was also focally or diffusely expressed in up to 90% of conventional ACC; Volante & Papotti 2009, unpublished observation), whereas no reactivity was found for synapsin (except for a single case with focal reactivity), CD57, chromogranin A, or hASH1, the latter being a transcription factor of the Notch pathway that regulates neuroendocrine differentiation during development.

Comparison with the immunophenotype of the normal adrenal gland – The adult and fetal adrenal glands showed the expected immunoprofile, with melan A and α -inhibin expression in the cortex and neuroendocrine marker reactivity in the medulla. No neuroendocrine marker (chromogranin A,

NSE, CD57, CD56 and hASH1) reactivity was seen in the adult or fetal adrenal cortex, with the exception of synaptophysin (present in both fetal and adult cortex) and of neurofilaments. The latter were expressed only in extremely rare cells of the *zona glomerulosa* of a single adult adrenal gland (case #2), all other adult adrenal gland tissue being negative. However, a strong neurofilament reactivity was found in small cells arranged singly or in small clusters in the peripheral layers of all 8 fetal adrenal cortices investigated (**Figure 3**). There was a slight decrease of the number of reactive cell with increase of the gestational age. The type of neurofilaments expressed in individual adrenal cortical cells was mostly the 68 kDa subunit. There were very rare cells which also stained for the 160 (but not the 200) kDa subunit, paralleling the reactivity above described in the myxoid tumors.

DISCUSSION

In this study, we describe the clinico-pathological and immunophenotypic features of 14 ACT having varying degrees of distinctive myxoid features. Most of these cases had malignant features, with a Weiss score of 1 found in two cases only, one of the cases eventually displaying an aggressive clinical course with fatal outcome.

In a review of a large series of ACC at our Institution, myxoid features were observed in approximately 10% of the cases and accounted for 5 to 90% of the tumor cell population in individual cases, being in general associated and often intermingled with areas of conventional ACC. This wide variability in the extent of the myxoid component was associated to distinctive growth patterns, which have been only partially addressed in previous reports. In the literature, the extension of myxoid changes in single tumors has only been reported by Brown and coworkers (4), who indicated a variable percentage of myxoid areas (from 10 to 95%) in their 14 tumors, these changes being generally higher in the benign cases. In another single case report (17), large pools of

myxoid material were described which involved most of the tumor.

Morphological features – Although the appearance of the myxoid background was not different from that of a variety of human tumors with myxoid features, i.e. mostly characterized by more or less extensive areas of extracellular accumulation of light basophilic amorphous material, the cell population present within the myxoid material had distinctive characteristics in our series. In some cases (Group 2 - # 11 to 14), the tumor cells were very similar to those of conventional ACC, i.e. large, irregularly shaped and deeply eosinophilic. The nuclei were large, atypical, and with prominent nucleoli. These cells were arranged in irregular nests or cords and merged with areas of conventional ACC having a diffuse growth pattern. In our view, these cases represent classical ACC having more or less extensive (5 to 20% of the tumor area) accumulation of myxoid material, probably as a result of focal intratumoral degenerative changes. The other cases (Group 1 - #1 to #10) had a different architecture and apparently form a separate group of ACT having distinctive histological features, already recognized by some workers (4). These tumors had a relatively homogeneous growth pattern made of small-to-medium sized cells with minimal atypia, arranged in thin trabeculae, pseudoglands or small cysts, resembling the patterns of adenoid-cystic carcinoma in a more or less abundant myxoid stroma. With regard to the malignant cases, the well known features of classical ACC, as summarized in the nine Weiss score parameters, were not readily apparent, with the exception of “dark” cell cytoplasm, mitotic figures, and necrosis. The other Weiss score parameters could be identified in a variable percentage, but some of these criteria were hard to assess in the myxoid areas. Among them, small vessel invasion was less apparent due to the myxoid background, and diffuse growth pattern was never a feature in these tumors, whereas atypia was minimal or absent. For these reasons, and as already reported for other ACC variants, such as the oncocytic ACC (2) or the pediatric ACCs (5), Weiss criteria might be inadequate to reliably detect malignancy in myxoid ACC. Moreover, when these distinctive morphological features are predominant in an adrenal tumor, the differential diagnosis should include several types

of metastatic tumors, including breast carcinoma, salivary or skin adnexal carcinomas of the adenoid cystic type, and neuroendocrine tumors. All of these tumors are potentially capable of giving metastatic spread to the adrenal gland, and an immunohistochemical marker profile is therefore mandatory.

Immunophenotype - The immunohistochemical profile of both the conventional ACC with a myxoid component (Group 2) and the pure myxoid ACT (Group 1) is similar to that of classical ACC. Thus, melan A and α -inhibin are regularly present in myxoid tumors, as is synaptophysin (12,18). A correct definition of the adrenocortical origin can therefore be obtained in all cases, irrespective of their myxoid material content. Focal or diffuse cytokeratin expression was observed in approximately 60% of cases, while in all (except case # 2) tumors, the reticulin stain demonstrates architectural disruption, which was recently described as a major marker of ACC (27). The Ki-67 proliferation index in myxoid ACC was not different from that of conventional ACC, being on average 31.8% in malignant cases as opposed to 3 and 4% in the borderline cases, respectively.

A distinctive feature was the expression of neurofilament proteins in the small cell, pseudoglandular or trabecular areas of cases having a predominant (i.e. > 70% of tumor) myxoid component (#1 to #6), in a fraction of tumor cells generally not exceeding 15-25% of the tumor population (with the exception of case # 2). Neurofilaments were generally absent in cases with only focal myxoid stromal component, with the exception of cases #10, 11 and 13, which showed focal neurofilaments reactivity in single cells. Neurofilament expression in ACC has been reported previously in the Literature only once and in a limited series of cases, apparently without any association with specific morphological features (20). As a matter of fact, neurofilament expression is instead considered a marker of adrenal medullary cells and their tumors. To test whether neurofilament expression was restricted to the myxoid and small cell ACC here described, a series of conventional ACC was tested and neurofilaments were found to be expressed in 19/47 cases

(40.4%). The extent of the reactivity was mostly focal (12 cases) and restricted to a small paranuclear dot, but seven cases had a more diffuse, finely granular cytoplasmic positivity in up to 25% of the tumor cells. These findings indicate that neurofilament expression is characteristic of predominantly myxoid ACCs, but that it also occurs in a fraction of conventional ACC, thus expanding the list of neural and neuroendocrine markers detected in adrenocortical cells and tumors, such as synaptophysin (12,18). Whether ACC in general and its myxoid variants in particular are tumors having a divergent differentiation towards endocrine (steroid-producing) and neuroendocrine lineages is not known. Along these lines, other neuroendocrine markers were tested in the current cases (as well as in the fetal normal glands), including chromogranin A, synapsin, CD57 and CD56. Only the latter was found positive in all tested cases, but it is known that CD56 is highly expressed in normal adrenal cortex and derived tumors (22,24). It is worth noting, however, that in focally myxoid tumors the expression of neurofilaments and CD56 was mostly restricted to the myxoid areas. To further explore the neural/neuroendocrine phenotype of these rare myxoid tumors, the expression of transcription factors driving neuronal and endocrine differentiation during the embryonal life and in some neuroendocrine tumors was also assessed, with special reference to hASH1 (human achete scute homologue 1), but no immunoreactivity was found for this marker in any tumor.

Interestingly, although the peritumoral adrenal cortex of the current cases was totally unreactive to neurofilaments (with the exception on scattered cells in case #2), a consistent immunoreactivity was observed in subcapsular cortical isolated cells or clusters of the fetal adrenal gland when antibodies specific to the 68 and 160 kDa neurofilament subunits were employed. A similar observation had already been mentioned in an old study on fetal and adult human adrenal medullary cells, in which the authors quoted as a “*peculiar phenomenon*” the expression of medium molecular weight neurofilament subunits through all adrenocortical developmental stages and also in the adult adrenal cortex (21).

Clinical features – Most myxoid ACT (71%) in our series were functioning malignant neoplasms, with greater frequency of Cushing-related symptoms. The rate of functioning tumors of the present series is in line with the literature data on the 13 currently reported malignant ACC with myxoid features (3-5,12,18,28) and is higher than that generally recorded in conventional ACC, ranging from less than 50% in our experience (27) to 60% in the literature (8). Unfortunately, from the literature review, it seems that some heterogeneity exists in the reported cases, in that some of these cases probably represent examples of conventional ACC having focal myxoid changes and containing large eosinophilic atypical cells. The true clinical behavior of pure myxoid ACA and ACCs is difficult to assess. Brown et al (4) reported 14 cases, comprising 6 benign and 8 malignant tumors. The latter (which had myxoid areas in 10 to 60% of the tumor mass) followed an aggressive course in 50% of cases. However, the benign tumors had frequently a large size (>5 cm in four cases), questionable capsular invasion (in four cases) and a mitotic activity potentially exceeding the cutoff of 5/50HPF (four cases had one or more mitoses in 10 HPF). In the present series, a case originally considered of borderline malignancy (Weiss score 1) developed peritoneal spread and eventually killed the patient five years after diagnosis. The 12 ACC cases had a Weiss score of 3 to 9 and metastatic disease at diagnosis in five instances. With regard to the outcome data, in the absence of a comparable control group, it is difficult to state whether patients with ACT with myxoid features have a survival different from unselected ACC patients, and the responsiveness of myxoid ACT to systemic chemotherapy (8) warrants further testing.

In conclusion, myxoid changes rarely occur in ACT. They are identified most frequently in malignant or borderline tumors, and are associated to two distinctive cellular growth patterns, one similar to conventional ACC, and the other representing a morphologically distinct entity made up of small-to-medium sized cells with minimal atypia, arranged in trabecular, pseudoglandular or small cystic spaces in a myxoid background which may represent up to 90% of the tumor cell population. Their immunoprofile overlaps with that of conventional ACTs. Interestingly,

neurofilament expression, only focally and inconsistently present in conventional ACC, emerged as a distinctive feature of predominantly myxoid tumors, and was paralleled by a similar neurofilament reactivity in the normal fetal adrenal cortex, too.

ACKNOWLEDGEMENTS: We are grateful to dr. G. Fadda (Catholic University, Rome) for providing histological material of case #11 and to dr. E. Bollito (San Luigi Hospital, Orbassano) for helpful discussion.

REFERENCES

1. Berruti A, Terzolo M, Sperone P, et al. Etoposide, doxorubicin and cisplatin plus mitotane in the treatment of advanced adrenocortical carcinoma: a large prospective phase II trial. *Endocr Relat Cancer*. 2005;12:657-666
2. Bisceglia M, Ludovico O, Di Mattia A, et al. Adrenocortical oncocytic tumors: report of 10 cases and review of the literature. *Int J Surg Pathol*. 2004;12:231-243
3. Bollito ER, Papotti M, Porpiglia F, et al. Myxoid adrenocortical adenoma with a pseudoglandular pattern. *Virchows Arch*. 2004;445:414-418
4. Brown FM, Gaffey TA, Wold LE, et al. Myxoid neoplasms of the adrenal cortex: a rare histologic variant. *Am J Surg Pathol*. 2000;24:396-401
5. Dehner LP, Hill DA. Adrenal cortical neoplasms in children: why so many carcinomas and yet so many survivors? *Pediatr Dev Pathol*. 2009;12:284-291
6. De Padua M, Rajagopal V. Myxoid adrenal adenoma with focal pseudoglandular pattern. *Indian J Med Sci*. 2008;62:199-203

7. Dundr P, Novák K. Pseudoglandular myxoid adenoma of the adrenal gland. *Pathol Res Pract.* 2003;199:493-496
8. Fassnacht M, Allolio B. Clinical management of adrenocortical carcinoma. *Best Pract Res Clin Endocrinol Metab.* 2009;23:273-289
9. Fine SW, Pindzola JA, Uhlman EJ, et al. Pathologic quiz case: a 64-year-old man with an adrenal mass. Myxoid adrenal cortical neoplasm. *Arch Pathol Lab Med.* 2005;129:541-542
10. Forsthoefel KF. Myxoid adrenal cortical carcinoma. A case report with differential diagnostic considerations. *Arch Pathol Lab Med.* 1994;118:1151-1153
11. Gerald WL, Miller HK, Battifora H, et al. Intra-abdominal desmoplastic small round-cell tumor. Report of 19 cases of a distinctive type of high-grade polyphenotypic malignancy affecting young individuals. *Am J Surg Pathol.* 1991;15:499-513
12. Haak HR, Fleuren GJ. Neuroendocrine differentiation of adrenocortical tumors. *Cancer.* 1995;75:860-864
13. Honda K, Kashima K, Daa T, et al. Myxoid adrenal cortical adenoma. *Pathol Int.* 2001;51:887-891

14. Izumi M, Serizawa H, Iwaya K, et al. A case of myxoid adrenocortical carcinoma with extensive lipomatous metaplasia. *Arch Pathol Lab Med.* 2003;127:227-230
15. Ishida M, Yoshida K, Miyamoto K, et al. Cytological features of myxoid adrenocortical adenoma with a pseudoglandular component: a case report with differential diagnostic considerations. *Diagn Cytopathol.* 2008;36:576-580
16. Jang KY, Chung MJ, Moon WS, et al. Adrenocortical adenoma with unusual myxoid histological pattern: a case report. *Pathology.* 2009;41:188-191
17. Karim RZ, Wills EJ, McCarthy SW, et al. Myxoid variant of adrenocortical carcinoma: report of a unique case. *Pathol Int.* 2006;56:89-94
18. Komminoth P, Roth J, Schröder S, et al. Overlapping expression of immunohistochemical markers and synaptophysin mRNA in pheochromocytomas and adrenocortical carcinomas. Implications for the differential diagnosis of adrenal gland tumors. *Lab Invest.* 1995;72:424-431
19. Lu HS, Gan MF, Chen HS, et al. Adrenal myelolipoma within myxoid cortical adenoma associated with Conn's syndrome. *J Zhejiang Univ Sci B.* 2008;9:500-505.
20. Miettinen M. Neuroendocrine differentiation in adrenocortical carcinoma. New immunohistochemical findings supported by electron microscopy. *Lab Invest.* 1992;66:169-174.

21. Molenaar WM, Lee VM, Trojanowski JQ. Early fetal acquisition of the chromaffin and neuronal immunophenotype by human adrenal medullary cells. An immunohistological study using monoclonal antibodies to chromogranin A, synaptophysin, tyrosine hydroxylase, and neuronal cytoskeletal proteins. *Exp Neurol.* 1990;108:1-9

22. Muench MO, Ratcliffe JV, Nakanishi M, et al. Isolation of definitive zone and chromaffin cells based upon expression of CD56 (neural cell adhesion molecule) in the human fetal adrenal gland. *J Clin Endocrinol Metab.* 2003;88:3921-3930

23. Raparia K, Ayala AG, Sienko A, et al. Myxoid adrenal cortical neoplasms. *Ann Diagn Pathol.* 2008;12:344-348

24. Shigematsu K, Nishida N, Sakai H, et al. Synaptophysin immunoreactivity in adrenocortical adenomas: a correlation between synaptophysin and CYP17A1 expression. *Eur J Endocrinol.* 2009;161:939-945

25. Suresh B, Kishore TA, Albert AS, et al. Myxoid adrenal cortical carcinoma--a rare variant of adrenocortical carcinoma. *Indian J Med Sci.* 2005;59:505-507

26. Tang CK, Harriman BB, Toker C. Myxoid adrenal cortical carcinoma: a light and electron microscopic study. *Arch Pathol Lab Med.* 1979;103:635-638

27. Volante M, Bollito E, Sperone P, et al. Clinicopathological study of a series of 92 adrenocortical carcinomas: from a proposal of simplified diagnostic algorithm to prognostic stratification. *Histopathology*. 2009;55:535-543
28. Weiss LM. Comparative histologic study of 43 metastasizing and nonmetastasizing adrenocortical tumors. *Am J Surg Pathol*. 1984;8:163-169
29. Weiss LM, Medeiros LJ, Vickery AL Jr. Pathologic features of prognostic significance in adrenocortical carcinoma. *Am J Surg Pathol*. 1989;13:202-206
30. Zhu Y, Wu YX, Zhang CY, et al. Myxoid adrenocortical adenoma: a case report. *Chin Med J (Engl)*. 2008;121:1598-1600

FIGURE LEGENDS

Figure 1 - Gross features of case # 1 (a) showing a well circumscribed yellowish mass having extensive translucent appearance, corresponding to the myxoid areas observed in the low power view of the tumor (b) in which microcystic spaces contain basophilic material. A huge adrenocortical carcinoma (case #10) (c) has extensive necrotic areas and a solid whitish portion (top) with translucent appearance, which corresponds to the myxoid lakes found at the microscopic level (d). [Hematoxylin & Eosin, original magnification 100x in b, 200x in d].

Figure 2 – Pure myxoid tumors are made of cords or small glands or cysts of small uniform cells (a-b) with more or less extensive myxoid background. In some cases, tumor nests and cords contain myxoid material and small-medium size cells with minimal atypias (c). This architecture can also be detected in small biopsy samples, as in the case # 6, predominantly characterized by small eosinophilic cells in a myxoid matrix (d). Conventional adrenocortical carcinomas having focal myxoid changes may show areas of transition from classical solid and diffuse growth (e, bottom-left) to myxoid pattern (e, top-right). The extent of myxoid material accumulation is variable and cells are generally isolated or in small cords (f). Cytologically, remarkable atypias are generally present in large eosinophilic cells growing in the myxoid background (g). [Hematoxylin & Eosin, original magnification 100x in a, 200x in b-c-e, 400x in d-f; 600x in g].

Figure 3 – Immunoreactivity for Melan A in a peripheral area of case # 2 including adrenal cortex (a, left) and small strongly reactive tumor cells in pseudoglands and microcysts (a, right). The same tumor area is also intensely expressing neurofilament proteins in most cells (b). In the same case, a double immunohistochemical stain for Melan A (brown color) and neurofilaments (blue color) revealed a co-expression of these markers in the same cells (a-b, inset). An adrenocortical carcinoma

with focal myxoid changes has neurofilament reactivity mostly restricted to the myxoid component (c, bottom-right; same case as Fig 1d). In fetal adrenal gland at 12 week gestation, the cortex is diffusely positive for Melan A (d), while some subcapsular cells of an adjacent section are neurofilament reactive in thin cytoplasmic protrusions or in a paranuclear dot or cap (e). [Immunoperoxidase, original magnification 100x in a-c, 200x in d-e. Inset: double immunoperoxidase and alkaline phosphatase, 600x].

Table 1. Clinical and pathological features of myxoid adrenocortical neoplasms.

#	Sex/ age	Hormonal status	Site	Stage	Surgery	Weight (g)	Size (cm)	Diagnosis	Myxoid area (%)	Growth pattern (predominant)	Weiss score	Ki-67 (%)	NF IHC	Mitotane/ other	Rec/mets	Status (months)
GROUP 1 – MYXOID ADRENOCORTICAL TUMORS																
1	M/58	NF	R	1	radical	55	5	T-UMP	90	trabecular, microacinar	1	4	+ foc	mit^	local & peritoneal (60mos)	DOD 68
2	F/52	NF	L	1	radical	20	4	T-UMP	90	trabecular, microacinar	1	3	+	-	-	NED 9
3	F/72	cort/andr	L	4	non rad	200	9	ACC	70	trabecular	5	70	-	mit	lung (at dx)	DOD 18
4	M/43	cortisol	L	1	radical	3200	30	ACC	90	trabecular, solid	7	15	+	mit	-	NED 9
5	M/47	NF	L	2	radical	1000	25	ACC	85	trabecular, solid	7	na	+	EDP+mit	local, liver, lung (6mos)	DOD 33
6	F/70	cort/andr	R	4	no	(biopsy)	na	ACC	75	trabecular	na	na	na	mit	liver, lung, bone (at dx)	DOD 5
7	M/66	cortisol	L	4	non rad	250	9	ACC	15	conv & focal trabecular	8	35	-	mit	lung (at dx)	DOD 8
8	F/60	cortisol	L	4	radical	60	5	ACC	20	conv & focal trabecular	4	20	-	EDP+mit	local & lung (14mos)	DOD 29
9	F/43	cortisol	L	4	non rad	700	10	ACC	5	conv & focal trabecular	8	50	-	EDP+mit	lung (at dx)	AWD 8
10	F/53	NF	L	4	radical§	3000	28	ACC	20	conv & focal trabecular	9	30	+ foc	EDP+mit	lung (at dx)	NED 9
GROUP 2 – CONVENTIONAL ACC WITH FOCAL MYXOID DEGENERATIVECHANGES																
11	M/43	cortisol	R	1	radical	60	5	ACC	20	solid, atypias	4	5	+ foc	-	-	NED 9
12	F/52	cortisol	L	2	radical#	300	10	ACC	20	solid, atypias	5	40	-	mit	local (192mos)	NED 204
13	F/53	cortisol	R	2	radical	250	10	ACC	10*	solid, atypias	6	35	+ foc	EDP+mit	local & liver (3mos)	NED 36
14	F/68	androgens	L	3	radical	260	10	ACC	5	solid, atypias	9	25	-	EDP+mit	local (6mos), liver, lung (7mos)	DOD 15

Abbreviations: M: male; F: female; NF: non functioning; cort: cortisol; andr: androgens; R: right; L: left; non rad: non radical surgery; §: surgery performed after chemotherapy; #: after local recurrence, the patient underwent a second radical surgery and adjuvant mitotane; na: not available; T-UMP: tumor of uncertain malignant potential; ACC: adrenocortical carcinoma; *: both primary and local recurrence; conv: conventional ACC growth patterns; NF: neurofilaments; IHC: immunohistochemistry; foc: focal; mit: mitotane; ^: administrated at the time of tumor recurrence and progression; EDP: etoposide, doxorubicin, cisplatin
mos: months; at dx: at diagnosis; NED: no evidence of disease, AWD: alive with disease; DOD: died of disease.

Table 2. Distinctive features of myxoid ACC and conventional ACC with focal myxoid changes

Myxoid ACC (Group 1, cases #1-10)	<i>Pathological feature</i>	Conventional ACC with focal myxoid degenerative changes (Group 2, cases #11-14)
Separated from conventional areas if any, extensive in 6/10 cases	<i>Type of myxoid changes</i>	Merged with conventional ACC areas, and always focal (<20% of the tumor area)
Usually trabecular, microacinar	<i>Growth pattern</i>	As conventional ACC, usually solid/diffuse
Small, uniform	<i>Cell size</i>	Large, heterogeneous
Mild*	<i>Nuclear atypia</i>	Moderate to high
Scant, eosinophilic	<i>Cell cytoplasm</i>	Abundant, granular eosinophilic
Present in 5/9 cases, generally diffuse	<i>Neurofilament expression</i>	Present in 2/4 cases, focal

Notes. ACC: adrenocortical carcinoma; *: high in case #4.

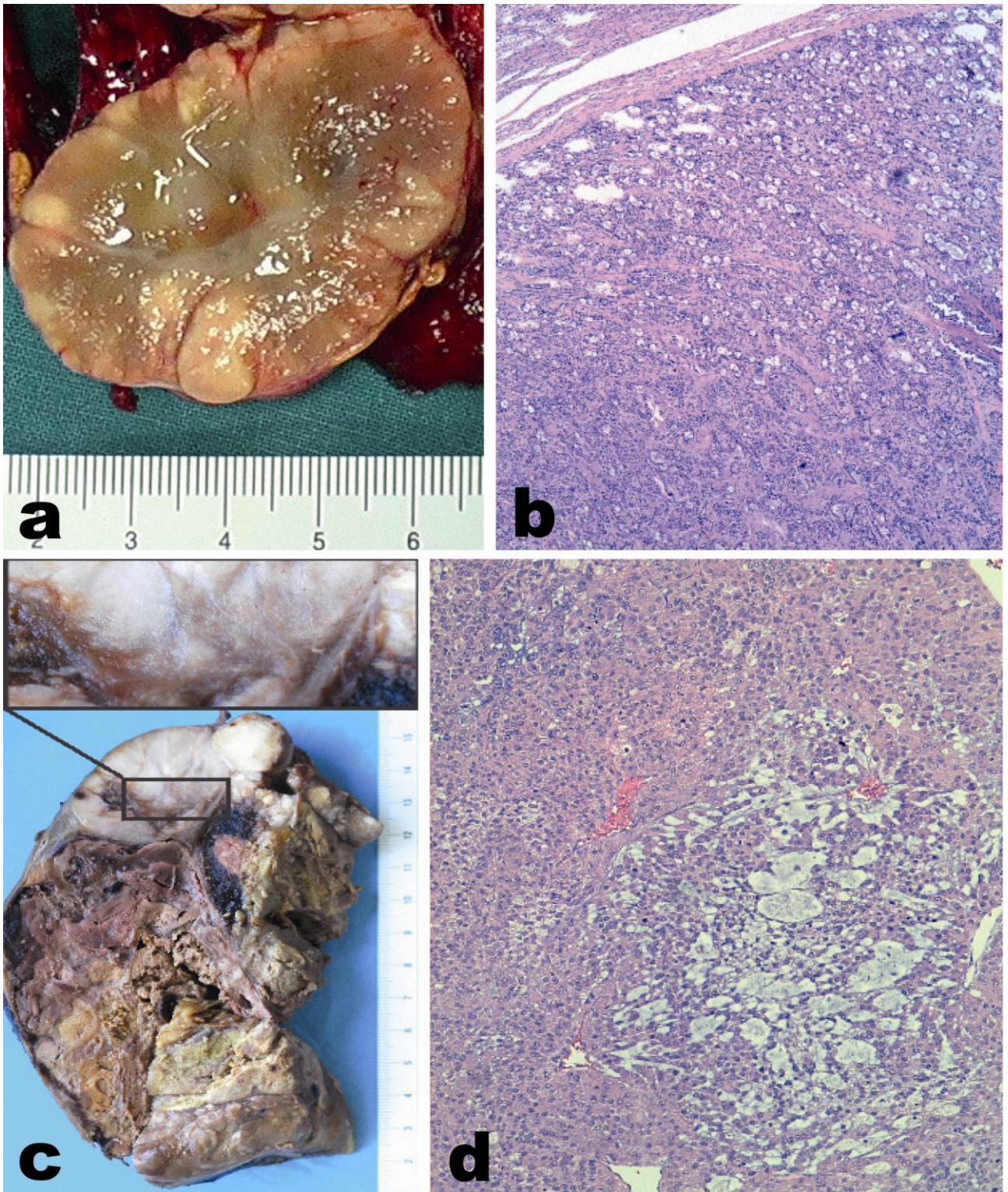


FIGURE 1

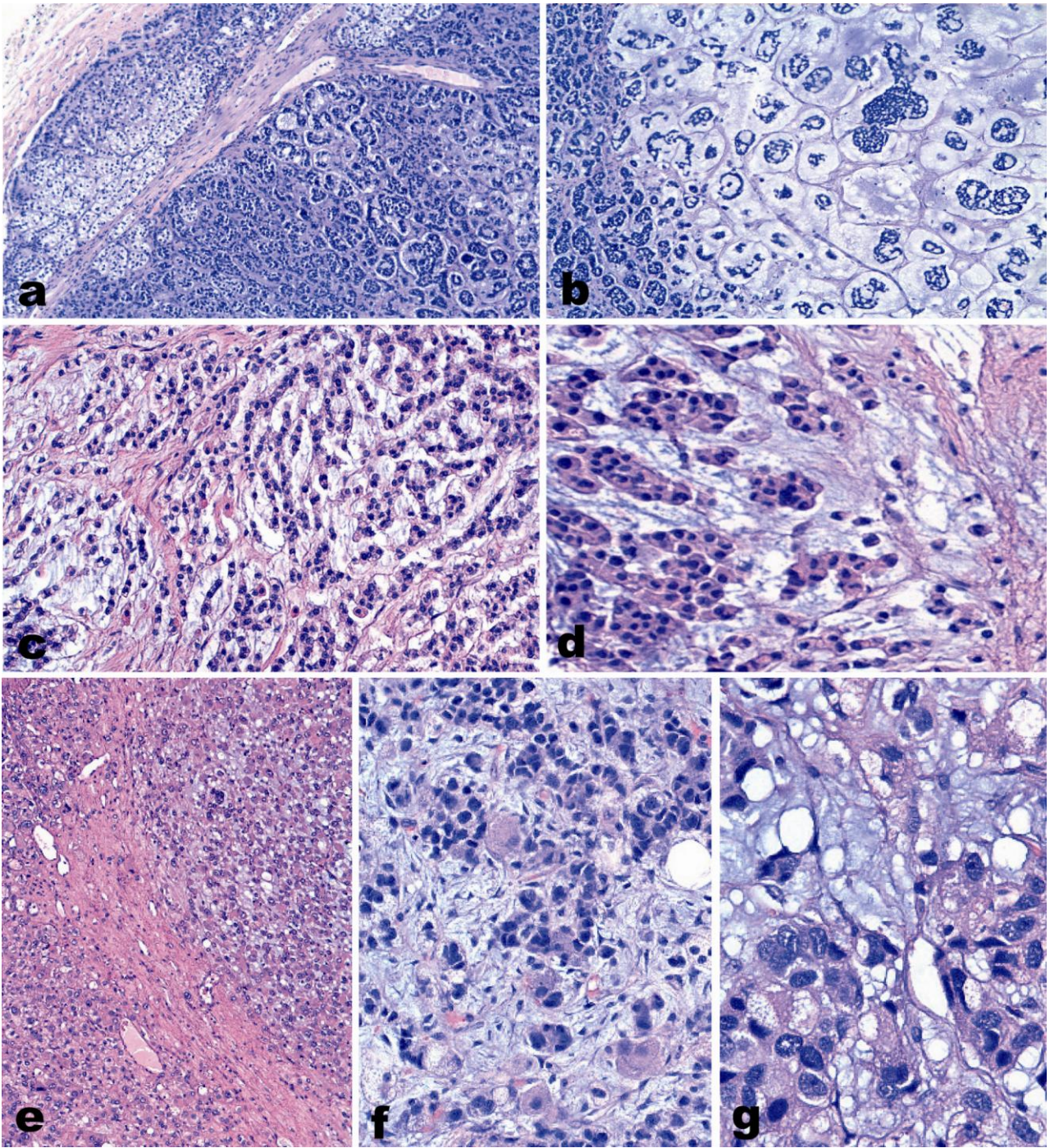


FIGURE 2

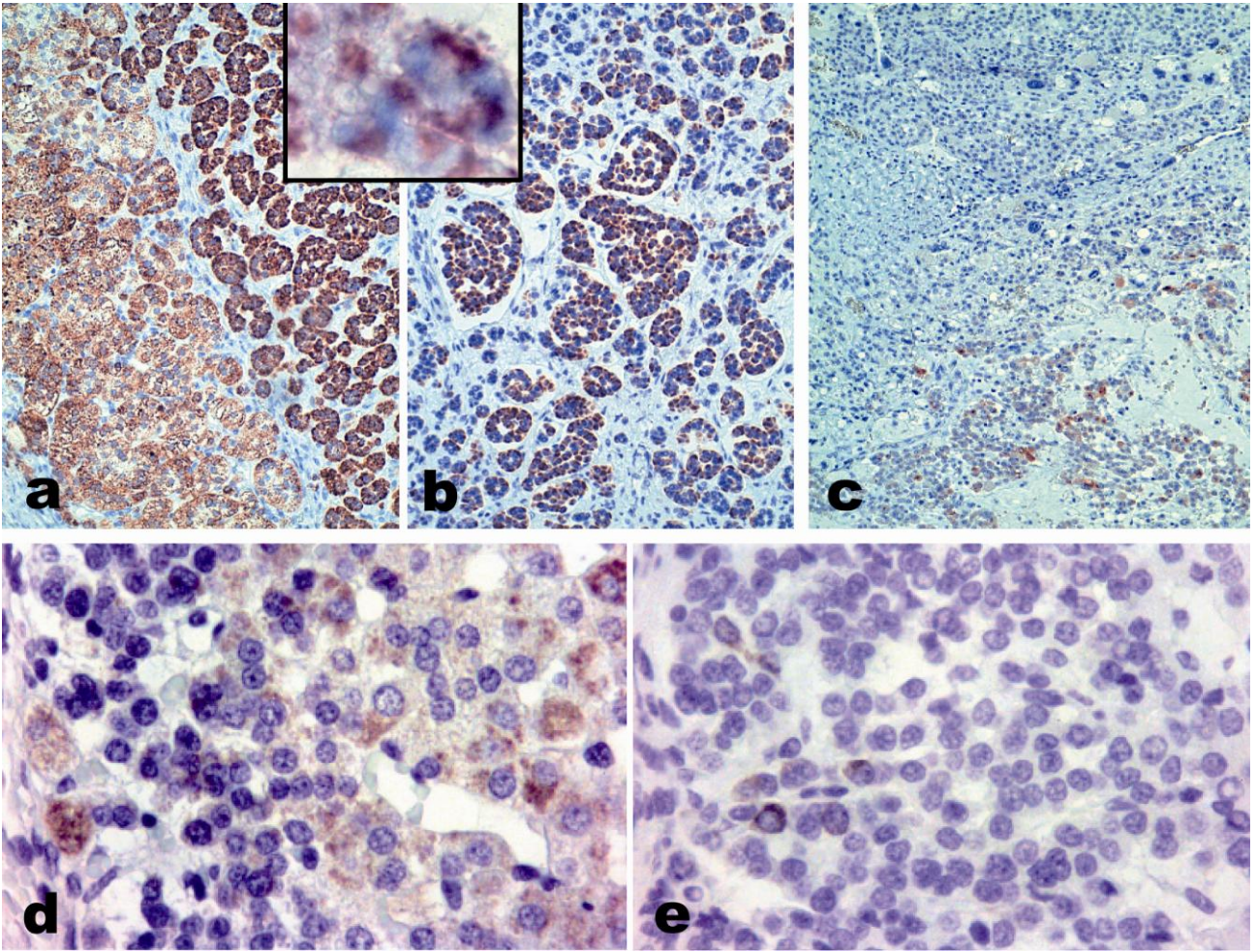


FIGURE 3