

AperTO - Archivio Istituzionale Open Access dell'Università di Torino

**TNF-alpha TGF-beta2 and IL-1beta levels in gingival and peri-implant crevicular fluid before and after de novo plaque accumulation**

**This is the author's manuscript**

*Original Citation:*

*Availability:*

This version is available <http://hdl.handle.net/2318/44033> since

*Terms of use:*

Open Access

Anyone can freely access the full text of works made available as "Open Access". Works made available under a Creative Commons license can be used according to the terms and conditions of said license. Use of all other works requires consent of the right holder (author or publisher) if not exempted from copyright protection by the applicable law.

(Article begins on next page)

# TNF- $\alpha$ TGF- $\beta$ 2 and IL-1 $\beta$ levels in gingival and peri-implant crevicular fluid before and after de novo plaque accumulation

Gianmario Schierano<sup>1</sup>, Giovanni Pejrone<sup>1</sup>, Paola Brusco<sup>1</sup>, Antonella Trombetta<sup>2</sup>, Germana Martinasso<sup>2</sup>, Giulio Preti<sup>1</sup> and Rosa Angela Canuto<sup>2</sup>

<sup>1</sup>Department of Biomedical Sciences and Human Oncology, Section of Prosthetic Dentistry, School of Dentistry, University of Turin, Turin, Italy; <sup>2</sup>Department of Experimental Medicine and Oncology, University of Turin, Turin, Italy

Schierano G, Pejrone G, Brusco P, Trombetta A, Martinasso G, Preti G, Canuto RA. TNF- $\alpha$  TGF- $\beta$ 2 and IL-1 $\beta$  levels in gingival and peri-implant crevicular fluid before and after de novo plaque accumulation. *J Clin Periodontol* 2008; 35: 532–538. doi: 10.1111/j.1600-051X.2008.01224.x.

## Abstract

**Aims:** The aim of this split-mouth study was to investigate levels of tumour necrosis factor alpha (TNF- $\alpha$ ), transforming growth factor beta (TGF- $\beta$ 2) and interleukin-1 beta (IL-1 $\beta$ ) in gingival crevicular fluid (GCF) and peri-implant crevicular fluid (PICF) after a 21-day-period of de novo plaque accumulation in the same patient.

**Material and Methods:** In 25 patients, samples of GCF and PICF were collected in the sulcus of the tooth and of the implant after professional hygiene. After the no-hygiene phase (21 days), second samples of GCF and PICF were taken. Third samples were collected after 69 days of re-establishment oral hygiene techniques. The crevicular fluids were used to determine the volume and the levels of TNF- $\alpha$ , TGF- $\beta$ 2 and IL-1 $\beta$ .

**Results:** The volume of the crevicular fluids increased significantly after 21 days of plaque accumulation around teeth and implants and decreased significantly by 69 days. TNF- $\alpha$  and TGF- $\beta$ 2 did not change significantly among the three different samples. A significant increase of IL-1 $\beta$  was observed after plaque accumulation around the teeth GCF, whereas in the PICF the increase was not statistically significant.

**Conclusions:** These data suggest that increased volumes of GCF and PICF could be useful markers of early inflammation in gingival and peri-implant tissues. In the presence of de novo plaque, implants showed lower, and nearly significant, levels of IL-1 $\beta$  compared with teeth.

Key words: crevicular fluid; cytokine; gingivitis; peri-implant mucositis; plaque

Accepted for publication 13 February 2008

Clinical trials and animal experiments have demonstrated that plaque accumulation around dental implants can result in the development of an inflammatory

reaction in the peri-implant mucosa (Pontoriero et al. 1994, Moon et al. 1999, Zitzmann et al. 2001, Gualini & Berglundh 2003, Quirynen et al. 2007). The initiation and early development of the lesion can be induced by bacterial metabolites, such as proteolytic enzymes, by cell surface molecules, like lipopolysaccharides (LPS), or by host cells that release several types of cytokines that can activate degradative pathways (Birkedal-Hansen et al. 1988, Birkedal-Hansen 1993, Okada & Murakami 1998, Delaleu & Bickel 2004,

Orozco et al. 2006). Some researches indicate that the tissue damage is caused more by the host response, rather than from direct bacterial action (Golub et al. 1997, Graves & Cochran 2003, Rathe et al. 2007).

Recent studies show that in periodontal and peri-implant tissues, cytokines such as interleukin-1 beta (IL-1 $\beta$ ), tumour necrosis factor alpha (TNF- $\alpha$ ) and transforming growth factor beta (TGF- $\beta$ ) have an important role in regulating and in amplifying the inflammatory response (Panagakos et al. 1996,

## Conflict of interest and source of funding statement

The authors declare that they have no conflict of interests.

This study was supported by grants from the Ministry of Universities and Research, Italy, and from the University of Turin, Italy.

Delima et al. 2001, Graves & Cochran 2003).

One of the most important cytokines in the inflammatory process in the oral cavity is IL-1 $\beta$ , a multifunctional mediator that plays a major role in acute and chronic periodontal inflammation. It is a strong pro-inflammatory protein because it mediates the production of prostaglandins, leukotrienes and platelet-activating factor in several cell types. Moreover, it promotes osteoclast formation and bone resorption (Gowen & Mundy 1986, Billingham 1987, Tatakis et al. 1988). High levels of IL-1 $\beta$  in gingival crevicular fluid (GCF) (Hönig et al. 1989, Masada et al. 1990, Engebretson et al. 2002) and in gingival tissue (Hönig et al. 1989, Stashenko et al. 1991, Engebretson et al. 1999) have been associated with chronic periodontitis (Masada et al. 1990, Ishihara et al. 1997, Goutoudi et al. 2004, Orozco et al. 2006). It has been shown that inhibition of IL-1 $\beta$  reduced tissue destruction and the progression of inflammation in experimental periodontitis (Graves et al. 1998, Delima et al. 2001, Ataoglu et al. 2002, Delaleu & Bickel 2004).

In peri-implant crevicular fluid (PICF), higher levels of IL-1 $\beta$  have been associated with peri-implantitis (Kao et al. 1995, Panagakos et al. 1996, Salcetti et al. 1997, Aboyoussif et al. 1998, Ataoglu et al. 2002, Murata et al. 2002, Tsalikis et al. 2002).

TNF- $\alpha$  is another pro-inflammatory cytokine with many functions similar to those of IL-1 $\beta$  (Beutler & Cerami 1986, Sunderkotter et al. 1994). TNF- $\alpha$  stimulates bone resorption and fibroblasts to produce collagenase (Bertolini et al. 1986, Meikle et al. 1989). It enhances apoptosis of matrix-producing cells, limiting the repair capacity of the periodontium (Graves et al. 2001, Hock et al. 2001).

The involvement of TNF- $\alpha$  in peri-implant mucositis or peri-implantitis is not yet clear. It still has to be determined whether this cytokine is a marker of peri-implant health (Panagakos et al. 1996, Ataoglu et al. 2002).

TGF- $\beta$  is a protein with anti-inflammatory properties and seems to have an important role in regulating the development and progression of periodontal diseases (Sporn & Roberts 1990, Skaleric et al. 1997, Steinsvoll et al. 1999, Buduneli et al. 2001, Wright et al. 2001, 2003). In the repair and regeneration process of the periodontium, this cyto-

kine is a key feedback inhibitor of bone resorption and stimulates bone formation (Sporn & Roberts 1990, Graves & Cochran 1994). The presence of TGF- $\beta$  has been shown in peri-implant healthy tissue (Schierano et al. 2000, 2003). Few data exist on the involvement of this cytokine in peri-implantitis (Salcetti et al. 1997, Cornellini et al. 2003, Schultze-Mosgau et al. 2006), and no data exist regarding peri-implant mucositis.

No data are available in literature on the behaviour of these cytokines in the both periodontal and peri-implant soft tissues in the same patient. The aim of this split-mouth study was to investigate quantitative changes in IL-1 $\beta$ , TNF- $\alpha$  and TGF- $\beta$ 2 levels in gingival and PICF after experimental plaque accumulation around a healthy implant and a healthy tooth in the same patient.

## Material and Methods

### Study population

This split-mouth study protocol was approved by the Local Ethics Board. All patients gave informed written consent.

Twenty-five Caucasian patients (18 females, seven males, mean age  $53 \pm 14$ ) were enrolled in the study. All patients were motivated and showed good oral hygiene techniques. They did not have a history of periodontitis and no bleeding levels before the start of the study. The patients were all non-smokers in good general health and none had taken medications, such as antibiotics or anti-inflammatory drugs, which could affect their periodontal and peri-implant health, for at least 6 months before the study. All patients had been rehabilitated with the implant-fixed prosthesis (Branemark System, Nobel Biocare AB, Göteborg, Sweden) for at least 24 months before the start of the study (Table 1).

An implant and a natural tooth sites were selected in each patient. Table 1 also shows the position of the tooth and implant abutment (length abutment: one = 3 mm; seventeen = 4 mm; six = 5 mm and one = 5.5 mm).

### Clinical recordings and CF collection

The oral hygiene of each patient was monitored until the beginning of the trial. When the study began, the patients underwent a professional oral hygiene

session. One week after the professional oral hygiene session (baseline/day 0), the patients were asked to refrain from performing any oral hygiene procedure, to abstain from any kind of drug that could affect cytokine production and to avoid chewing "hard" foods (such as raw vegetables), gum that could stimulate self-cleaning of the teeth, for 3 weeks. After this time (day 21), the patients re-started cleaning their teeth again. Three different samples of GCF and PICF were taken at the following times: the first at baseline/day 0; the second at 21 days; and the third 3 months after baseline (day 90), i.e. 69 days after re-starting normal oral hygiene.

At baseline, days 21 and 90, the plaque index (PI; Silness & Loe 1965) and gingival index (GI; Loe 1967) were assessed (Table 2).

Two Periopaper absorbing strips (Oraflow, Plainview, NY, USA) were inserted into both the gingival and two in the peri-implant crevice for 30 s, one mesial-buccally and the other disto-buccally.

The volume of the crevicular fluids was determined by positioning the strips between the upper and the lower counterparts of the pre-calibrated Periotron 8000 (Oraflow); the volume of the crevicular fluids was measured in "Periotron units" and then converted into microlitres.

The paper strips were then placed in a single labelled test tube containing 350  $\mu$ l of phosphate-buffered saline (PBS), sealed and immediately sent to the lab. After 15 min. of shaking at room temperature, the strips were removed and the eluates were centrifugated (5 min, 3000  $\times$  g) to remove plaque and cellular elements. The samples were stored at  $-80^{\circ}\text{C}$  for subsequent assays. The reported volumes and the cytokine amounts were the average of the two samples (mesial- and disto-buccal) collected at each site.

### Cytokine assays

The levels of TNF- $\alpha$ , TGF- $\beta$ 2 and IL-1 $\beta$  were determined using commercial ELISA kits (TNF- $\alpha$ , IL-1 $\beta$ : Euroclone Life Sciences, Pero (MI), Italy; TGF- $\beta$ 2: Promega Corporation, Madison WI, USA). Hundred microlitres from each eluted sample was assayed according to the manufacturer's instructions. The test sensitivity is so high that it manages to

Table 1. Subject characteristics of study population

Patient	Age	Sex	Social background	Total natural teeth	Total implants	Site tooth selected	Site implant selected
1	68	F	Psychologist	22	4	33	34
2	70	F	Housewife	18	6	26	25
3	47	F	Laboratory technician	24	1	22	23
4	60	M	Administration employee	23	3	33	36
5	71	F	Retired	21	4	35	36
6	69	M	Retired	20	4	22	23
7	49	F	Administration employee	23	4	27	26
8	47	F	Nurse	16	5	35	34
9	60	M	Driver	27	1	47	46
10	65	F	Teacher	17	7	43	45
11	64	F	Administration employee	16	5	27	24
12	24	F	Administration employee	30	1	34	35
13	53	F	Administration employee	22	5	25	24
14	67	F	Administration employee	14	9	34	35
15	28	M	Student	30	2	14	12
16	52	F	Cashier	20	3	34	35
17	34	M	Administration employee	26	3	15	13
18	63	F	Retired	21	2	26	25
19	46	M	Worker	27	1	16	14
20	41	F	Administration employee	23	2	33	24
21	34	F	Administration employee	25	2	33	34
22	36	F	Teacher	29	1	44	43
23	60	M	Retired	16	3	26	22
24	63	F	Retired	13	5	17	16
25	50	F	Worker	23	2	22	12

Table 2. Means and SDs of plaque index (PI; Silness &amp; L oe 1965) and gingival index (GI; L oe 1967) of whole mouth. 0, no plaque; 1, visible plaque; 2, great accumulation of plaque

	1° sample	2° sample	3° sample
	Plaque index (PI)		
25 patients	0.00 ± 0.00	1.00 ± 0.00	0.00 ± 0.00
	Gingival index (GI)		
25 patients	0.00 ± 0.00	1.16 ± 0.37	0.24 ± 0.43

detect TNF- $\alpha$ , TGF- $\beta$ 2 and IL-1 $\beta$  even when the quantity is <8, 32, 5 pg/ml, respectively, as indicated in the technical cards.

Before the assay, the samples used for TGF- $\beta$ 2 determination were processed by an in vitro acid treatment to obtain the bioactive form of the protein (total TGF- $\beta$ 2). Briefly, the specimens were diluted 1:4 in Dulbecco's PBS and acidified with 1 N HCl (1  $\mu$ l per 50  $\mu$ l of diluted sample), incubated at room temperature for 15 min. and then neutralized by adding 1 N NaOH (1  $\mu$ l per 50  $\mu$ l of diluted sample).

The amounts for each cytokine were examined using a microplate reader at 450 nm as the primary wavelength and at 620 nm as the reference wavelength. Concentrations of the cytokines in each 100  $\mu$ l sample were determined by generation of standard curves. Cytokines are expressed as total amounts in pg/site.

#### Statistical analysis

The reported volumes and cytokine total amounts were the average of the two samples collected at each site. Data are expressed as means and standard deviations. Owing to the non-normal distribution of data, the non-parametric Friedman's test was used when comparing the repeated measurements during the follow-up. When the Friedman test was significant at the 0.05 level, pairwise comparisons based on the Wilcoxon rank test were carried out, with the Bonferroni correction to adjust for multiple pairwise comparisons ( $\alpha = 0.05/3 = 0.016$ ). Differences between tooth and implant at each time point were evaluated using the Wilcoxon rank test with Bonferroni's correction ( $\alpha = 0.05/3 = 0.016$ ) to avoid an inflation of type I error due to multiple analyses.

All statistical analyses were performed using STATA 8.0 software.

#### Results

The clinical indices assessed demonstrated that at the test sites, plaque accumulation with gingival and peri-implant mucosa inflammation was induced after 21 days of no oral hygiene. Both the PI and the GI increased in all patients between days 0 and 21 and returned to baseline values by day 90 (Table 2).

In all 25 patients, a significant increase in GCF and PICF volume was induced by non-brushing compared with day 0. Samples collected at day 90 demonstrated a significant decrease in GCF and PICF volume compared with day 21 (Fig. 1). Although a significant reduction in volume occurred after the re-establishment of daily oral hygiene, at day 90, the volume of the GCF from the study teeth was still significantly elevated compared with the baseline. Instead, the PICF volume, at day 90, returned to baseline levels. In comparing the CGF and PICF volumes at the times of evaluation, no significant differences were noticed.

TNF- $\alpha$  was detected in all 25 patients; no significant changes were detected in the total level of this cytokine for both the teeth and the implants during the three experimental timings ( $p > 0.05$ ). The comparison of the total amount of TNF- $\alpha$  detected in GCF with that in PICF at all three sampling points

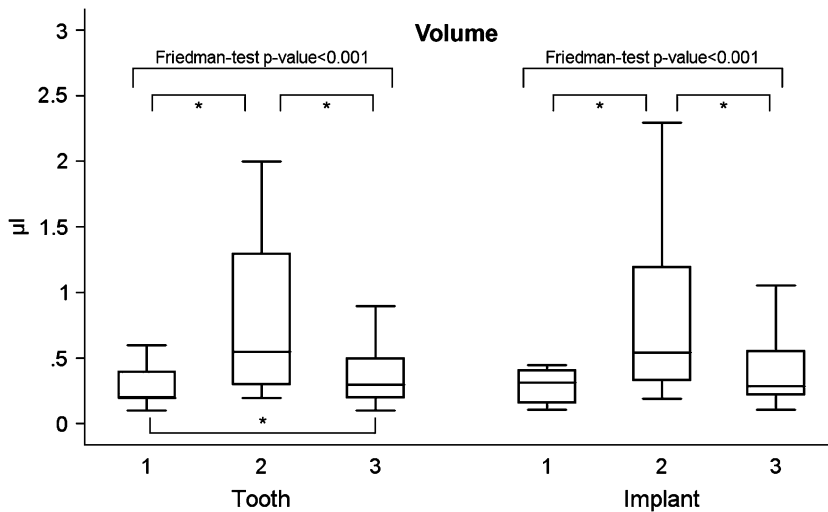


Fig. 1. Boxplots of crevicular fluid volume around teeth and implants. Outliers were not plotted, but included in the statistical analysis. Sample 1, day 0; sample 2, day 21; sample 3, day 90. \*Statistical significance.

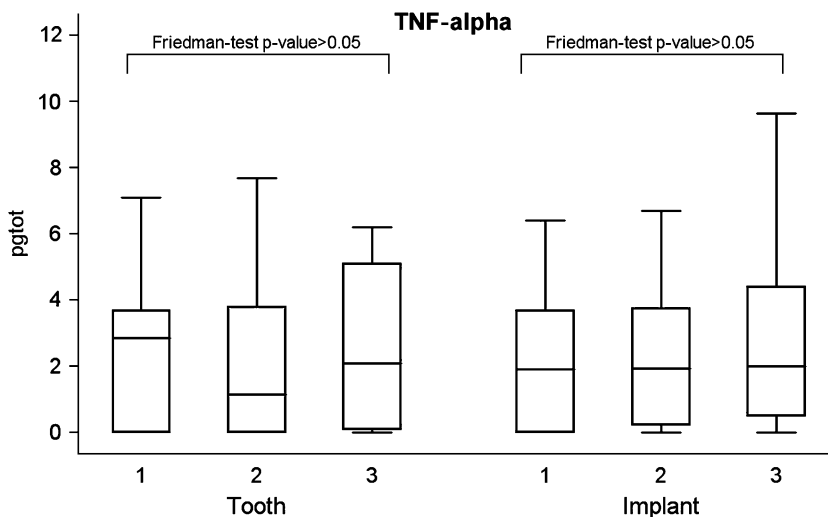


Fig. 2. Boxplots of mean values of TNF- $\alpha$  (total amount, pg/tot) around teeth and implants. TNF- $\alpha$ , tumour necrosis factor alpha. Outliers were not plotted, but included in the statistical analysis. Sample 1, day 0; sample 2, day 21; sample 3, day 90.

showed no significant difference ( $p > 0.05$ , Fig. 2).

TGF- $\beta 2$  was observed in all crevicular fluid samples, around implants and teeth, but no significant change in the total amount of this cytokine was detected in the study ( $p > 0.05$ ). Moreover, no significant differences were observed on comparing the GCF values with PICF at the three sampling points ( $p > 0.05$ , Fig. 3).

IL-1 $\beta$  was also detected in all 25 patients. In the GCF, a significant increase in the total amount of this cytokine was detected at day 21 com-

pared with the baseline. The re-establishment of oral hygiene induced a significant reduction by day 90. No significant difference was observed between the total amount of cytokine at day 90 and baseline (Fig. 4).

Twenty-one days of plaque accumulation in the PICF induced a non significant increase of IL-1 $\beta$  levels, while at day 90, a significant reduction of this cytokine was detected, the amount being similar to that at baseline (Fig. 4).

At day 21, the total amount of IL-1 $\beta$  in the GCF was higher than in the PICF, but this difference was not significant at

the 0.016 level fixed with the Bonferroni correction for multiple analyses ( $p = 0.0382$ ). No significant differences were found at day 0 or 90.

## Discussion

This split-mouth study evaluated the trends of volume and cytokines in GCF and PICF before and after plaque accumulation in the same patient. For this reason, the data are not affected by individual changes. Other studies have not analysed these parameters in the same patient (Lamster et al. 1985, Niimi & Ueda 1995, Panagakos et al. 1996, Salcetti et al. 1997, Ataoglu et al. 2002, Murata et al. 2002, Eberhard et al. 2003, Wright et al. 2003).

The results of the present study confirm previous findings (Løe et al. 1965, Zitzmann et al. 2001, Wright et al. 2003) and clearly demonstrate that when oral hygiene procedures are interrupted, an increase in plaque accumulation and the establishment of clinically relevant mucosal inflammation occur around both dental implants and teeth.

A relationship between GCF and gingival inflammation has been reported previously (Lamster et al. 1985, Eberhard et al. 2003). In this study, all patients showed a significant increase in GCF volume after 21 days of no oral hygiene. After oral care was resumed, this volume decreased significantly (Wright et al. 2003).

The PICF volume increased significantly after plaque accumulation (day 21) compared with day 0, as observed in other studies (Niimi & Ueda 1995, Salcetti et al. 1997, Murata et al. 2002). After resuming oral hygiene techniques, the PICF volume decreased significantly. This is the first study demonstrating that oral hygiene can reduce peri-implant mucosal inflammation, as assessed by PICF volume, in a 69-day period (90–21 days). These data suggest that increased volumes of GCF and PICF could be useful markers of early (21 days) inflammation in gingival and peri-implant tissues.

In contrast with other studies (Wright et al. 2003), the GCF decreased around the study teeth 69 days after the re-establishment of hygiene procedures, but was still significantly higher than at baseline, even if, clinically, the gingival tissues appeared healthy. The fact that GCF did not return to baseline as it occurred for PICF could be explained by the anti-inflammatory effect of titanium,

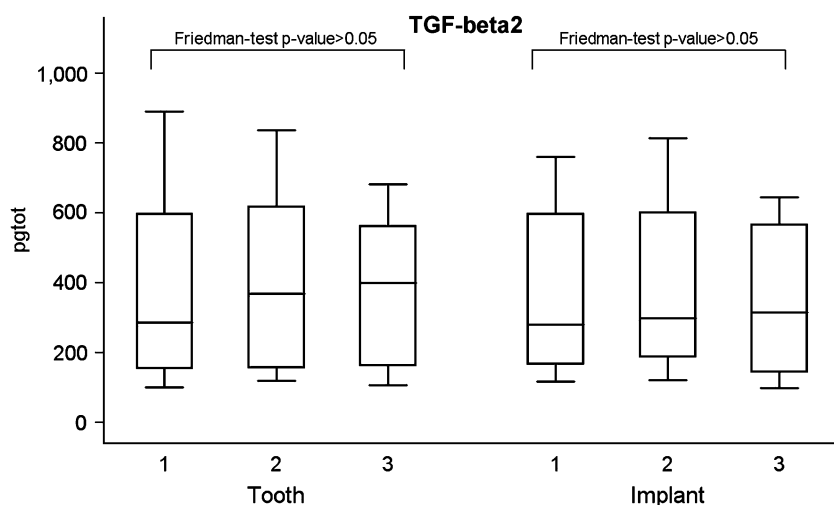


Fig. 3. Boxplots of mean values of TGF- $\beta$ 2 (total amount, expressed in pg/tot) around teeth and implants. TGF- $\beta$ , transforming growth factor beta. Outliers were not plotted, but included in the statistical analysis. Sample 1, day 0; sample 2, day 21; sample 3, day 90.

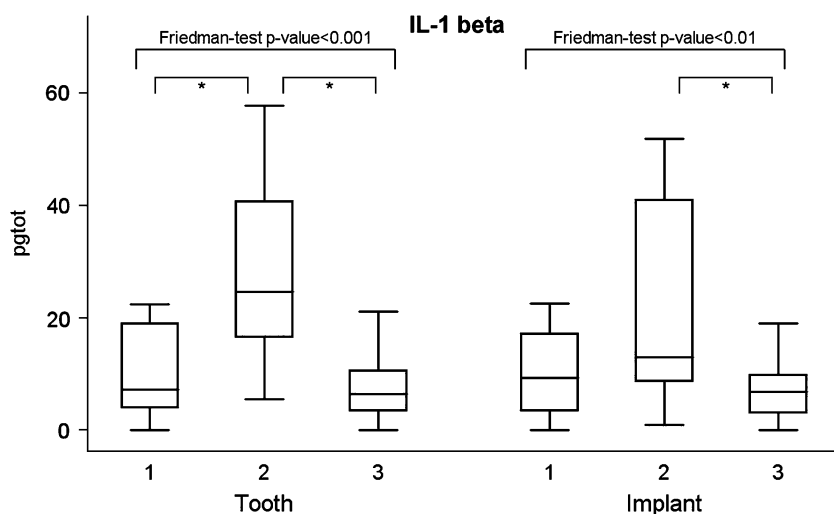


Fig. 4. Boxplots of mean values of IL-1 $\beta$  (total amount, expressed in pg tot) around teeth and implants. IL-1 $\beta$ , interleukin-1 beta. Outliers were not plotted, but included in the statistical analysis. Sample 1, day 0; sample 2, day 21; sample 3, day 90. \*Statistical significance.

as shown in *in vitro* studies (Larsson et al. 2004, Contreras et al. 2007).

With respect to cytokines, most of the patients had measurable TNF- $\alpha$  levels, but no significant change in the overall amount was evident after the establishment of plaque-associated mucosal inflammation. This result is similar to the one of Ataoglu et al. (2002), who detected TNF- $\alpha$  in 37 of 42 implant samples, but found no correlation between the severity of peri-implant inflammation and the presence of TNF- $\alpha$ . It remains unclear whether the level

of this cytokine in PICF and CGF can be considered to be a measure of tissue health.

TGF- $\beta$ 2 has been detected at all experimental timings. Despite the reported involvement of this cytokine in the repair process of insults in the periodontium (Sporn & Roberts 1990, Graves & Cochran 1994), no significant change in the total amount was detected after 21 days of plaque accumulation or 69 days after the re-establishment of oral hygiene, nor was any difference detected when implants were compared

with teeth. These data confirm the results of a study in which no significant increase was found in TGF- $\beta$ 1 after 14 and 21 days of plaque accumulation following the induction of experimental gingivitis (Wright et al. 2003). These results may suggest that 21 days of plaque accumulation around implants and teeth are not sufficiently severe to stimulate changes in the level of this cytokine. Perhaps an established and chronic lesion may be necessary to stimulate a significant production of TGF- $\beta$  isoforms.

IL-1 $\beta$  was the only cytokine examined that demonstrated significant changes during the study. A significantly increased level of this cytokine was detected after plaque accumulation in the crevicular fluid of teeth. These results confirm the findings of other studies showing increased IL-1 $\beta$  crevicular fluid levels after induction of experimental gingivitis with *de novo* plaque accumulation (Gonzales et al. 2001, Tsalikis et al. 2002, Giannopoulou et al. 2003).

The resumption of oral hygiene techniques produced a significant reduction in IL-1 $\beta$ , as detected at day 90, and a recovery in gingival health as observed clinically. This further demonstrated how this cytokine is correlated with the early phases of the gingival inflammatory process, in addition to chronic gingivitis and periodontitis (Faizuddin et al. 2003, Goutoudi et al. 2004, Orozco et al. 2006).

The PICF analyses showed that at day 21, an increase in the total amount of IL-1 $\beta$  occurred, but it was not statistically significant compared with the baseline values. After 69 days of resumed oral hygiene, a significant reduction in the cytokine level was detected. At day 90, the amount of IL-1 $\beta$  present in the PICF was similar to the baseline. In periodontal disease, several studies have demonstrated a correlation between this cytokine and established peri-implantitis (Kao et al. 1995, Panagakos et al. 1996, Aboyoussef et al. 1998, Murata et al. 2002); the present study is the first to assess changes in IL-1 $\beta$  before, during and after the resolution of a peri-implant mucositis.

Comparing the content of IL-1 $\beta$  in CGF and PICF, it is possible to observe a higher, but not significant, amount of this cytokine at day 21 in the CGF. The biological mechanism involved is still unclear; a possible explanation may be the previously mentioned anti-inflammatory

property of titanium surfaces (Larsson et al. 2004, Contreras et al. 2007).

After analysing the data, we reached the following conclusions.

- 1) Re-establishment of oral hygiene can restore the health of mucosal tissues, even after 3 weeks of plaque accumulation around teeth and implants.
- (2) GCF and PICF volume are correlated with gingival and peri-implant mucosal inflammation; the crevicular fluid volume around teeth and implants may be an index for the evaluation of the presence of soft tissue inflammation.
- (3) The amount of IL-1 $\beta$  in the CGF and PICF may be parameters that could be considered to evaluate the inflammatory process.
- (4) In the presence of de novo plaque, implants showed lower, and nearly significant, levels of IL-1 $\beta$  compared with teeth.

#### Acknowledgements

We thank Dr. Andrea Evangelista for his help with statistical analysis.

#### References

- Aboyoussef, H., Carter, C., Jandinski, J. J. & Panagakos, F. (1998) Detection of prostaglandin E2 and matrix metalloproteinase in implant crevicular fluid. *International Journal of Oral Maxillofacial Implants* **13**, 689–696.
- Ataoglu, H., Alptekin, N. O., Haliloglu, S., Guresel, M., Ataoglu, T., Serpek, B. & Durmus, E. (2002) Interleukin-1 $\beta$  and tumor necrosis factor- $\alpha$  levels and neutrophil elastase activity in peri-implant crevicular fluid. Correlation with clinical parameters and effect of smoking. *Clinical Oral Implant Research* **13**, 470–476.
- Bertolini, D. R., Nedwin, G. E., Bringman, T. S., Smith, D. D. & Mundy, G. R. (1986) Stimulation of bone resorption and inhibition of bone formation in vitro by human tumor necrosis factors. *Nature* **319**, 516–518.
- Beutler, B. & Cerami, A. (1986) Catechin and tumor necrosis factor as two sides of the same biological coin. *Nature* **320**, 584–588.
- Billingham, M. E. (1987) Cytokines as inflammatory mediators. *British Medical Bulletin* **43**, 350–357.
- Birkedal-Hansen, H. (1993) Role of cytokines and inflammatory mediators in tissue destruction. *Journal of Periodontal Research* **28**, 500–510.
- Birkedal-Hansen, H., Taylor, R. E., Zambon, J. J., Barwa, P. K. & Neiders, M. (1988) Characterization of collagenolytic activity from strains of *Bacteroides gingivalis*. *Journal of Periodontal Research* **23**, 258–264.
- Buduneli, N., Kutukculer, N., Aksu, G. & Atilla, G. (2001) Evaluation of transforming growth factor- $\beta$ 1 level in crevicular fluid of cyclosporine A-treated patients. *Journal of Periodontology* **72**, 526–531.
- Contreras, R., Sahlin, H. & Frangos, J. A. (2007) Titanate biomaterials with enhanced anti-inflammatory properties. *Journal of Biomedical Material Research. Part A* **80**, 480–485.
- Cornelini, R., Rubini, C., Fioroni, M., Bavero, G. & Stocchi, R. (2003) Transforming growth factor-beta 1 expression in the peri-implant soft tissues of healthy and failing dental implants. *Journal of Periodontology* **74**, 446–450.
- Delaleu, N. & Bickel, M. (2004) Interleukin-1 $\beta$  and interleukin-18: regulation and activity in local inflammation. *Periodontology 2000* **35**, 42–52.
- Delima, A. J., Oates, T., Assuma, R., Schwartz, Z., Cochran, D., Amar, S. & Graves, D. T. (2001) Soluble antagonists to interleukin-1 (IL-1) and tumor necrosis factor (TNF) inhibits loss of tissue attachment in experimental periodontitis. *Journal of Clinical Periodontology* **28**, 233–240.
- Eberhard, J., Ehlers, H., Falk, W., Acil, Y., Albers, H. K. & Jepsen, S. (2003) Efficacy of subgingival calculus removal with Er:YAG laser compared to mechanical debridement: an in situ study. *Journal of Clinical Periodontology* **30**, 511–518.
- Engelbreton, S. P., Grbic, J. T., Singer, R. & Lamster, I. B. (2002) IL-1beta profiles in periodontal disease. *Journal of Clinical Periodontology* **29**, 48–53.
- Engelbreton, S. P., Lamster, I. B., Herrera-Abreu, M., Celenti, R. S., Timms, J. M., Chaudhary, A. G. A., di Giovine, F. & Korman, K. (1999) The influence of interleukin gene polymorphism on expression of interleukin-1 $\beta$  and tumor necrosis factor- $\alpha$  in periodontal tissue and gingival crevicular fluid. *Journal of Periodontology* **70**, 567–573.
- Faizuddin, M., Bharathi, S. H. & Rohini, N. V. (2003) Estimation of interleukin-1beta levels in the gingival crevicular fluid in health and in inflammatory periodontal disease. *Journal of Periodontal Research* **38**, 111–114.
- Giannopoulou, C., Cappuyns, I. & Mombelli, A. (2003) Effect of smoking on gingival crevicular fluid cytokine profile during experimental gingivitis. *Journal of Clinical Periodontology* **30**, 996–1002.
- Golub, L., Lee, H. & Greenwald, R. (1997) A matrix metallo-proteinase inhibitor reduces bone-type collagen degradation fragments and specific collagenases in gingival crevicular fluid during adult periodontitis. *Inflammation Research* **46**, 310–319.
- Gonzales, J. R., Herrmann, J. M., Boedeker, R. H., Franz, P. I., Biesalski, H. & Meyle, J. (2001) Concentration of interleukin-1beta and neutrophil elastase activity in gingival crevicular fluid during experimental gingivitis. *Journal of Clinical Periodontology* **28**, 544–549.
- Goutoudi, P., Diza, E. & Arvantidou, M. (2004) Effect of periodontal therapy on crevicular fluid interleukin-1 $\beta$  and interleukin-10 levels in chronic periodontitis. *Journal of Dentistry* **32**, 511–520.
- Gowen, M. & Mundy, G. R. (1986) Actions of recombinant IL-1 IL-2 and interferon-a on bone resorption in vitro. *Journal of Immunology* **136**, 2478–2482.
- Graves, D. T. & Cochran, D. (1994) Periodontal regeneration with polypeptide growth factors. *Current Opinions in Periodontology* **2**, 178–186.
- Graves, D. T. & Cochran, D. (2003) The contribution of interleukin-1 and tumor necrosis factor to periodontal tissue destruction. *Journal of Periodontology* **74**, 391–401.
- Graves, D. T., Delima, A., Assuma, R., Amar, S., Oates, T. & Cochran, D. (1998) Interleukin-1 and tumor necrosis factor antagonist inhibit the progression of inflammatory cell infiltration toward alveolar bone in experimental periodontitis. *Journal of Periodontology* **69**, 1419–1425.
- Graves, D. T., Osokouli, M. & Volejnikova, S. (2001) Tumor necrosis factor modulates fibroblast apoptosis, PMN recruitment, and osteoclast formation in response to *P. gingivalis* infection. *Journal of Dental Research* **80**, 1875–1879.
- Gualini, F. & Berglundh, T. (2003) Immunohistochemical characteristics of inflammatory lesion at implants. *Journal of Clinical Periodontology* **30**, 14–18.
- Hock, J., Krishnan, V., Onyia, J., Bidwell, J., Milas, J. & Stanislaus, D. (2001) Osteoblast apoptosis and bone turnover. *Journal of Bone Mineralogy Research* **16**, 975–984.
- Hönig, J., Rordorf-Adam, C. & Siegmund, C. (1989) Increased interleukin-1 beta (IL-1 $\beta$ ) concentration in gingival tissue from periodontitis patients and healthy control subjects. *Journal of Periodontal Research* **24**, 362–367.
- Ishihara, Y., Nishihara, T., Kuroyanagi, T., Shirozu, N., Yamagishi, E., Ohguchi, M., Koide, M., Veda, N., Amano, K. & Noguchi, T. (1997) Gingival crevicular interleukin-1 and interleukin-1 receptor antagonist level in periodontally healthy and diseased sites. *Journal of Periodontal Research* **32**, 524–529.
- Kao, R. T., Curtis, D. A., Richards, D. W. & Preble, J. (1995) Increased interleukin-1 $\beta$  in the crevicular fluid of diseased implants. *International Journal of Oral Maxillofacial Implants* **10**, 696–701.
- Lamster, I. B., Mandella, R. D. & Gordon, J. M. (1985) Lactate dehydrogenase activity in gingival crevicular fluid collected with filter paper strips: analysis in subjects with non-inflamed and mildly inflamed gingiva. *Journal of Clinical Periodontology* **12**, 153–161.
- Larsson, J., Persson, C., Tengvall, P. & Lundqvist-Gustafsson, H. (2004) Anti-inflammatory effects of titanium-peroxy gel: role of oxygen metabolites and apoptosis. *Journal of Biomedical Materials Research* **68**, 448–457.

- Löe, H. (1967) The gingival index, the plaque index, and the retention index. *Journal of Periodontology* **38**, 610–616.
- Löe, H., Theilade, E. & Jensen, S. B. (1965) Experimental gingivitis in man. *Journal of Periodontology* **36**, 177–178.
- Masada, M. P., Persson, R. & Kenney, J. S. (1990) Measurement of interleukin 1 $\alpha$  and 1 $\beta$  in gingival crevicular fluid: implication for the pathogenesis of periodontal disease. *Archives Oral Biology* **25**, 156–163.
- Meikle, M. C., Atkinson, S. J., Ward, R. V., Murphy, J. & Reynolds, J. J. (1989) Gingival fibroblasts degrade type 1 collagen films when stimulated with tumor necrosis factor and IL-1 evidence that breakdown is mediated by metalloproteinase. *Journal of Periodontal Research* **24**, 207–213.
- Moon, I.-S., Berglundh, T., Abrahamsson, I., Linder, E. & Lindhe, J. (1999) The barrier between the keratinized mucosa and the dental implant. An experimental study in the dog. *Journal of Clinical Periodontology* **26**, 658–663.
- Murata, M., Tatsumi, J., Kato, Y., Suda, S., Nunokawa, Y., Kobayashi, Y., Takeda, Y., Arakai, H., Shin, K., Okuda, K., Miyata, T. & Yoshie, H. (2002) Osteocalcin, deoxyypyridinoline and interleukin 1 $\beta$  in peri-implant crevicular fluid of patients with peri-implantitis. *Clinical Oral Implant Research* **13**, 637–643.
- Niimi, A. & Ueda, M. (1995) Crevicular fluid in the osseointegrated implant sulcus: a pilot study. *International Journal of Oral Maxillofacial Implants* **10**, 434–436.
- Okada, H. & Murakami, S. (1998) Cytokine expression in periodontal health and disease. *Critical Review in Oral Biology and Medicine* **9**, 248–266.
- Orozco, A., Gemmel, E., Bickel, M. & Seymour, G. J. (2006) Interleukin 1 $\beta$ , interleukin-12 and interleukin-18 levels in gingival fluid and serum of patients with gingivitis and periodontitis. *Oral Microbiology Immunology* **21**, 256–260.
- Panagakos, F. S., Aboyoussef, H., Dondero, R. & Jandinski, J. J. (1996) Detection and measurement of inflammatory cytokines in implant crevicular fluid: a pilot study. *International Journal of Oral Maxillofacial Implants* **11**, 794–799.
- Pontoriero, R., Tonelli, M. P., Carnevale, G., Mombelli, A., Nyman, S. R. & Lang N, P. (1994) Experimentally induced peri-implant mucositis. A clinical study in humans. *Clinical Oral Implant Research* **5**, 254–259.
- Quirynen, M., Abarca, M., Van Assche, N., Nevins, N. & van Steenberghe, D. (2007) Impact of supportive periodontal therapy and implant surface roughness on implant outcome in patients with a history of periodontitis. *Journal of Clinical Periodontology* **34**, 805–815.
- Rathe, F., Ausschill, T. M., Sculean, A., Gaudsuhn, Ch. & Arweiler, N. B. (2007) The plaque and gingivitis reducing effect of a chlorhexidine and aluminium lactate containing dentifrice (Lacalut aktiv<sup>®</sup>) over a period of 6 months. *Journal of Clinical Periodontology* **34**, 646–651.
- Salcetti, J. M., Moriarty, J. D., Cooper, L. F., Smith, F. W., Collins, J. C., Socransky, S. S. & Offembacher, S. (1997) The clinical, microbiological and host response characteristics of the failing implant. *International Journal of Oral Maxillofacial Implants* **12**, 32–42.
- Schierano, G., Bassi, F., Gassino, G., Mareschi, K., Bellone, G. & Preti, G. (2000) Cytokine production and bone remodelling in patients wearing overdentures on oral implants. *Journal of Dental Research* **79**, 1675–1682.
- Schierano, G., Bellone, G., Cassarino, E., Pagano, M., Preti, G. & Emanuelli, G. (2003) Transforming growth factor-beta and interleukin 10 in oral implant sites in humans. *Journal of Dental Research* **82**, 428–432.
- Schultze-Mosgau, S., Wehrhan, F., Wichmann, M., Schlegel, K. A., Holst, S. & Thorwarth, M. (2006) Expression of interleukin 1-beta, transforming growth factor beta-1, and vascular endothelial growth factor in soft tissue over implant before uncovering. *Oral Surgery Oral Medicine Oral Pathology Oral Radiology and Endodontics* **101**, 565–571.
- Silness, J. & Löe, H. (1965) Periodontal disease in pregnancy. *Acta Odontologica Scandinavica* **22**, 121–135.
- Skaleric, U., Kramar, B., Petelin, M., Pavlica, Z. & Wahl, S. M. (1997) Changes in TGF- $\beta$ 1 levels in gingival crevicular fluid and serum associated with periodontal inflammation in humans and dogs. *European Journal of Oral Science* **105**, 136–142.
- Sporn, M. B. & Roberts, A. B. (1990) The transforming growth factor- $\beta$ s: past, present and future. *Annals of New York Academy of Science* **569**, 1–6.
- Stashenko, P., Jandinski, J. J., Fusjioshi, P., Rynar, J. & Socranski S, S. (1991) Tissue levels of bone resorptive cytokines in periodontal disease. *Journal of Periodontology* **62**, 504–509.
- Steinsvoll, S., Haltenstein, T. S. & Schenk, K. (1999) Extensive expression of TGF- $\beta$ 1 in chronically inflamed periodontal tissue. *Journal of Clinical Periodontology* **26**, 366–373.
- Sunderkotter, C., Steinbrink, K., Goebeler, M., Bhardwaj, R. & Sorg, C. (1994) Macrophages and angiogenesis. *Journal of Leukocytic Biology* **55**, 410–422.
- Tatakis, D. N., Schneeberger, G. & Dziak, R. (1988) Recombinant interleukin-1 stimulates prostaglandin E2 production by osteoblastic cells: synergy with parathyroid hormone. *Calcified Tissue International* **42**, 358–362.
- Tsalikis, L., Parapanisiou, E., Bata-Kyrkou, A., Polymenides, Z. & Konstantinidis, A. (2002) Crevicular fluid levels of interleukin-1alpha and interleukin-1beta during experimental gingivitis in young and old adults. *Journal of International Academy of Periodontology* **4**, 5–11.
- Wright, H. J., Chapple, I. L. C. & Matthews, J. B. (2001) TGF- $\beta$  isoforms and TGF- $\beta$  receptors in drug induced and hereditary gingival overgrowth. *Journal of Oral Pathology and Medicine* **30**, 281–289.
- Wright, H. J., Chapple, I. L. C. & Matthews, J. B. (2003) Levels of TGF- $\beta$ 1 in gingival crevicular fluid during 21-day experimental model gingivitis. *Oral Diseases* **9**, 88–94.
- Zitzmann, N. U., Berglundh, T., Marinello, C. P. & Lindhe, J. (2001) Experimental peri-implant mucositis in man. *Journal of Clinical Periodontology* **28**, 517–523.

## Address:

Schierano Gianmario  
 Department of Biomedical Sciences and Human Oncology  
 Section of Prosthetic Dentistry  
 School of Dentistry, University of Turin  
 Corso Dogliotti 14, 10126  
 Turin  
 Italy  
 E-mail: gianmario.schierano@unito.it

**Clinical Relevance**

*Scientific rationale for the study:* some cytokines appear to have roles in regulating inflammatory response amplification because in periodontal and peri-implant tissues, inducing osteoclastic bone resorption and con-

nective tissue degradation, the levels of cytokines were assessed in crevicular fluid to evaluate the periodontal and peri-implant inflammation. *Principal findings:* GCF and PICF volumes increased in the presence of plaque accumulation and were

correlated with gingival and peri-implant mucosal inflammation. *Practical implications:* the crevicular fluid volumes and IL-1 $\beta$  content around teeth and implants may provide an index for the evaluation of the presence of soft tissue inflammation.