

Case report

Acute bilateral compartment syndrome of the thigh induced by spinning training

U. Bertoldo^a, A. Nicodemo^a, J. Pallavicini^b, A. Massè^{a,*}

^a *1st Orthopaedic Clinic, Department of Orthopaedics, Traumatology and Occupational Medicine, University of Turin, Turin, Italy*

^b *Department of General Surgery, Centro Traumatologico Ortopedico, Turin, Italy*

Accepted 7 June 2002

1. Case report

A 49-year-old man, was admitted in the emergency room of our hospital complaining of pain and swelling of the thighs; he had performed a particular exercise for 1 h, about 48 h before in a fitness centre. This exercise was the so-called “spinning”, a relatively new fitness activity, which consist of group static fast cycling. He was used to training regularly, but had never performed spinning before.

He noticed a brownish discoloration of his urine about 12 h after the end of the exercise. He had used no medications and had no history of previous relevant diseases. Both thighs were extremely tender to palpation. Neurological examination did not show any abnormalities. On admission the creatinine level was 1.5 mg/dl (NR 0.5–1.2); serum glutamic-pyruvic transaminase level was 592 U/l (NR 4–41); serum glutamic-oxaloacetic transaminase level was 2546 U/l (NR 0–38); creatine phosphokinase level was 185600 U/l (NR 5–190); and lactic dehydrogenase level was 8840 U/l (NR 240–480).

Compartment pressures were measured using a Stryker STIC monitor. The needles were placed anteriorly, in the rectus femoris, vastus medialis and vastus lateralis, and posteriorly, in the flexor muscles. The pressure of the anterior compartment was 70 mmHg in the left thigh and 45 mmHg in the right, while the pressure of the posterior and medial compartments was normal.

On the basis of the clinical observation and the laboratory and instrumental exams, a diagnosis of acute bilateral anterior compartment syndrome of the thigh was made: rehydration and forced alkaline diuresis were immediately initiated. The patient was taken to the operating theatre for a bilateral fasciotomy: a lateral incision was made on

each thigh, about 25 cm in length, deep into the fascia lata; epymiotomia was performed along the skin incision. The quadriceps appeared macroscopically tense, oedematous and slightly pale. The wounds were packed open.

The laboratory exams performed 1 and 5 days post-operatively showed improvement of renal function and a reduction of the cellular catabolites (Fig. 1).

On the 12th post-operative day the muscular oedema was almost completely resolved, and the wounds were closed. The patient was discharged 4 days later to begin physical therapy. At this time the patient was able to walk about 100 m without supports. One year later, we performed a follow-up visit and MRI. The patient had begun practicing sports again without any complaints. There was a mild contracture of both the surgical wounds. The MRI showed a fibrotic area of 5 cm in diameter in the right rectus femoris in its lateral portion. There were no abnormal findings in the left side.

2. Discussion

While muscle overuse is frequently involved in the pathogenesis of chronic compartment syndromes of the leg and the arm, it is exceptionally reported as the cause of acute compartment syndrome, particularly in the thigh: the width of the compartments in this region allows for a relevant swelling of the muscular tissues, before circulatory damages onset. In this case the vigorous exercise brought to necrosis of muscular cells (i.e. rhabdomyolysis) inducing oedema and augmentation of compartmental pressure.

We found in literature eight more cases of acute compartment syndrome of the thighs induced by overexertion (Table 1). Noteworthy is the fact that all the cases regard male patients, and that three cases were reported during the year 2000.

The case we report was induced by the practice of a relatively new fitness activity, the spinning: this is a program

* Corresponding author. Present address: I Clinica Ortopedica e Traumatologica, Via Zuretti 29–10122 Torino, Italy.

E-mail address: alessandro.masse@cto.unito.it (A. Massè).

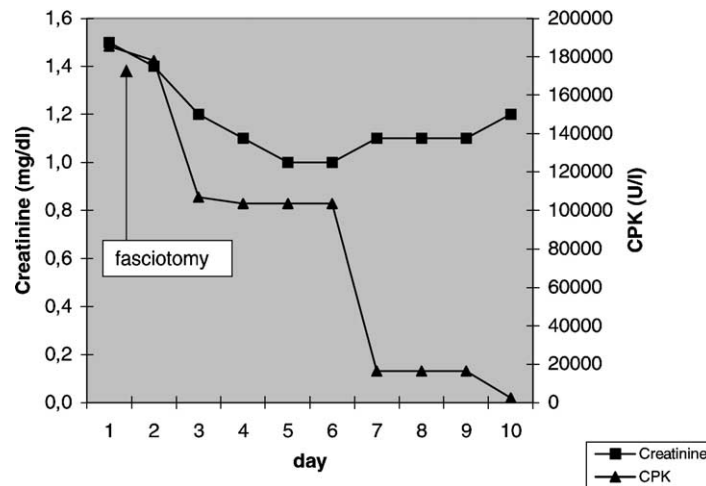


Fig. 1. Creatinine and CPK blood levels.

Table 1
acute compartment syndrome of the thigh induced by overexertion in the literature

	Year	M/F	Monolateral/bilateral	Age	Kind of exercise
Lonka et al. [4]	1987	Male	Bilateral, thighs and legs (fatal)	27	Marathon running
Kahan et al. [2]	1994	Male	Bilateral	27	200 squats
Presnal et al. [6]	1995	Male	Monolateral	Unknown	Unknown
Bidwell et al. [1]	1996	Male	Monolateral	16	Weight training
Wise et al. [8]	1997	Male	Bilateral	28	Weight lifting
Nau et al. [5]	2000	Male	Monolateral	51	Weight training
Kuklo et al. [3]	2000	Male	Bilateral, thighs and legs (fatal)	33	Timed 2 mile run
Robinson et al. [7]	2000	Male	Bilateral	Unknown	Weight lifting

of indoor exercising that uses stationary cycles with a fix gear and a heavy flywheel. This kind of exercise submits the muscles, in particular the quadriceps, to relevant fatigue: this may explain the isolated involvement of the anterior compartment of the thighs in this patient.

References

- [1] Bidwell JP, Gibbons CE, Godsiff S. Acute compartment syndrome of the thigh after weight training. *Br J Sports Med* 1996;30(3):264–5.
- [2] Kahan JS, McClellan RT, Burton DS. Acute bilateral compartment syndrome of the thigh induced by exercise. A case report. *J Bone Joint Surg Am* 1994;76(7):1068–71.
- [3] Kuklo TR, Tis JE, Moores LK, Schaefer RA. Fatal rhabdomyolysis with bilateral gluteal, thigh, and leg compartment syndrome after the Army Physical Fitness Test. A case report. *Am J Sports Med* 2000;28(1):112–6.
- [4] Lonka L, Pedersen RS. Fatal rhabdomyolysis in marathon runner. *Lancet* 1987;1(8537):857–8.
- [5] Nau T, Mentch-Chiari WA, Seitz H, Vecsei V. Acute compartment syndrome of the thigh associated with exercise. *Am J Sports Med* 2000;28(1):120–2.
- [6] Presnal BP, Heavilon JA. Exercise-induced acute compartment syndrome of the thigh. Case report. *Am J Knee Surg* 1995;8(2):77–9.
- [7] Robinson SJ. Acute quadriceps compartment syndrome and rhabdomyolysis in a weight lifter using high-dose creatine supplementation. *J Am Board Fam Pract* 2000;13(2):134–7.
- [8] Wise JJ, Fortin PT. Bilateral, exercise-induced thigh compartment syndrome diagnosed as exertional rhabdomyolysis. A case report and review of the literature. *Am J Sports Med* 1997;25(1):126–9.