

American Journal of Immunology 10 (1): 23-32, 2014

ISSN: 1553-619X

©2014 Science Publication

doi:10.3844/ajisp.2014.23.32 Published Online 10 (1) 2014 (<http://www.thescipub.com/aji.toc>)

CLINICAL EXPERIENCE OF CANCER IMMUNOTHERAPY INTEGRATED WITH OLEIC ACID COMPLEXED WITH DE-GLYCOSYLATED VITAMIN D BINDING PROTEIN

¹Emma Ward, ¹Rodney Smith, ²Jacopo J.V. Branca,
³David Noakes, ²Gabriele Morucci and ¹Lynda Thyer

¹Macro Innovations Ltd, Cambridge, UK

²Department of Experimental and Clinical Medicine, University of Firenze, Firenze, Italy

³Immuno Biotech Ltd, Guernsey, Channel Islands

Received 2014-02-26; Revised 2014-03-07; Accepted 2014-03-8

ABSTRACT

Proteins highly represented in milk such as α -lactalbumin and lactoferrin bind Oleic Acid (OA) to form complexes with selective anti-tumor activity. A protein present in milk, colostrum and blood, vitamin D binding protein is the precursor of a potent Macrophage Activating Factor (GcMAF) and in analogy with other OA-protein complexes, we proposed that OA-GcMAF could demonstrate a greater immunotherapeutic activity than that of GcMAF alone. We describe a preliminary experience treating patients with advanced cancers, often labelled as “incurable” with an integrative immunotherapy centred on OA-GcMAF. Patients with advanced cancer were treated at the Immuno Biotech Treatment Centre with OA-GcMAF-based integrative immunotherapy in combination with a very low carbohydrate, high protein diet, fermented milk products containing naturally produced GcMAF, vitamin D₃ and low-dose acetylsalicylic acid. When the primary tumor or a metastasis could be measured by ultrasonographic techniques, we observed, on average, a decrease of tumor volume of approximately 25% in a week. We also observed a consistent increase in splenic blood flow that was interpreted in the context of generalised immune system activation and allowed to assess the degree of responsiveness of the individual patient. The results reported here are consistent with the results previously described in the experimental animal harbouring a human hepatocellular carcinoma as well as with the results reported for neoadjuvant chemotherapy. OA-protein complexes are bound to play a leading role in cancer therapy thanks to selectivity of antitumoral effects, absence of any side effects, safety and oral availability. We hypothesise that OA-GcMAF, combines the known anticancer effects OA-protein complexes with the well established immune stimulating effects of GcMAF.

Keywords: GcMAF, Oleic Acid, Advanced Cancer, Integrative Immunotherapy, Ultrasonography

1. INTRODUCTION

It is well assessed that proteins highly represented in milk such as α -lactalbumin and lactoferrin can bind Oleic Acid (OA) to form complexes, which exhibit highly selective anti-tumor activity *in vitro* and *in vivo* (Fang *et al.*, 2013). Recent observations seem to indicate that OA plays the key role in the tumoricidal action of these protein-OA complexes (Hoque *et al.*, 2013). Study

of the structural features of such tumoricidal protein-OA complexes demonstrated that all these complexes exhibit a common feature that is a tendency toward protein oligomerization. Since OA-induced oligomerization has been reported for other proteins as well, it was hypothesised that this phenomenon may be inherent to many proteins (Nemashkalova *et al.*, 2013).

It should be noticed that some of the milk proteins forming OA-protein tumoricidal complexes, such as

Corresponding Author: Jacopo J.V. Branca, Department of Experimental and Clinical Medicine, University of Firenze, Largo Brambilla 3, 50134 Firenze, Italy Tel: +39 055 4271810 Fax: +39 055 4379500

lactoferrins, are potent modulators of the immune system (Vogel, 2012), thus lending credit to the hypothesis that the immune system is involved in the anticancer effects of OA-protein complexes.

In addition to lactoferrins, another immunogenic protein highly represented in milk, as well as in colostrum and blood, is the vitamin D binding protein. This is the precursor of a very potent macrophage activating factor that derives from its selective deglycosylation. Since vitamin D binding protein is also termed Gc-globulin, this macrophage activating factor is known as Gc-globulin-derived Macrophage Activating Factor (GcMAF) (for review on vitamin D binding protein and GcMAF, Ruggiero and Pacini, 2011).

The potent immunotherapeutic effects of GcMAF in human tumors have been demonstrated since 2007 in a variety of cancers ranging from the most common breast and prostate cancers to the less frequent oligodendroglioma (Yamamoto *et al.*, 2008a; 2008b; 2008c; Inui *et al.*, 2013; Thyer *et al.*, 2013a; 2013b).

Therefore, in analogy with other OA-protein complexes, we postulated that OA-GcMAF complexes could show an antitumor activity even greater than that of GcMAF alone. Since OA-protein complexes and GcMAF show no evidence of toxicity (Ho *et al.*, 2012; Bradstreet *et al.*, 2012), these complexes were selected as part of an integrative immunotherapeutic approach to advanced cancers in the context of the so-called compassionate approach. In this study we describe the preliminary experiences of treating patients with advanced cancers, some of them considered as “incurable”, with an integrative immunotherapy centred on OA-GcMAF.

2. PATIENTS AND METHODS

At the Immuno Biotech Treatment Centre, patients with advanced late stage 4 cancer, are currently being treated with an OA-GcMAF-based integrative immunotherapy. OA-GcMAF is used in combination with a very low carbohydrate, high protein diet that is known to slow tumor growth and prevent cancer initiation (Ho *et al.*, 2011), fermented milk products containing naturally produced GcMAF, high vitamin D₃ supplementation (Den Hollander *et al.*, 2013) and low-dose acetylsalicylic acid (Thun *et al.*, 2012). All of these approaches aim to strengthen and activate the immune system and can be considered complementary and not alternative to other anti-neoplastic therapeutic procedures that the patients may want to take into consideration.

2.1. OA-GcMAF

OA-GcMAF complexes were prepared “in-house” at immuno biotech with a proprietary procedure. Briefly,

GcMAF was purified according to the procedure previously described (Yamamoto *et al.*, 2008b). Vitamin D binding protein was isolated from purified human serum obtained from the American Red Cross, using either 25-hydroxyvitamin D₃-sepharose high affinity chromatography or actin-agarose affinity chromatography. The bound material was eluted and then further processed by incubation with three immobilized enzymes as described (Bradstreet *et al.*, 2012). The resulting GcMAF was filter sterilized. The protein content and concentration was assayed using standard Bradford protein assay methods (Bradford, 1976). Purity was assessed by SDS-PAGE and Western Blot analysis performed after each step of the preparation procedure; only one band of the expected molecular weight was visible (Smith *et al.*, 2013). At the end of the production process, GcMAF was checked for sterility in-house and externally by independent laboratories. Its safety and biological activity were tested in monocytes, human breast cancer cells and chick embryo chorionallantoic membrane (Pacini *et al.*, 2011; Pacini *et al.*, 2012; Thyer *et al.*, 2013c). Highly purified OA (molecular weight, 282.46; molecular formula, C₁₈ H₃₄ O₂; Acros Organics, Geel, Belgium) was complexed with GcMAF in accordance with the molecular structure described in Thyer *et al.* (2013c). The optimal conditions for the preparation of the complexes were established according to the principles described in Knyazeva *et al.* (2008).

Because of the complexing of the protein with the fatty acid hydrophobic moiety together with the well-known properties of OA as an absorption enhancer, OA-GcMAF complexes could also be administered sublingually (Cui *et al.*, 2005; Sakata *et al.*, 2011), as an aerosol with a common nebuliser (Lu *et al.*, 2011), or as suppositories (Goto *et al.*, 1991).

2.2. Assessment of OA-GcMAF Induced Immunotherapeutic Effects

Macrophage activation *in vivo* could be assessed by monitoring the patient’s blood pressure before and after OA-GcMAF administration. Thus, it is well known that activated macrophages release nitric oxide a compound that causes vasodilatation and seems to be responsible for some of the anti-cancer properties of activated macrophages (Stuehr and Nathan, 1989; Nathan and Hibbs, 1991; Hiroi *et al.*, 2013). It has been consistently observed that a small but significant decrease in both systolic and diastolic blood pressure, e.g. from 137/84 to 122/71. In our experience, the administration of OA-GcMAF (880 ng dissolved in 5 mL saline) with a nebuliser resulted in the most rapid decrease of blood

pressure with the effects clearly appreciable 1 min after the end of the nebulisation. In order to have another assessment of immune stimulation, the splenic blood flow has been monitored with an ultrasound system (MyLab25Gold, Esaote, Genoa, Italy) using the echo-colour-doppler technique. An increase in the peripheral splenic blood flow has been consistently observed after OA-GcMAF administration and it persisted for several days (Fig. 1A and 1B).

2.3. Integrative Cancer Immunotherapy with OA-GcMAF

The standard protocol of our integrative cancer immunotherapy is as follows:

OA-GcMAF (880 ng) has been administered daily using the route of administration that was regarded as most suitable for each patient e.g., in patients with lung cancer or metastases, the preference was to administer OA-GcMAF with a nebuliser. In patients with liver cancer or metastases, the preference was through suppositories. In other cases, the intramuscular route as originally proposed by Yamamoto *et al.* (2008a) was the preferred route.

2.4. Other Complementary Integrative Approaches

In order to exploit the synergistic anti-cancer properties of vitamin D₃ and bearing in mind that GcMAF constitutes part of the vitamin D axis (Thyer *et al.*, 2013c), patients have taken a nutritional supplementation of

vitamin D₃ at 20,000 IU per day (Den Hollander *et al.*, 2013) with monitoring the blood levels of such a vitamin. Patients are taught to drink at least 2 litres of water (or other liquids such as herbal teas) per day.

Patients have followed a nutritional regime based on the recent scientific observations demonstrating that a very low carbohydrate, high protein diet slows tumor growth and prevents cancer initiation (Ho *et al.*, 2011). In order to favour the compliance to this type of diet, non-glucidic food containing only 2% of carbohydrates and a relatively high protein content (Le Gamberi Foods, Forlì, Italy) have been provided.

The patients' weight and muscle mass is monitored and they are taught the strategies to decrease the Prognostic Inflammatory Nutritional Index (PINI) score is upheld as well as strategies to avoid Cancer Anorexia Cachexia Syndrome (CACS) according to Fabris *et al.* (2012). The supplementation with amino acids (Master Aminoacid Patter, International Nutrition Research Center, Coral Gables, FL, USA) is also intended for this scope (Lucà-Moretti *et al.*, 2003).

In order to exploit the well-known immune stimulating and anticancer effects of probiotic fermented milk products (Lakritz *et al.*, 2013), a probiotic fermented milk product containing colostrum and microorganisms that are known to produce a natural GcMAF from the Gc-globulin in the milk and colostrum during the fermentation process (Bravo Probiotic, Les Alpes, Wellington, NZ) has also been administered.

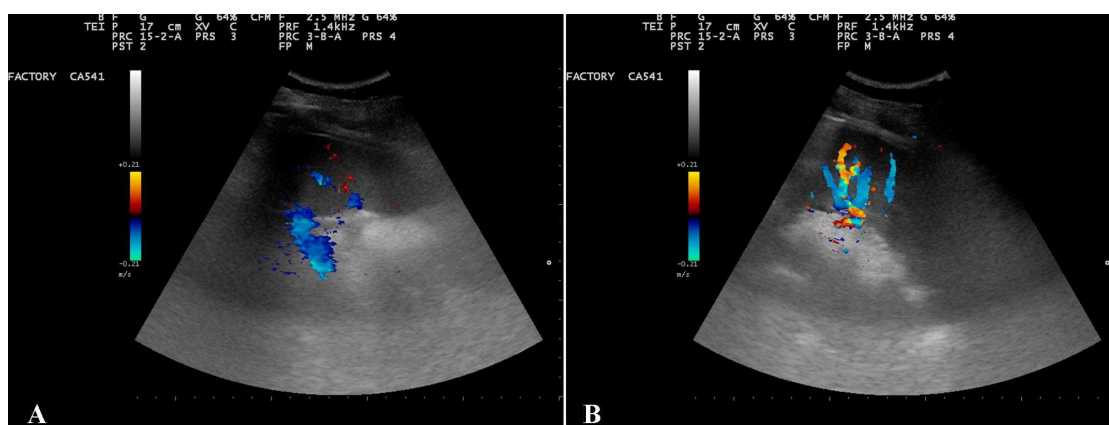


Fig. 1. Increased splenic blood flow following administration of OA-GcMAF. Oleic Acid (OA) complexed with vitamin D binding protein-derived Macrophage Activating Factor (OA-GcMAF, Goleic; Immuno Biotech Ltd, Guernsey, Channel Islands), 880 ng, dissolved in 5 mL saline, was administered by nebulisation. Splenic blood flow was assessed by echo-colour-doppler ultrasonographic technique. Panel A, basal, i.e., before any administration of OA-GcMAF. Panel B, 48 h after OA-GcMAF administration. The increase in peripheral splenic blood flow is evident. This picture is representative of several others that gave qualitatively identical results

Finally, considering the well assessed role of low-dose acetylsalicylic acid in cancer prevention (Thorat and Cuzick, 2013), patients have been receiving a 100 mg dose per day.

3. RESULTS

At the end of October 2013, patients with cancer started treatment at the Immuno Biotech Treatment Centre using the OA-GcMAF integrative approach described above. By the end of February 2014, immuno biotech had treated 30 patients. When the primary tumor or the metastasis could be accurately measured by ultrasonographic techniques, it has been observed, on average, a decrease of tumor volume of approximately 25% in a week. Although this reduction may appear dramatic, it is fully consistent with the results reported by Nonaka *et al.* (2012), who observed a 97% volume reduction of human hepatocellular carcinoma after 3 weeks of subcutaneous injection with GcMAF. It is also consistent with the results reported for neoadjuvant chemotherapy (Partridge *et al.*, 2005).

Among the patients observed at the Immuno Biotech Treatment Centre, we present several cases here each as a representative of common cancers for whom this integrative immunotherapy was remarkably effective. To our knowledge, this is the first example of actual images of tumor volume reduction following GcMAF immunotherapy. In effect, so far the effectiveness of immunotherapy of cancer with GcMAF has relied upon non-specific markers such as serum α -N-acetylgalactosaminidase levels (Yamamoto *et al.*, 2008a; 2008b; 2008c; Thyer *et al.*, 2013a) or anecdotic reports (Inui *et al.*, 2013; Thyer *et al.*, 2013b).

Patient 1

A 63-year-old woman was diagnosed with colon cancer in 1997. A CT scan performed in April 2013 had confirmed metastases in lung and liver. The scan of the liver reported a distortion of the superior liver suspected due to pleural carcinomatosis (diaphragmatic invasion probable) and invasion of the liver surface also possible. After 2 weeks of integrative immunotherapy where OA-GcMAF was administered by alternating nebulisation and intramuscular injections, the lesion at the level of the liver, measured with ultrasonography showed a decrease of calculated volume from 13 to 6.6 mL (**Fig. 2A and 2B**).

Patient 2

A 62-year-old woman was diagnosed with multiple myeloma. After 4 weeks of integrative immunotherapy where OA-GcMAF was administered by intramuscular injections, the monocytes almost doubled (from $0.39 \times 10^9/L$ to $0.70 \times 10^9/L$). This finding is consistent with

the original observation that GcMAF stimulates the bone marrow production of the progenitor cells for extensive mitogenesis and activation of macrophages, thus rebuilding the immune system (Yamamoto and Naraparaju, 1998). The stimulation of the immune system in this case could also be determined by the increase of lymphocytes that were abnormally low before the integrative immunotherapy ($0.81 \times 10^9/L$) and had returned to normal level in afterward ($1.59 \times 10^9/L$). Also the total number of white blood cells returned to normal level ($5.0 \times 10^9/L$) from previously low levels ($3.3 \times 10^9/L$). Also the modest increase of platelets (from 187 to $201 \times 10^9/L$) and of red blood cells (from 3.31 to $3.48 \times 10^{12}/L$) has to be interpreted as a consequence of successful macrophage activation. Thus, that it has been known for a long time that nitric oxide released by activated macrophages stimulates bone marrow haematopoiesis (Iversen *et al.*, 1994; Cokić and Schechter, 2008). In addition to multiple myeloma and independently of this condition, this patient had simple breast cysts that could be visualised by ultrasonography. It has been determined that a significant decrease in the major diameter of one of these cysts, that was taken as being representative of the others. The diameter decreased from 5.4 to 3.8 mm (**Fig. 3A and B**). It is well assessed that breast cysts, although non-malignant, develop when an overgrowth of glands and connective tissue block milk ducts, causing them to dilate and fill with fluid (Guinebretière *et al.*, 2005). Therefore, the observed effects of the integrative immunotherapy on the size of this breast cyst seem to indicate that this approach could be effective in controlling abnormal cell growth even when this is not frankly malignant.

Patient 3

A 43-year-old woman was diagnosed with metastatic breast cancer to bone and liver in February 2013. After 1 week of integrative immunotherapy where OA-GcMAF was administered by localised subcutaneous injections, the primary tumor at the level of the breast, measured with ultrasonography showed a decrease of calculated volume from 1.8 to 1.3 mL (**Fig. 4A and B**). This case was representative of four other cases of breast cancer that qualitatively gave similar results.

Patient 4

A 60-year-old man was diagnosed with metastatic thyroid cancer to bone and soft tissue. After 4 weeks of integrative immunotherapy where OA-GcMAF was administered by alternating nebulisation and localised subcutaneous injections, one of the bone metastases taken as representative, measured with ultrasonography showed a decrease of its thickness from 43.3 to 37.3 mm (**Fig. 5A and B**).

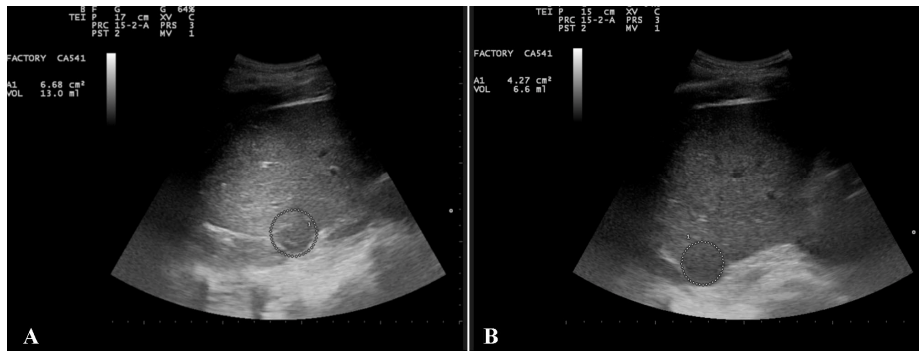


Fig. 2. Ultrasonography of liver metastasis. A 63-year-old woman was diagnosed with colon cancer in 1997. A CT scan performed in April 2013 had confirmed metastases in lung and liver. After 2 weeks of integrative immunotherapy where OA-GcMAF (880 ng/day) was administered by alternating nebulisation and intramuscular injections, the lesion at the level of the liver showed a decrease of calculated volume from 13 ml (panel A) to 6.6 mL (panel B). This corresponds to approximately a 50% overall reduction

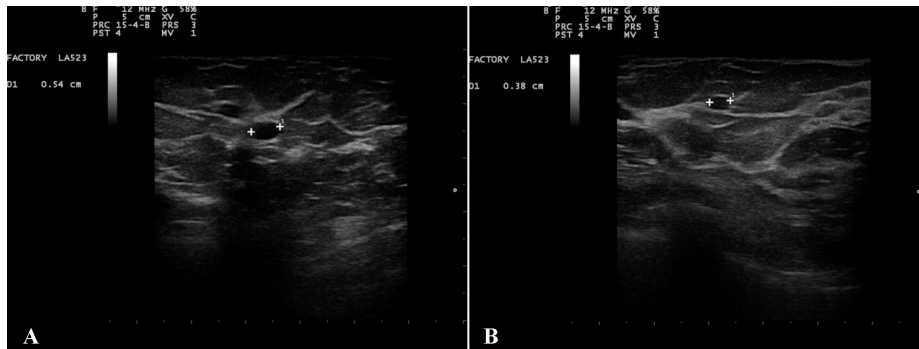

Fig. 3. Ultrasonography of breast cyst. A 62-year-old woman was diagnosed with multiple myeloma. After 4 weeks of integrative immunotherapy where OA-GcMAF (880 ng/day) was administered by intramuscular injections, the diameter of one benign breast cysts decreased from 5.4 mm (panel A) to 3.8 mm (panel B). This corresponds to approximately a 65% overall reduction

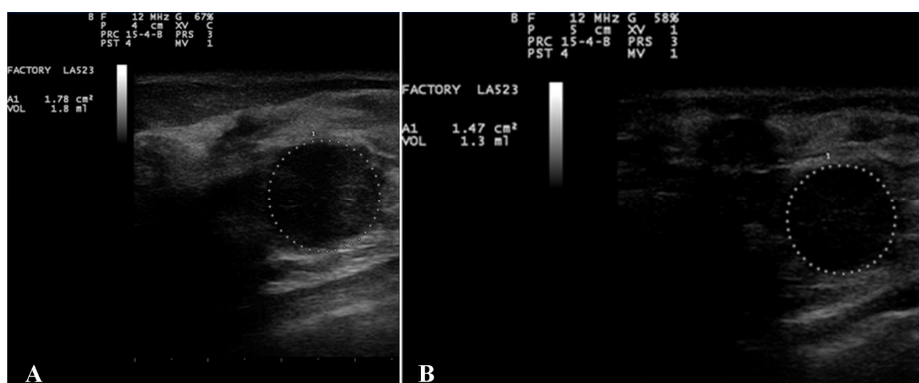


Fig. 4. Ultrasonography of breast cancer. A 43-year-old woman was diagnosed with metastatic breast cancer to bone and liver in February 2013. After 1 week of integrative immunotherapy where OA-GcMAF (880 ng/day) was administered by localised subcutaneous injections, the primary tumour at the level of the breast, measured with ultrasonography, showed a decrease of calculated volume from 1.8 mL (panel A) to 1.3 mL (panel B). This corresponds to approximately a 28% overall reduction. This case was representative of four other cases of breast cancer that qualitatively gave similar results

Patient 5

A 78-year-old man was diagnosed with metastatic renal carcinoma. After 2 weeks of integrative immunotherapy where OA-GcMAF was administered by alternating nebulisation and intramuscular injections, one of the kidney lesions taken as representative, measured with ultrasonography, showed a decrease of its diameter from 33.7 to 29.8 mm (**Fig. 6A and B**).

Patient 6

A 36-year-old man was diagnosed with metastatic melanoma. After 1 week of integrative immunotherapy where OA-GcMAF was administered by alternating nebulisation and intramuscular injections, one of the

lesions in the abdomen, interpreted as coalescent metastatic peritoneal nodes, measured with ultrasonography, showed a decrease of its length from 52.1 to 48.6 mm (**Fig. 7A and B**).

Patient 7

A 55-year-old woman was diagnosed with metastatic adenocarcinoma of the colon. After 3 weeks of integrative immunotherapy where OA-GcMAF was administered by alternating nebulisation, intramuscular injections and suppositories, one of the lesions in the abdomen, interpreted as one of the metastases previously described, measured with ultrasonography, showed a decrease of its length from 76.8 to 70.1 mm (**Fig. 8A and B**).

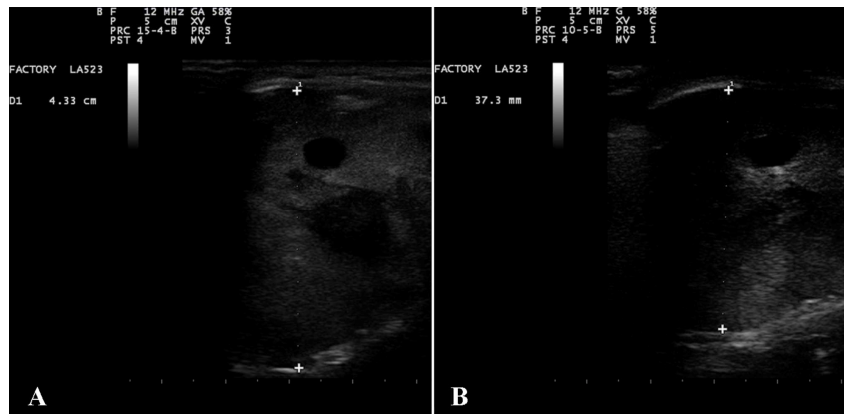


Fig. 5. Ultrasonography of bone metastasis. A 60-year-old man was diagnosed with metastatic thyroid cancer to bone and soft tissue. After 4 weeks of integrative immunotherapy where OA-GcMAF (880 ng/day) was administered by alternating nebulisation and localised subcutaneous injections, one of the bone metastases taken as representative, measured with ultrasonography, showed a decrease of its thickness from 43.3 mm (panel A) to 37.3 mm (panel B). This corresponds to an approximate 14% linear diameter reduction. In this case the volume could not be fully extrapolated since the mass showed an irregular shape

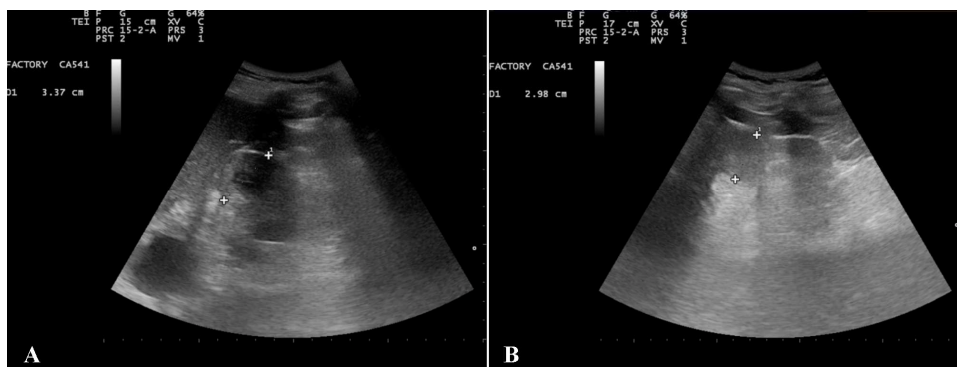


Fig. 6. Ultrasonography of kidney metastasis. A 78-year-old man was diagnosed with metastatic renal carcinoma. After 2 weeks of integrative immunotherapy where OA-GcMAF (880 ng/day) was administered by alternating nebulisation and intramuscular injections, one of the kidney lesions taken as representative, measured with ultrasonography, showed a decrease of its diameter from 33.7 mm (panel A) to 29.8 mm (panel B). This corresponds to approximate a 31% overall reduction

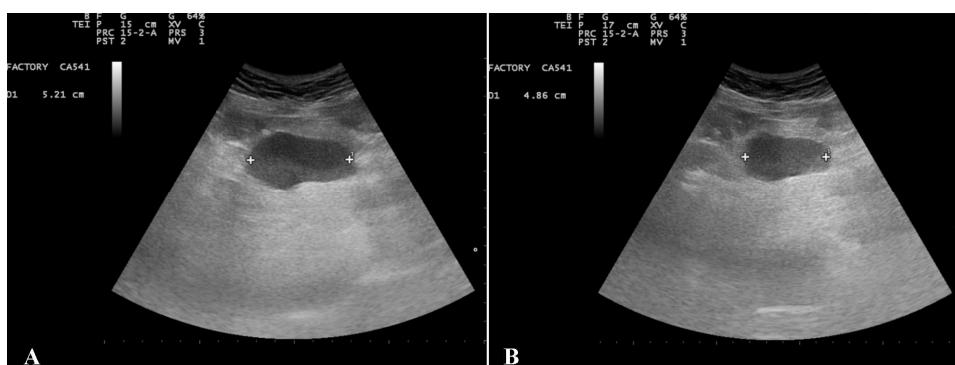


Fig. 7. Ultrasonography of abdominal nodes. A 36-year-old man was diagnosed with metastatic melanoma. After 1 week of integrative immunotherapy where OA-GcMAF (880 ng/day) was administered by alternating nebulisation and intramuscular injections, one of the lesions in the abdomen, interpreted as coalescent metastatic peritoneal nodes, measured with ultrasonography, showed a decrease of its length from 52.1 mm (panel A) to 48.6 mm (panel B). This corresponds to an approximate 7% linear diameter reduction. In this case the volume could not be fully extrapolated since the mass showed an irregular elongated shape

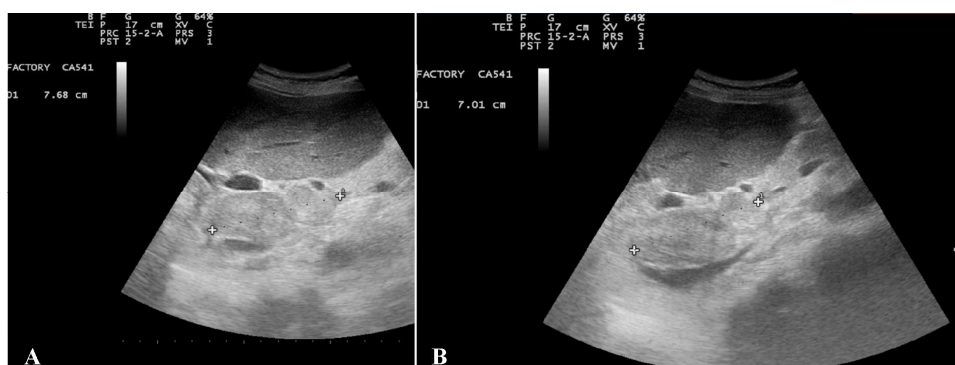

Fig. 8. Ultrasonography of abdominal metastasis. A 55-year-old woman was diagnosed with metastatic adenocarcinoma of the colon. After 3 weeks of integrative immunotherapy where OA-GcMAF (880 ng/day) was administered by alternating nebulisation, intramuscular injections and suppositories, one of the lesions in the abdomen, interpreted as one of the metastases previously described, measured with ultrasonography, showed a decrease of its length from 76.8 mm (panel A) to 70.1 mm (panel B). This corresponds to an approximate 9% linear diameter reduction. In this case the volume could not be fully extrapolated since the mass showed an irregular elongated shape

4. DISCUSSION

OA-protein complexes are bound to play a leading role in cancer therapy (Smith, 2013) thanks to the selectivity of antitumoral effects, absence of side effects, safety and oral availability (Artym and Zimecki, 2013; Puthia *et al.*, 2014).

The synthesis of OA-GcMAF, combines the known anticancer effects of OA-protein complexes with the anticancer and immune stimulating effects of GcMAF. In fact, it is well assessed that GcMAF, in addition to activating tumoricidal macrophages (Thyer *et al.*, 2013c),

directly inhibits cancer cell proliferation (Gregory *et al.*, 2010; Pacini *et al.*, 2012) as well as cancer cell-induced neo-angiogenesis.

On account of the natural absorption enhancing activity of OA, the complexed OA-GcMAF represents the physiological assembly of naturally occurring GcMAF. This new formulation allows GcMAF to be administered through a variety of more desirable routes that eliminate a major obstacles to its widespread use. This feature favours a treatment tailored to the individual patient's characteristics, with the possibility of delivering the OA-GcMAF to the sites where it can best exert its action.

Table 1. Showing the decrease in tumour volumes (as calculated by ultrasonography measurements), with the types of cancer treated and the no of weeks treatment at the point of measurement

| Patient | Cancer presentation | Weeks treated for observed results | (%) Measured decrease |
|---------|------------------------------------|------------------------------------|-----------------------|
| 1 | Metastatic colon cancer | 2 | 49.2 |
| 2 | Multiple myeloma | 4 | 29.6 |
| 3 | Metastatic breast cancer | 1 | 27.7 |
| 4 | Metastatic thyroid cancer | 4 | 13.9 |
| 5 | Metastatic renal carcinoma | 2 | 11.6 |
| 6 | Metastatic melanoma | 1 | 6.8 |
| 7 | Metastatic adenocarcinoma of colon | 3 | 8.7 |

We are well aware that the clinical cases reported here are heterogeneous and describe patients with different types of tumors at different stages. In all cases, patients had undergone a variety of conventional and complementary. In all cases, integrative immunotherapy was initiated at late stages of tumor progression since it is understandable that conventional therapies were preferred at earlier stages. In addition, since this is an open-label, non-controlled, retrospective analysis, caution must be employed when ascribing cause and effect to any treatment outcome. However, the response to integrative immunotherapy was robust (**Table 1**) and, even though any statistical analysis is inappropriate in such an heterogeneous recollection of clinical stories, the absence of adverse side effects and clinical improvement supported by objective evidences emerge evident.

5. CONCLUSION

To our knowledge, the ultrasonographic images shown here represent the first direct evidence demonstrating an anticancer effect of GcMAF (OA-GcMAF in this case) in humans. They show a significant reduction in tumor size (**Table 1**) and are fully consistent with the actual images of tumor shrinkage shown by Nonaka *et al.* (2012) reporting on the effects of GcMAF in human hepatocarcinoma cells transplanted in SCID-mice. They also show a consistent increase in splenic blood flow that has to be interpreted in the context of generalised immune system activation and allows to assess almost immediately the degree of responsiveness of the individual patient. Therefore, we suggest that diagnostic imaging rather than measurement of α -N-acetylgalactosaminidase should become the gold standard to assess the efficacy of GcMAF treatment in cancer patients.

Although almost all patients were late stage 4, it was a requirement that they were well enough to travel and be active enough to cope with residency at the Treatment

Centre. All of these patients have showed significant clinical improvements. These patients will be followed up and reported on more fully at a later date.

5.1. Potential Conflicts of Interest

DN is the CEO of immuno biotech, Ltd (the company isolating and purifying the GcMAF protein). However, DN had no knowledge of the therapies being used nor of the names of any patients whose data were being analyzed. Neither he, nor any employee of immuno biotech ltd, had any knowledge of the clinical records or the patient names used in this study.

6. REFERENCES

- Artym, J. and M. Zimecki, 2013. Milk-derived proteins and peptides in clinical trials. *Postępy Hig. Med. Dośw.*, 67: 800-816. PMID: 24018446
- Bradford, M.M., 1976. A rapid and sensitive method for the quantitation of microgram quantities of protein utilizing the principle of protein-dye binding. *Analytical Biochem.*, 72: 248-254. DOI: 10.1016/0003-2697(76)90527-3
- Bradstreet, J.J., E. Vogelaar and L. Thyer, 2012. Initial observations of elevated alpha-N-acetylgalactosaminidase activity associated with autism and observed reductions from gc protein-macrophage activating factor injections. *Autism Insights*, 4: 31-38. DOI: 10.4137/AUI.S10485
- Cokić, V.P. and A.N. Schechter, 2008. Chapter 7 effects of nitric oxide on red blood cell development and phenotype. *Curr. Top. Dev. Biol.*, 82: 169-215. DOI: 10.1016/S0070-2153(07)00007-5
- Cui, C.Y., W.L. Lu, L. Xiao, S.Q. Zhang and Y.B. Huang *et al.*, 2005. Sublingual delivery of insulin: effects of enhancers on the mucosal lipid fluidity and protein conformation, transport and *in vivo* hypoglycemic activity. *Biol. Pharmaceutical Bull.*, 28: 2279-2288. DOI: 10.1248/bpb.28.2279

- Den Hollander, P., M.I. Savage and P.H. Brown, 2013. Targeted therapy for breast cancer prevention. *Frontiers Oncol.*, 3: 250. DOI: 10.3389/fonc.2013.00250
- Fabris, A., P. Biagioni, T. Punzi, G. Morucci and M. Gulisano *et al.*, 2012. Role of angiotensin-converting enzyme and vitamin D receptor gene polymorphisms in cancer anorexia-cachexia syndrome. *Am. J. Immunol.*, 8: 65-70. DOI: 10.3844/ajisp.2012.65.70
- Fang, B., M. Zhang, M. Tian, L. Jiang and H.Y. Guo *et al.*, 2013. Bovine lactoferrin binds oleic acid to form an anti-tumor complex similar to HAMLET. *Biochim. Biophys. Acta.*, 1841: 535-543. PMID: 24368211
- Goto, S., M. Kawata, T. Suzuki, N.S. Kim and C. Ito, 1991. Preparation and evaluation of Eudragit gels. I: Eudragit organogels containing drugs as rectal sustained-release preparations. *J. Pharmaceutical Sci.*, 80: 958-961. DOI: 10.1002/jps.2600801011
- Gregory, K.J., B. Zhao, D.R. Bielenberg, S. Dridi and J. Wu *et al.*, 2010. Vitamin D binding protein-macrophage activating factor directly inhibits proliferation, migration and uPAR expression of prostate cancer cells. *PLoS One*, 5: e13428. DOI: 10.1371/journal.pone.0013428
- Guinebretière, J.M., E. Menet, A. Tardivon, P. Cherel and D. Vanel, 2005. Normal and pathological breast, the histological basis. *Eur. J. Radiol.*, 54: 6-14. DOI: 10.1016/j.ejrad.2004.11.020
- Hiroi, M., Y. Sakaeda, H. Yamaguchi and Y. Ohmori, 2013. Anti-inflammatory cytokine interleukin-4 inhibits inducible nitric oxide synthase gene expression in the mouse macrophage cell line RAW264.7 through the repression of octamer-dependent transcription. *Mediators Inflamm.*, Epub 2013: 369-693. DOI: 10.1155/2013/369693
- Ho, C.S.J., A. Rydström, M. Trulsson, J. Bålfors and P. Storm *et al.*, 2012. HAMLET: Functional properties and therapeutic potential. *Future Oncol.*, 8: 1301-1313. DOI: 10.2217/fon.12.122
- Ho, V.W., K. Leung, A. Hsu, B. Luk and J. Lai *et al.*, 2011. A low carbohydrate, high protein diet slows tumor growth and prevents cancer initiation. *Cancer Res.*, 71: 4484-4493. DOI: 10.1158/0008-5472.CAN-10-3973
- Hoque, M., S. Dave, P. Gupta and M. Saleemuddin, 2013. Oleic acid may be the key contributor in the BAMLET-induced erythrocyte hemolysis and tumoricidal action. *PLoS One*, 8: e68390. DOI: 10.1371/journal.pone.0068390
- Inui, T., D. Kuchiike, K. Kubo, M. Mette and Y. Uto *et al.*, 2013. Clinical experience of integrative cancer immunotherapy with GcMAF. *Anticancer Res.*, 33: 2917-2919. PMID: 23780980
- Iversen, P.O., G. Nicolaysen and H.B. Benestad, 1994. Endogenous nitric oxide causes vasodilation in rat bone marrow, bone and spleen during accelerated hematopoiesis. *Exp. Hematol.*, 22: 1297-1302. PMID: 7957715
- Knyazeva, E.L., V.M. Grishchenko, R.S. Fadeev, V.S. Akatov and S.E. Permyakov *et al.*, 2008. Who is Mr. HAMLET? Interaction of human alpha-lactalbumin with monomeric oleic acid. *Biochemistry*, 47: 13127-13137. DOI: 10.1021/bi801423s
- Lakritz, J.R., T. Poutahidis, T. Levkovich, B.J. Varian and Y.M. Ibrahim *et al.*, 2013. Beneficial bacteria stimulate host immune cells to counteract dietary and genetic predisposition to mammary cancer in mice. *Int. J. Cancer*. DOI: 10.1002/ijc.28702
- Lu, H.T., R.N. Chen, M.T. Sheu, C.C. Chang and P.Y. Chou *et al.*, 2011. Rapid-onset sildenafil nasal spray carried by microemulsion systems: *In vitro* evaluation and in vivo pharmacokinetic studies in rabbits. *Xenobiotica*, 41: 567-577. DOI: 10.3109/00498254.2011.563877
- Lucà-Moretti, M., A. Grandi, E. Lucà, G. Muratori and M.G. Nofroni *et al.*, 2003. Master Amino acid Pattern as substitute for dietary proteins during a weight-loss diet to achieve the body's nitrogen balance equilibrium with essentially no calories. *Adv. Therapy*, 20: 282-291. DOI: 10.1007/BF02849857
- Nathan, C.F. and J.B. Hibbs, 1991. Role of nitric oxide synthesis in macrophage antimicrobial activity. *Current Opin. Immunol.*, 3: 65-70. DOI: 10.1016/0952-7915(91)90079-G
- Nemashkalova, E.L., A.S. Kazakov, L.M. Khasanova, E.A. Permyakov and S.E. Permyakov, 2013. Structural characterization of more potent alternatives to HAMLET, a tumoricidal complex of α -lactalbumin and oleic acid. *Biochemistry*, 52: 6286-6299. DOI: 10.1021/bi400643s
- Nonaka, K., S. Onizuka, H. Ishibashi, Y. Uto and H. Hori *et al.*, 2012. Vitamin D binding protein-macrophage activating factor inhibits HCC in SCID mice. *J. Surgical Res.*, 172: 116-122. DOI: 10.1016/j.jss.2010.07.057

- Pacini, S., G. Morucci, T. Punzi, M. Gulisano and M. Ruggiero, 2011. Gc protein-derived Macrophage-Activating factor (GcMAF) stimulates cAMP formation in human mononuclear cells and inhibits angiogenesis in chick embryo chorionallantoic membrane assay. *Cancer Immunol. Immunotherapy*, 60: 479-485. DOI: 10.1007/s00262-010-0953-7
- Pacini, S., T. Punzi, G. Morucci, M. Gulisano and M. Ruggiero, 2012. Effects of vitamin d-binding protein-derived macrophage-activating factor on human breast cancer cells. *Anticancer Res.*, 32: 45-52. PMID: 22213287
- Partridge, S.C., J.E. Gibbs, Y. Lu, L.J. Esserman and D. Tripathy *et al.*, 2005. MRI measurements of breast tumor volume predict response to neoadjuvant chemotherapy and recurrence-free survival. *AJR. Am. J. Roentgenol.*, 184: 1774-1781. DOI: 10.2214/ajr.184.6.01841774
- Puthia, M., P. Storm, A. Nadeem, S. Hsiung and C. Svanborg, 2014. Prevention and treatment of colon cancer by peroral administration of HAMLET (human α -lactalbumin made lethal to tumour cells). *Gut*, 63: 131-142. DOI: 10.1136/gutjnl-2012-303715
- Ruggiero, M. and S. Pacini, 2011. The vitamin D axis in chronic kidney disease-state of the art and future perspectives. *Eur. Nephrol.*, 5: 15-19.
- Sakata, O., Y. Machida and H. Onishi, 2011. Semi-solid dosage form of clonazepam for rapid oral mucosal absorption. *Drug Dev. Ind. Pharm.*, 37: 809-814. DOI: 10.3109/03639045.2010.545069
- Smith, K., 2013. Therapy: HAMLET takes a leading role on the colorectal cancer stage. *Nat. Rev. Gastroenterol. Hepatol.*, 10: 126. DOI: 10.1038/nrgastro.2013.27
- Smith, R., L. Thyer, E. Ward, E. Meacci and J.J.V. Branca *et al.*, 2013. Effects of Gc-macrophage activating factor in human neurons; implications for treatment of chronic fatigue syndrome. *Am. J. Immunol.*, 9: 120-129. DOI: 10.3844/ajisp.2013.120.129
- Stuehr, D.J. and C.F. Nathan, 1989. Nitric oxide. A macrophage product responsible for cytostasis and respiratory inhibition in tumor target cells. *J. Exp. Med.*, 169: 1543-1555. DOI: 10.1084/jem.169.5.1543
- Thorat, M.A. and J. Cuzick, 2013. Role of aspirin in cancer prevention. *Current Oncol. Reports*, 15: 533-540. DOI: 10.1007/s11912-013-0351-3
- Thun, M.J., E.J. Jacobs and C. Patrono, 2012. The role of aspirin in cancer prevention. *Nat. Rev. Clin. Oncol.*, 9: 259-267. DOI: 10.1038/nrclinonc.2011.199
- Thyer, L., E. Ward, R. Smith, J.J. Branca and G. Morucci *et al.*, 2013a. GC protein-derived macrophage-activating factor decreases α -N-acetylgalactosaminidase levels in advanced cancer patients. *Oncoimmunology*, 2: e25769-25775. DOI: 10.4161/onci.25769
- Thyer, L., E. Ward, R. Smith, J.J.V. Branca and G. Morucci *et al.*, 2013b. Therapeutic effects of highly purified de-glycosylated GcMAF in the immunotherapy of patients with chronic diseases. *Am. J. Immunol.*, 9: 78-84. DOI: 10.3844/ajisp.2013.78.84
- Thyer, L., E. Ward, R. Smith, M.G. Fiore and S. Magherini *et al.*, 2013c. A Novel role for a major component of the vitamin D axis: Vitamin D binding protein-derived macrophage activating factor induces human breast cancer cell apoptosis through stimulation of macrophages. *Nutrients*, 5: 2577-2589. DOI: 10.3390/nu5072577
- Vogel, H.J., 2012. Lactoferrin, a bird's eye view. *Biochem. Cell Biol.*, 90: 233-244. DOI: 10.1139/o2012-016
- Yamamoto, N. and V.R. Naraparaju, 1998. Structurally well-defined macrophage activating factor derived from vitamin D3-binding protein has a potent adjuvant activity for immunization. *Immunol. Cell Biol.*, 76: 237-244. DOI: 10.1046/j.1440-1711.1998.00748.x
- Yamamoto, N., H. Suyama, N. Yamamoto and N. Ushijima, 2008a. Immunotherapy of metastatic breast cancer patients with vitamin D-binding protein-derived Macrophage Activating Factor (GcMAF). *Int. J. Cancer*, 122: 461-467. DOI: 10.1002/ijc.23107
- Yamamoto, N., H. Suyama and N. Yamamoto, 2008b. Immunotherapy for prostate cancer with Gc protein-derived macrophage-activating factor, GcMAF. *Translat. Oncol.*, 1: 65-72. DOI: 10.1593/tlo.08106
- Yamamoto, N., H. Suyama, H. Nakazato, N. Yamamoto and Y. Koga, 2008c. Immunotherapy of metastatic colorectal cancer with vitamin D-binding protein-derived macrophage-activating factor, GcMAF. *Cancer Immunol. Immunotherapy*, 57: 1007-1016. DOI: 10.1007/s00262-007-0431-z