

History of Medicine

Michelangelo's David: triumph of perfection or perfect combination of variation and disproportions? A human perspective

Matteo Della Monica¹, Pietro Antonio Bernabei³, Elena Andreucci¹, Giovanna Traficante¹, Ferdinando Paternostro², Francesca Peluso¹, Roberto Mauri⁴, Aldesia Provenzano⁵, Sabrina Giglio⁵, Ornella Casazza³, Massimo Gulisano²

¹ Medical Genetics Unit, Meyer Children's University Hospital, Viale Gaetano Pieraccini, 24 - 50139 Firenze, Italy

² Department of Experimental and Clinical Medicine, University of Florence, Largo Brambilla 3 - 50134 Firenze, Italy

³ Independent Fine Art Professional Firenze, Italia

⁴ Medical Director Elcor Rehabilitation Center Arnot Medical Center, Elmira NY, USA

⁵ Department of Clinical and Experimental Biomedical Sciences and Medical Genetics Unit, Meyer Children's University Hospital, viale Pieraccini, 24 - 50139 Firenze, Italy

Abstract

Michelangelo's marble sculpture of David is one of the most admired works of art in the world. It is the most iconic symbol of the Florentine Renaissance, and a representation of the idealized human form in its perfection and proportion. The statue was examined in 2004 by two anatomists who observed the apparent absence of a single muscle. Our re-examination of the statue, from our perspective as clinical geneticists, shows unexpected and hitherto unpublished details of variations and disproportions within the overall context of exceptional harmony and beauty. This apparent contradiction raises the question as to what is considered to be morphologically "normal" and what "is not".

Keywords

Michelangelo's David, morphology, minor anomalies, reverse phenotyping, NGS.

Introduction

In Florence in 1501, Michelangelo Buonarroti (1475-1564) began shaping the statue of David from a block of marble initially discarded by the workers of the Opera di Santa Maria del Fiore, the cathedral of Florence. The block of marble was given, in 1463, to Agostino di Duccio for the realization of a colossal statue, perhaps a prophet or David himself (DeTolnay, 1933). The statue was meant to be placed on one of the buttresses of the Florentine Cathedral (the Duomo), as from a document of the Opera dating August 18, 1464 (Poggi, 1909). Since Agostino did not complete the work, the marble was given to Antonio Rossellino on May 6, 1476, but it was abandoned in the courtyard of the Opera till August 16, 1501, when it was taken by Michelangelo, and, by that time, the idea of placing it on the top of the cathedral had almost been given up (Falletti, 2002; Goldscheider, 2004; Paolucci, 2004; Acidini Luchinat, 2010).

* Corresponding author. E-mail: ferdinando.paternostro@unifi.it

After having tested its consistency, Michelangelo, on October 14, ordered to built the "cage" of wooden board to work inside. On January 25, 1504, the statue was almost done, but the final decision on its placement had not yet been taken. Thus, a committee, including artists such as Andrea della Robbia, Cosimo Rosselli, Francesco Granacci, Piero di Cosimo, Davide Ghirlandaio, Simone del Pollaiuolo, Filippino Lippi, Sandro Botticelli, Antonio e Giuliano da Sangallo, Andrea Sansovino, Pietro Perugino, Lorenzo di Credi, was appointed to reach a decision (Goldscheider, 2004). The Herald of the Signoria proposed to place the statue next to the door of Palazzo Vecchio, in the so called "Arengario", resuming the will of Michelangelo; whereas Giuliano da Sangallo was pushing the proposal of Leonardo da Vinci to place the statue inside the "loggia dell'Orcagna", within a black niche. The final decision was that of placing the statue next to the door of Palazzo Vecchio, on the site of the "Giuditta" by Donatello, which, on June 8, 1504, was placed inside the "Loggia dell'Orcagna". Simone del Pollaiuolo and Antonio da Sangallo took care of moving the David, that, eventually, on September 8, 1504, was placed in the "Arengario" where stood up for the next three centuries (today replaced by a copy) (Landucci, 1883), and "nè mai più si è veduto un posamento sì dolce, nè grazia che tal cosa pareggi" (Vasari, 1906) ("never again has anyone seen such a beautiful and graceful masterpiece"). One of the absolute masterpieces of all time, the biblical hero stood as the perfect representation of the city of Florence; small compared to the giants of the large states of Europe, but capable of prevailing and winning with his strength and intelligence. In an epoch in which mass communication did not exist, the paintings and especially the statues situated in the city, were meant to transmit ideas and messages. Those of David are extraordinarily effective; it is a small, young, firm, determined, and winning hero. Several acts of vandalism and/or damage, caused by accident, characterized its history until the final placement in the Galleria dell'Accademia (Gallery of the Academy) of Florence, in 1872; where it is still possible to admire it today, after restoration (Figs. 1 and 2). Presently, we are lucky, as we can enjoy two copies of this masterpiece; a marble one, located in Piazza della Signoria, and a bronze one located in Piazzale Michelangelo, the terrace overlooking Florence.

Materials and methods

The statue was studied directly in the museum, thanks to the help and willingness of the then director Franca Falletti, and of professor Umberto Baldini. The measurements were made using rigid metric rulers, and measuring tape. The statue has a height of 516 cm, a weight of 5,660 kg, and a surface area of 19.47 square meters. It represents a 180-185 cm tall Caucasian male of the apparent age of 20-30 years. The actual measurements are illustrated in table 1. Of note, the traditional points of anatomical reference are accurately represented, allowing a detailed measurement of their reciprocal distances, which had been taken into account by that expert anatomist of Michelangelo (Premuda, 1957; Baldini, 1981, 2001; Condivi, 1998; Parronchi, 2003). The head is one eighth of the height. The occipito-frontal diameter measures 66.15 cm, versus the bi-parietal diameter of 43.70 cm, with a cephalic index (CI) of 66.06 (normal CI is between 76-80.9) (Gripp et al., 2013). It is important to keep in mind that when measuring the OFC in the live individual, we pay attention to the



Fig. 1. Frontal view of Michelangelo's David.




Fig. 2. Rear view of Michelangelo's David.

possible presence of thick hair, in order to avoid taking falsely elevated values. This has not been possible with the David, whose scalp hair appears thick and curly. The outer ears are of normal conformation, but the Darwin tubercle is not evident (Fig. 3). They have an angle of rotation of 22° degrees (the average value is usually between 17° and 22°) (Gripp et al., 2013) (Fig. 4). The orbital region presents a distinct feature. The distance between the outer corner and inner corner of the right eye (5.6 cm), between the inner corner of both eyes (5.09 cm), and from the inner corner to the outer corner of the left eye (6.5 cm) does not respect the perfect symmetry of the "three eyes" (Aase, 1990). The left pupil appears deviated sideways as per a mild divergent strabismus. The lips are everted and the bilateral axes are perpendicular to both alae nasi, passing slightly through the corners of the mouth (Fig. 5), which is narrow. The chin is slightly prominent but rounded. The thorax is slightly inclined. A "groove" is recognizable between the spine and the right scapula; mimicking a pos-

Table 1. Measurements made in the Gallery of the Academy of Florence, by Massimo Gulisano and Pietro Antonio Bernabei, in 2004

Chin – vertex	69,83 cm
Facial Height	55,51 cm
Head Width	43,70 cm
Head Length	66,15 cm
Cephalic Index	66,06 cm
Bizygomatic Distance	33,54 cm
Biacromial Distance	123,54 cm
Bi-iliac Distance	87,83 cm
Penile Length	15,31 cm
Torso Length	135,17 cm
VII cervical vertebrae-coccyx	157,27 cm
Upper Arm Length	108,37 cm
Forearm Length	72,39 cm
Palm Length	32,17 cm
I Phalanx of the middle finger	15,78 cm
II + III Phalanx of the middle finger	15,16 cm
Palm Width	27,72 cm
Upper Leg	102,30 cm
Lower Leg	101,96 cm
Foot Length	77,75 cm
Foot Width	32,90 cm

sible hypoplasia of the extensor muscle of the spine (Fig. 6). The arm span is 611.28 vs. the height of 516 cm. The span based on a man's height of 182.5 cm, should be 216 cm. Therefore, the span exceeds the height by at least 33.5 cm. (Fig. 7). The ratio between the proximal and distal half of the body is 1.1, when it should be less than 1 for a male over 10 years of age.

The hands show visible dorsal veins on the right and not on the left, related to the limb posture; and the tip of the right middle finger (partly flexed) is close to the knee, appearing too long (Figs. 1, and 8). The hands measure 63.11 cm and the feet 77.75 cm. The ratio of the hands and feet to the median stature (estimated as 180-185 cm), corresponds to 22.32 cm and 27 cm, respectively. Regarding the genitalia, the testes appear proportionate and of apparent normal volume for an adult male (G5 Tanner), whereas the shaft corresponds more to that of an adolescent state (G3 Tanner), with a constriction of the glans as seen in phimosis. The David is standing on his right foot, with the body slightly swiveled to the right, the left leg slightly forward and flexed at the knee, the heel lifted from the ground, the left side of pelvis tilted up, the upper body slightly turned and flexed to right, the head partly turned to left (Fig. 1,

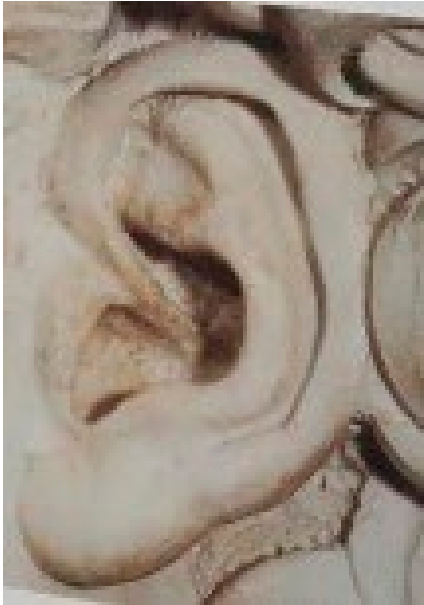

Fig. 3. The left ear of David.




Fig. 4. Lateral view of David's head and right ear angle.




Fig. 5. The face of David.

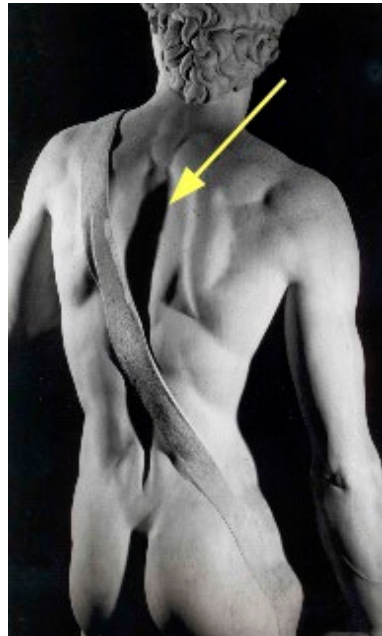


Fig. 6. The groove of the "missing muscle" on David's back.

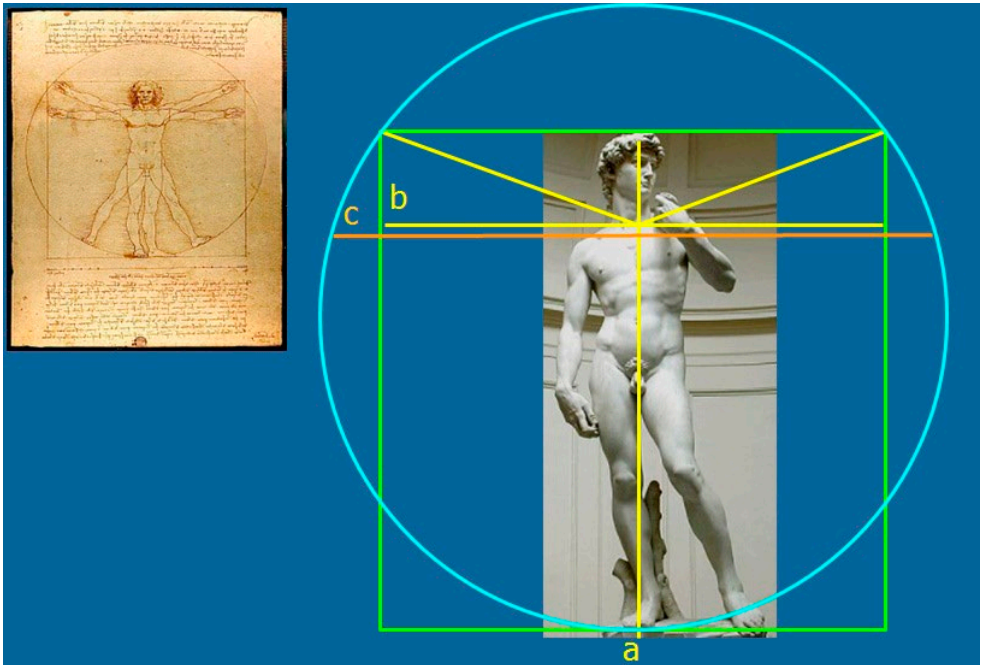


Fig. 7. a. Vertical yellow line: David's height. --b. Horizontal yellow line: Arm SPAN, cm 182.5 (as expected in relation to the height). --c. Horizontal orange line: Actual Arm SPAN (cm 216).



Fig. 8. "Physiological asymmetry".



Fig. 9. Middle panel; frontal view of David's face. Left panel: "Artificial" face constructed out of two right halves of David's face. Right panel: "Artificial" face constructed out two left halves of David's face.

and 2). In summary, the most relevant data demonstrate a "hyper"-dolichocephalic cranium, an arm span much greater than the height, an apparent unilateral extensor spinal muscle hypoplasia, and the upper section of the body almost the same as the lower one.

Discussion

The concept of the ideal human figure is credited to the Greek sculptor Polycletus, the elder, who promoted the pursuit of the theoretical model of the supreme ideal of masculine and feminine symmetry, balanced in its parts (Giuliano, 1998). Over the centuries the word "proportion" was synonymous with the "golden section" or "golden ratio", a concept that Leonardo called the "divine proportion" (Pacioli, 2010). In the third book of the treatise "De Architectura" (1990), Vitruvius describes the ideal measurements of the face and the human body, and well known is its representation of the human figure inscribed in a square and a circle (Kruft, 1988). In this context the David of Michelangelo immediately impressed as a masterpiece of extraordinary beauty; acknowledged as an example of perfection for the form of the naked body, and for the masterly interplay of apparent proportions among the different body segments. The observance of the proportions in such a big statue suggests that Michelangelo started his work identifying the points of anatomical reference, always rigorously located. However, our examination and detailed measurements of the statue, while simultaneously confirming it as a wonderful representation of the human body, showed details and characteristics that do not fit a "perfect" model. Some of these, like the broad hands, may depend more on an optical impression (the view from the base of the statue) than a real disproportion, and, moreover, may have been intended for figurative purposes to indicate specific messages, such as strength and work. The "groove" on David's back has provoked more than a dispute on its interpretation. According to some art historians and anatomists, the "groove" might be due

to the absence of the extensor muscle of the spine, probably due to a defect in the block of marble upon which Michelangelo was determined to work (Vasari, 1906; Seymour, 1967; Baldini, 1981; Falletti, 2002; Goldscheider, 2004; Alvarez-Gonzales, 2008). However, based on Michelangelo's observations, it is not unlikely that he knew how this anatomical region shows great variability in the general population. Some authors in their treatise on human anatomy, note that there is a great deal of variation in the development of the spinalis muscles (Schaeffer, 1893 and Kendall & Kendall McCreary, 2005). In addition, a recent British edition of Gray's Anatomy (1991) describes spinalis cervicis and capitis as variably blended and often absent. Of note, a recent study has reported the occurrence of an atrophy of the dorsal muscles, namely the infraspinous muscle, in professional pitchers (Pexa, 2017), whose sport is very similar to the slingsman movement (Friz, 2001). This might suggest that Michelangelo had observed such a muscle pathology frequently occurring in the slingsmen, rather than masquerading a defect in the marble. Last, but not least, the "groove" might also be explained by the dynamic posture of David, showing most of the weight on one leg, with the shoulders and arms twisted off-axis from the hips and legs. We should consider that the disproportions might correspond to the actual variations Michelangelo observed in the real world; it is well known that he and other artists of his time derived their models from the careful study of real bodies, and from their own environment (Pedretti, 2007). On several occasions, Michelangelo studied anatomy flaying cadavers to observe how the bones, muscles, nerves, and veins were tied together and would work in order to allow all the positions of the human body (Vasari, 1906). He could then be well aware of the existence of that variable physiological degree of asymmetry of the human body, known as "fluctuating asymmetry" (Opitz and Utkus, 2001), and David's face fully demonstrates it (Fig. 9). In addition, as has been done by other artists in the past, slight asymmetries or disproportions were deliberately sought in masterpieces (such as the bust of Nefertiti or the Venus Cnidia) to make the work more realistic. In the introduction of small imperfections a masterpiece gained dynamism and vitality (Bredenkamp, 2016). Working at a time of spectacular rediscovery of classical statuary in Greece, Italy, Magna Graecia, Michelangelo was keenly aware of the artistic effects used by Phidias, Praxiteles, and their peers to impress, to elicit admiration, awe, and a keen feeling of aesthetic pleasure beholding their works. This involved the deliberate introduction into their sculptures of subtle asymmetries to heighten effects and to introduce that element of surprise and "interest" that distinguishes genius from mediocrity. On the other hand, does there exist a canon of perfection that counters our scientific concept of "malformation"? Or are there always common (minor) anomalies and variants of phenotype present even in the apparently "normal" human being? It is common knowledge that there exists an extraordinary and incredible variety of size and shape of the human beings as well as of all living species. Within this range of morphological diversity, the geneticist must be able to identify, describe, and distinguish: (a) the common variants (minor phenotypic variants or phenogenesis disorders with prevalence of $>4\%$), (b) minor anomalies (phenogenesis disorders $\leq 4\%$), and (c) malformations (embryogenesis disorders) (Merks et al., 2003). Accuracy in the recognition of the human phenotype and its precise description is becoming necessary as an indispensable resource for the current use of modern research technologies (Next-Generation Sequencing) that involve the understanding of new genetic conditions, and a correct

exchange of data with other doctors, laboratories, and researchers. An international group of clinicians (2009-2013) has worked to achieve a standardization of the terms used in the description of human morphology (Hennekam et al, 2013). In the same way, quantitative characteristics should all be carefully evaluated and measured with respect to the average within that ethnicity, and in that population by sex and age (Gripp et al, 2013).

Conclusions

Michelangelo's David is an artistic masterpiece of extraordinary beauty and of apparent correct proportions obtained through a perfect knowledge of the points of anatomical reference and of their ratio and reciprocal distances. However our aim is not that of an art criticism, which is far away from our expertise, but instead an analysis of the result in the light of what we can define a Michelangelo's "anatomical style" (Gulisano e Bernabei, 2001). It is well known that he employed the knowledge acquired by means of a long dissection practice to represent through the form, and, often even through its anomalies, precise symbolic and artistic concepts. On this purpose, let's think to the "Bacco" in whom he represented a mixture of masculine and feminine traits; or to the "Crocifisso di Santo Spirito" for which he used, as a model, the cadaver of a child to express the purity of Christ uncorrupted by the sin (Vasari, 1906; Condivi, 1998; Baldini, 2001). The unbelievable artistic level of the author allows that such anomalies contribute to the artistic value of the masterpiece. At this point, we wish to stress the following: 1) the points of anatomical reference are accurately described and represented throughout the David's body; 2) the layers of dissection are accurately respected, as we can appreciate in both hands; 3) the muscles are represented either in contraction or relaxation according to the movement that a particular body part is involved in; as comes from the observation of the peroneal muscles and, even better, from the muscles of the limb going to employ the sling, and from the mimic muscles (see the contraction of the procerus and of the nares dilatator muscle, and elevator of the lip, expressing aggressiveness). All this allows us to speak of a true Michelangelo's anatomical style. Therefore, we consider significant that our detailed examination of the statue revealed surprising quantitative and qualitative morphological variations, not just explained by the initial idea of placing it on one of the buttresses of the Florentine cathedral (the Duomo). In fact, when Michelangelo took care of the marble, that initial project had been given up, and his contemporaries state that he pushed so that its placement would be in the "Arengario", moving the "Giuditta" by Donatello (which was placed there), inside the "loggia dell'Orcagna" (Landucci, 1883; Vasari, 1906; Falletti, 2002; Goldscheider, 2004; Paolucci, 2004; Acidini Luchinat, 2010). The above seemingly contradicts the view of David as a masterpiece of absolute perfection from a strictly anthropological point of view. We could instead describe it as a masterpiece of a "perfect" combination of anomalies and common traits. This correlates with our daily experiences working with real world individuals; common variants and minor anomalies may always be present even in apparently normal and harmonic phenotypes. The role of the medical geneticist that seemed to be slowly and inexorably declining, finds itself today in a renewed and essential mission. Precise measurements are valuable and

necessary to adequately define phenotypes in order to diagnose, target, and correlate them with the identified genotypes. The challenges of the technological revolution in molecular genetics (NGS) make it even more essential to establish a correct phenotypic correlation to the genomic variants not yet described or of unknown significance. Among the many messages that the marvelous statue of David gives to humanity, we have also found one for medical geneticists; i.e., the ever-present morphological variations and disproportions demonstrating the extraordinary variability of phenotypes and the beauty of each ethnicity and of each living species. Of note, the anatomical, anthropological, and biological observation of Michelangelo was highly original for those times, when the basis for the knowledge of the human body were just founded by the artists. It was only later that physicians, such as Vesalio, carried on the study, but still exploiting the artistic knowledge, turning to great artists for the anatomical tables of their own books (see G.B. Morgagni with Tiziano; R. Colombo with Michelangelo) (Premuda, 1957, Ficarra, 1968, Singer, 1993, Condivi, 1998, Parronchi, 2003).

"To escape the world, there is no surer way than through Art, and there is nothing better than Art to keep one connected to it."

Johann Wolfgang Goethe (1992).

Acknowledgments

We wish to thank the Direction of the Gallery of the Academy, the Mayor, and the Municipality of Florence; and Alice Vuoso-Mauri, Ph.D., for helping with translation of this document from Italian into English. We are very grateful to Dr. John M. Opitz for critical reading of the manuscript.

References

- Acidini Luchinat C. (2010) Michelangelo Scultore. 24 ore Cultura, Milano.
- Aase J.M. (1990) Principles of normal and abnormal embryogenesis. In: Diagnostic Dysmorphology. Plenum Company Book Medical, New York and London.
- Alvarez-Gonzales M. (2008) Michelangelo. Mondadori Electa.
- Baldini U. (1981) Michelangelo Scultore. Sansoni, Firenze.
- Baldini U. (2001) Il Crocifisso di Santo Spirito di Michelangelo. La Critica d'Arte, Vol. 10, Firenze.
- Bredenkamp H.M.L. 2016. Ohne Abweichung kein Leben-Die bildende Kunst und die Symmetrie. Nova Acta Leopoldina NF. 412: 187-209.
- Condivi A. (1998) Vita di Michelagnolo Buonarroti. S.P.E.S., Firenze.
- De Tolnay C. (1933) Michelangelo Studien. Jahrbuch der Preussischen Kunstmmlungen, 54: 95-122.
- Falletti F. (2002) Il David di Michelangelo. Sillabe, Livorno.
- Ficarra A.M. (1968) L'Anonimo Magliabechiano. Fiorentino, Napoli.
- Friz R.C. (2001) Personal Communication.
- Giuliano A. (1998) Storia dell'arte greca. Carocci, Roma.

- Goethe J.W. (1992) *Scritti sull'arte e sulla letteratura*. Stefano Zecchi (ed.). Bollati Boringhieri, Torino.
- Goldscheider L. (2004) *Michelangelo: dipinti, sculture, architetture*. Phaidon Press, London.
- Gray H. (1991) *Anatomy: Descriptive and Surgical*. John W. Parker & Son, London. Facsimile of the First Edition 1858. Longmeadow Press, Stamford, CT.
- Gripp K.W., Slavotinek A.M., Hall J.G., Allanson J.E. (2013) *Handbook of Physical Measurements*. 3rd Ed. Oxford University Press, New York and Oxford.
- Guliano M., Bernabei P.A. (2001) *Anatomia del Crocifisso ligneo di S. Spirito. La Critica d'Arte*, Vol. 10, Firenze.
- Hennekam R.C., Biesecker L.G., Allanson J.E., Hall J.G., Opitz J.M., Temple I.K., Carey J.C. (2013) Elements of morphology: general terms for congenital anomalies. *American Journal of Medical Genetics, Part A*. 161: 2726-33 (pages 11).
- Kendall F. & Kendall McCreary E. (2005) *Muscoli. Funzioni e test con postura e dolore*. Verducci, Roma.
- Kruft H.W. (1988) *Storie delle teorie architettoniche da Vitruvio al Settecento*. Laterza, Bari.
- Landucci L. (1883) *Diario Fiorentino dal 1450 al 1516*. Sansoni, Firenze.
- Merks J.H., van Karnebeek C.D., Caron H.N., Hennekam R.C. (2003) Phenotypic abnormalities: terminology and classification. *American Journal of Medical Genetics, Part A*. 123: 211-30 (pages 3).
- Opitz J.M., Utkus A. (2001) Comments on Biological Asymmetry. *American Journal of Medical Genetics*. 101: 359-369.
- Pacioli L. (2010) *De Divina Proportione*. Riproduzione anastatica della copia conservata presso la Biblioteca Ambrosiana di Milano (manoscritto 170 sup.). Silvana, Milano.
- Paolucci A. (2004) *La nascita di un mito: Michelangelo e il David*. Giunti, Firenze.
- Parronchi A. (2003) Le moment de la dissection anatomique. In: Rabbi-Bernard C. *L'anatomie chez Michel-Ange*. Hermann Editeurs de Science et Arts, Paris.
- Pedretti C. (2007) *Il tempio dell'anima*. Cartei e Bianchi, Foligno.
- Pexa B.S., Ryan E.D., Hibberd E.E., Teel E., Rucinski T.J., Myers J.B. (2017) Infraspinal cross sectional area and shoulder range of motion change following live-game baseball pitching. *Journal of Sport Rehabilitation*. 15: 1-26.
- Poggi G. (1909) *Il Duomo di Firenze. Ricordi della vita e documenti d'arte*. Rassegna nazionale, Firenze.
- Premuda L. (1957) *Storia dell'iconografia anatomica*. Martello, Milano.
- Schaeffer J.P. (1893) *Morris' Human Anatomy*. The Blakiston Company, Philadelphia.
- Seymour C. (1967) *Michelangelo's David: a search for identity*. University of Pittsburgh Press, Pittsburgh. P. 93.
- Singer C. (1993) Beginning of Academic Practical Anatomy. In: Choulan L. *History and Bibliography of Anatomical Illustration in its relations to Anatomic Science and the Graphic Arts*. Martino, Mansfield.
- Vasari G. (1906) *Le vite de' più eccellenti pittori, scultori, architettori, con nuove annotazioni e commenti di Gaetano Milanesi*. Sansoni, Firenze. 7: 153-154.
- Vitruvio Pollione M. (1990) *De Architectura Libri X*. L. Migotto (trad.). Studio Tesi, Pordenone. P. 127.