


available at www.sciencedirect.com
journal homepage: www.europeanurology.com/eufocus



Infections

Infectious Complications After Laser Vaporization of Urinary Stones During Retrograde Intrarenal Surgery Are Not Associated with Spreading of Bacteria into Irrigation Fluid but with Previous Use of Fluoroquinolones

Tommaso Cai^{a,*}, Andrea Cocci^b, Franco Coccarelli^a, Lorenzo Ruggera^c, Paolo Lanzafame^d, Patrizio Caciagli^e, Gianni Malossini^a, Alfonso Crisci^b, Alberto Trinchieri^f, Giampaolo Perletti^{g,h}, Marco Carini^b, Gernot Bonkatⁱ, Riccardo Bartoletti^j, Truls E. Bjerklund Johansen^k

^a Department of Urology, Santa Chiara Hospital, Trento, Italy; ^b Department of Urology, University of Florence, Florence, Italy; ^c Department of Urology, University of Padua, Padua, Italy; ^d Department of Microbiology, Santa Chiara Regional Hospital, Trento, Italy; ^e Department of Laboratory Medicine, Santa Chiara Regional Hospital, Trento, Italy; ^f Urology Unit, Manzoni Hospital, Lecco, Italy; ^g Department of Biotechnology and Life Sciences, Section of Medical and Surgical Sciences, Università degli Studi dell'Insubria, Varese, Italy; ^h Faculty of Medicine and Medical Sciences, Ghent University, Ghent, Belgium; ⁱ Department of Urology, alta uro AG, Basel, Switzerland; ^j Department of Urology, University of Pisa, Pisa, Italy; ^k Department of Urology, Oslo University Hospital, Oslo, Norway

Article info

Article history:

Accepted February 25, 2019

Associate Editor:

Richard Lee

Keywords:

Bacteriuria
Retrograde intrarenal surgery
Antibiotic resistance
Urinary tract infection
Urinary stones

Abstract

Background: The pathogenesis of infectious complications after retrograde intrarenal surgery (RIRS) is not fully understood.

Objective: To evaluate spreading of bacteria into irrigation fluid and blood during RIRS for stone management and to correlate such spreading with infectious complications.
Design, setting, and participants: From January to December 2017, 38 patients who underwent RIRS for stones in two urological units were enrolled in this prospective, longitudinal cohort study.

Intervention: A urine culture was taken before surgery and antimicrobial prophylaxis was given in line with the European Association of Urology guidelines. Blood and irrigation fluid samples were collected at the start of the endoscopic procedure and every 30 min during the procedure. All samples were microbiologically examined and findings were compared with clinical data.

Outcome measurements and statistical analyses: Symptomatic and asymptomatic urinary tract infectious complications were correlated with microbiological and clinical data, using Student *t* test or Mann–Whitney *U* test.

Results and limitations: Ten patients showed significant bacterial growth in irrigation fluid samples (seven *Escherichia coli*, two *Klebsiella pneumoniae*, and one *Pseudomonas aeruginosa*). Eight patients (21%) got febrile urinary tract infections during hospital stay: two had bacterial growth in the irrigation fluid (25%) and one also had bacteremia (12.5%). No correlation was found either between the bacterial growth in the irrigation fluid samples and the urine cultures that were taken before the procedure, or between the bacterial growth in the irrigation fluid samples and the development of postoperative infectious complications. Previous use of fluoroquinolones and a history of urinary tract infections were associated with infectious complications after RIRS.

* Corresponding author. Department of Urology, Santa Chiara Hospital, Largo Medaglie d'Oro 9, Trento, Italy. Tel.: +39 0461 903306; Fax: +39 0461 903101.
E-mail address: ktommy@libero.it (T. Cai).

<https://doi.org/10.1016/j.euf.2019.02.018>

2405–4569/© 2019 European Association of Urology. Published by Elsevier B.V. All rights reserved.

Please cite this article in press as: Cai T, et al. Infectious Complications After Laser Vaporization of Urinary Stones During Retrograde Intrarenal Surgery Are Not Associated with Spreading of Bacteria into Irrigation Fluid but with Previous Use of Fluoroquinolones. *Eur Urol Focus* (2019), <https://doi.org/10.1016/j.euf.2019.02.018>

Conclusions: We demonstrated spreading of bacteria into the irrigation fluid during RIRS procedures, but this spreading was not associated with the development of infectious complications. Particular attention should be given to previous antibiotic treatment before administration of antimicrobial prophylaxis.

Patient summary: Bacterial spreading into irrigation fluid is a common finding during retrograde intrarenal surgery, but it is not associated with infectious complications after the procedure. Particular attention should be given to previous antibiotic treatment before administration of antimicrobial prophylaxis.

© 2019 European Association of Urology. Published by Elsevier B.V. All rights reserved.

1. Introduction

Over the last 10 yr, retrograde intrarenal surgery (RIRS) has become an increasingly important option for the treatment of kidney stones [1,2]. Despite a high safety profile, severe complications such as urosepsis and death have been described [3,4]. Urinary tract infection (UTI) is the most common complication after stone treatment, and a 4.4% risk of postoperative fever and 0.7% risk of sepsis have been reported despite adequate perioperative antimicrobial prophylaxis (PAP) [5]. The most likely pathogenetic mechanism for infectious complications is that stone-contained bacteria enter the urine with systemic transudation, resulting in symptomatic UTI or sepsis [6]. In order to reduce the risk of

symptomatic UTI and urosepsis after RIRS, American Urological Association guidelines suggest to operate only on patients with sterile urine, to administer prophylactic antibiotics in all patients, to irrigate with caution while checking the continuous outflow, not to exceed 2 h of operation time, and to observe patients carefully in the first 6 postoperative hours [7]. On the contrary, the European Association of Urology (EAU) guidelines suggest using PAP only in patients at a high risk of infections complications. Potential risk factors are stone size, location of the stone, bleeding, and the surgeon's experience [8]. However, despite these recommendations, until today no study has demonstrated spreading of bacteria into irrigation fluid or blood during RIRS. Filling this knowledge gap would improve the

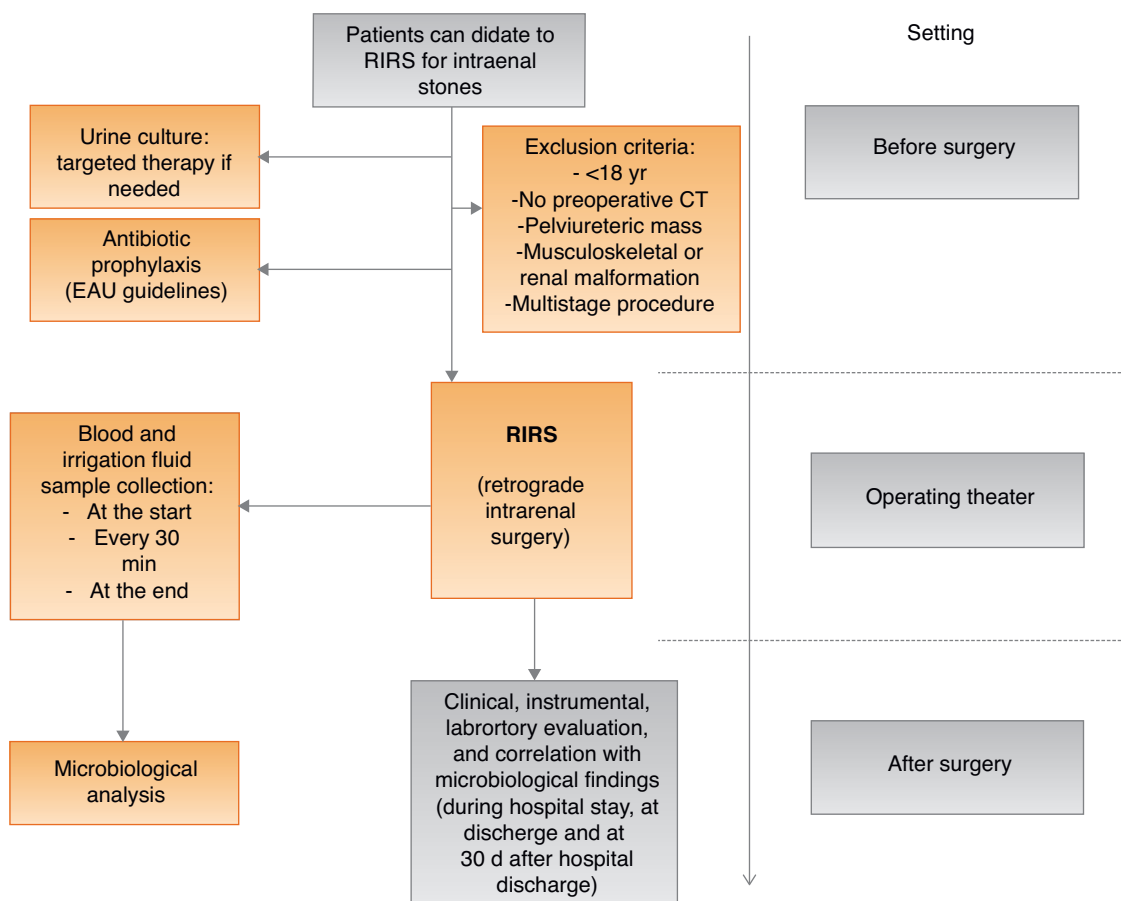


Fig. 1 – Study schedule according STROBE guidelines. CT = computed tomography; EAU = European Association of Urology; RIRS = retrograde intrarenal surgery.

rationale for PAP, and help identify the most appropriate antibiotic and the administration schedule. We aim to analyze spreading of bacteria into the irrigation fluid and blood during RIRS for intrarenal stones, and to correlate findings with clinical parameters and the development of infectious complications after the procedure.

2. Patients and methods

2.1. Study population, design, and schedule

From January 2017 to December 2017, we recruited 38 patients in two urological units for this longitudinal cohort study. All patients underwent RIRS for intrarenal stones. Urine cultures were taken before surgery and PAP was administered in line with EAU guidelines [8]. In case of positive urine culture before the RIRS, a targeted therapy was administered and a new urine sample was analyzed before surgery in order to demonstrate a negative culture. Blood and irrigation fluid samples were collected at the start of the endoscopic procedure and every 30 min thereafter until the end of the procedure. Reported symptomatic and asymptomatic urinary tract infectious complications were recorded, and correlated with microbiological and clinical data. Figure 1 shows the study schedule. The study primary endpoint was the prevalence of febrile or afebrile infectious complications after RIRS, and the correlation between these complications and the bacterial spreading into the irrigation fluid and blood, taken during the procedure. This study was performed as a longitudinal cohort study [9], in line with the STROBE statement (<http://www.strobe-statement.org/>).

2.2. Clinical and procedural considerations

All patients underwent RIRS in line with the EAU guidelines on urolithiasis [10]. All procedures were performed by two dedicated and experienced endourologists (F.C., Trento, and A.C., Florence). Stone burden, collecting system anatomy, and stone characteristics were preoperatively evaluated by a computed tomography (CT) scan. Stone size was calculated by measurement of the longest diameters. All patients were positioned in the dorsal lithotomy position. Before RIRS, a diagnostic semirigid ureterorenoscopy (8 Fr; Karl Storz, Tuttlingen, Germany) was performed. This procedure was also routinely used for dilatation of the ureter. After that a 9.5- or 11.5-Fr ureteral access sheath (Cook Medical) was placed in position. A 7.5-Fr Flex-X2 flexible ureteroscope (Karl Storz) was inserted through the access sheath. Normal saline irrigation was used with a standard pressurized irrigation system (100 mmHg). A 272- μ m laser fiber was used for treatment of all stones. The holmium laser power was set to 10 W. Fragmented stones were removed successively. Following the completion of stone removal, the ureter was visualized all along its length to see any ureteral injury. A ureteral stent was not routinely placed after the procedure; it was placed when there was mucosal edema or injury of the mucosa, or the duration of the procedure was ≥ 2 h. The ureteral stent was usually removed within 2–4 wk postoperatively [11]. Moreover, intraoperative pyelograms were not routinely performed, but only in selected cases. The diagnosis of symptomatic UTI after RIRS was based on the following parameters: patient interview and patient-reported symptoms, physical examination, bedside dipstick urinalysis, and urine culture [8]. Previous antibiotic therapy and history of UTI were defined, respectively, as the use of antibiotics for the management of UTI in the previous 6 mo [12], and one or more UTI episodes in the past year [13]. We excluded all patients <18 yr old; patients with no available preoperative CT images, with a pelviureteric mass, and with musculoskeletal or renal malformation; and patients with a multistage procedure. RIRS was considered successful in patients who became completely stone free or had clinically insignificant residual (<3 mm) at the postoperative imaging.

2.3. Microbiological and laboratory examinations

The microbiological and laboratory analyses used have been described by us in previous reports [14,15]. All clean-catch midstream urine samples were collected close to the procedure and immediately before the PAP was given. During RIRS, a venous blood sample was collected from the patient's arm by the nurse anesthetist in the operating theatre at the start of the endoscopic procedure and every 30 min until the end of the procedure. A 10 cc sample of irrigation fluid was collected through the working/irrigation channel in the renal pelvis immediately before the stone fragmentation. The collection methods and the volume of the

Table 1 – Clinical, instrumental, and laboratory characteristics of patients.

No. of patients	38
Median age (\pm SD)	48.1 (\pm 7.5)
Charlson Comorbidity Index	1 (0–2)
Comorbidities	
Diabetes	3 (7.8)
Hypertension	12 (31.5)
Chronic cardiovascular diseases	1 (2.6)
Sex	
Male	18 (47.3)
Female	20 (52.7)
BMI, kg/m ² (\pm SD)	24.3 (\pm 2.5)
History of UTI and antibiotic use	
Yes	7 (18.4)
No	31 (81.6)
History of previous stone surgery or DJ placement	
Yes	5 (13.2)
No	33 (86.8)
Stone size, mm (\pm SD)	25.3 (\pm 11.3)
Stone composition	
Calcium oxalate	30 (78.9)
Struvite	2 (5.3)
Uric acid	2 (5.3)
Calcium phosphate	(7.9)
Cystine	1(2.6)
Stone location	
Renal pelvis	14 (36.8)
Upper calyx	3 (7.8)
Middle calyx	11 (29.1)
Lower calyx	10 (26.3)
Mean stone density (HU unit)	815.7 \pm 353.5
Side	
Right kidney	21 (55.2)
Left kidney	17 (44.8)
Presence of hydronephrosis	3 (7.8)
Operation time (min), mean \pm SD	48 \pm 11.8
Stone-free rate	27 (71.1)
Irrigation volume (ml), mean \pm SD	2008.4 \pm 756.8
Irrigation flow/rate (ml/min), mean \pm SD	41.0 \pm 10.4
Hospitalization time (d), mean (range)	3 (1–7)
Urine culture result before surgery	
Negative	32 (84.3)
Positive*	6 (15.7)
Isolated strains from urine culture*	
<i>E. coli</i> ESBL–	4 (66.6)
<i>Citrobacter freundii</i>	1 (16.7)
<i>K. pneumoniae</i> ESBL–	1 (16.7)
Antimicrobial prophylaxis (drug) on 32 patients with negative preoperative urine culture	
Aminoglycoside	6 (18.7)
Ampicillin/sulbactam	6 (18.7)
Cephalosporins	3 (9.4)
Fluoroquinolones	17 (53.2)

BMI = body mass index; DJ = double J; ESBL– = negative extended-spectrum β -lactamase strain; HU unit = Hounsfield unit; SD = standard deviation; UTI = urinary tract infection.

sample had been discussed with the microbiologists before the start of the study. An irrigation fluid sample was collected every 30 min until the end of the procedure. All urine and blood samples were immediately taken to the laboratory under refrigerated conditions. Microbiological cultures were performed according to Hooton et al [16]. For microbiological diagnosis, a colony count of $\geq 10^5$ units/ml was considered the cutoff for significant bacterial finding.

2.4. Statistical analysis and ethical considerations

Continuous variables were given as means (standard deviations) and compared using Student *t* test or Mann–Whitney *U* test. Owing to the study design, no sample size calculation was needed. All reported *p* values were two sided. Statistical analyses were performed using IBM SPSS 20.0 software for Apple-Macintosh (IBM, NY, USA). Dedicated informed consent was not required as all procedures were performed according to standard routines. All patients signed the informed consent related to the surgical procedure, and were informed about the nature of the study and the blood and irrigation fluid sample collection during the procedure. They were informed that the sample collection would not prolong the operating time and would not impact the RIRS outcome. Our study was conducted in line with the Good Clinical Practice guidelines and the ethical principles laid down in the latest version of the Declaration of Helsinki. All anamnestic, clinical, and laboratory data containing sensitive information about patients were deidentified in order to ensure analysis of anonymous data only. The deidentification process was performed by nonmedical staff by means of dedicated software.

3. Results

All anamnestic, laboratory, instrumental, and microbiological characteristics of analyzed patients are described in Table 1. Three patients showed a grade I hydronephrosis. The stone-free rate after RIRS is displayed in Table 1. Six out of 38 patients showed positive urine cultures before RIRS and were treated in line with antibiogram results. All microbiological findings and treatment schedules are also described in Table 1.

3.1. Microbiological findings and correlation with infectious complications

Ninety-six irrigation fluid and 93 blood samples were collected. About 3.5 samples per patient were collected. In three patients, the last blood sample was not collected due to anesthesiological problems. Among all patients, 10 showed significant bacterial growth in the irrigation fluid samples. In this group, all patients had significant bacterial growth in one or more irrigation fluid samples (range 1–3). By contrast, one patient showed bacterial growth in the blood during the procedure. Eight patients (21%) developed febrile UTIs during hospital stay. Among patients with infectious complications, two showed bacterial growth in the irrigation fluid (25%) and one also showed bacteremia (12.5%). On the contrary, among all patients without complications, eight out of 30 showed bacterial growth in the irrigation fluid (26.6%). No multiple strains were isolated. All microbiological findings are displayed in Tables 2 and 3. Twenty-one patients (55.2%) showed asymptomatic bacteriuria (ABU) during hospital stay. In line with the EAU guidelines on urological infections, no patients were treated for this ABU. Moreover, eight patients (21%) showed febrile UTIs after the procedure, which required antibiotic treatment. Six patients required a longer period of hospitalization and parenteral broad-spectrum antibiotic treatment. No severe complications were reported. The most common causative pathogen was fluoroquinolone-resistant *Escherichia coli*. Among all patients without infectious complications after RIRS, four reported previous use of fluoroquinolones and a history of UTI (13.3%).

3.2. Subanalysis of all patients with symptomatic UTI

Eight of 38 patients (21%) reported symptomatic UTI after the procedure. In this cohort, one patient showed spreading

Table 2 – Microbiological findings during procedures and follow-up results.

No. of total collected samples (blood and urine)			189
No. of samples collected for patient, median (range)			3.5 (2–6)
Bacterial growth			
Total			11 (28.9)
Irrigation fluid			10
Blood			1
Isolated strains from irrigation fluid			
<i>E. coli</i>			7
<i>K. pneumoniae</i>			2
<i>P. aeruginosa</i>			1
Patients with symptomatic and asymptomatic bacteriuria after procedure			
Symptomatic (febrile) UTI			8
Asymptomatic bacteriuria			21
	Patients with symptomatic UTI after procedure	Patients with asymptomatic UTI after procedure	Total
Bacterial growth			
Irrigation fluid	2 (25) (<i>E. coli</i>)	5 (16.6) (<i>E. coli</i>) 2 (6.6) (<i>K pneumoniae</i>) 1 (3.3) (<i>P. aeruginosa</i>)	7 2 1
Blood	1 (12.5) (<i>P. aeruginosa</i>)	0	1
No bacterial growth	5	22	27
Total	8	30	38
UTI = urinary tract infection.			

Table 3 – Susceptibility of all isolated strains.

Patients with symptomatic infectious complications (8)		
Irrigation fluid		
<i>E. coli</i> (2 strains)		
	Sensitive/resistant	
	Strain 1	Strain 2
Amikacin	S	S
Amixio/clavulanic acid	R	S
Ceftazidime	R	S
Ciprofloxacin	R	R
Gentamicin	S	S
Imipenem	S	S
Levofloxacin	R	R
Piperacillin-tazobactam	R	S
Sulfamethoxazole	R	R
ESBL	+	-
Blood		
<i>P. aeruginosa</i>		
	Sensitive/resistant	
Amikacin	S	
Amixio/clavulanic acid	R	
Cefepime	R	
Ceftazidime	R	
Ciprofloxacin	R	
Colistina	S	
Gentamicin	S	
Imipenem	S	
Levofloxacin	R	
Piperacillin-tazobactam	S	
Sulfamethoxazole	R	
ESBL	+	
Patients without symptomatic infectious complications (30)		
Irrigation fluid		
<i>E. coli</i> (5 strains)		
	Sensitive/resistant	
	Strain 1	
Amikacin	S	
Amixio/clavulanic acid	S	
Ceftazidime	S	
Ciprofloxacin	S	
Gentamicin	S	
Imipenem	S	
Levofloxacin	S	
Piperacillin-tazobactam	S	
Sulfamethoxazole	R	
ESBL	-	
<i>K. pneumoniae</i> (2 strains)		
	Sensitive/resistant	
	Strain 1	Strain 2
Amikacin	S	S
Amixio/clavulanic acid	S	R
Ampicillin	R	R
Cefepime	S	S
Ciprofloxacin	S	S
Gentamicin	S	S
Imipenem	S	S
Levofloxacin	S	S
Piperacillin-tazobactam	S	S
Sulfamethoxazole	S	R
ESBL	-	-
<i>P. aeruginosa</i> (1 strains)		
	Sensitive/resistant	
	Strain 1	
Amikacin	R	
Amixio/clavulanic acid	R	
Cefepime	S	
Ceftazidime	S	
Ciprofloxacin	S	
Gentamicin	S	
Imipenem	S	
Levofloxacin	S	
Piperacillin-tazobactam	R	

Table 3 (Continued)

Patients with symptomatic infectious complications (8)	
Sulfamethoxazole	R
ESBL	-

ESBL- = negative extended-spectrum β-lactamase strain.

of bacteria into the blood (*Pseudomonas aeruginosa*—extended-spectrum β-lactamase- and fluoroquinolone-resistant strain). All these patients had received PAP with fluoroquinolones, and in one case, a combination of fluoroquinolone and an aminoglycoside. No clinically relevant comorbidities were reported. In three cases, a history of previous UTI and previous use of antibiotic (fluoroquinolones) were reported (37.5%). No patients showed bacterial growth at urine culture before RIRS. No significant differences were reported in terms of site/size of stones, history of previous stone surgery, or DJ placement between this cohort and the other patients who did not report any symptomatic UTI after the procedure (Table 4). No significant relationship between irrigation volume, duration of the procedure, and infectious complications was reported after RIRS.

Among all patients who reported infectious complications, two showed bacterial growth (25%), while eight out of 30 patients without complications (26.6%) had bacterial growth. No correlation was found between bacterial growth in the irrigation fluid samples and postoperative symptomatic or asymptomatic infectious complications ($p = 1.0$). No correlation was found between bacterial growth in the irrigation fluid samples and urine cultures taken before the procedure.

4. Discussion

4.1. Main findings

Spreading of bacteria into the irrigation fluid is commonly found during RIRS procedures, but not bacteremia. However, we found no correlation between the spreading of bacteria into the irrigation fluid and infectious complications after RIRS. Moreover, patients with previous use of fluoroquinolones seem to be at a high risk of developing infectious complications after RIRS.

4.2. Results compared with previous studies

Mitsuzuka and coworkers [17] recently demonstrated that despite PAP, the degree of preoperative pyuria was associated with the rate of infectious complications after ureteroscopy. Careful management of patients with pyuria or a history of upper UTIs is needed in order to reduce the risk of postoperative febrile UTI or urosepsis [17]. Several authors demonstrated that pyuria is an important risk factor for developing infectious complications after the procedure and PAP is able to reduce this risk [18]. A recent systematic review and meta-analysis demonstrated that a single dose

Table 4 – Comparison between patients with UTI and without UTI after RIRS.

	Without symptomatic UTI	With symptomatic UTI	p value
Number of patients	30	8	
Time to develop infectious complications (postoperative day, mean (range))	–	1 (1–3)	
Median age (\pm SD)	47.5 (\pm 3.2)	49.3 (\pm 5.4)	0.23
Sex			
Male	13 (43.3)	5 (62.5)	0.43
Female	17 (56.7)	3 (37.5)	
Charlson Comorbidity Index	1 (0–2)	1 (0–2)	–
Previous history of UTI and antibiotic use			
Yes	4 (13.3)	3 (37.5)	0.14
No	26 (86.7)	5 (62.5)	
History of previous stone surgery or DJ placement			
Yes	4 (13.3)	1 (12.5)	1.0
No	26 (86.7)	7 (87.5)	
Stone size, mm (\pm SD)	24.8 (\pm 12.1)	25.8 (\pm 10.1)	0.83
Urine culture result before surgery			
Negative	24 (80)	8 (100)	0.30
Positive	6 (20)	–	
Antimicrobial prophylaxis on 32 patients with negative preoperative urine culture			
Fluoroquinolones	20 (66.6)	7 (87.5)	0.74
Fluoroquinolones + aminoglycoside	–	1 (12.5)	
Cephalosporins	3 (10)	–	
Ampicillin/sulbactam	1 (3.3)	–	
Presence of hydronephrosis	2 (6.6)	1 (12.5)	0.51
Operation time, min (mean \pm SD)	47.9 \pm 11.9	48.2 \pm 11.6	0.94
Irrigation volume, ml (mean \pm SD)	2000.3 \pm 768.7	20 011.7 \pm 747.3	0.97
Irrigation flow/rate, ml/min (mean \pm SD)	40.7 \pm 12.1	42.1 \pm 9.8	0.76

DJ = double J; RIRS = retrograde intrarenal surgery; SD = standard deviation; UTI = urinary tract infection.

of prophylactic antibiotics is beneficial in reducing the rate of postoperative pyuria and bacteriuria, although there was no statistically significant benefit in reducing postoperative UTIs [19]. The efficacy of PAP in reducing the risk of infectious complications is, theoretically, due to the effect of the antibiotic on the spreading of bacteria in the kidney during lithotripsy. For these reasons, international guidelines suggest to use antibiotics with a high concentration in the urine in order to control this bacterial spread. This recommendation is not based on accurate knowledge of the pathogenesis of the postoperative infectious complications after RIRS, but is based on clinical studies [7,8,20]. Even if the recommendations for PAP are based on clinical trial data, the present study gives important new information for a broader comprehension of the pathophysiology of infectious complications after modern lithotripsy.

Spreading of bacteria into the irrigation fluid during the surgical procedure has previously been hypothesized but not documented. Our finding that there is no correlation between the spreading of bacteria into the irrigation fluid and the development of symptomatic infectious complications after procedure extends our comprehension of the pathogenesis of infectious complications after RIRS. Tokas et al [21] highlighted the role of irrigation volume and irrigation flow rate as independent risk factors for SIRS after RIRS [22]. Moreover, increasing the irrigation volume is correlated with an increase in intrarenal pressures and a subsequent increased risk of infectious complications. Here, we did not find any significant correlation between irrigation volume and infectious complications. This is probably due to the fact that we used a ureteral access sheath in all

procedures in order to maintain a low level of intrarenal pressure, as recommended [23]. However, this is only a hypothesis because we did not measure the intrarenal pressure. According to Tokas et al [21], measurement of intrarenal pressure is not a standardized procedure, and the reproducibility and accuracy are low. However, we totally agree that increased intrarenal pressure remains a neglected predictor of upper tract endourology complications and that intraoperative monitoring should be considered. On the contrary, the absence of a correlation between preoperative urine culture results, bacterial spreading, and development of infectious complications calls for a rethink of the principles of PAP. The aim of PAP should be to decrease bacterial load in the surgical field in order to decrease the risk of infectious complications. In the RIRS procedure, the surgical field is the urinary tract, but the infectious complications are the results of bacterial spread into the blood with subsequent systemic infection. Hence, the ideal antibiotic to use for preventing infectious complications after RIRS should achieve a higher blood concentration than minimal inhibitory concentration for all causative pathogens. In our study, eight patients developed symptomatic UTI after RIRS (21%). On analysis of this cohort of patients, we found that in only one case, spreading of a bacterium into the blood was reported. In this case, previous use of fluoroquinolones and a UTI history were reported. Moreover, in two other patients with infectious complications after RIRS, previous treatment with fluoroquinolones for UTI was reported too. Accurate evaluation of the patient's characteristics and anamnestic data is important before PAP is decided. Another point to consider is the local

bacterial resistance rate. Today, resistance to nearly all classes of antibiotics is growing dramatically [24]. Therefore, the prescription of fluoroquinolone-based PAP should be avoided, and should only be used by exception in patients who did not receive fluoroquinolone drugs in the last 6 mo and who do not live in an area with a high prevalence of fluoroquinolone-resistant strains [12].

4.3. Strengths and limitations of this study

An important point to highlight is the prospective nature of this study that allows reducing the bias related to data collection. Moreover, a single experienced surgeon in each center should also be considered a strength of this study. On the contrary, the limited number of enrolled patients could be considered a limitation, but the complexity of sample collection and analysis should be taken into account. Furthermore, the lack of stone cultures is a limitation of our study. Several authors reported the value of obtaining urine directly from the renal pelvis for culture in order to guide prompt and appropriate antibiotic treatment for patients who develop postoperative infectious complications after stone surgery [25,26]. However, in our centers, we do not routinely perform stone culture. The lack of intrarenal pressure measurement should also be considered a limitation of this study.

5. Conclusions

This study showed spreading of bacteria into the irrigation fluid but not into the blood during RIRS. Moreover, bacterial spreading into the irrigation fluid is not associated with infectious complications after RIRS. Future studies should be planned to confirm these results, but our findings call for a rethink of the principles of using PAP before RIRS.

Author contributions: Tommaso Cai had full access to all the data in the study and takes responsibility for the integrity of the data and the accuracy of the data analysis.

Study concept and design: Cai, Coccarelli, Cocci.

Acquisition of data: Crisci, Coccarelli, Cocci.

Analysis and interpretation of data: Cai, Ruggera, Lanzafame, Caciagli.

Drafting of the manuscript: Cai, Cocci.

Critical revision of the manuscript for important intellectual content: Trinchieri, Bonkat, Johansen.

Statistical analysis: Cai.

Obtaining funding: None.

Administrative, technical, or material support: None.

Supervision: Perletti, Malossini, Carini, Bartoletti.

Other: None.

Financial disclosures: Tommaso Cai certifies that all conflicts of interest, including specific financial interests and relationships and affiliations relevant to the subject matter or materials discussed in the manuscript (eg, employment/affiliation, grants or funding, consultancies, honoraria, stock ownership or options, expert testimony, royalties, or patents filed, received, or pending), are the following: None.

Funding/Support and role of the sponsor: None.

References

- [1] Giusti G, Proietti S, Pescechera R, et al. Sky is no limit for ureteroscopy: extending the indications and special circumstances. *World J Urol* 2015;33:257–73.
- [2] Cindolo L, Castellano P, Scoffone CM, et al. Mortality and flexible ureteroscopy: analysis of six cases. *World J Urol* 2016;34:305–10.
- [3] Fall B, Mouracade P, Bergerat S, Saussine C. Flexible ureteroscopy and laser lithotripsy for kidney and ureter stone: indications, morbidity and outcome. *Prog Urol* 2014;24:771–6.
- [4] Watson JM, Chang C, Pattaras JG, Ogan K. Same session bilateral ureteroscopy is safe and efficacious. *J Urol* 2011;185:170–4.
- [5] Berardinelli F, De Francesco P, Marchioni M, et al. Infective complications after retrograde intrarenal surgery: a new standardized classification system. *Int Urol Nephrol* 2016;48:1757–62.
- [6] Wollin DA, Joyce AD, Gupta M, et al. Antibiotic use and the prevention and management of infectious complications in stone disease. *World J Urol* 2017;35:1369–79.
- [7] Wolf JS, Bennett CJ, Dmochowski RR, et al. Best practice policy statement on urologic surgery antimicrobial prophylaxis. <https://http://www.auanet.org/common/pdf/education/clinical-guidance/Antimicrobial-Prophylaxis.pdf>2014.
- [8] EAU. European Association of Urology guidelines on urological infections, update 2018. <http://uroweb.org/guideline/urological-infections/>.
- [9] Porta M, editor. *A dictionary of epidemiology*. ed. 5. New York, NY: Oxford University Press; 2008.
- [10] EAU. European Association of Urology guidelines on urolithiasis, update 2018. <http://uroweb.org/guideline/urolithiasis/>.
- [11] Demirbas A, Yazar VM, Ersoy E, et al. Comparison of percutaneous nephrolithotomy and retrograde intrarenal surgery for the treatment of multicalyceal and multiple renal stones. *Urol J* 2018;15:318–22.
- [12] Sundvall PD, Elm M, Gunnarsson R, et al. Antimicrobial resistance in urinary pathogens among Swedish nursing home residents remains low: a cross-sectional study comparing antimicrobial resistance from 2003 to 2012. *BMC Geriatr* 2014;14:30.
- [13] Parker AS, Cerhan JR, Lynch CF, Leibovich BC, Cantor KP. History of urinary tract infection and risk of renal cell carcinoma. *Am J Epidemiol* 2004;159:42–8.
- [14] Cai T, Mazzoli S, Mondaini N, et al. The role of asymptomatic bacteriuria in young women with recurrent urinary tract infections: to treat or not to treat? *Clin Infect Dis* 2012;55:771–7.
- [15] Cai T, Lanzafame P, Caciagli P, et al. Role of increasing leukocyturia for detecting the transition from asymptomatic bacteriuria to symptomatic infection in women with recurrent urinary tract infections: a new tool for improving antibiotic stewardship. *Int J Urol* 2018;25:800–6.
- [16] Hooton TM, Scholes D, Gupta K, Stapleton AE, Roberts PL, Stamm WE. Amoxicillin-clavulanate vs ciprofloxacin for the treatment of uncomplicated cystitis in women: a randomized trial. *JAMA* 2005;293:949–55.
- [17] Mitsuzuka K, Nakano O, Takahashi N, Satoh M. Identification of factors associated with postoperative febrile urinary tract infection after ureteroscopy for urinary stones. *Urolithiasis* 2016;44:257–62.
- [18] Hsieh CH, Yang SS, Lin CD, Chang SJ. Are prophylactic antibiotics necessary in patients with preoperative sterile urine undergoing ureterorenoscopic lithotripsy? *BJU Int* 2014;113:275–80.
- [19] Lo CW, Yang SS, Hsieh CH, Chang SJ. Effectiveness of prophylactic antibiotics against post-ureteroscopic lithotripsy infections: systematic review and meta-analysis. *Surg Infect (Larchmt)* 2015;16:415–20.
- [20] Matsumoto T, Kiyota H, Matsukawa M, et al. Japanese guidelines for prevention of perioperative infections in urological field. *Int J Urol* 2007;14:890–909.

- [21] Tokas T, Herrmann TRW, Skolarikos A, Nagele U, Training and Research in Urological Surgery and Technology (T.R.U.S.T.) Group. Pressure matters: intrarenal pressures during normal and pathological conditions, and impact of increased values to renal physiology. *World J Urol* 2019;37:125–31.
- [22] Zhong W, Leto G, Wang L, Zeng G. Systemic inflammatory response syndrome after flexible ureteroscopic lithotripsy: a study of risk factors. *J Endourol* 2005;29:25–8.
- [23] Breda A, Territo A, López-Martínez JM. Benefits and risks of ureteral access sheaths for retrograde renal access. *Curr Opin Urol* 2016;26:70–5.
- [24] Perletti G, Magri V, Cai T, Stamatou K, Trinchieri A, Montanari E. Resistance of uropathogens to antibacterial agents: emerging threats, trends and treatments. *Arch Ital Urol Androl* 2018;90:85–96.
- [25] Walton-Diaz A, Vinay JI, Barahona J, et al. Concordance of renal stone culture: PMUC, RPUC, RSC and post-PCNL sepsis—a non-randomized prospective observation cohort study. *Int Urol Nephrol* 2017;49:31–5.
- [26] Korets R, Gravarsen JA, Kates M, Mues AC, Gupta M. Post-percutaneous nephrolithotomy systemic inflammatory response: a prospective analysis of preoperative urine, renal pelvic urine and stone cultures. *J Urol* 2011;186:1899–903.