

Original Article

Treatment effects of the Carriere® Motion 3D™ appliance for the correction of Class II malocclusion in adolescents

Hera Kim-Berman^a; James A. McNamara Jr.^b; Joel P. Lints^c; Craig McMullen^d; Lorenzo Franchi^e

ABSTRACT

Objectives: To determine the treatment effects produced in Class II patients by the Carriere® Motion 3D™ appliance (CMA) followed by full fixed appliances (FFA).

Materials and Methods: This retrospective study evaluated 34 adolescents at three time points: T1 (pretreatment), T2 (removal of CMA), and T3 (posttreatment). The comparison group comprised 22 untreated Class II subjects analyzed at T1 and T3. Serial cephalograms were traced and digitized, and 12 skeletal and 6 dentoalveolar measures were compared.

Results: Phase I with CMA lasted 5.2 ± 2.8 months; phase II with FFA lasted 13.0 ± 4.2 months. CMA treatment restricted the forward movement of the maxilla at point A. There was minimal effect on the sagittal position of the chin at pogonion. The Wits appraisal improved toward Class I by 2.1 mm during the CMA phase but not during FFA. Lower anterior facial height increased twice as much in the treatment group as in controls. A clockwise rotation (3.9°) of the functional occlusal plane in the treatment group occurred during phase I; a substantial rebound (-3.6°) occurred during phase II. Overjet and overbite improved during treatment, as did molar relationship; the lower incisors proclined (4.2°).

Conclusions: The CMA appliance is an efficient and effective way of correcting Class II malocclusion. The changes were mainly dentoalveolar in nature, but some skeletal changes also occurred, particularly in the sagittal position of the maxilla and in the vertical dimension. (*Angle Orthod.* 0000;00:000–000.)

KEY WORDS: Carriere Motion appliance; Class II treatment

INTRODUCTION

The Carriere® Motion 3D™ appliance (CMA; Henry Schein Orthodontics, Carlsbad, Calif) has become more popular during the past decade as a versatile intermaxillary Class II corrector. The clinical principle of Class II correction using the CMA is based on establishing a

Class I relationship at the beginning of treatment when patient compliance is high and before initiating the correction of the position and alignment of individual teeth with fixed appliances (or clear aligner therapy).¹

Introduced by its developer, Luis Carriere, in 2004 as the Carriere® Distalizer™,¹ the renamed Carriere®

^a Clinical Assistant Professor and Program Director of Graduate Orthodontics, Department of Orthodontics and Pediatric Dentistry, School of Dentistry, The University of Michigan, Ann Arbor, Mich, USA.

^b Thomas M. and Doris Graber Endowed Professor Emeritus, Department of Orthodontics and Pediatric Dentistry, School of Dentistry; Professor Emeritus of Cell and Developmental Biology, School of Medicine; and Research Scientist Emeritus, Center for Human Growth and Development, The University of Michigan, Ann Arbor, Mich; and Private Practice, Ann Arbor, Mich, USA.

^c Private practice, Ann Arbor, Mich, USA.

^d Resident, Graduate Orthodontic Program, Department of Orthodontics and Pediatric Dentistry, School of Dentistry, The University of Michigan, Ann Arbor, Mich, USA.

^e Assistant Professor and President of the School of Dentistry, Department of Experimental and Clinical Medicine, Section of Dentistry, Orthodontics, The University of Florence, Florence, Italy, and Thomas M. Graber Visiting Scholar, Department of Orthodontics and Pediatric Dentistry, School of Dentistry, The University of Michigan, Ann Arbor, Mich, USA.

Corresponding author: Dr Hera Kim-Berman, Department of Orthodontics and Pediatric Dentistry, University of Michigan, Ann Arbor, MI 48109-1078
(e-mail: bermanh@umich.edu)

Accepted: April 2019. Submitted: December 2018.

Published Online: June 24, 2019

© 0000 by The EH Angle Education and Research Foundation, Inc.

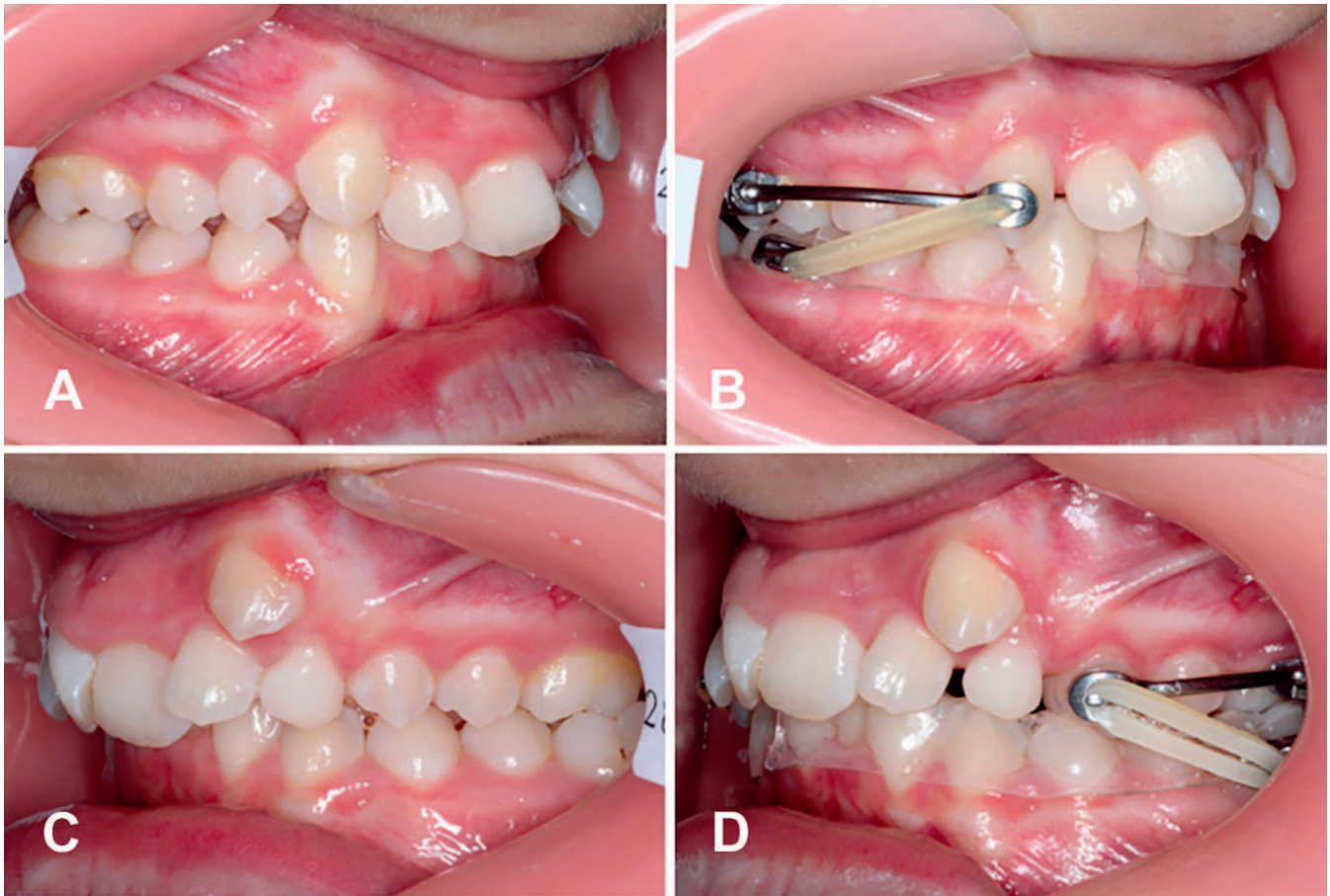


Figure 1. Intraoral views of the Carriere® Motion 3D™ appliance. (A, C) Pretreatment intraoral photos. (B) Intraoral view of the typical CMA appliance after Class II correction. (D) “Shorty” version of the CMA appliance when the canine cannot be used for attachment. Photographs courtesy of Dr Luis Carriere.

Motion 3D™ appliance consists of two rigid bars bonded bilaterally to the maxillary canines and first molars (Figure 1). The canine pad with a hook attachment used for placement of intermaxillary elastics is bonded to the anterior third of the clinical crown. In cases in which the maxillary canine has not erupted or has erupted ectopically, the first premolar can be used as the anterior attachment (Figure 1D). Posteriorly, the molded pad with a ball-and-socket joint is bonded to the first molar at the center of its clinical crown to facilitate molar derotation and distalization.

Intermaxillary elastics are anchored to the mandibular molars. Bonded buccal tubes with hooks are placed on the second molars or on the first molars if the second molars have not erupted sufficiently or are unerupted. The protocol for mandibular anchorage includes the use of a removable Essix-type clear (invisible) retainer^{2,3} that has been modified posteriorly to accommodate the bonded buccal tubes or hooks. Other methods of mandibular anchorage can include a lower lingual arch, temporary anchorage devices, and fixed appliances.⁴

Activation of the appliance is with heavy-force (6 oz and 8 oz) Class II elastics with anchorage provided by the invisible retainer. Full-time wear of intermaxillary elastics (22 hours) is required. Phase I treatment typically takes 5–8 months to complete, given good compliance. In the adolescent patient, the CMA was shown to be more comfortable for the patient to wear, offered a more positive overall experience, and had fewer negative comfort-related side effects compared with other appliances for Class II treatment.⁵

There have been limited investigations on treatment effects produced by the CMA. Existing studies include case reports, case series, and technique-oriented publications.^{1,6–8} Sandifer et al.⁴ examined the treatment effects of the CMA using two mandibular anchorage protocols: a lingual arch and fixed appliances. There was successful correction of Class II occlusion immediately following the use of CMA, with minimal maxillary molar tipping observed during molar distalization. Mandibular dental movement also was noted, with the mandibular plane angle opening in the lower lingual arch group only. Overall, Sandifer et al.⁴

found no significant differences in the type of mandibular anchorage technique used. It should be noted, however, that the Sandifer et al. study looked at only two time points: pretreatment and after CMA use. Currently, there are no studies that have investigated the skeletal and dentoalveolar effects following treatment with CMA followed by comprehensive orthodontic treatment.

Given the increasing popularity of the CMA and the lack of published data on the effects of CMA treatment, the purpose of the current study was to evaluate skeletal and dentoalveolar treatment effects in subjects with Class II malocclusions immediately after CMA therapy and following comprehensive treatment with preadjusted fixed orthodontic appliances.

MATERIALS AND METHODS

The Health Sciences and Behavioral Sciences Institutional Review Board (IRB) at the University of Michigan determined that this research was exempt from IRB oversight (No. HUM00088814).

This retrospective clinical study analyzed patients who were treated without extractions using CMA followed by fixed appliances. This sample was treated by Dr Luis Carriere of Barcelona, Spain, who used his standardized protocol on all patients. Sample size determination was calculated for the repeated-measures analysis of variance (ANOVA) on the basis of an effect size f of .25 for the primary outcome variable "molar relationship," an alpha level of .05, and a power of .80. The minimum sample size calculated was 28 patients (G*Power).⁹ The treating office was asked to provide records of 30 or more consecutively finished patients. Of the 44 such patient records collected, 10 patients were excluded from consideration for one or more of the following reasons:

1. technical radiographic issues that made one or more films in the series unusable;
2. the duration of phase I treatment with CMA was greater than 12 months, and/or
3. posttreatment records were obtained more than 4 months following the conclusion of active treatment.

The final subject sample consisted of 34 adolescent patients (23 girls and 11 boys) who were an average of 12.8 ± 1.4 years of age at T1 (pretreatment), 13.2 ± 1.5 years at T2 (removal of CMA), and 14.3 ± 1.5 years at T3 (posttreatment). Six patients were in the late mixed dentition and, in three of these patients, deciduous teeth were lost at T2. The control group consisted of 22 subjects (10 girls and 12 boys) with untreated Class II malocclusion, the records of whom were selected from the files of the University of Michigan Growth Study (eight subjects), the Denver

Child Growth Study (eight subjects), and the Bolton-Brush Growth Study (six subjects). The lateral cephalograms were available through the American Association of Orthodontists Foundation Craniofacial Growth Legacy Collection. The average age of the control group at first observation, T1, was 12.2 ± 0.8 years, while the average age at the second observation, T3, was 14.4 ± 0.8 years.

All patients were treated with CMA during phase I. The fit of the CMA was determined using the manufacturer's instructions. In the mandible, buccal tubes with elastic hooks were bonded to the mandibular second or first molars, and a clear invisible retainer made from 1-mm-thick Essix A+ plastic (Dentsply Sirona, York, Penn) was placed (Figure 1).

Elastic wear consisted of Force 1™ elastics (1/4-inch 6 oz) and Force 2™ elastics (3/16-inch 8 oz; Henry Schein Orthodontics) worn until the end of treatment with CMA. Subsequently, full fixed appliances (FFA) with preadjusted 0.022-inch edgewise brackets (Carriere SLX™ Self-ligating Brackets, Henry Schein Orthodontics) were placed.

Lateral head films of each patient were analyzed at T1, T2, and T3 and for the untreated group at T1 (first observation) and T3 (second observation). Twelve skeletal and six dentoalveolar measurements were used to evaluate changes following treatment (Table 1). The cephalograms were traced by one investigator (Dr Kim-Berman) and then examined thoroughly by another examiner (Dr McNamara) to verify landmark locations; any disparities were resolved mutually. Each tracing was digitized using Dentofacial Planner software (Toronto, Ontario, Canada) on a digitizing tablet (model DT-11, Houston Instruments, Austin, Tex).

Statistical Analysis

Chi-square tests were used to assess differences in sex distribution between groups. All cephalometric data at T1, T2, and T3 and for the T1–T2 (pretreatment to removal of CMA), T2–T3 (removal of CMA to posttreatment), and T1–T3 (pretreatment to posttreatment) changes were tested for normal distribution (Shapiro-Wilk test). Intragroup comparisons within the CMA group for the T1–T2, T2–T3, and T1–T3 changes were carried out with repeated-measures ANOVA or with Friedman tests if data were not normally distributed.

Comparisons between the CMA group and the control sample for dentoskeletal features at T1 (starting forms) and for the T1–T3 changes were analyzed using independent-samples t -tests or with Mann-Whitney U -tests when data were not distributed normally. All statistical computations were performed

Table 1. Descriptive Statistics and Statistical Comparisons (Independent-Samples *t*-Tests and Mann-Whitney *U*-Test) of the Starting Forms (Cephalometric Values at T1)^a

Variable	Treatment Group			Control Group			Difference	<i>P</i> Value	95% CI of the Difference	
	Mean	Median	SD IQR	Mean	Median	SD IQR			Lower	Upper
Maxillary skeletal, sagittal										
SNA, °	80.3		3.1	81.2		3.8	-0.9	.384	-2.7	1.1
Pt A to nasion perp, mm	-0.4		3.1	0.3		4.1	-0.7	.523	-2.5	1.3
Co-A, mm	94.9		4.3	92.1		6.2	2.8	.051	0.0	5.6
Mandibular skeletal, sagittal										
SNB, °	75.4		2.7	76.1		3.3	-0.7	.384	-2.3	0.9
Pg to nasion perp, mm	-8.4		5.1	-7.0		7.0	-1.4	.369	-4.7	1.8
Co-Gn, mm	116.0		5.1	113.8		6.6	2.2	.183	-1.0	5.2
Maxillomandibular										
ANB, °	5.2		1.7	4.9		2.5	0.3	.736	-0.7	0.9
Wits, mm	2.8		2.8	3.3		3.2	-0.5	.563	-2.1	1.2
Max-Mand differential	21.0		4.1	21.7		4.3	-0.7	.552	-3.0	1.6
Vertical skeletal										
ANS to Me, mm	65.8		4.9	66.5		4.5	-0.7	.598	-3.3	1.9
FH to mand plane, °	24.0		4.6	22.4		5.4	1.6	.264	-1.2	4.2
FH to occlusal plane, °	9.3		3.6	8.4		3.2	0.9	.318	-0.9	2.8
Dentoalveolar										
Overjet, mm	5.4		2.4	7.0		2.0	-1.6	.011*	-2.8	0.4
Overbite, mm	5.2		1.3	4.9		2.1	1.5*	.002*	0.5	2.4
Molar relationship, mm	-1.3		1.4	-1.6		1.8	0.3	.398	-0.5	1.2
U1 to Pt A vert, mm	4.7		2.5	5.3		2.0	-0.6	.360	-1.9	0.7
L1 to mand plane, °	96.6		7.7	99.4		6.6	-2.8	.178	-6.7	1.3
Interincisal angle, °	129.7		11.6	125.0		8.7	4.7	.107	-1.1	10.5

^a Perp indicates perpendicular; FH, Frankfort horizontal; U1, maxillary incisor; L1, mandibular incisor; SD, standard deviation; IQR, interquartile range; CI, confidence interval. Significance: *P* < .05. The molar relationship was measured as the distance between mesial contact heights of contour on the maxillary and mandibular first molars, measured along the occlusal plane. A value of 0 mm means an end-to-end relationship, a positive value indicates a tendency to Class I relationship, and a negative value signifies a tendency to Class II relationship.

* *P* < .05

with statistical software (IBM Statistical Package for the Social Sciences™, SPSS®, version 22, Armonk, NY).

RESULTS

The mean starting age at T1 was 12.8 ± 1.3 years. Phase I with the CMA lasted an average of 5.2 ± 2.8 months; phase II was 13.0 ± 4.2 months. The total treatment time was 18.2 ± 4.8 months. For comparison, the control group was studied at two observations (T1 and T3). The average interval between the two observations was 26.4 ± 4.3 months. To provide a direct comparison of treatment effects, the control data were extrapolated to match the T1 to T3 interval of the CMA group (18 months).

Comparison of Starting Forms (T1)

A comparison of the CMA and control groups at T1 indicated that the starting forms were similar between groups (Table 1). Only two of the 18 variables (overjet and overbite) demonstrated a statistically significant difference (*P* < .05) between the two groups; overjet in the treatment group was slightly smaller while the overbite was slightly larger when compared with controls (5.4 mm vs 7.0 mm and 5.7 mm vs 4.2 mm, respectively).

Treatment Effects During Phases I and II (T1–T2, T2–T3, T1–T3)

Table 2 provides the means and standard deviations of the changes in the cephalometric variables and statistical significance (*P* < .05) at three observations.

Sagittal Position of the Maxilla

SNA decreased slightly (-0.6°) during phase I, with an additional decrease of -0.7° during phase II; thus, there was a net decrease of -1.3° during the overall treatment period. Similarly, the sagittal distance from point A to nasion perpendicular¹⁰ was reduced by -0.4 mm during phase I and -0.7 mm during phase II. The distance from condyion to point A increased slightly (0.4 mm) during the 5-month CMA phase and by 0.9 mm during the 12-month fixed appliance phase, with an overall increase in midfacial length of 1.3 mm.

Sagittal Position of the Mandible

SNB increased 0.1° during phase I and decreased -0.3° during phase II, resulting in a minimal negative change (-0.2°). Pogonion moved anteriorly 0.5 mm relative to nasion perpendicular during phase I but moved posteriorly -0.5 mm during phase II. Mandibular

Table 2. Descriptive Statistics and Statistical Comparisons (Repeated-Measures ANOVA) of T1–T2 (Pretreatment to Removal of CMA), T2–T3 (Removal of CMA to Posttreatment), and T1–T3 (Pretreatment to Posttreatment) Changes in the Treatment Group^a

Variable	T1–T2		T2–T3		T1–T3	
	Mean	SD	Mean	SD	Mean	SD
Maxillary skeletal, sagittal						
SNA angle, °	–0.6	1.0	–0.7	1.0	–1.3*	1.4
Point A to nasion perp, mm	–0.4*	1.0	–0.7*	1.1	–1.1*	1.3
Condylion to point A, mm	0.4	1.2	0.9	1.4	1.3*	1.8
Mand skeletal, sagittal						
SNB angle, °	0.1	1.0	–0.3	1.1	–0.2	1.1
Pogonion to nasion perp, mm	0.5	1.8	–0.5	1.5	0.0	2.1
Condylion to gnathion, mm	2.0*	1.3	3.1*	2.1	5.1*	2.2
Maxillomandibular relationships						
Wits appraisal, mm	–2.1*	2.0	0.1	1.7	–2.0*	2.7
ANB angle, °	–0.8*	0.9	–0.3	0.9	–1.1*	1.2
Max-mand differential, mm	1.7*	1.5	2.1*	1.8	3.8*	2.0
Vertical skeletal relationships						
ANS to menton, mm	1.1*	1.2	2.6*	1.9	3.7*	1.9
FH to functional occlusal plane, °	3.9*	3.0	–3.6*	3.0	0.3	2.5
FH to mandibular plane, °	0.2	1.4	0.0	1.4	0.2	1.7
Dentoalveolar relationships						
Overjet, mm	–2.1*	1.3	–0.8*	1.1	–2.9*	2.0
Overbite, mm	–2.1*	1.4	–0.5*	1.5	–2.6*	1.2
Molar relationship, mm	5.1*	2.0	–1.8*	1.6	3.3*	1.6
U1 to point A vertical, mm	0.3	1.2	–0.9*	1.4	–0.6	1.8
L1 to mandibular plane, °	4.9*	3.9	–0.7	6.3	4.2*	5.0
Interincisal angle, °	–6.6*	6.0	3.1	9.7	–3.5	9.7

^a Perp indicates perpendicular; max, maxillo; mand, mandibular; FH, Frankfort horizontal; U1, maxillary incisor; L1, mandibular incisor; SD, standard deviation.

* $P < .05$.

length (Co-Gn) increased 2.0 mm during the 5-month CMA phase and by an additional 3.1 mm during the 12-month fixed appliance phase.

Maxillomandibular Relationships

Treatment with CMA resulted in a 2.1-mm improvement in the Wits appraisal value; however, the measurement remained unchanged during phase II. The net change was 2.0 mm. The ANB angle also decreased slightly during both phase I (–0.8°) and phase II (–0.3°), resulting in a –1.1° overall closure of the ANB angle. The maxillomandibular differential, the difference between Co-Pt A and Co-Gn,¹⁰ registered a 1.7-mm increase toward Class I during phase I and an additional 2.1 mm during phase II, leading to an overall improvement of 3.8 mm.

Vertical Skeletal Relationships

Lower anterior facial height (ANS-menton) increased by 1.1 mm during phase I and by an additional 2.6 mm during the FFA phase, leading to an overall increase in lower anterior vertical dimension of 3.7 mm. The mandibular plane did not change significantly during phases I or II. A clockwise rotation of the functional occlusal plane (FOP) relative to Frankfort horizontal of 3.9° occurred during phase I. In phase II, however,

there was a substantial rebound in the orientation of the FOP (–3.6°), so that the overall change was only –0.3 mm from T1 to T3.

Dentoalveolar Relationships

The molar relationship improved by 5.1 mm during phase I; the same measure rebounded slightly (–1.8 mm) during phase II, with a net improvement of 3.3 mm toward Class I. Overjet was reduced by 2.1 mm during the CMA phase, and it also decreased slightly (–0.8 mm) during the FFA phase; these changes resulted in a net decrease in overjet of –2.9 mm overall. Overbite decreased by –2.1 mm during phase I.

The sagittal position of the upper incisor relative to a line drawn through point A perpendicular¹⁰ to the Frankfort horizontal was evaluated. Minimal change (0.3 mm) was noted during phase I. Slight retraction (–0.9 mm) of the upper incisor was observed during the fixed appliance phase. Proclination of the lower incisor (4.9°) occurred during the CMA phase. During phase II, a slight uprighting (–0.7°) was noted.

Comparison of the Treatment and Control Groups (T1–T3)

Skeletal relationships. Table 3 provides a direct comparison between the pretreatment to posttreatment

Table 3. Descriptive Statistics and Statistical Comparisons (Independent-Samples *t*-Tests and Mann-Whitney *U*-Test) of the T1–T3 (Pretreatment to Posttreatment) Changes in the Treatment and Control Groups^a

Variable	Treatment Group			Control Group			Difference	<i>P</i> Value	95% CI of the Difference	
	Mean	Median	SD IQR	Mean	Median	SD IQR			Lower	Upper
Maxillary skeletal, sagittal										
SNA angle, °	–1.3		1.4	0.5		0.8	–1.8*	.000*	–2.3	–1.2
Point A to nasion perp, mm	–1.1		1.3	0.6		1.8	–1.7*	.001*	–2.5	–0.8
Condylion to point A, mm	1.3		1.8	2.3		1.3	–1.0*	.019*	–1.8	–0.2
Mandibular skeletal, sagittal										
SNB angle, °	–0.2		1.1	0.6		0.8	–0.8*	.003*	–1.3	–0.3
Pogonion to nasion perp, mm	0.0		2.1	1.5		3.0	–1.5	.055	–3.0	0.0
Condylion to gnathion, mm	5.1		2.2	4.3		1.7	0.8	.106	–0.2	1.9
Maxillo-mandibular										
ANB angle, °	–1.1		1.2	–0.2		0.7	–0.9*	.001*	–1.4	–0.4
Wits appraisal, mm	–2.0		2.7	0.0		2.0	–2.0*	.003*	–3.3	–0.7
Maxillomandibular differential	3.8		2.0	2.8		1.8	1.0	.056	0.0	2.0
Vertical skeletal										
ANS to menton, mm	3.7		1.9	1.9		1.3	1.8*	.000*	1.0	2.7
FH to mandibular plane, °	0.2		1.7	–1.0		1.4	1.2*	.003*	0.5	2.1
FH to occlusal plane, °	0.3		2.5	–0.6		1.9	0.9	.160	–0.3	2.0
Dentoalveolar										
Overjet, mm	–2.9		2.0	0.0		0.5	–2.9*	.000*	–3.7	–1.9
Overbite, mm	–2.6		1.2	0.0		0.8	–2.6*	.000*	–3.1	–2.0
Molar relationship, mm	3.3		1.6	0.2		1.1	3.1*	.000*	2.4	3.8
U1 to point A vertical, mm	–0.6		1.8	0.2		0.8	–0.8*	.024*	–1.5	–0.1
L1 to mandibular plane, °	4.2		5.0	0.4		2.1	3.8*	.000*	1.8	5.7
Interincisal angle, °	–3.5*		9.7	0.4		2.9	–3.9*	.032*	–7.5	–0.4

^a Perp indicates perpendicular; FH, Frankfort horizontal; U1, maxillary incisor; L1, mandibular incisor; SD, standard deviation; IQR, interquartile range; CI, confidence interval. Significance: *P* < .05.

* *P* < .05.

interval and the extrapolated control cephalometric values. A reduced forward movement of the maxilla at point A in the treatment group compared with controls was noted. In contrast, the chin point at pogonion remained in the same sagittal position (0.0 mm) relative to the nasion perpendicular during T1–T3; the chin moved forward 1.5 mm in the controls. The SNB angle decreased slightly (–0.2°) in the treatment group but increased 0.6° in the controls. Both ANB (–0.9°) and the Wits appraisal (–2.0 mm) showed significant decreases in the treatment group in comparison with controls. Lower anterior facial height (ANS to menton) increased in the treatment group by 3.7 mm, which was almost double that of the untreated Class II controls.

Dentoalveolar relationships. Major changes also were observed in the dentoalveolar measures. All six measures of dentoalveolar relationships in the control group remained relatively unchanged from T1 to T3. In the treatment group, overjet and overbite improved (–2.9 mm and –2.6 mm, respectively) as did molar relationship (3.3 mm). There was 4.2° of proclination of the lower incisor as well as a slight closure of the interincisal angle (–3.5°).

DISCUSSION

The results of this study indicated that the CMA is an efficient and effective way of correcting the sagittal

component of Class II malocclusion within the first half-year of treatment. Comprehensive therapy using fixed appliances or other methods such as clear aligners can then be used, sometimes combined with rapid maxillary expansion or dental arch expansion, to refine and detail the occlusion.

Popowich and coworkers¹¹ evaluated predictors for Class II treatment duration. Following evaluation of nonextraction Class II patients, the investigators reported average times for Class II elastic wear and overall treatment length of 10.0 months (±6.0 months) and 25.7 months (±6.8 months), respectively. In the CMA sample, the first phase averaged 5.1 months (±2.8 months), and the second phase with fixed appliances lasted 13.0 months (±4.2 months). The total treatment duration was 18.2 months (±4.8 months). Thus, one of the major advantages of treatment with CMA was the reduced duration of elastic wear and overall treatment time, which makes this method of treatment efficient.

When discussing changes in skeletal or dentoalveolar measures, the difference between statistical significance and clinical significance must be mentioned. For this study, a *P* value of <.05 was used to determine statistical significance. In prior clinical investigations, a change of ≥2.0 mm or 2.0° of any cephalometric variable was chosen as an indication of

clinical significance, following the recommendations of O'Brien and coworkers,¹² among others. Limitations of this study were its retrospective nature and the use of historical controls.

A significant restriction of maxillary growth (Co-A, -1.0 mm) was recorded with respect to the control sample. Similarly, the differences between the treatment and control groups in the SNA angle (-1.8°) and point A to nasion perpendicular (-1.7 mm) were not only statistically significant but also approached clinical significance. Maxillary adaptations mostly accounted for the favorable intermaxillary changes, with significant decreases both in the ANB angle (-0.9°) and Wits appraisal (-2.0 mm).

During CMA treatment, the mandible is brought forward by heavy elastics that are worn nearly full-time by the patients. Thus, mandibular length (Co-Gn) increases might be expected during treatment over what would occur during normal growth. In fact, there was no statistically or clinically significant increase in mandibular length (Table 3) compared with controls. SNB showed a statistically significant although clinically irrelevant decrease (-0.8°). This decrease in the SNB angle could have been related to the increase in vertical skeletal relationships that occurred in the CMA sample with respect to the controls. There was no difference in the anteroposterior position of the chin at pogonion between the two groups.

The sagittal skeletal changes produced by the CMA were like those described for Class II elastics combined with fixed appliances. For example, Janson and colleagues¹³ reported that the decrease in ANB ranged between -1.3° and -1.7° , sustained primarily by maxillary growth restriction rather than mandibular growth stimulation or mandibular advancement. Similar changes in ANB (-1.7° per year) were reported for fixed functional appliances with respect to untreated Class II controls.¹⁴ This improvement, however, was accomplished by relatively equal contributions from mandibular growth (0.9° per year) and restriction of maxillary growth (0.8° per year).

One clinically and statistically relevant effect of treatment with CMA occurred in lower anterior facial height (LAFH; ANS-Menton, 1.8 mm) that was associated with a significant increase in the mandibular plane angle (FH to mandibular plane, 1.2°). The amount of increase in LAFH with CMA was smaller than that reported for Class II elastics and fixed appliances (5.0 mm),¹³ while it was similar to that described for the crown or acrylic Herbst appliance (3.2 mm and 4.0 mm, respectively)¹⁴ and for the Forsus appliance (4.0 mm).¹⁵

During Phase I treatment with CMA, a clockwise rotation of the FOP relative to Frankfort (3.9°) was noted. Interestingly, a rebound in that measurement

(-3.6°) occurred during Phase II (Table 2), so there was no statistically significant difference between groups at T3 (Table 3). A similar behavior for the occlusal plane angulation has been reported for Class II elastics combined with fixed appliances.¹³

In general, the six dentoalveolar measurements remained unchanged in the control group from T1 to T3; all of these measurements changed in the treatment group. The most obvious change was molar relationship, which improved by 5.1 mm during phase I, when the molar classification went from Class II to Class I (or even "overcorrected" to slightly Class III; Table 2). A rebound occurred in this measure (-1.8 mm) in phase II as the occlusion was detailed with fixed appliances. In the control group, from T1–T3, there was virtually no change (0.2 mm) in molar relationship; the overall change in the CMA group was 3.3 mm (Table 3). Overjet (-2.9 mm), overbite (-2.6 mm), and lower incisor angulation (4.2°) all changed in both a statistically and clinically significant manner. Similar dentoalveolar changes were described also for Class II elastics combined with fixed appliances and for fixed functional appliances.¹³

CONCLUSIONS

- This study examined the treatment effects produced by CMA treatment followed by comprehensive orthodontics. The overall treatment time was relatively short (17.6 months), and Class II correction typically was achieved during the first 5–6 months of treatment.
- The following conclusions are reached based on the data analyzed:
 - The CMA is efficient and effective in resolving Class II malocclusion.
 - The primary treatment effects are dentoalveolar in nature, with changes in molar relationship, overbite, and overjet combined with some lower incisor proclination.
 - The most obvious skeletal change was an increase in lower anterior facial height.
 - There was a slight restriction in the forward movement of the maxilla at point A.
 - Mandibular length was not affected by treatment.
 - The chin point at pogonion did not move forward in the treatment group due, in part, to the increase in lower anterior facial height.

REFERENCES

1. Carriere LA. New Class II distalizer. *J Clin Orthod.* 2004;38:224–231.
2. Ponitz RJ. Invisible retainers. *Am J Orthod.* 1971;59:266–272.
3. McNamara JA Jr, Kramer KL, Jeunker JP. Invisible retainers. *J Clin Orthod.* 1985;19:570–578.

4. Sandifer CL, English JD, Colville CD, Gallerano RL, Akyalcin S. Treatment effects of the Carrière distalizer using lingual arch and full fixed appliances. *J World Fed Orthod.* 2014;3: e49–e54.
5. Hamilton CF, Saltaji H, Preston CB, Flores-Mir C, Tabbaa S. Adolescent patients' experience with the Carriere distalizer appliance. *Eur Paediatr Dent.* 2013;14:219–224.
6. Pardo Lopez B, DeCarlos Villafranca F, Cobo Plana J. Distalizer treatment of an adult Class II Division 2 malocclusion. *J Clin Orthod.* 2006;40:561–565.
7. Rodrigues H. Unilateral application of the Carriere distalizer. *J Clin Orthod.* 2011;45:177–180.
8. Singh DP, Arora S, Yadav SK, Kedia NB. Intraoral approaches for maxillary molar distalization: case series. *J Clin Diagn Res.* 2017;11:ZR01–ZR04.
9. Faul F, Erdfelder, Lang AG, Buchner A. G*Power 3: a flexible statistical power analysis program for the social, behavioral, and biomedical sciences. *Behav Res Methods.* 2007;39: 175–191.
10. McNamara JA Jr. A method of cephalometric evaluation. *Am J Orthod.* 1984;86:449–469.
11. Popowich K, Nebbe B, Heoc G, Glover K, Major P. Predictors for Class II treatment duration. *Am J Orthod Dentofacial Orthop.* 2005;127:293–300.
12. O'Brien K, Wright J, Conboy F, et al. Effectiveness of early orthodontic treatment with the Twin-block appliance: a multicenter, randomized, controlled trial. Part 1: dental and skeletal effects. *Am J Orthod Dentofacial Orthop.* 2003;124: 234–243.
13. Janson G, Sathler R, Fernandes TM, Branco NC, Freitas MR. Correction of Class II malocclusion with Class II elastics: a systematic review. *Am J Orthod Dentofacial Orthop.* 2013;143:383–389.
14. Burkhardt DR, McNamara JA Jr, Baccetti T. Maxillary molar distalization or mandibular enhancement: a cephalometric comparison of the Pendulum and Herbst appliances. *Am J Orthod Dentofacial Orthop.* 2003;123:108–116.
15. Franchi L, Alvetro L, Giuntini V, Masucci C, Defraia E, Baccetti T. Effectiveness of comprehensive fixed appliance treatment used with the Forsus fatigue resistant device in Class II patients. *Angle Orthod.* 2011;81:678–683.