

A comparison of two fixation methods for femoral trochanteric fractures: a new generation intramedullary system vs sliding hip screw

Christian Carulli
 Federico Piacentini
 Tommaso Paoli
 Roberto Civinini
 Massimo Innocenti

Orthopaedic Clinic, University of Florence, Florence, Italy

Address for correspondence:
 Christian Carulli
 Orthopaedic Clinic
 University of Florence
 Florence, Italy
 E-mail: christian.carulli@unifi.it

Summary

Introduction. Trochanteric fractures are frequent and generally associated with bone fragility. There is still debate on the best fixation device to treat stable or rather stable trochanteric fractures: we report our clinical and radiological results of fixation with Proximal Femoral Nail “antirotation” (PFNa) in a population of patients compared to a control group treated by Sliding Hip Screw (SHS).

Materials and methods. A prospective study was conducted in 71 consecutive patients treated by PFNa (group A), and 69 by a SHS (group B), with a mean age of 81.6 and 83.4 years respectively. Short Form 12 was administered to check postoperative results, and the following parameters were evaluated: range of motion, evaluation of pain, gait ability, X-rays, and Tip Apex Distance Index.

Results. A minimum follow-up was conducted in 128 patients: 66 subjects belonging to the PFNa group and 62 to the DHS group. All patients in the group A were able to reach partial or full weight-bearing on the operated leg before leaving the hospital. Forty-four patients (63.8%) of the group B were able to walk with partial weight-bearing before discharge.

We recorded 17 complications with a final overall percentage of 17.2% on the overall study population with one single case of failure in both the two groups.

Discussion. A statistical significance ($p < 0.01$) of superiority for PFNa was demonstrated regarding surgical time, amputation time, intraoperative blood loss, hospital stay, recovery of weight-bearing before discharge. Less significant results ($p < 0.05$) were found for walking ability at the three-months follow-up and patients' satisfaction 6 months after surgery.

Conclusions. PFNa may be considered an useful choice for the treatment of stable or rather stable trochanteric

fractures as well as DHS. The light superiority of PFNa may be principally related to its mechanical advantages.

KEY WORDS: trochanteric fractures; femur; fragility fractures; intramedullary nail; sliding hip screw; fixation; PFNa; DHS; cut-out.

Introduction

Trochanteric fractures are generally associated with bone fragility and caused by a low energy trauma: a significant increase of these fractures is expected on the next decades (1, 2). Improvements of anaesthesiologic and surgical techniques have increased the rate of success and reduced the elevated risk of death within the first year after fracture, independently from the patients' age and health status [2]. Surgical fixation and early rehabilitation are the goals of an adequate treatment in order to allow a quick recovery for patients. The recent acquisition that an early timing (<48 hours from trauma) of surgical treatment may reduce postoperative complications and mortality adds to our knowledge further implications (3, 4).

The Sliding Hip Screw (SHS) is considered the gold standard device for fixation of stable trochanteric fractures (5-15). In case of unstable or reverse obliquity pattern fracture, intramedullary nails seem to be more effective with respect to SHS (16-18). However, the first intramedullary nails showed high rates of intraoperative complications (5, 12, 14, 15, 19-25). Modern nails are free from such drawbacks and easier to be applied. Among these, the *Proximal Femoral Nail “antirotation”* (PFNa®, Synthes, Oberdorf, Switzerland) has been recently released, showing *in vitro* biomechanical improvements (26). To date, few papers in literature have reported the clinical results of PFNa in the treatment of trochanteric fractures (27-31).

The aim of this paper is the evaluation of our clinical and radiological results of fixation of stable or minimal unstable trochanteric fractures with PFNa in a population of patients compared to a control group treated by SHS.

Materials and methods

A prospective study was performed on 140 consecutive patients affected by a trochanteric fracture, treated by internal fixation either with PFNa or DHS® (Synthes, Oberdorf, Switzerland) between January 2007 to December 2009 at the Authors' Institution. Inclusion criteria were adult patients with trochanteric fracture (31.A1 or 31.A2 according to AO classification) (32), able to give a full consent to the study. Exclusion criteria were: patients with a 31.A3 fracture, psychiatric diseases, any form of neurologic deficit to lower limbs, any contraindication to surgery. Patients were randomized for treatment with PFNa or DHS with a sealed envelopes system after adequate information. The local Institu-

tional Review Board approved the study, and all patients gave their informed consent to the procedure, acquisition of clinical informations, and radiologic follow-up.

Two groups resulted: the group A (PFNa) of 71 patients and the group B (DHS) of 69 patients. In the group A, there were 29 male and 42 female patients, with a mean age of 81.6 years (range: 67-98). In the group B, 25 subjects were male and 44 females with a mean age of 83.4 years (range: 64-98). Demographic data of the enrolled patients are presented in Table 1.

All subjects were studied by conventional radiology in Emergency Room, received antibiotic and antithromboembolic prophylaxis, and were evaluated with a subjective health survey concerning the status until the day of the fracture, the *Short Form 12* (SF12) (33). In the group A, almost all patients presented a single fracture, following an accidental fall, and only 12 (16.9%) were affected by other fractures (wrist, chest, proximal humerus), additional minor lesions as head, spine, or legs bruises or sprains. Thirty-eight patients lived by their own and without any support for daily activities; some of them lived with other relatives, needing some help in daily life actions; the remainders were assisted in residential healthcare facilities. In 55 cases (77.5%), patients were affected by comorbidities, mostly related to cardiologic, metabolic, and circulatory issues. The group A consisted in 21 closed fractures classified as 31.A1 (35.2%), 45 (64.7%) as 31.A2.

In the group B, all patients but fifteen (21.7%) presented a single fracture: associated lesions consisted in dorsal or lumbar spine, wrist, or shoulder fractures, and bruises, sprains, wounds. Comorbidities were reported in 54 cases (78.3%). The group B consisted in 28 fractures type 31.A1 (40.6%), 41 type 31.A2 (59.4%). All were closed fractures.

All patients (group A + B) underwent a surgical procedure under fluoroscopy, within an average time of 2.3 days after hospitalization (range: 1-7 days). About 80.4% of fractures were treated in the first 48 hours after trauma (early timing). Intraoperative data concerning blood loss, operative and radiological exposure time, and postsurgical onset of complications were registered. A protocol of functional recovery was proposed with assisted passive motion in bed at the first postoperative day. At second postoperative day, depending on pain tolerance, patients were allowed to seat in bed performing active knee and ankle exercises. From the third postoperative day in stable patterns, assisted standing and gait exercises with devices were proposed. The same exercises were later allowed in patients with poor bone quality (as tested during surgery), or with associated spine or arm fractures. Subjects were then discharged, and sent to rehabilitative facilities in a way to complete their functional recovery.

PFNa system presents a proximal angulation of 6° on the coronal plane, and no bendings on the sagittal one, in order to be implanted bilaterally. It is available in several sizes (length: from 170 mm to 420 mm, with 40 mm increments), and with different angles between helicoidal blade and body of the nail (125°, 130°, 135°). Finally, the helicoidal blade lengthens from 80 mm to 125 mm, with 5 mm increments. The helicoidal blade is introduced “open” after reaming a bone tunnel (in younger patients) or directly in porotic bone, approximately 10 mm from the surface of the femoral head: then, it is closed by a locking mechanism in the body of the nail with an inner screwing system, with an effect similar to set screws of other intramedullary devices.

Table 1- Patients' characteristics and follow-up.

	Study population		3 months after surgery			6 months after surgery			1 year after surgery		
	PFNa	DHS	PFNa	DHS	SS	PFNa	DHS	SS	PFNa	DHS	SS
Patients (n)	71	69	69	67		68	63		66	62	
Age (years)	81.62 ± 7.82	83.41 ± 7.90	81.27 ± 7.79	82.92 ± 7.48	N S	81.71 ± 7.81	81.88 ± 7.44	NS	81.52 ± 7.93	81.49 ± 6.92	NS
Female (n)	42 (59.15%)	44 (63.76%)	42 (60.86%)	43 (64.17%)	N S	42 (61.76%)	42 (66.66%)	NS	41 (62.12%)	42 (66.74%)	NS
Fracture Type (n)											
- 31.A1	25 (35.21%)	28 (40.57%)	23 (33.33%)	28 (41.79%)	N	23 (33.82%)	26 (41.26%)	NS	21 (31.81%)	26 (41.9%)	NS
- 31.A2	46 (64.69%)	41 (59.43%)	46 (66.66%)	39 (58.21%)	S	45 (66.17%)	37 (58.74%)	NS	45 (68.18%)	36 (58.10%)	NS
			N S		N S			NS			NS

PFNa: proximal femoral nail antirotation. DHS: dynamic hip screw. SS: Statistical significance. Data are mean ± SD (range) or n; Quantitative variables were analyzed using the Student's t-test and categorical variables were analyzed by the X2 test. NS not statistically significant (p >0.05).

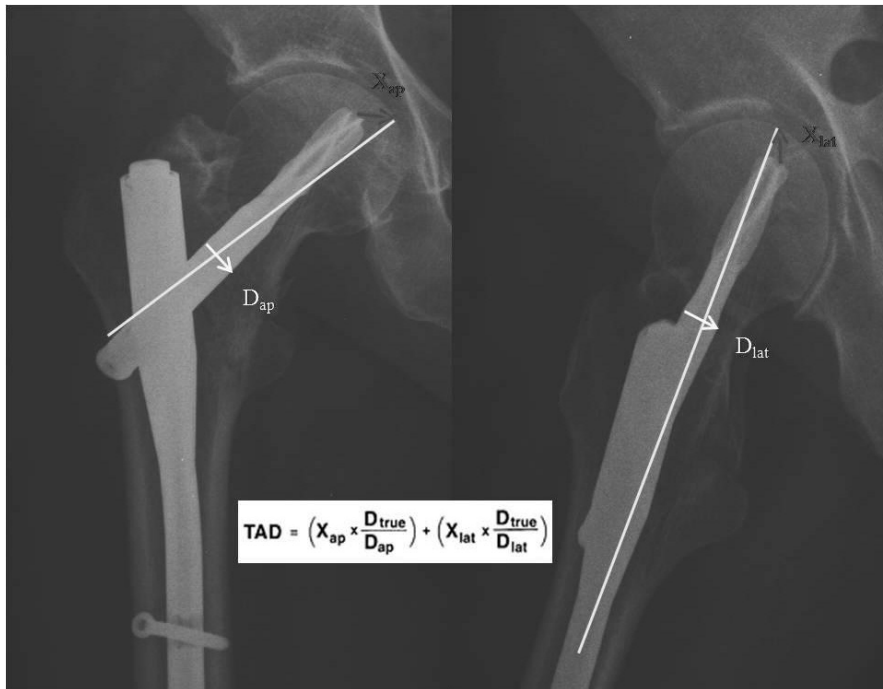


Figure 1 - Example of TAD evaluation: TAD is 22 mm.

DHS system presents well-known features, and the surgical technique has been reported since many years in literature. Follow-up evaluations consisted in outpatient visits at one, three, six, and twelve months: SF12 was administered to check postoperative results. Criteria to assess clinical outcomes were based on the evaluation of pain, range of motion (ROM), and gait ability. Standard X-rays were made to evaluate blade positioning on femoral neck and head following Kyle's classical criteria (34), and Tip-Apex Distance (TAD) (35), both considered the more predictive parameters for the assessment of potential mechanical failures of fixation. As reported in recent papers (36, 37), TAD index was calculated on fractures treated both with extramedullary and intramedullary fixation devices (Figure 1). Radiographs were also used for evaluation of bone healing and periarticular ossifications. The full healing of fractures was assessed by check of fragments alignment, recovery of posteromedial buttress, and femoral neck length on standard X-rays. From a clinical point of view, the healing was confirmed when patients were able to standing free with full weight bearing, and to walk independently, with or without assisting devices. A statistical analysis was performed by SPSS 17.0 software (SPSS Inc., Chicago, IL, USA) using the Student's t-test and the X2 test for categorical variables with a significance level of $p < 0.05$.

Results

The groups were substantially homogeneous. Two patients in the group A and four in the group B died before completing the one-year follow-up. One patient in both groups did not presented at our outpatients' clinic after the 3-months evaluation. Other two patients in the group A and two in the group B did not attend the last follow-up visit. Thus, a complete one-year follow-up was conducted in 128 patients, 66 subjects belonging to the PFNa group and 62 to the DHS group.

In the group A, fracture fixation was achieved by a 130° PFNa nail in 62 patients (87.3%), while the others were treated by a 125° nail. In 64 patients (90.1%), a 10 mm diameter PFNa was implanted; in the others, a 11 mm diameter was chosen. All nails were 200 mm long, distally and statically fixed. In the group B, 40 patients (58.0%) were treated by a 4-holes 135° DHS, 17 (24.6%) by a 4-holes 140° DHS, 3 (4.4%) by a 4-holes 145° DHS, 2 (3.0%) by a 6-holes 135° DHS. In the PFNa group, the mean surgical time was 46.1 minutes (range: 30-85); the mean arthroscopy time was 60.4 seconds (range: 45-85). The average blood loss was about 129.6 cc (range: 40-280). In the DHS group, the mean surgical time was 63.4 minutes (range: 40-105); the mean arthroscopy time was 45.8 seconds (range: 35-65). The average blood loss was about 250.2 cc (range: 120-500). All patients received two bags of heterologous blood postoperatively; one patient in the group A and two in the group B needed a pre-surgical blood transfusion.

Postoperative X-rays in the group A demonstrated anatomical reduction in all cases but 3 (4.5%) in which a varus deformity more than 5° was present. In the group B, we recorded an anatomical reduction in all cases but 2 (3.0%) with a valgus deformity less than 5° and of varus deformity less than 4°. Mean TAD resulted in 25 mm (range: 12-35) in group A, 24mm (range: 13-34) in the group B. Referring to its position, the spiral blade was implanted on inferior and middle portion of the femoral neck in 35 cases; on inferior and anterior in 16 cases; on middle in 8 cases; on inferior and posterior in 3 cases; on middle and anterior in 3 cases; on superior and anterior in 1 case. According to the same criteria, the cephalic screw on the DHS group was positioned on inferior and middle portion of the femoral neck in 39 cases; on inferior and anterior in 16 cases; on middle in 4 cases; on inferior and posterior in 2 cases; on middle and anterior in 1 case. All patients were able to reach an assisted gait with a frame, and partial or full weight-bearing on the operated leg before leaving the hospital in the group treated by PFNa. Forty-four patients (63.8%) treated by DHS were able to walk with par-

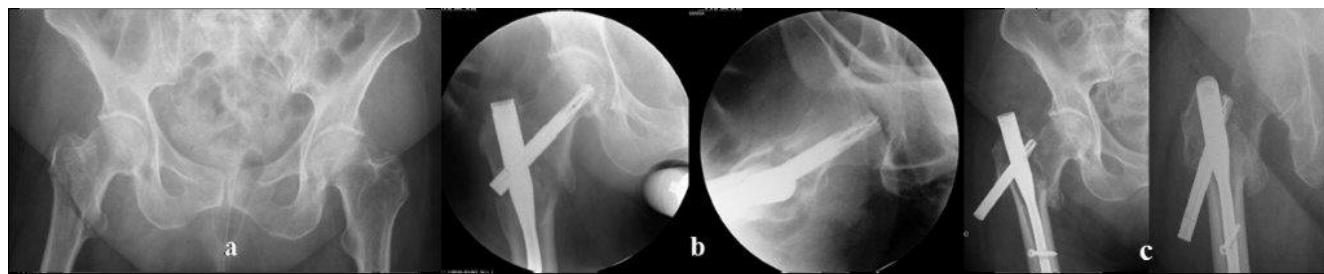

Figure 2 - Preoperative images of a 81-year-old patient with a 31.A2 trochanteric fracture (a) treated by PFNa (b). One month after surgery the patient complained pain and was unable to walk: radiologic evidence of cut-out (c).

tial weight-bearing before discharge: the remainders were not able to apply weight-bearing on the operated leg (10 subjects with 31.A2 fractures), or were not allowed to for an associated spinal fracture or other concomitant clinical issues (3 patients with 31.A2 fractures, 1 with 31.A1 fracture).

We recorded 17 complications, with a final overall percentage of 17.2% on the overall study population. In the group A, we had 4 complications (6.1%) not correlated with the device: death (one case, 9 days after surgery related to pulmonary embolism), pulmonary infection (one case, treated by antibiotic administration), not complicated Deep Venous Thrombosis (DVT - 2 cases, managed with Low Molecular Weight Heparin and mechanical compressive devices). In 4 cases (6.1%), we had complications related to the procedure: a single case of implant failure at one month that required surgery; two cases of Spiral Blade medial migration through the femoral head without protrusion over the cortex; one case of slight lateral protrusion of the blade, with trochanteric bursitis treated with local steroid injections after fracture healing. The single failure occurred one month after surgery in a 81-year-old patient who complained pain and unable to walk. X-rays demonstrated a cut-out of the nail. The implant was removed and the patient underwent a cemented hip hemiarthroplasty. After two months the patient was able to walk without crutches and without symptoms (Figure 2).

In the group B, we recorded 9 complications (13.3%): one death (on third post-operative day due to cardiac failure); one *ab ingestis* pulmonary infection (treated by Intensive Care Management); two DVTs (managed as previously stated); one urinary tract infection (treated by systemic antibiotics); two superficial wound infections (treated by wound advanced care and antibiotics); we also had a case of implant failure requiring surgery at three months of follow-up; one case of migration of two of the 6 screws of a DHS plate without any complaint by the patient. The single failure occurred in a 80-year-old patient who complain symptoms and severe functional impairment related to an instability of the device with breakage of some screws and varus deformity. As for the failure of group A, the patient underwent a hardware removal and a cemented hemiarthroplasty with success (Figure 3). Mortality and complications data of the two groups are presented in Table 2.

At the 3-month follow-up visit, in the group A 58 patients (81.7%) were able to walk independently without crutches or at least with one cane; the remainders (all with 31.A2 fractures) were able to perform an almost normal gait within 6 months post-operatively. At the same interval, in the group B 45 patients (67.2%) were able to walk independently without crutches or at least with one cane: all the others (31.A2 fractures) reached the same result at 6 months post-operatively,

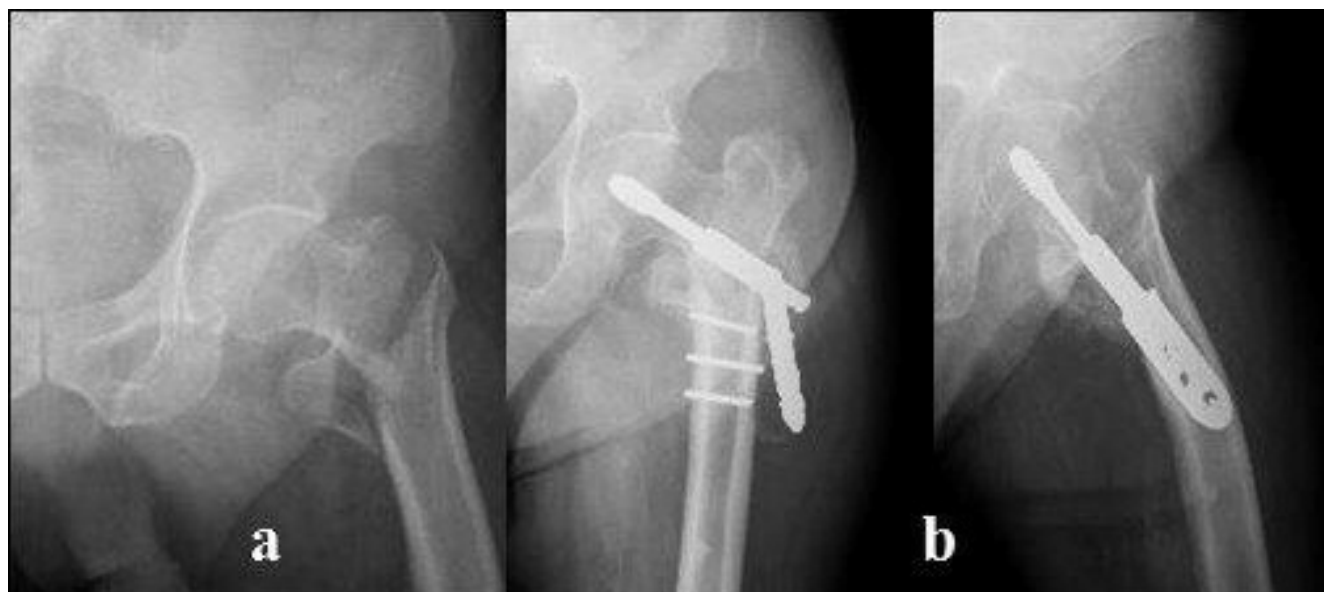

Figure 3 - Preoperative X-rays of a 80-year-old patient with a 31.A2 trochanteric fracture treated by DHS (a). Three months after surgery: screws breakage and varus deformity (b).

Table 2 - Mortality, dropouts, and complications.

	PFNa	DHS	Statistical significance
Dead at follow up 1 year	2	4	NS
Lost at follow up 3 months	1	1	NS
Lost at follow up 1 year	2	2	NS
Death	1	1	NS
Pulmonary infection	1	1	NS
Deep Venous Thrombosis	2	2	NS
Urinary tract infection	0	1	NS
Superficial wound infection	0	2	NS
Mechanical complications			
- Spiral Blade migration	2	/	NS
- Lateral blade protrusion	1	/	NS
- Migration of plate screws	/	1	NS
- Failure	1	1	NS

PFNa: proximal femoral nail antirotation. DHS: dynamic hip screw. Data are mean ± SD (range) for age or n. Quantitative variables were analyzed using the Student's t-test and categorical variables were analysed by the X2 test.

with 7 patients (10.1%) recommended to use permanently at least one cane.

In the PFNa series, we recorded radiographic findings of

complete fracture healing at 6-months in 59 patients (86.7%). At the same time, in the other 5 cases (7.2%), radiographs showed incomplete healing, even if clinically the patients were able to walk without a significant impairment, and with a painless ROM. At the same time, in the remainders (6.0%) we found a persistency of pain and a limited ROM correlated with an incomplete radiographic healing, and some functional limitation (all were 31.A2 fractures).

In the control series, we observed radiographic a complete fracture healing at 6-months in 53 patients (84.1%); in 6 patients (9.5%), radiographs showed incomplete healing without significative symptoms, and with almost full ROM. In the remainders (6.3%) persistency of pain and limited ROM correlated with incomplete radiographic healing at 6-months follow-up, corresponding in all cases to 31.A2 fractures.

Forty-nine patients (74.2%) treated by PFNa referred a restored walking ability and a feeling of health very close to the status before the fracture, reaching a mean value of 59.4 (range: 46-66) for the physical component, and 66.0 (range: 55-74) for the mental component of SF12 one year after surgery. Forty-one patients (66.1%) treated by DHS referred a full recovery and health status as before the fracture, reaching a mean value of physical component of 58.3 (range: 43-66), and mental of 64.7 (range: 55-72). Intra and post-operative data of the enrolled patients are presented in Table 3.

Finally, in 7 patients (10.6%) of group A and in 3 patients (4.8%) of group B we found periarticular ossifications after the first follow-up visit, treated with oral administration of daily 75 mgs of Indometacin for 4 weeks when appropriated.

Table 3 - Intra and postoperative data.

	PFNa	DHS	Statistical significance
Surgical time (minutes)	46.06 ± 10.10	61.21 ± 15.01	p < 0.01
Amplioscopic time	60.45 ± 16.52	45.89 ± 8.17	p < 0.01
Estimated intraoperative blood loss (cc)	127.80 ± 54.52	250.16 ± 89.54	p < 0.01
Postoperative blood bags (n)	2.10 ± 0.43	2.06 ± 0.36	NS
Hospital Stay (days)	6.91 ± 1.63 (4-13)	8.05 ± 2.46 (4-15)	p < 0.01
Walking with partial or full weight-bearing before discharge	71/71 (100%)	44/69 (63.76%)	p < 0.01
Independent walking ability at 3 months (n)	58/69 (81.60%)	45/67 (67.16%)	p < 0.05
Radiologic healing at 6 months (n)	59/68 (86.76%)	53/63 (84.12%)	NS
Patients'satisfaction at 6 months (n)	48/68 (70.58%)	33/63 (52.38%)	p < 0.05
SF12 mean value at 12 months			
• physical	59.7 ± 10.04	58.4 ± 9.78	NS
• mental	65.2 ± 11.06	64.2 ± 11.89	NS
Restore walking activity and health status pre-fracture at 12 months (n)	49/66 (74.24%)	41/62 (66.12%)	NS

PFNa: proximal femoral nail antirotation. DHS: dynamic hip screw. Data are mean ± SD (range) or n; Quantitative variables were analyzed using the Student's t-test and categorical variables were analyzed by the X2 test. NS not statistically significant (p>0.05).

Discussion

The surgical treatment of trochanteric fractures is intended to prevent morbidity and mortality, improving life quality, and limiting complications with a reduction of personal and social costs (2, 5-8). Even if still debated, an adequate choice of the fixation device may play a fundamental role. Surgery means an anatomical reduction, but also a stable fixation. The stability of a fracture depends on several factors: bone quality, fracture pattern, reduction, type of fixation device, surgical technique (38-40). The latter three factors are under surgeon's control, despite bone quality and type of fracture. However, the quality of reduction is also influenced by geometry of fragments, as positioning of fixation device is correlated with the device itself and pattern of fracture. Thus, the main variable actually related to surgeons is the choice of the fixation device. Many Authors consider SHS as the better choice even if this device has some biomechanical limitations. Its characteristic long lever arm may not allow early weight-bearing in unstable or reverse pattern fractures: in these cases, if prematurely allowed, the forces may typically bear on fracture site influencing negatively the healing process with concentration of excessive tensile thrusts. On the other hand, this may be limited increasing the number of holes and screws: such solution may not however ensure a stability in severe porotic bone. Finally, a high incidence of *cut-out* of SHS cephalic screw is reported in trochanteric fractures with inverse fracture pattern (21, 41). Recent data report about cases of excessive sliding of cephalic screw on the plate, causing groin pain, medial shift of distal fragment, and leg shortening: all these conditions may lead to high rates of fixation failure (12, 13, 41-43). However, as before mentioned, large series of patients with stable or rather stable (displaced reduced or not properly reduced) trochanteric fractures treated by SHS device showed excellent results (44). In the present experience, we had only one mechanical failure requiring surgery.

The PFNa was introduced to avoid the limits of extramedullary devices (19, 22, 23). Theoretical advantages were represented by the high biomechanical efficiency in unstable fractures, the low soft tissues and vascular supply damages, and the intrinsic mechanical solidity and load distribution with respect to SHS. The latter feature allows nails to support most of the forces acting on the hip during gait (axial weight-bearing and bending moments) avoiding stress on the fracture site (24, 45). There have been many changes and improvements, mostly to avoid mechanical complications often reported (iatrogenic fractures during nail positioning, poor rotation control of cephalic fragment). Recently, a brand new design of cephalic screw with a helical profile has been introduced as PFNa. Preclinical *in vitro* tests have shown high stability and elevated integration due to improved contact area with the host bone with respect to the previous mentioned devices (26). However, interesting studies have compared clinical and radiological results of fractures treated by SHS and intramedullary nails, with demonstration of efficacy for both systems at 6-month follow-up (7-9, 14, 25). The unstable fractures are usually challenging, and several reports confirmed the superiority of nails over plates in fixation and stability (21, 22, 24, 30). Referring to the PFNa system is reported less blood loss and shorter duration of hospitalization (31, 46) and also a lower biomechanical-inflammatory profile that can be related to a lower invasiveness of the procedure (47). Other Authors reported good results also with the SHS

(5, 6, 15, 25) with the same risk of postoperative complications of PFNa (48). The lack of structural bone on posterior and medial area of the proximal femoral metaphysis in 31.A2 type fractures and in the lateral cortex on type 31.A3 may theoretically cause instability with varus or rotational deformity and consequent pending cut-outs. Many studies report a lower incidence of complications for PFNa (46, 49, 50). According to these studies, we recorded a single mechanical failure of such nail requiring surgery. Some Authors has focused the attention on the importance of the femoral head rotation as a possible cause of cut-out (51, 52). The introduction of a helicoidal blade enhancing the contact area with bone and compression, ensures an additional antirotative effect (26, 50). Other studies reported about few cases of symptomatic perforation of the femoral head by the spiral blade without gross functional limitations (53, 54).

In our series, outcomes at one year after surgery, need for blood transfusions, and radiographic results were similar in the two groups. We observed significant differences in parameters such as intraoperative blood loss, surgical and amploscope times, hospital stay, recovery of weight-bearing before discharge in the PFNa group with respect to control ($p < 0.01$). Finally, less significant results ($p < 0.05$) were the walking ability at the three-months follow-up and the satisfaction referred by patients 6 months after surgery.

The overall complications rate on this series should be considered in line with the recent metanalysis (44, 55).

This study has several limits. The number of patients is not consistent; no specific study on bone density and bone metabolism was carried out, and the patients with neurologic or mental impairments were excluded. All these aspects surely influenced the final outcome, and particularly the selection of patients without mental conditions given the high rates of mental degenerative diseases generally affecting patients with a trochanteric fracture. However, no differences in complications rates between the two groups were recorded. On the basis of the present study, we support the effectiveness of intramedullary nailing as well as extramedullary device in the treatment of trochanteric fractures, allowing satisfactory results in stable or rather stable fractures. The light superiority of PFNa may be principally related to its mechanical advantages over sliding hip screw.

Acknowledgements

All Authors disclose any financial and personal relationships with other people or organizations that could have inappropriately influenced or biased their work.

References

1. Gullberg B, Johnell O, Kanis JA. World-wide projections for hip fractures. *Osteopor Int*. 1997;7:407-413.
2. Parker MJ. Cost-benefit analysis of hip fracture treatment. *J Bone J Surg Br*. 1992;74:261-264.
3. Weller I, Wai EK, Jaglal S, and Kreder HJ. The effect of hospital type and surgical delay on mortality after surgery for hip fracture. *J Bone J Surg Br*. 2005;87:361-366.
4. Matassi F, Carulli C, Munz G, Lualdi C, Civinini R, Innocenti M. Preliminary results of an early vs delayed timing of surgery in the management of proximal femur fragility fractures. *Clin Cases Miner Bone Metab*. 2015;12:11-17.
5. Bridle SH, Patel AD, Bircher M, et al. Fixation of intertrochanteric fractures of the femur: a randomized prospective comparison of the Gamma

- nail and Dynamic Hip Screw. *J Bone Joint Surg Br.* 1991;73:330-334.
6. Butt MS, Kriler SJ, Nafie S, et al. Comparison of Dynamic Hip Screw and Gamma nail: a prospective, randomized, controlled trial. *Injury.* 1995;26:615-618.
 7. Goldhagen PR, O'Connor DR, Schwarze D, et al. A prospective comparative study of the compression hip screw and the Gamma nail. *J Orthop Trauma.* 1994;8:367-372.
 8. O'Brien PJ, Meek RN, Blachunt PA, et al. Fixation of intertrochanteric hip fractures: Gamma nail vs Dynamic Hip Screw. A randomized, prospective study. *Can J Surg.* 1995;38:516-520.
 9. Redford PJ, Needoff M, Webb JK. A prospective randomized comparison of the Dynamic Hip Screw and the Gamma locking nail. *J Bone Joint Surg Br.* 1993;75:789-793.
 10. Ahregart L, Tornkvist H, Fornander P, et al. A randomized study of the compression hip screw and Gamma nail in 42 fractures. *Clin Orthop Relat Res.* 2002;401:209-222.
 11. Leung KS, So WS, Shen WY, et al. Gamma nails and Dynamic Hip Screws for peritrochanteric fractures: a randomized prospective study in elderly patients. *J Bone Joint Surg Br.* 1992;74:345-351.
 12. Parker MJ, Pryor GA. Gamma vs Dynamic Hip Screw nailing for extracapsular femoral fractures: meta-analysis of ten randomized trials. *Int Orthop.* 1996;20:163-168.
 13. Kim WY, Han CH, Park JI, et al. Failure of intertrochanteric fracture fixation with a Dynamic Hip Screw in relation of preoperative fracture stability and osteoporosis. *Int Orthop.* 2001;25:360-362.
 14. Pajarinen J, Lindahl J, Michelsson, et al. Peritrochanteric femoral fractures treated with a dynamic hip screw or a proximal femoral nail. A randomised study comparing post-operative rehabilitation. *J Bone Joint Surg Br.* 2005;87:76-81.
 15. Madsen JE, Naess L, Aune AK, et al. Dynamic Hip Screw with trochanteric stabilizing plate in the treatment of unstable proximal femoral fractures: a comparative study with the Gamma nail and compression hip screw. *J Orthop Trauma.* 1998;12:241-248.
 16. Haidukewych GJ, Israel TA, Berry DJ. Reverse obliquity fractures of the intertrochanteric region of the femur. *J Bone Joint Surg Am.* 2001;83-A:643-50.
 17. Sadowski C, Lübbecke A, Saudan M, Riand N, Stern R, Hoffmeyer P. Treatment of reverse oblique and transverse intertrochanteric fractures with use of an intramedullary nail or a 95 degrees screw-plate: a prospective, randomized study. *J Bone Joint Surg Am.* 2002;84:372-81.
 18. Matre K, Havelin LI, Gjertsen JE, Vinje T, Espehaug B, Fevang JM. Sliding hip screw versus IM nail in reverse oblique trochanteric and subtrochanteric fractures. A study of 2716 patients in the Norwegian Hip Fracture Register. *Injury.* 2013;44:735-742.
 19. Simmermacher RK, Bosch AM, Van der Werken C. The AO/ASIF proximal nail (PFN): a new device for the treatment of unstable proximal femoral fracture. *Injury.* 1999;30:327-332.
 20. Chevalley F, Gamba D. Gamma nailing of peritrochanteric and subtrochanteric fractures: clinical results of a series of sixtythree consecutive cases. *J Orthop Trauma.* 1997;11:412-415.
 21. Magit DP, Medvecky MJ, Baumgartner MR. Intramedullary nailing for the management of intertrochanteric and subtrochanteric geriatric fractures. *Techn Orthop.* 2004;19:153-162.
 22. Schipper IB, Steyerberg EW, Castelein RM, et al. Treatment of unstable trochanteric fractures. Randomized comparison of the Gamma nail and the Proximal Femoral Nail. *J Bone Joint Surg Br.* 2004;86:86-94.
 23. Zickel RE. A new fixation device for subtrochanteric fractures of the femur: a preliminary report. *Clin Orthop Relat Res.* 1967;54:115-123.
 24. Bellabarba C, Herscovici D, Ricci WM. Percutaneous treatment of peritrochanteric fractures using the Gamma nail. *Clin Orthop Relat Res.* 2000;375:30-42.
 25. Rantanen J, Aro HT. Intramedullary fixation of high subtrochanteric femoral fractures: a study comparing two implants design, the Gamma nail and the intramedullary hip screw. *J Orthop Trauma.* 1998;12:249-252.
 26. Sommers MB, Roth C, Hall H, et al. A laboratory model to evaluate cutout resistance of implants for peritrochanteric fracture fixation. *J Orthop Trauma.* 2004;18:361-368.
 27. Gardenbroek TJ, Segers MJ, Simmermacher RK, Hammacher ER. The proximal femur nail antirotation: an identifiable improvement in the treatment of unstable peritrochanteric fractures? *J Trauma.* 2011;71:169-174.
 28. Knoke M, Drescher W, Heussen N, Sellei RM, Pape HC. Is helical blade nailing superior to locked minimally invasive plating in unstable peritrochanteric fractures? *Clin Orthop Relat Res.* 2012;470:2302-2312.
 29. Zou J, Xu Y, Yang H. A comparison of proximal femoral nail antirotation and dynamic hip screw devices in trochanteric fractures. *J Int Med Res.* 2009;37:1057-1064.
 30. Şahin EK, İmerci A, Kırık H, Karapınar L, Canbek U, Savran A. Comparison of proximal femoral nail antirotation (PFNA) with AO dynamic condylar screws (DCS) for the treatment for unstable peritrochanteric femoral fractures. *Eur J Orthop Surg Traumatol.* 2014;24:347-352.
 31. Ma KL, Wang X, Luan FJ, Xu HT, Fang Y, Min J, Luan HX, Yang F, Zheng H, He SJ. Proximal femoral nails antirotation, gamma nails, and dynamic hip screws for fixation of intertrochanteric fractures of femur: a meta-analysis. *Orthop Traumatol Surg Res.* 2014;100:859-866.
 32. Müller ME, Nazarian S, Koch P, Schatzker J. The Comprehensive Classification of Fractures of Long Bones. Mau Springer, Springer-Verlag, Berlin. 1990;120-121.
 33. Ware JE, Kosinski M, Keller SD. A 12-Item Short-Form Health Survey: Construction of scales and preliminary tests of reliability and validity. *Medical Care.* 1996;34:220-233.
 34. Kyle RF, Gustilo RB, Premer RF. Analysis of six hundred and twenty-two intertrochanteric hip fractures. A retrospective and prospective study. *J Bone Joint Surg Am.* 1979;61:216-221.
 35. Baumgaertner MR, Curtin SL, Lidskog DM, Keggi JM. The value of the Tip-Apex Distance in predicting failure of fixation of peritrochanteric fractures of the hip. *J Bone Joint Surg Am.* 1995;77:1058-1064.
 36. Parmar V, Kumar Shyam AJ. The importance of surgical education in the accuracy of implant placement during hip fracture fixation. *J Orthopaed Traumatol.* 2009;10:59-61.
 37. Kraus M, Krischak G, Wiedmann K, Riepl C, Gebhard F, Jöckel JA, Scola A. Clinical evaluation of PFNA® and relationship between the tip-apex distance and mechanical failure. *Unfallchirurg.* 2011;114:470-8.
 38. Innocenti M, Civinini R, Carulli C, Matassi F. Proximal femoral fractures: epidemiology. *Clin Cases Miner Bone Metab.* 2009;6:117-119.
 39. Carulli C, Matassi F, Civinini R, Villano M, Innocenti M. Surgical prosthetic treatment. *Clin Cases Miner Bone Metab.* 2010;7:32-38.
 40. Kaufer H. Mechanism of the treatment of hip injuries. *Clin Orthop Relat Res.* 1980;146:53-61.
 41. Rha JD, Kim YH, Yoon SI, et al. Factors affecting sliding of the lag screw in intertrochanteric fractures. *Int Orthop.* 1993;17:320-324.
 42. Jacobs RR, McClain O, Armstrong HJ. Internal fixation of intertrochanteric hip fractures: a clinical and biomechanical study. *Clin Orthop Relat Res.* 1980;146:62-70.
 43. Baixauli F, Vincent V, Baixauli E, et al. A reinforced rigid fixation device for unstable intertrochanteric fractures. *Clin Orthop Relat Res.* 1999;361:205-215.
 44. Parker MJ, Handoll HHG. Gamma and other cephalocondylic intramedullary nails versus extramedullary implants for extracapsular hip fractures in adults. *Cochrane Database Syst Rev.* 2010;8:CD000093.
 45. Baumgartner MR, Curtin SL, Lidskog DM, et al. Intramedullary vs extramedullary fixation for treatment of intertrochanteric hip fractures. *Clin Orthop Relat Res.* 1998;348:87-94.
 46. Shen L, Zhang Y, Shen Y, Cui Z. Antirotation proximal femoral nail versus dynamic hip screw for intertrochanteric fractures: A meta-analysis of randomized controlled studies. *Orthop Traumatol Surg Res.* 2013;99:377-383.
 47. Marino M, Palmieri G, Peruzzi M, Scuderi F, Bartocioni E. A Study of Inflammatory/Necrosis Biomarkers in the Fracture of the Femur Treated with Proximal Femoral Nail Antirotation. *Mediators Inflamm.* 2015; 2015:1-5.
 48. Zehir S, Zehir R, Zehir S, Azboy İ, Haykir N. Proximal femoral nail antirotation against dynamic hip screw for unstable trochanteric fractures; a prospective randomized comparison. *Eur J Trauma Emerg Surg.* 2014;41:393-400.
 49. Takigami, Matsumoto K, Ohara A, Yamanaka K, Naganawa T, Ohashi M, Date K, Shimizu K. Treatment of trochanteric fractures with the PFNA (proximal femoral nail antirotation) nail system - report of early results. *Bull NYU Hosp Jt Dis.* 2008;66:276-279.
 50. Simmermacher RKJ, Ljungqvist J, Bail H, Hockertz T, Vochteloo AJH, Ochs U, Werken CVD. The new proximal femoral nail antirotation (PFNA®) in daily practice: Results of a multicentre clinical study. *Injury.* 2008;39:32-939.

51. De Bruijn K, den Hartog D, Tuinebreijer W, Roukema G. Reliability of predictors for screw cutout in intertrochanteric hip fractures. *J Bone Joint Surg Am.* 2012;94:1266-1272.
52. Chinzei N, Hiranaka T, Niikura T, Tsuji M. Comparison of the Sliding and Femoral Head Rotation among Three Different Femoral Head Fixation Devices for Trochanteric Fractures. *Clin Orthop Surg.* 2015;3:291-297.
53. Takigami, Ohnishi K, Ito Y, Nagano A, Sumida H, Tanaka K, Shimizu K. Acetabular Perforation After Medial Migration of the Helical Blade Through the Femoral Head After Treatment of an Unstable Trochanteric Fracture With Proximal Femoral Nail Antirotation (PFNA): A Case Report. *J Orthop Trauma.* 2011;25:86-e89.
54. Brunner A, Jockel JA, Babst R. The PFNA proximal femur nail in treatment of unstable proximal femur fractures: 3 cases of postoperative perforation of the helical blade into the hip joint. *J Orthop Trauma.* 2008;22:731-736.
55. Evaniew N Bhandari M. Cochrane in CORR®: Intramedullary Nails for Extracapsular Hip Fractures in Adults (Review). *Clin Orthop Relat Res.* 2015;473:767-774.