

Primary Pyomyositis as Unusual Cause of Limp: Three Cases in Immunocompetent Children and Literature Review

Livia Drovandi¹ Sandra Trapani¹ Simona Richichi¹ Donatella Lasagni¹ Massimo Resti¹

¹Paediatric Unit, Department of Sciences of Health, Anna Meyer Children's Hospital, Florence, Italy

Address for correspondence Livia Drovandi, MD, Paediatric Unit, Department of Sciences of Health, Anna Meyer Children's Hospital, Viale Pieraccini, 24, 50139 Florence, Italy (e-mail: livia.drovandi@gmail.com).

J Pediatr Infect Dis 2018;13:242–246.

Abstract

Pyomyositis (PM) is an uncommon primary skeletal muscle infection caused mainly by *Staphylococcus aureus* that is characterized by single or multiple intramuscular abscess formation. In our ward, between 2013 and 2015, three children (two females and one male) aged from 2 to 12 years were diagnosed and treated for PM. Patients' medical records and imaging studies were examined retrospectively. All patients, otherwise healthy, complained of limp, fever, and severe lower limb pain. Skin scratch lesions were detected in two cases; one of them showed an edematous appearance of the affected area. Multifocal bilateral abscesses of gemini and gastrocnemius were detected in the youngest patient; right obturator and iliac muscles were affected in the second patient; and right gluteus and piriform muscles were involved in the third patient. All patients showed elevated acute phase reactants and had normal serum creatinine kinase levels. Blood cultures and polymerase chain reaction (PCR) investigations were negative in all cases. Magnetic resonance imaging (MRI) findings included muscle enlargement, deep fascia, high signal in subcutaneous tissues, and postgadolinium abscess formation. No patient required surgical or percutaneous drainage. All three were treated conservatively with intravenous oxacillin, associated with ceftriaxone in the first patient and ceftazidime in the other two, followed by oral antibiotic therapy for a period ranging from 5 to 6 weeks. Pyomyositis must be considered as an unusual cause of limp in children of all ages. When promptly diagnosed and adequately treated, it has a favorable outcome without relapses or sequelae as occurred in all our patients.

Keywords

- ▶ pyomyositis
- ▶ children
- ▶ limp
- ▶ musculoskeletal infection

Introduction

Pyomyositis (PM) is a primary infection of skeletal muscles characterized by intramuscular abscesses due to hematogenous spread from occult sources. The most common microorganism implicated is *Staphylococcus aureus*. Trauma, malnutrition, and immunodeficiency may have important predisposing roles. Primary PM in immunocompetent children is uncommon in nontropical regions. The most commonly involved muscles are quadriceps, gluteal, ileopsoas, gastrocne-

mius, abdominal, and spinal muscles. Prompt diagnosis is difficult because of nonspecific clinical signs and the wide range of differential diagnoses. Radiological evaluation by magnetic resonance imaging (MRI) is extremely useful; the gold standard for diagnosis is the culture of pus aspirated from the affected muscles, when possible. Treatment consists of intravenous antibiotics and abscess drainage depending on its size and depth. When not properly treated, PM can progress to osteomyelitis and septic arthritis, and even to life-threatening septic shock. Between 2013 and 2015, three children aged from

received
March 13, 2017
accepted after revision
May 18, 2017
published online
July 4, 2017

Copyright © 2018 by Georg Thieme
Verlag KG, Stuttgart · New York

DOI <https://doi.org/10.1055/s-0037-1604036>.
ISSN 1305-7707.

2 to 12 years were diagnosed and treated in our ward for multifocal PM. Patients' medical records and imaging studies were retrospectively examined. Pyomyositis involved bilaterally gastrocnemius, gemini, and tibialis muscles in the youngest patient, iliac and iliopsoas muscles in the second patient, and gluteus and piriform muscles in the third complicated with iliac osteomyelitis. None of them had trauma, underlying diseases, or immunodeficiency.

Case 1

A 2-year-old female patient presented with fever, lower limb pain, and refusal to walk. Ibuprofen was administered without any improvement. There was no history of trauma, skin lesions, or overseas travel. Diffuse tenderness in the gastrocnemius muscles, slight limp, and unwillingness to bear weight were associated with hyperpyrexia. Hip ultrasound revealed distension of joint capsule and moderate synovial enlargement. Laboratory data showed mild leukocytosis (white blood cell [WBC], 20,000/ μ L) and an elevated C-reactive protein (CRP, 6.31 mg/dL). The child was discharged with diagnosis of transient arthritis on nonsteroidal anti-inflammatory drugs (NSAIDs) and antibiotic treatment. Two days later, the fever and limb pain had worsened, and the child now also had a mild sore throat, vomiting, and diarrhea; she represented to the emergency department. Due to the increased leukocytosis (WBC, 42,280/ μ L) and CRP (19.2 mg/dL), she was admitted to our ward. Blood cultures were negative for aerobic, anaerobic, and fungal agents. Severe tenderness was still present on palpation of both calves; active, but not passive, movement elicited pain.

Initially, a slight improvement in acute phase reactants (WBC, 31,310/ μ L; CRP, 17.6 mg/dL; erythrocyte sedimentation rate [ESR], 43 mm/h) was observed. Creatine phosphokinase (CPK), lactate dehydrogenase (LDH), uric acid, and ferritin levels were within normal ranges; serum aldolase

was increased up to 17.8 U/L (normal value <7.3 U/L). Group A *Streptococcus*-induced myositis was excluded by low anti-streptolysin O (ASO) and anti-DNase B antibody titers. A blood sample tested negative for *Streptococcus pneumoniae*, *Streptococcus pyogenes*, and *Staphylococcus aureus* by polymerase chain reaction (PCR). A stool sample tested negative for enteroviruses, rotaviruses, and adenoviruses by PCR. A pharyngeal swab tested for adenoviruses, influenza viruses, and coxsackieviruses by PCR was also negative. Serodiagnostic tests for *Salmonella* and *Brucella* were also negative.

Lower limb musculoskeletal ultrasound showed abnormal echotexture with multiple hypoechoic little focal ovular lesions in the gemini and anterior tibialis muscles. X-rays of the lower limbs and chest, abdomen ultrasound, and cardiac echocolor Doppler were normal. MRI showed multiple bilateral ovular focal areas of low attenuation in both gastrocnemius muscles with smooth peripheral rim enhancement after contrast administration. Postgadolinium scans demonstrated pathological enhancement of the gastrocnemius fascia; similar pronounced areas were found in the posterior and medial thigh muscles with subcentimetric lymph nodes in popliteal fossa (→Fig. 1a, b). Suspecting a musculoskeletal infection, empiric antibiotic therapy with ceftriaxone and oxacillin was commenced. On the third day, the child became afebrile, muscle tenderness progressively decreased, and she could walk. Clinical healing was confirmed by normalization of hematological and radiological features. After 2 weeks of IV antibiotics, she was discharged with a 3-week course of oral therapy. Three months later, the child appeared in good general health; extensive immunological evaluations were normal, including quantitative immunoglobulins, enumeration of T-lymphocyte subpopulations, total hemolytic complement levels, and leukocyte function by reduction of nitroblue tetrazolium (NBT). Six months later, an MRI confirmed complete remission. At 1-year follow-up, the patient had not suffered any relapses or sequels.

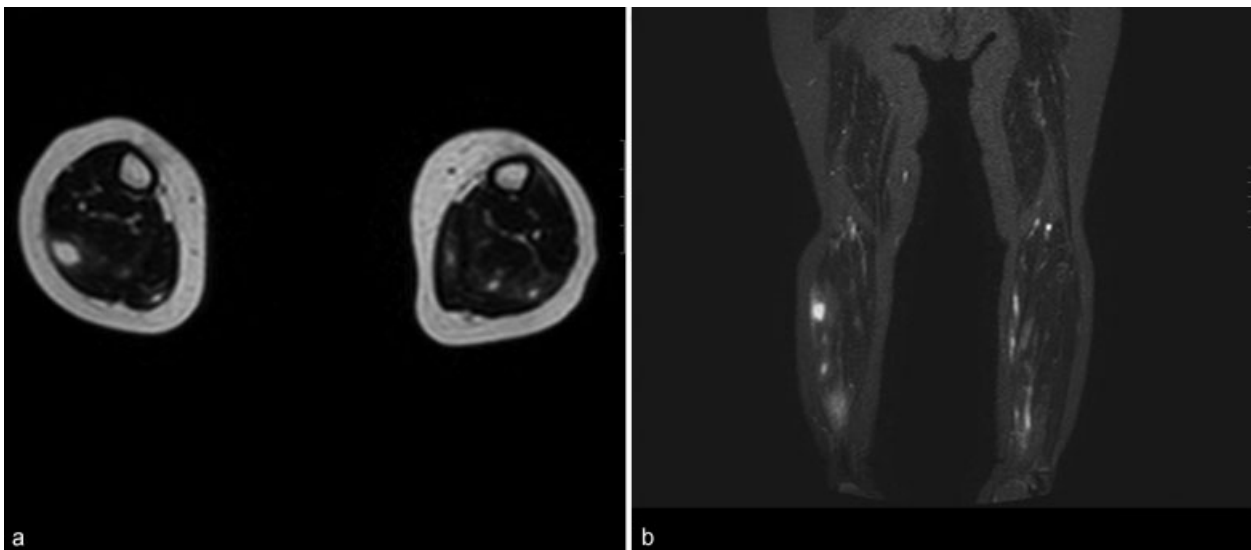


Fig. 1 Sagittal (a) and coronal (b) lower limbs magnetic resonance imaging (MRI) indicative of multiple bilateral abscesses in both gastrocnemius muscles with smooth peripheral rim enhancement after contrast administration. Postgadolinium scans demonstrated pathological enhancement of its fascia with subcentimetric lymph nodes in popliteal fossa.

Case 2

A 12-year-old male patient was admitted to a peripheral hospital complaining of right leg and gluteal pain with limp and functional deficiency. There was no history of trauma or of travel abroad. He suffered from atopic dermatitis and had scratch marks over the popliteal skin. Topical anti-inflammatory drugs were applied without any improvement. Laboratory data were normal while lumbosacral spine X-ray showed S1 vertebral schisis. Neurological pain was suspected and the child was transferred to our emergency department. He appeared pale and uncomfortable; he had a low-grade fever and cutaneous oozing lesions in the popliteal regions. Severe gluteal pain was elicited by movements with loss of power and hyporeflexia and a positive Lasègue's sign; there was no loss of sensation or sphincter function. Pain was uncontrollable by intravenous analgesia; the right leg was extended and adducted and the child was unable to walk. Lumbosacral MRI confirmed the schisis but excluded spondylodiscitis and neoplastic and neurosurgical conditions. Laboratory tests showed neutrophil leukocytosis (WBC, 18,050/ μ L; neutrophils, 88.8%) and elevated CRP (7 mg/dL). Liver and renal function tests, electrolytes, LDH, CPK, and ferritin levels were within the normal range. Serum aldolase level was 10.8 U/L (normal value <7.3 U/L). Haplotype, HLA B27, was negative. Repeated blood cultures were negative. A cutaneous swab and blood were both negative for *S. aureus*, *S. pyogenes*, and *S. pneumoniae* by PCR. The ASO titer was low, antibodies for *Salmonella* and *Brucella* were negative, and a QuantiFERON test was also negative. An X-ray of the pelvis and sacroiliac joints was negative, but MRI showed diffuse inflammation in all the right thigh and pelvic muscles with multiple nonenhancing areas compatible with multiples abscesses, unreachable by fine needle aspiration. A diagnosis of PM was made and empirical IV antibiotic therapy with ceftriaxone and oxacillin was commenced. Due to the poor clinical response, clindamycin was later added, which was followed by a progressive reduction of CRP. A comprehensive immunological evaluation was normal. During the following days, the patient was gradually able to stand although mild tenderness over the sacroiliac joints persisted. A further MRI of the pelvis and sacroiliac joints confirmed a reduction in the muscle inflammation but showed iliac wing bone and right sacroiliac joint involvement without joint effusion. With a diagnosis of PM complicated by osteomyelitis, IV antibiotic therapy was continued for 4 weeks; the patient was then discharged on oral antibiotics for another 2 weeks. Two months after the discharge, he was asymptomatic without hematological alterations.

Case 3

A 4-year-old female patient was referred to our emergency department complaining of right hip pain, functional deficiency, and limp associated with a high-grade fever. Again, there was no previous history of trauma or travel abroad. However, there was a history of a 5-day episode of fever occurring 2 weeks previously. Laboratory data showed CRP of 8.57 mg/dL and ESR of 67 mm/h with mild leukocytosis

(WBC, 20,270/L; N, 83%). Ultrasound examination revealed a gluteal abscess and plain X-ray confirmed soft tissue edema in the right buttock. On physical examination, the girl was febrile and there was flexed decubitus of the right leg while the upper gluteal region was hot and swollen. Leg extension and internal rotation of the right hip were limited and painful. Infected scratch marks were noted on the sacral region skin. Blood cultures and ASO titer were negative. After making a provisional diagnosis of acute musculoskeletal infection, IV oxacillin and ceftazidime were started. An abdominal MRI scan confirmed a large abscess in the right gluteus muscle extending along its fibers into its insertion and piriform muscle until the right sacroiliac bone. Testing of blood for *S. pyogenes*, *S. pneumoniae*, and *S. aureus* by PCR was negative and culture of the infected skin lesions was unrevealing. Tests for antibodies against *Salmonella* and *Brucella* were negative as was a QuantiFERON test; immunological workup was normal. The patient was hospitalized for 3 weeks for parenteral antibiotic therapy and then discharged to continue oral antibiotic therapy for a further 7 days. Because of the prompt response to antibiotic therapy, surgical drainage was not considered necessary. Three months later, the child was asymptomatic with a full range of hip movements and no residual disability.

Discussion

Pyomyositis is a primary acute pyogenic infection of the skeletal muscles with abscess formation.¹ It is known as an endemic entity in the tropical areas, where almost 40% of cases are pediatric. It is less common in temperate climates (1 per 3,000 pediatric admissions), mostly related to underlying conditions associated with being immunocompromised.² Because of its rarity and the nonspecific nature of the signs and symptoms, the diagnosis is often delayed, the mean delay being 10 days. In our cases, the mean time to diagnosis was 5 days, rather shorter than previously reported. It is postulated that PM occurs when a transient bacteremia (mainly from cutaneous sites as in our cases, 2 and 3) seeds a site of muscle injury. Pelvic and lower limb muscles are the most commonly affected sites in children, requiring a careful differential diagnosis from septic arthritis or intra-abdominal processes. PM is more commonly a unilateral infection, mainly affecting the dominant side of the body.³ However, being a complication of transient bacteremia, it can also have a multifocal dissemination as in our first and second cases. According to literature, only 10 to 20% of PM is multifocal.⁴ *S. aureus* is the most commonly implicated microorganism associated with up to 90% of cases in tropical areas and 75% in temperate countries with an increasing frequency of methicillin-resistant *S. aureus* (MRSA).⁵ Group A streptococci account for another 1 to 5% of cases. Other uncommonly implicated microorganisms are *S. pneumoniae*,⁶ *Neisseria*, *Haemophilus*, *Serratia*, *Yersinia*, *Pseudomonas*, *Klebsiella*, and *Enterococcus* species and *Escherichia coli*. More rarely, anaerobes and *Mycobacterium* have been reported, mostly in immunocompromised adults. *Salmonella enterica* is another very rare cause of PM in healthy children.⁷ Clinical features are various during the different

phases of the disease. The first one (invasive stage) is characterized by insidious onset of strong cramping pain with anorexia and fever. Clinical examination reveals localized edema with or without erythema. The muscle is woody with either little or no tenderness. In this phase, lasting from 10 to 21 days, children are mostly treated with NSAIDs without improvement as in our cases. Only 2% of patients are correctly diagnosed at this stage. The second, purulent or suppurative stage, in which most patients present to the physician, occurs when abscess forms in the muscle context. Needle aspiration in this phase yields pus. High-spiking fever and severe systemic symptoms mark the beginning of this stage. The third stage is characterized by tenderness of the involved area. The patient has a high fever and may occasionally be in a septic shock. Septicemia, septic shock, acute renal failure, and metastatic abscesses are some of the complications described. When PM involves the muscles of the pelvis, pain is usually transferred to the hip. To recognize PM, the first step is a careful clinical evaluation: a distinctive combination of painful active motion and pain-free passive motion of the joint involved is a characteristic as in our first case.⁸ It is noteworthy that patients with pelvic PM may also present with limited range of articular motion as commonly seen in septic arthritis.³ Laboratory tests may reveal high ESR and CRP, which are the most sensitive and helpful laboratory parameters in monitoring the disease course and its response to treatment.⁹ Leukocytosis always develops 12 to 24 hours later. CPK level is usually normal while serum aldolase may be increased as in our cases. Concerning radiological evaluation, plain radiography may be useful to help exclude osteomyelitis (OM); ultrasonography, though widely available, is not always diagnostic. MRI is the gold standard method for imaging.⁹ The causal relationship between OM and PM is difficult to resolve, especially when the two conditions appear to occur simultaneously as in our second case. OM is usually considered a complication of PM, but in most cases, both of them probably represent simultaneous manifestations of the same bacteremia. Alternatively, secondary OM may arise, either from a subsequent bacteremia or through contiguous extension of the muscular infection; a reactive aseptic OM must also be considered. Rarely, PM can be the complication of a primary OM. Secondary PM is even rarer and is associated with non-*S. aureus* infections.¹⁰ In both cases, the frequent occurrence of periosteal reaction and fistula proves the causal relationship.

The etiological diagnosis of PM is often difficult; blood cultures are frequently negative and therefore *S. aureus* must be regarded empirically as the causal germ. Gold standard for diagnosis is aspiration and analysis of the pus from the muscle or muscular biopsy with culture and tissue staining in case of macroabscesses. The right approach is to perform blood culture only in the case of unresponsiveness of drained material culture. Concerning our patients, no drainage of abscesses was performed due to the prompt response to empiric antibiotic therapy; moreover, in the first case, the abscesses were multiple and small and in the second case, they were too deep. In all three cases, repeated blood cultures were negative, underlining the observation by Section et al that blood cultures may be positive in a good

proportion of OS cases, but not in other musculoskeletal infections as PM.¹¹ Notably, PCR-based testing for *S. aureus*, *S. pyogenes*, and *S. pneumoniae* was also negative in all three of our cases.

For therapy, univocal guidelines for the management are not available. The best practice depends on the stage at presentation⁹ and upon local epidemiology and susceptibility patterns. Because *S. aureus* is the most common causative agent, empiric therapy (targeting that microorganism and other gram-positive bacteria), such as oxacillin or cloxacillin 150 to 200 mg/kg intravenously every 6 hours, is usually administered. Another approach is to start treatment with broad-spectrum antibiotics as we did in all our cases and as was suggested by Verma.³ For MRSA (demonstrated or epidemiologically suspected), clindamycin (alone or associated with cloxacillin or amikacin) is recommended.³ Vancomycin, teicoplanin, or linezolid are required in cases of clindamycin-resistant MRSA.³ When group A streptococci are isolated, treatment should be changed to benzyl penicillin.^{5,12} For gram-negative bacteria, an aminoglycoside (gentamicin) should be considered in addition to cephalosporins.^{5,13} In immunocompromised patients, ampicillin/sulbactam or piperacillin/tazobactam may be required. If *Pseudomonas aeruginosa* infection is suspected, ceftazidime may be the treatment of choice; if anaerobic infection is suspected, metronidazole is indicated.⁵ The optimal treatment duration is not defined: we successfully treated our patients with 4 weeks of IV therapy followed by 2 weeks of oral antibiotics. Shorter course IV treatment is effective too, if followed by 2 to 6 weeks of oral therapy¹⁴ as in osteoarticular infections.¹⁵ However, the administered therapy must be continued until the leukocyte count normalizes and the patient remains afebrile for 7 to 10 days. Our experience confirms that when a prompt and adequate antibiotic therapy is performed, surgical or percutaneous drainage is not always necessary in uncomplicated cases of childhood PM. Children should be monitored carefully for relapse, which should be suspected with any episode of fever after healing. Untreated PM can lead to serious local complications, including compartment syndrome and osteonecrosis,¹⁶ and disseminated illness including organ involvement and septic shock; the mortality rate may be as high as 0.5 to 2%.⁹ With adequate treatment, PM usually resolves without any sequelae as in all our cases.

Conclusion

The aim of this paper was to focus the attention on the potential for multifocal primary PM in immunocompetent children to present to the pediatrician with a limp, even in temperate countries. In recent years, PM is being more frequently diagnosed, probably as a result of a greater availability of diagnostic tests.⁹ However, there may also be an increase in the incidence of this condition. Some authors have suggested that the emergence of MRSA has added to the burden of PM in temperate countries, but this view is not supported by recent studies.¹⁴ In conclusion, this report highlights the main features of this unusual entity and emphasizes the need for an early imaging in case of unexplained limp to also provide a

correct differential diagnosis between PM and OM. Uncontrolled PM can cause sequelae as septic shock, OM, and septic arthritis. Awareness of this condition will facilitate both correct diagnosis and early treatment.

Compliance with Ethical Standards

This article does not contain any studies with human or animals performed by any of the authors.

Conflict of Interests

All authors declare that they have no conflict of interests.

References

- Mitsionis GI, Manoudis GN, Lykissas MG, et al. Pyomyositis in children: early diagnosis and treatment. *J Pediatr Surg* 2009; 44(11):2173–2178
- Crum NF. Bacterial pyomyositis in the United States. *Am J Med* 2004;117(06):420–428
- Verma S. Pyomyositis in children. *Curr Infect Dis Rep* 2016; 18(04):12
- Hashemi SA, Vosoughi AR, Pourmokhtari M. Hip abductors pyomyositis: a case report and review of the literature. *J Infect Dev Ctries* 2012;6(02):184–187
- Chauhan S, Jain S, Varma S, Chauhan SS. Tropical pyomyositis (myositis tropicans): current perspective. *Postgrad Med J* 2004; 80(943):267–270
- Zadroga RJ, Zylla D, Cawcutt K, et al. Pneumococcal pyomyositis: report of 2 cases and review of the literature. *Clin Infect Dis* 2012; 55(03):e12–e17
- Minami K, Sakiyama M, Suzuki H, Yoshikawa N. Pyomyositis of the vastus medialis muscle associated with *Salmonella enteritidis* in a child. *Pediatr Radiol* 2003;33(07):492–494
- Gonzalez Moran G, Garcia Duran C, Albiñana J. Imaging on pelvic pyomyositis in children related to pathogenesis. *J Child Orthop* 2009;3(06):479–484
- García-Mata S, Hidalgo-Ovejero A, Esparza-Estaun J. Primary obturator-muscle pyomyositis in immunocompetent children. *J Child Orthop* 2012;6(03):205–215
- Corey SA, Agger WA, Saterbak AT. Acromioclavicular septic arthritis and sternoclavicular septic arthritis with contiguous pyomyositis. *Clin Orthop Surg* 2015;7(01):131–134
- Section J, Gibbons SD, Barton T, Greenberg DE, Jo CH, Copley LA. Microbiological culture methods for pediatric musculoskeletal infection: a guideline for optimal use. *J Bone Joint Surg Am* 2015; 97(06):441–449
- Tennant SJ, Burgess DR, Rybak JM, Martin CA, Burgess DS. Utilizing Monte Carlo simulations to optimize institutional empiric anti-pseudomonal therapy. *Antibiotics (Basel)* 2015;4(04):643–652
- Bassetti M, Righi E. New antibiotics and antimicrobial combination therapy for the treatment of gram-negative bacterial infections. *Curr Opin Crit Care* 2015;21(05):402–411
- Miller NJ, Duncan RD, Huntley JS. The conservative management of primary pyomyositis abscess in children: case series and review of the literature. *Scott Med J* 2011;56(03):i-181
- Moriarty P, Leung C, Walsh M, Nourse C. Increasing pyomyositis presentations among children in Queensland, Australia. *Pediatr Infect Dis J* 2015;34(01):1–4
- Taksande A, Vilhekar K, Gupta S. Primary pyomyositis in a child. *Int J Infect Dis* 2009;13(04):e149–e151