

Cite this article as: Bongiolatti S, Voltolini L, Borgianni S, Borrelli R, Tancredi G, Viggiano D *et al.* Uniportal thoracoscopic decortication for pleural empyema and the role of ultrasonographic preoperative staging. *Interact CardioVasc Thorac Surg* 2017;24:560–6.

# Uniportal thoracoscopic decortication for pleural empyema and the role of ultrasonographic preoperative staging<sup>†</sup>

Stefano Bongiolatti<sup>§,\*</sup>, Luca Voltolini, Sara Borgianni, Roberto Borrelli, Giorgia Tancredi,  
Domenico Viggiano and Alessandro Gonfiotti<sup>§</sup>

Thoracic Surgery Unit, University Hospital Careggi, Florence, Italy

\* Corresponding author. Thoracic Surgery Unit, University Hospital Careggi, Largo Brambilla 3, 50134 Florence. Tel: +39-055-7946807; fax: +39-055-7949557; e-mail: stefanobongiolatti@gmail.com (S. Bongiolatti).

Received 6 July 2016; received in revised form 19 November 2016; accepted 29 November 2016

## Abstract

**OBJECTIVES:** The surgical approach to chronic pleural empyema is still controversial. Video-assisted thoracic surgery (VATS) debridement and decortication has shown favourable outcomes, while the uniportal VATS (U-VATS) approach is still anecdotal. We report our experience with ultrasonographic (US) preoperative staging followed by U-VATS decortication for pleural empyema.

**METHODS:** We performed a retrospective analysis of patients who underwent surgical treatment of stage II and stage III pleural empyema from 2012 to 2015. Pre-, intra- and postoperative data were investigated to evaluate outcomes including postoperative complications and disease recurrence. Results were analysed according to preoperative US appearance of pleural space (stages A–E) and surgical approach (thoracotomy vs U-VATS).

**RESULTS:** We performed 30 (47%) uniportal thoracoscopic pleural decortication and 34 (53%) open decortication for empyema in stage II (40%) or III (60%) obtaining a complete debridement and decortication in all patients. In-hospital mortality was zero and overall morbidity was 29%. U-VATS was associated with lower blood loss ( $118 \pm 80$  ml vs  $247 \pm 140$  ml  $P < 0.001$ ), lower chest tubes duration ( $5.6 \pm 1.4$  vs  $10.6 \pm 4.4$  days  $P < 0.001$ ), shorter hospital stay ( $6.7 \pm 1.9$  vs  $12.2 \pm 4.7$  days,  $P < 0.001$ ) and lower complications (10% vs 16%,  $P < 0.001$ ). Elevated US patterns (D–E) are associated with thoracotomy, higher blood loss, operative time and a significant incidence of complications.

**CONCLUSIONS:** Uniportal thoracoscopic decortication for pleural empyema is a safe and effective approach for selected patients based on a combination of clinical and imaging staging. US patterns well corresponded with intraoperative pleural findings and showed a prognostic value.

**Keywords:** Pleural empyema • Ultrasonography • Decortication • Uniportal-VATS surgery

## INTRODUCTION

The recent literature demonstrated that an early and aggressive minimally invasive approach for empyema in phase II provides rapid relief from infection and guarantees lower morbidity rate, short hospital stay, lower costs and clinical resolution [1–4]; however, the role of video-assisted thoracic surgery (VATS) in later organizing phase empyema is still controversial. The objective of surgical treatment of chronic pleural empyema is to drain infected collections from pleural cavity and to achieve a complete lung re-expansion by removal of visceral cortex. Some studies [5–8] showed that VATS decortication is feasible and safe with similar outcomes in terms of resolution of infection and

functional results, and some advantages related to less morbidity and better visualization of entire pleural cavity in comparison to thoracotomy. A recent consensus statement by European Association for Cardio-Thoracic Surgery (EACTS) [9] concluded that VATS has an important role in the management of pleural empyema determined by its safety and effectiveness both in stages II and III, but thoracotomy still plays a fundamental role especially for decortication. The application of the uniportal VATS (U-VATS) approach for the treatment of pleural infection is not yet well identified, but it could be useful to minimize surgical trauma.

Diagnostic imaging (chest X-ray, computed tomography [CT] scan and chest ultrasonography) are useful to determine the boundary pleural effusion, the pleural thickening, the presence of adhesions, loculations, septa and underlying pulmonary disease. For these purposes, chest ultrasonography (US) has advantages over CT including safety, absence of radiation exposure, non-invasiveness, low-cost and identification of the distribution of

<sup>†</sup>Presented at the 24th European Conference on General Thoracic Surgery, Naples, Italy, 29 May–1 June 2016.

<sup>§</sup>These authors contributed equally to this work.

pleural fluid, the presence of loculations and septa and permit to guide real-time manoeuvres [10]. However, US does not have a clear role in defining the time of surgery and suggesting the surgical approach which is chosen according to the onset of symptoms, the infectious status and the empyema stage. This information, related to other clinical data, can help the clinicians to optimize the timing for surgical procedure and planning a tailored approach.

This study was undertaken to compare indications, clinical features, ultrasonographic patterns and postoperative outcomes in patients receiving U-VATS decortication for stage II or III pleural empyema.

## MATERIALS AND METHODS

This is a retrospective study using a prospective database of consecutive patients who underwent surgical debridement and decortication for pleural chronic empyema from January 2012 to December 2015 with minimally invasive U-VATS approach.

The preoperative management of pleural empyema in our Unit was in accordance with the British Thoracic Society guidelines [11].

Preoperative diagnostic work-up included complete medical history, blood sample analysis (red cells count, white cells count, serum C-reactive protein and serum procalcitonin), electrocardiogram, emogas-analysis, chest X-ray, chest CT, chest ultrasonography, diagnostic thoracentesis or tube thoracostomy. The surgical decision was made after a multidisciplinary consult in the presence of the following criteria and after failed medical therapy:

1. Persistence of septic status (with or without positive cultures)
2. Chronic or infected pleural fluid (free or septated, with or without gas)
3. Pleural thickening that causes entrapped lung
4. Patient fit for open or VATS surgery.

Patient with complicated parapneumonic effusion had a pleural fluid pH inferior to 7.1, glucose level inferior to 40 mg/dl, LDH greater than three times the normal serum value, multi-loculated effusion (class 4 or 5 of Light's classification); patients with pleural empyema had a positive bacterial culture, frank pus on thoracentesis and/or multi-loculated effusion on CT scan (class 6 or 7).

## Ultrasonographic staging

We performed chest ultrasonography (US) with 3.5–7.5 MHz linear or sector probe twice: in the preoperative period during the decision-making process and in the operating room before surgical incision.

We classified the ultrasonographic appearance in this way, modifying the classification of US patterns of pleural effusion described originally by Yang *et al.* [12] in 1992 and Heffner *et al.* [10] in 2010:

- A. Simple (anechoic)
- B. Complex (containing heterogeneous echogenic material)
- C. Septated with countable loculations
- D. Septated without countable loculations
- E. Homogeneously echogenic with pleural hyper-reflectivity.

These patterns are associated with different stage: classically, stage III empyema shows a sonographic appearance D or E, stage II is associated more frequently with patterns C and D and stage I occurs almost exclusively with A appearance. The 'new pattern D' represents the intermediate stage between hyper-echogenic pleural fluid associated with visceral pleural thickness with fibrous peel (pattern E, empyema stage III) and the presence of fibrinous septa forming multiple loculations with fluid that is characteristic of empyema stage II (Table 1 and Fig. 1).

The comparison between US and CT scan was considered not feasible for the presence of several confounding factors as time (the CT scan was often performed days or weeks before surgery and we decided to not repeat) and professional skills (US was always done by a trained surgeon, not by a radiologist).

The surgical approach was decided based on preferences, attitudes and background of the surgeon and integrated with clinical history and radiological findings. For patients with recent symptoms onset, short antibiotic therapy, ultrasonographic pattern C or D (but not exclusively), surgeons skilled in VATS procedures proposed U-VATS approach, whereas in other cases, we used thoracotomy. To test the feasibility, safety and the outcomes of U-VATS decortication, we compared the data of patients undergoing minimally invasive surgery with those of the patients with thoracotomic access.

## Uniportal thoracoscopic technique

The U-VATS procedure was performed with general anaesthesia and one-lung ventilation using a double-lumen endotracheal tube or bronchial blocker. We used a single incision of 3–4 cm planned according to the ultrasonographic appearance of the pleural space (usually at the seventh or eighth intercostal space in the posterior axillary line) for 5 mm or 10 mm 30° camera and endoscopic and standard instruments. This incision was located in the lowest area of the hemithorax, over the diaphragm (previously identified with US) and this access allowed to reach all regions involved by inflammatory process and also allowed to easily free the diaphragmatic surface of the lower lobe (Fig. 2).

The first phase involved the removal of all adhesions and inflammatory effusion. After complete debridement, the inflammatory peel was separated from the visceral pleura and subpleural lung with a blunt and sharp dissection avoiding important parenchymal injury. The diaphragm was also cleaned up by the typical inflammatory reaction and diaphragmatic surface of the lung was completely freed to restore the diaphragmatic movements. For blunt dissection, we used a handmade long-

**Table 1:** Comparison of classification of pleural effusion according to Yang and Heffner and our classification

Yang 1992 US pleural effusion classification	Our classification
A. Anechoic	A. Anechoic
B. Complex non septated	B. Complex (containing heterogeneous echogenic material)
C. Complex septated	C. Septated with countable loculation
D. Homogeneously echogenic	D. Septated without countable loculation
	E. Homogeneously echogenic with pleural hyper-reflectivity

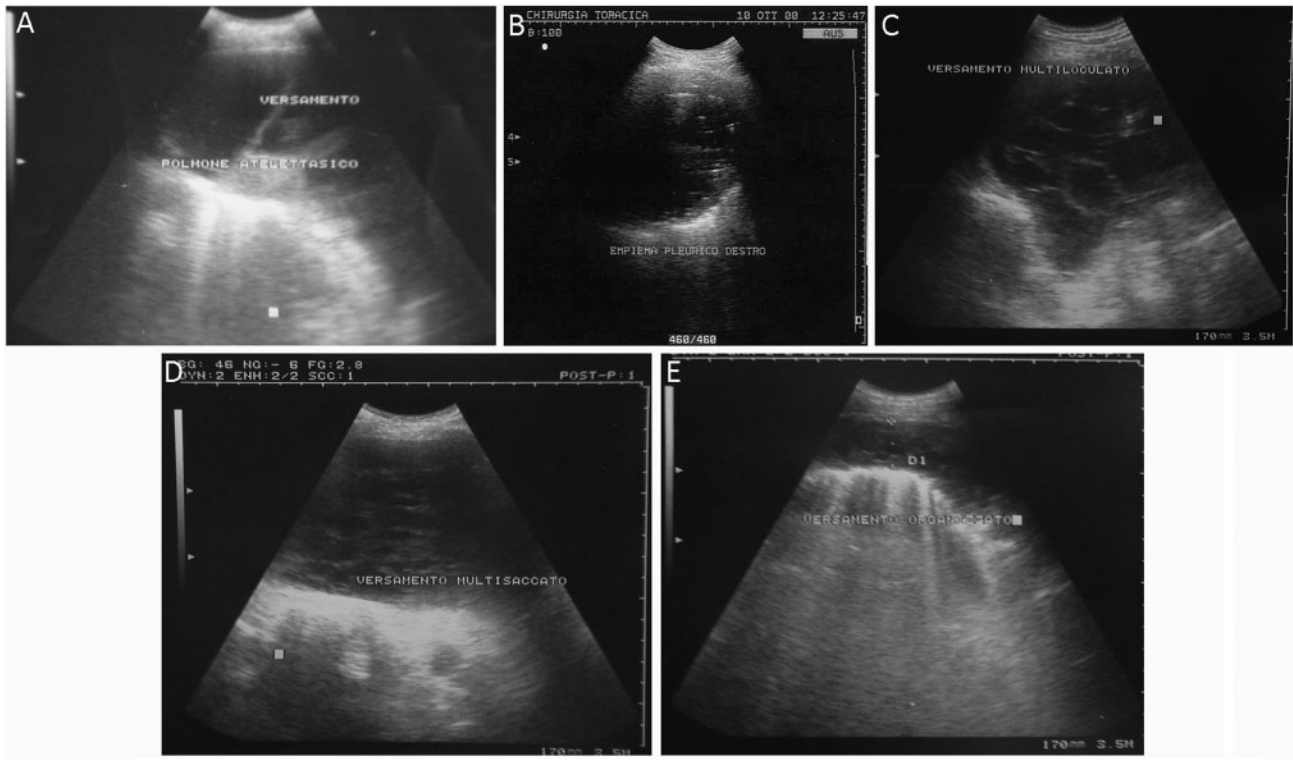


Figure 1: Ultrasonographic patterns of our classification.

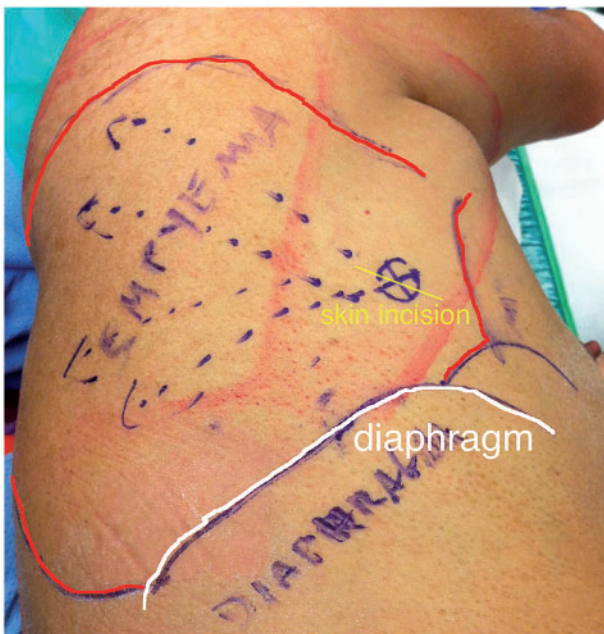


Figure 2: Identification of the operative working space and access with ultrasonography. The white line represents the US position of the diaphragm; the red line is the US distribution of the effusion and the yellow line is the skin incision based on US appearance of pleural space.

angled oval bone curette that allowed excellent removal of visceral peel without causing major parenchymal wound. Bleeding was managed with electrocautery and hot packing. In some cases, we performed lung or pleural biopsies. The procedure ended when we accomplished a full lung re-expansion and

placed two 28F chest tubes under endoscopic vision on diaphragm and at the apex.

Patients were extubated in the operating room and were transferred to our thoracic surgery recovery area for postoperative monitoring. Chest tubes were maintained on  $-20$  cm  $H_2O$  of suction for 36–48 h postoperatively and criteria for removal was absence of air leak, good lung re-expansion, bacterial culture negative and less than 200 ml of drainage in 24 h. Patients were followed with chest X-ray 2 weeks after discharge and monitored regularly clinically and radiologically for 12–24 months.

### Statistical analysis

Statistical analysis was completed with SPSS 16.0 software (SPSS Inc., Chicago, IL), continuous data were expressed as mean and standard deviation and compared with Student's *t*-test, while the Fisher exact test or  $\chi^2$  test were used for difference between proportions. A *P*-value less than 0.05 was considered statistically significant.

### RESULTS

From January 2012 to October 2015, we operated 64 patients affected by pleural empyema in stage II ( $n = 26$ , 40%) and stage III ( $n = 38$ , 60%).

The mean age of the population was  $57.8 \pm 16.4$  years with a high prevalence of men (40/64, 62%). The 34% of patients were affected by predisposing conditions such as chronic obstructive pulmonary disease, alcoholism, diabetes mellitus and chronic heart disease. The most common presenting symptoms were fever (59%), thoracic pain (10%) and dyspnoea (31%). The prevalent cause of pleural empyema was complicated bacterial pneumonia (85%);

other causes were chest trauma and subsequent retained haemothorax (11%) and previous thoracentesis (4%). All patients were treated with broad spectrum antibiotics for  $8.7 \pm 3.7$  days without clinical improvement and chest tube was inserted in 23 patients (35%); no fibrinolytic therapy had been attempted in our series.

Decortication was considered complete by the operating surgeon in all patients.

In our series, there was no in-hospital mortality and overall complication rate was 29%; the most common was bleeding requiring blood transfusions in 9 patients (14%) and re-intervention in 4 (6%). Late recurrence was reported in 2 patients (3%), 1 of whom underwent U-VATS decortication, documented and confirmed with chest-CT scan. These individuals received a second surgery. We also registered 3 prolonged air leaks and 1 respiratory failure that required tracheostomy. Sixty-two patients (96%) were stable at discharge and all of them had an improved lung re-expansion of the affected lung. This condition has remained stable at the first follow-up after decortication and at annual clinical and radiological follow-up.

Dividing patients according to surgical approach, we found 30 patients (46%) who underwent U-VATS debridement and decortication (Group A), while 34 (54%) were operated by thoracotomy (Group B). Demographic and preoperative characteristics are reported on Table 2.

There were no differences in the demographic and clinic-radiological findings (sex, age, comorbidities, symptoms, empyema staging) between the groups.

Comparing intraoperative and postoperative data, we found statistical differences for intraoperative blood loss, postoperative

hospital stay, chest drain duration and postoperative complications (10% vs 47%,  $P < 0.001$ ) as depicted in Table 3. We had three conversions from U-VATS to biportal or triportal VATS decortication (3/30 10%), none from U-VATS to thoracotomy.

Dividing patients according to US preoperative appearance (Table 4), we noted that elevated US pattern (grade E) is strongly associated with thoracotomy ( $n = 16$ , 89% vs  $n = 2$ , 11%;  $P < 0.001$ ) higher estimated blood loss, higher operative time and higher incidence of complications ( $n = 12$ , 19% vs  $n = 7$ , 10%;  $P < 0.001$ ). We found also that conversion rate was strongly associated to elevated ultrasonographic appearance: in fact, only patients with US pleural pattern E underwent conversion.

## DISCUSSION

The objective of surgical treatment of chronic pleural empyema is to drain infected collections from pleural cavity and to achieve a complete lung re-expansion by removal of visceral cortex. Decortication by open thoracotomy or VATS is proven superior to medical treatment for advanced empyema [13]. VATS has been demonstrated to allow effective drainage and removal of loculations of empyema in stage II [14], but its role in phase III (organizing phase) is still debated [3, 14–15]. Decortication is traditionally accomplished via thoracotomy, but VATS has some advantages such as less morbidity related to surgical trauma, better visualization of the entire pleural cavity, and equivalent outcomes in terms of resolution of infection and functional results [3, 6, 16]. In a large retrospective study of 420 patients conducted

**Table 2:** Demographical and clinical data of two groups

Demographic and clinical data	Patients, <i>n</i> = 64	Uniportal-D 30 patients	Open-D 34 patients	<i>P</i> -value
Mean age $\pm$ DS	57.8 $\pm$ 16.4	55 $\pm$ 16	64 $\pm$ 15	0.2
Male, <i>n</i> (%)	40/64 (62)	21 (70)	19 (56)	0.3
Symptoms				
Fever, <i>n</i> (%)	38 (59)	20 (66)	18 (53)	0.5
Dyspnoea, <i>n</i> (%)	20 (31)	8 (26)	12 (35)	
Chest pain, <i>n</i> (%)	6 (10)	2 (7)	4 (12)	
Aetiology				
Pneumonia, <i>n</i> (%)	50 (78)	23 (76)	27 (79)	<0.001
Retained haemothorax, <i>n</i> (%)	7 (11)	0	7 (20)	
Previous thoracentesis / iatrogenic, <i>n</i> (%)	3 (5)	3 (10)	0	
Other, <i>n</i> (%)	4 (6)	4 (13)	0	
Comorbid disease, <i>n</i> (%)	22 (34)	23	44	0.1
Chronic obstructive pulmonary disease (COPD)		1	3	
Heart disease		1	4	
Diabetes mellitus		3	0	
Liver disease		2	2	
Sepsis		0	3	
Other		0	3	
Duration of symptoms	19 $\pm$ 9	13 $\pm$ 4	25 $\pm$ 14	<0.001
Duration of antimicrobial treatment	8.7 $\pm$ 3.7	6.4 $\pm$ 1.8	11 $\pm$ 5.7	<0.001
Stage				
II, <i>n</i> (%)	26 (40)	12 (40)	14 (41)	0.9
III, <i>n</i> (%)	38 (60)	18 (60)	20 (59)	
US pattern				
Septated with countable loculations, <i>n</i> (%)	25 (39)	13 (43)	12 (35)	<0.001
Septated with uncountable loculations, <i>n</i> (%)	19 (30)	13 (43)	6 (18)	
Homogeneously echogenic with pleural hyper-reflectivity, <i>n</i> (%)	20 (31)	4 (14)	16 (47)	

CI: confidence interval; OR: odds ratio.



**Table 3:** Postoperative data of two groups

Postoperative data	Uniportal-D 30 patients	Open-D 34 patients	P-value	CI/(OR)
Operative time (m)	116 ± 28	135 ± 43	0.04	0.27-37.64
Estimated blood loss, ml	118 ± 80	247 ± 140	<0.001	70.52-187.18
Chest tube duration, days	5.6 ± 1.4	10.6 ± 4.2	<0.001	3.32-6.70
Postoperative complication, n (%)	3 (10)	16 (47)	<0.001	0.31-0.71 (0.47)
Hospital stay, days	6.7 ± 1.9	12.2 ± 4.7	<0.001	3.67-7.39

CI: confidence interval; OR: odds ratio.

**Table 4:** Operative and postoperative data associated with US findings

	US pattern E	US pattern C-D	P-value	CI/(OR)
Estimated blood loss (ml)	330 ± 131	130 ± 80	<0.001	-235, 98 to -145, 60
Operative time (min)	142 ± 23	120 ± 40	0.46	-41.81 to 0.34
Thoracotomy, n (%)	16 (89)	2 (11)	<0.001	1.76 to 28.21 (7.05)
Postoperative complication, n (%)	12 (19)	7 (11)	<0.001	1.29 to 4.28 (2.35)

US: ultrasonography; CI: confidence interval; OR: odds ratio.

by Tong *et al.* [5] in 2010, VATS decortication is demonstrated as safe, effective, with functional results comparable to thoracotomy decortication. However, VATS decortication is associated with shorter hospital stay, fewer prolonged air leaks, fewer blood transfusions, fewer postoperative respiratory complications and 30-day mortality, suggesting that it is a reasonable approach for all decortications. In a previous study of 2009, Cardillo *et al.* [7] compared the clinical outcomes of thoracotomy decortication and thoracoscopic decortication demonstrating the latter to be better in terms of postoperative pain, air leaks and hospital stay. Casali *et al.* [8] reported similar results but in addition showed that VATS decortication had higher improvement in subjective dyspnoea. A recent consensus statement by the European Association of Cardio-Thoracic Surgery (EACTS) concluded that VATS has an important role in the management of pleural empyema because of its safety and effectiveness, both in stage II and stage III, but thoracotomy plays a key role for obtaining complete lung re-expansion in presence of pleural thickness and entrapped lung [9].

The last frontier of minimally invasive thoracic surgery is U-VATS approach that causes less and singular intercostal trauma and potentially less postoperative pain and less morbidity. U-VATS is used routinely for the management of recurrent pleural effusions, preoperative staging in lung cancer, treatment of primitive spontaneous pneumothorax, palmar hyperhidrosis and only in experienced hands for anatomic lung resections [17, 18]. Few papers report the use of U-VATS approach for empyema treatment or decortication. In a small series (11 patients), Song *et al.* reported a high conversion rate (55%) due to the difficulties encountered in removing the thickened visceral pleura. For this reason, they used more frequently a three portal conventional VATS approach for removal of fibrous peel [19]. Marra *et al.* [20] developed an original 'hybrid' technique of single access thoracoscopy using a classical video-mediastinoscope to debride the cavity and disrupt all pleural septation. This approach was used

mainly for parapneumonic effusion (stage I) and empyema in fibrino-purulent phase without conversion to thoracotomy and with a low recurrence (6.5%) managed by redo single-VATS and postoperative irrigation through chest tubes or open thoracotomy. In larger experience of U-VATS procedure [17, 21] only a small portion of patients, affected by early stage empyema, were treated with single-port access without complications or mortality. In our report, we explained technical aspects of U-VATS decortication and demonstrated its safety (absence of postoperative mortality, lower morbidity) and its efficacy in terms of disease control (lower rate of recurrence,  $n=1$ , 3%) compared to the standard thoracotomy approach.

U-VATS decortication is a complex and demanding procedure that requires adequate skills and instrumentation because the exploration of the pleural cavity, the removal of adhesions and pleural peel on delicate and infected tissue (with a high bleeding risk) using a single access is very hard, laborious and sometimes tedious. Blunt dissection could be facilitated by angled oval bone curette and peanuts that allow gentle dissection over vulnerable tissue. At the beginning, we had some bleeding caused by less experience, but we found very useful to pack the cavity with a hot large sponge and using electrocautery devices such as bipolar forceps. We had few prolonged air leaks, which may be due to the correct dissection and removal of pleural peel and perhaps to the use of sealants.

In our series, 38 patients (60%) were affected by chronic empyema. Twenty underwent decortication by thoracotomy and 18 by U-VATS. Complete decortication and full lung re-expansion was obtained in all patients. Even in this subgroup, we observed a very low conversion rate and less recurrence, achieving similar functional results and better postoperative outcomes than thoracotomy. Probably, this fact could be related to correct preoperative staging also determined by accurate clinical and radiological assessment. During the diagnostic phase, all patients undergo chest X-ray, CT and ultrasonography (performed by

surgeons); so imaging and medical history can define accurately the empyema stage for a tailored treatment. In our experience, ultrasonography is very sensitive in defining the presence of free fluid (A) or corpuscolated fluid collection (B), loculations, cavities and septa (stages C and D) and also pleural thickness is well related with pleural fluid hyper-echogenicity (E). Our classification differs from Yang and Heffner's system for the presence of a new intermediate pattern, identified by letter D, between hyper-echogenicity of pleural effusion and visceral pleura, specific of stage III and loculations that are associated frequently with stage II. The impossibility to count these loculations may be interpreted by the presence of strong adhesions and significant visceral thickness that entrapped the lung, features proper to third stage. In our series, all patients with US pattern D had empyema in third phase and underwent decortication. We think that this US appearance could be the feature of a transition phase between stages II and III.

Sonographic appearance plays an important role in the diagnostic process, defining accurately the empyema stage, the evolution of pleural space and the timing of surgery or other therapeutic manoeuvres. CT scan remains the gold standard examination for the diagnosis and staging of pleural empyema, but US has several advantages in terms of non-invasiveness (absence of radiation exposure) and immediacy as a real-time visualization of the pleural space.

Also US is useful to plan the approach and the access and may also have prognostic significance. A strong hyper-reflectivity of visceral pleura associated with uncountable loculations forces us to perform decortication. U-VATS approach is used more frequently for US patterns C and D ( $n = 26/30$ , 86%) with few conversions to traditional VATS and no conversions to thoracotomy that is used for chronic empyema in the presence of pattern E ( $n = 16/20$ , 80%). This clearly demonstrated how the integration between the clinical data and ultrasonographical findings allowed a precise identification of the stage and subsequently a tailored surgical approach.

Our study did not show what were the appropriate techniques or findings to identify the various stage of empyema; however, CT loculations, pleural thickness and US hyper-reflectivity were associated with higher stage of empyema.

US was also useful to plan the surgical access to pleural cavity because it well defined the 'working space': with the patient in lateral decubitus, we identified the position of diaphragm, the distribution of effusion, septa and loculations and so we planned the skin incision to obtain a wide range to reach the apex and the diaphragm with a direction from anterior to dorsal region.

US had a fundamental preoperative role for planning the surgical approach but also had a predictive value for delineating patients with a higher risk of postoperative complications: US pattern E and thoracotomic decortication were risk factors for postoperative complications including bleeding, air leaks and respiratory failure. Obviously, we reserved thoracotomy for more advanced disease, and consequently complications were more expected and more frequent.

This study is limited by its retrospective nature in a small series analysed in a short period. Also we did not analyse functional long-term results. Although a randomized prospective trial could clarify debated issues and benefits of VATS, it is not practically feasible.

The primary finding in this study was that the U-VATS approach gave equally effective treatment for empyema even in patients with advanced disease compared with thoracotomy. Both

provided the removal of all loculations and inflammatory visceral peel and allowed complete lung expansion and obliteration of pleural space that are fundamental goals of the surgical management of pleural empyema. U-VATS approach could be an effective and safe alternative in well-selected patients with third-stage empyema with an equivalent incidence of complications and late recurrence.

Secondary ultrasonography was a fundamental tool for properly classify and then apply a targeted approach to chronic pleural empyema, but other studies are necessary to standardize its application and identify its predictive value.

## CONCLUSIONS

Uniportal thoracoscopic decortication for pleural empyema, even in stage III, is a safe and effective approach for well-selected patients based on a combination of clinical and imaging staging. Ultrasonography is a useful and non-invasive tool for identifying empyema stages, for planning the surgical approach and access, and also ultrasonographic patterns well corresponded with intraoperative pleural findings.

**Conflict of interest:** none declared.

## REFERENCES

- [1] Angelillo Mackinlay TA, Lyons GA, Chimondeguy DJ, Piedras MA, Angaromo G, Emery J. VATS debridement versus thoracotomy in the treatment of loculated postpneumonia empyema. *Ann Thorac Surg* 1996;61:1626-30.
- [2] Cassina PC, Hauser M, Hillejan L, Greschuchna D, Stamatis G. Video-assisted thoracoscopy in the treatment of pleural empyema: stage-based management and outcome. *J Thorac CardioVasc Surg* 1999;117:234-8.
- [3] Waller DA, Rengarajan A. Thoracoscopic decortication: a role for video-assisted surgery in chronic postpneumonic pleural empyema. *Ann Thorac Surg* 2001;71:1813-6.
- [4] Cheng YJ, Wu HH, Chou SH, Kao EL. Video-assisted thoracoscopic surgery in the treatment of chronic empyema thoracis. *Surg Today* 2002;32:19-25.
- [5] Tong BC, Hanna J, Toloza EM, Onaitis MW, D'Amico TA, Harpole DH *et al.* Outcomes of video-assisted thoracoscopic decortication. *Ann Thorac Surg* 2010;89:220-5.
- [6] Chan DT, Sihoe AD, Chan S, Tsang DS, Fang B, Lee TW *et al.* Surgical treatment for empyema thoracis: is video-assisted thoracic surgery "better" than thoracotomy? *Ann Thorac Surg* 2007;84:225-31.
- [7] Cardillo G, Carleo F, Carbone L, Di Martino M, Salvadori L, Petrella L *et al.* Chronic post-pneumonic pleural empyema: comparative merits of thoracoscopic versus pen decortication. *Eur J Cardiothorac Surg* 2009;36:914-8.
- [8] Casali C, Storelli ES, Di Prima E, Morandi U. Long-term functional results after surgical treatment of parapneumonic thoracic empyema. *Interact CardioVasc Thorac Surg* 2009;9:74-8.
- [9] Scarci M, Abah U, Solli P, Page A, Waller D, van Schil P *et al.* EACTS expert consensus statement for surgical management of pleural empyema. *Eur J Cardiothorac Surg* 2015;48:642-53.
- [10] Heffner JE, Klein JS, Hampson C. Diagnostic utility and clinical application of imaging for pleural space infections. *Chest* 2010;137:467-79.
- [11] Davies HE, Davies RJO, Davies CWH. Management of pleural infection in adults: British Thoracic Society pleural disease guideline 2010, on behalf of the BTS Pleural Disease Guideline Group. *Thorax* 2010;65 (Suppl 2):41-53.
- [12] Yang PC, Luh KT, Chang DB, Wu HD, Yu CJ, Kuo SH. Value of sonography in determining the nature of pleural effusion: analysis of 320 cases. *AJR* 1992;159:29-33.
- [13] Colice GL, Curtis A, Deslauriers J, Heffner J, Light R, Littenberg B *et al.* Medical and surgical treatment of parapneumonic effusions: an evidence-based guideline. *Chest* 2000;118:1158-71.

- [14] Shahin Y, Duffy J, Beggs D, Black E, Majewski A. Surgical management of primary empyema of the pleural cavity: outcome of 81 patients. *Interact CardioVasc Thorac Surg* 2010;10:565–7.
- [15] Chung JH, Lee SH, Kim KT, Jung JS, Son HS, Sun K. Optimal timing of thoracoscopic drainage and decortication for empyema. *Ann Thorac Surg* 2014;97:224–9.
- [16] Solaini L, Prusciano F, Bagioni P. Video-assisted thoracic surgery in the treatment of pleural empyema. *Surg Endosc* 2007;21:280–4.
- [17] Rocco G, Martucci N, La Manna C, Jones DR, De Luca G, La Rocca A *et al.* Ten-year experience on 644 patients undergoing single-port (uniportal) video-assisted thoracoscopic surgery. *Ann Thorac Surg* 2013;96:434–8.
- [18] Gonfiotti A, Jaus MO, Barale D, Viggiano D, Battisti N, Macchiarini P. Uniportal videothoracoscopic surgery: our indications and limits. *Innovations (Phila)* 2015;10:309–313.
- [19] Song IH, Yum S, Choi W, Cho S, Kim K, Jheon S *et al.* Clinical application of single incision thoracoscopic surgery: early experience of 264 cases. *J Cardiothorac Surg* 2014 8;9:44.
- [20] Marra A, Huenermann C, Bernd R, Ludger H. Management of pleural empyema with single-port video-assisted thoracoscopy. *Innovations (Phila)* 2012;7:338–345.
- [21] Xie D, Wang H, Fei K, Chen C, Zhao D, Zhou X *et al.* Single-port video assisted thoracic surgery in 1063 cases: a single-institution experience. *Eur J Cardiothorac Surg* 2016;49:i31–6.