

## Short Communication

# Low Florbetapir PET Uptake and Normal $A\beta_{1-42}$ Cerebrospinal Fluid in an *APP* Ala713Thr Mutation Carrier

Giuseppe Lombardi<sup>a</sup>, Valeria Berti<sup>a</sup>, Andrea Talla<sup>a</sup>, Silvia Bonifazi<sup>a</sup>, Luca Di Girolamo<sup>a</sup>

View metadata, citation and similar papers at [core.ac.uk](http://core.ac.uk)

brought to you by  CORE  
provided by Florence Research

Alberto Fuppi<sup>a</sup>, Benedetta Nacmias<sup>a</sup> and Sandro Sorbi<sup>b</sup>

<sup>a</sup>Department of Neuroscience, Psychology, Drug Research and Child Health, University of Florence, Florence, Italy

<sup>b</sup>Department of Biomedical, Experimental and Clinical Sciences “Mario Serio”, Nuclear Medicine Unit, University of Florence, Florence, Italy

<sup>c</sup>IRCCS Don Gnocchi, Florence, Italy

<sup>d</sup>Neuroradiology Unit AOU Careggi, Florence, Italy

Handling Associate Editor: Daniela Galimberti

Accepted 31 January 2017

**Abstract.** According to the literature, the *APP* Ala713Thr mutation is associated with Alzheimer's disease and cerebral amyloid angiopathy. We describe a case of dementia clinically compatible with frontotemporal dementia in an *APP* Ala713Thr mutation carrier in which both [<sup>18</sup>F]Florbetapir PET uptake and  $A\beta_{1-42}$  cerebrospinal fluid levels were normal. Further evidences are required to establish if this association is only incidental.

**Keywords:** *APP* Ala713Thr, familial Alzheimer's disease, florbetapir PET, frontotemporal dementia

## INTRODUCTION

The revised National Institute on Aging-Alzheimer's Association (NIA-AA) diagnostic criteria for dementia due to Alzheimer's disease (AD) encourage the use of biomarkers in order to improve AD cases identification [1], and according

to International Working Group-2 (IWG-2) research diagnostic criteria, the diagnosis of AD relies on the presence of a pathophysiological marker [2]. The accuracy of amyloid positron emission tomography (PET) imaging in detecting amyloid- $\beta$  ( $A\beta$ ) plaques has been demonstrated [3], and some authors have found a correlation between low cerebrospinal fluid (CSF)  $A\beta_{1-42}$  levels and a high number of plaques in the brain [4] as well as a high *in vivo* amyloid PET uptake [5]. In the occurrence of an AD causative mutation, the certainty that dementia is caused by AD pathology is increased according

\*Correspondence to: Prof. Benedetta Nacmias, Department of Neuroscience, Psychology, Drug Research and Child Health, University of Florence, Viale Pieraccini 6, 50139 Florence, Italy. Tel.: +39 055 7948910; Fax: +39 0552758265; E-mail: benedetta.nacmias@unifi.it.

to NIA-AA criteria, whereas applying the IWG research criteria, the genetic evidence is compatible to definite AD [6].

Among *APP* mutations, the *APP* Ala713Thr was considered by some authors as a possible non-pathogenic polymorphism [7]; more recently, the variant has been associated with autosomal dominant familial AD (FAD) with cerebrovascular lesions in Calabrian families [8, 9], and no relevant differences in clinical phenotype were found between heterozygous and homozygous patients, according to the definition of dominance [9].

## MATERIAL AND METHODS

A 51-year-old Italian man was admitted to our clinic because of gradual change in behavior and personality, cognitive decline, and urinary incontinence; symptoms started one year before the first visit. Family history included a maternal aunt affected by unspecified early onset dementia (55 years) who died at the age of 75. No other cases of neurodegenerative/vascular dementia were known in the family. The mother died at 76 years because of renal failure in diabetes mellitus, while the father was affected by syphilis and died at the age of 78 years.

Information about health status of his cousins were not available. The patient underwent clinical-neuropsychological assessment and conventional brain magnetic resonance imaging (MRI); subsequently, since the diagnosis was uncertain, supplemental investigations on biomarkers were performed: brain [ $^{18}\text{F}$ ]fluorodeoxyglucose ( $^{18}\text{F}$ )FDG PET, CSF analysis, genetic analysis for frontotemporal dementia (FTD), genetic analysis for FAD and lastly amyloid PET. All exams, except the amyloid PET, were carried out one year after the symptoms onset (baseline); neuropsychological evaluation was performed at baseline and at 6-month follow-up (Table 1), while amyloid PET was made 3 years after the symptoms onset.

The extensive neuropsychological evaluation was conducted with the Mini-Mental State Examination (MMSE) [10] and by tests assessing memory (Rey Auditory Verbal Learning Test [11], Babcock Story Recall Test [12], Digit Span Forward and Backward [13]), attention (Trail Making Test A and B [12]), language (Verbal Fluency [11, 14]), executive functions (Frontal Assessment Battery [15], Stroop Test [16]), visuospatial abilities (Rey-Osterrieth Complex Figure Test [17]), praxia (qualitative evaluation), mood

and behavior (Neuropsychiatric Inventory [18]), and functional performance (Activities of Daily Living Scale [19]). Conventional 1.5 T MRI was performed: the degree of medial temporal lobe atrophy was scored using the Scheltens' visual rating scale [20], the global cortical atrophy was assessed by the Pasquier scale [21], and the vascular burden using the Fazekas scale [22]. The [ $^{18}\text{F}$ ]FDG-PET scan was acquired 30 min after injection of [ $^{18}\text{F}$ ]FDG and the amyloid PET 40 min after injection of [ $^{18}\text{F}$ ]Florbetapir. Both examinations were carried out following the standard national and international guidelines. The PET data were analyzed by two experienced readers in a consensus reading based on visual assessment.

With regards to the genetic analysis, genomic DNA was extracted from peripheral blood leukocytes with standard procedures, by utilizing a QIAcube system (Qiagen, Hilden, Germany). Genetic tests for FTD causative mutations (*MAPT*, *GRN*, *C9orf72*) and then for FAD causative mutations (*PSEN1*, *PSEN2*, and *APP*) were performed following standard protocol [23]. The Apolipoprotein E (ApoE) genotype was determined using PCR and HRM, analyzing the combination of the two single nucleotide polymorphisms (rs429358 and rs7412) on the ApoE gene [24]. Lumbar puncture and CSF collection were carried out according to good clinical practice. CSF sample was analyzed for total-Tau, phospho-Tau, and  $\text{A}\beta_{1-42}$  by commercial enzyme-linked immunosorbent assay (innogenetics ELISA). Cut-off for normal values were: for total-Tau <300 pg/ml, for phospho-Tau <60 pg/ml, and for  $\text{A}\beta_{1-42}$  >600 pg/ml.

## RESULTS

At neurological examination, subcortical reflexes and left hand resting tremor were evident without other extrapyramidal signs. Neuropsychological assessment showed significant apathy, anosognosia, reduced verbal initiative and verbal fluency, long term memory impairment, slight deficit in executive functions, and functional decline (incontinence and self-care deficit). The MMSE score was under the reference norms (21), the Neuropsychiatric Inventory score was relatively high (28) because of auditory delusions, severe apathy, motor and verbal stereotyped behaviors, dietary changes, and excessive daytime sleepiness. The clinical profile was suggestive of early onset dementia in the frontotemporal spectrum.

Table 1

Neuropsychological evaluations (individual test results, in brackets raw data) at different time points: the first evaluation was made after 1-year symptoms onset, the second after 1.5-year symptoms onset

Test	Score at first evaluation	Score at 6-month follow-up	Cut-off
Mini-Mental State Examination	20.97 (21/30)	10.97 (11/30)	<23.8
Frontal Assessment Battery	13.9 (14/18)	8.9 (9/18)	≤14.30
Digit Span Forward	5.96 (6)	3.96 (4)	<4.26
Digit Span Backward	4.02 (4)	not evaluable	<2.65
Key Auditory Verbal Learning Test			
Immediate Recall	18.2 (19/75)	25.2 (26/75)	<28.53
Delayed Recall	0 (0/15)	0 (0/15)	<4.69
Babcock Story Recall Test			
Immediate Recall	(3/28)	not tested	<6
Delayed Recall	(2/28)		<9
Key Osterrieth Complex Figure Test			
Copy	19.25 (19/36)	not tested	<28.88
Delayed Recall	0.25 (2/36)		<9.47
Trail Making Test			
A	(55'')	(50'')	≥96''
B	73'' (110'')/1 Err	not evaluable	≥214 ''/≥3 Err
Stroop Test			
Time Interference Effect	17.5'' (18)	not evaluable	≥36.92
Errors Interference Effect	(0)	not evaluable	≥4.24
Phonemic Word Fluency	6.5 (5)	11.5 (10)	<17.35
Semantic Word Fluency	20.5 (19)	14.5 (13)	<24
Neuropsychiatric Inventory	(28/144)	(40/144)	
Activities of Daily Living Scale	(4/6 preserved)	(3/6 preserved)	

Brain MRI showed diffuse fronto-temporo-parietal atrophy (Pasquier score was 14 and the most affected regions were the fronto-temporals) with bilateral involvement of hippocampus (Scheltens score was 3 on the right side, 2 on the left side), without evident vascular burden (Fazekas score was 1) (Fig. 1a). The MRI pattern was not suggestive for any specific dementia subtype.

Brain [<sup>18</sup>F]FDG PET scan (Fig. 1b) revealed severe bilateral hypometabolism in the anterior prefrontal, anterior cingulate, medial frontal, orbitofrontal cortices, in the hippocampi, amygdala, temporal pole, and caudate nuclei (mainly on the right side). Moderate bilateral hypometabolism in the insula and posterior cingulate cortex was also evident, whereas the metabolism in the posterolateral parietal cortex was preserved. This pattern of predominantly anterior hypometabolism has been interpreted as suggestive of neurodegenerative disease not in the AD spectrum but more likely in the FTD spectrum.

With regards to CSF biomarkers, Aβ<sub>1-42</sub> and phospho-Tau were within the normal range (respectively, 771 pg/ml and 35 pg/ml), whereas total-Tau was slightly increased (354 pg/ml); according to current evidence, these values and their ratios were not suggestive of AD (total Tau/Aβ<sub>1-42</sub> value (0.46) was not suggestive of AD profile according to Duits

et al. [25], phospho-Tau/Aβ<sub>1-42</sub> value (0.045) was not suggestive of AD profile according to Tapiola et al. [26]).

Based on these results and on clinical picture, a diagnosis of behavioral FTD was made.

Genetic analysis for FTD causative mutations (*MAPT*, *GRN*, *C9orf72*) was negative. Because of early onset dementia, genetic analysis for FAD causative mutations was also performed and revealed the occurrence of an *APP* Ala713Thr (g.275329G>A) heterozygous mutation in the presence of ε3/ε3 ApoE genotype.

Lastly, amyloid imaging with [<sup>18</sup>F]Florbetapir PET was performed and no significant amyloid tracer retention was found (Fig. 1c). Three years after disease onset, the clinical picture was characterized by mutism and compulsive behavior, severe impairment of attention and executive functions, apraxic gait, and dysautonomic dysfunctions (sweating, hypersalivation).

According to all the data, an uncertain diagnosis of "frontal variant AD", in the presence of FAD causative mutation and in the absence of amyloid biomarkers, has been assumed. Alternatively, based on the non-genetic biomarkers profile and according to Rasovsky's criteria [27], a clinical diagnosis of possible FTD, behavioral variant, was more likely postulated.

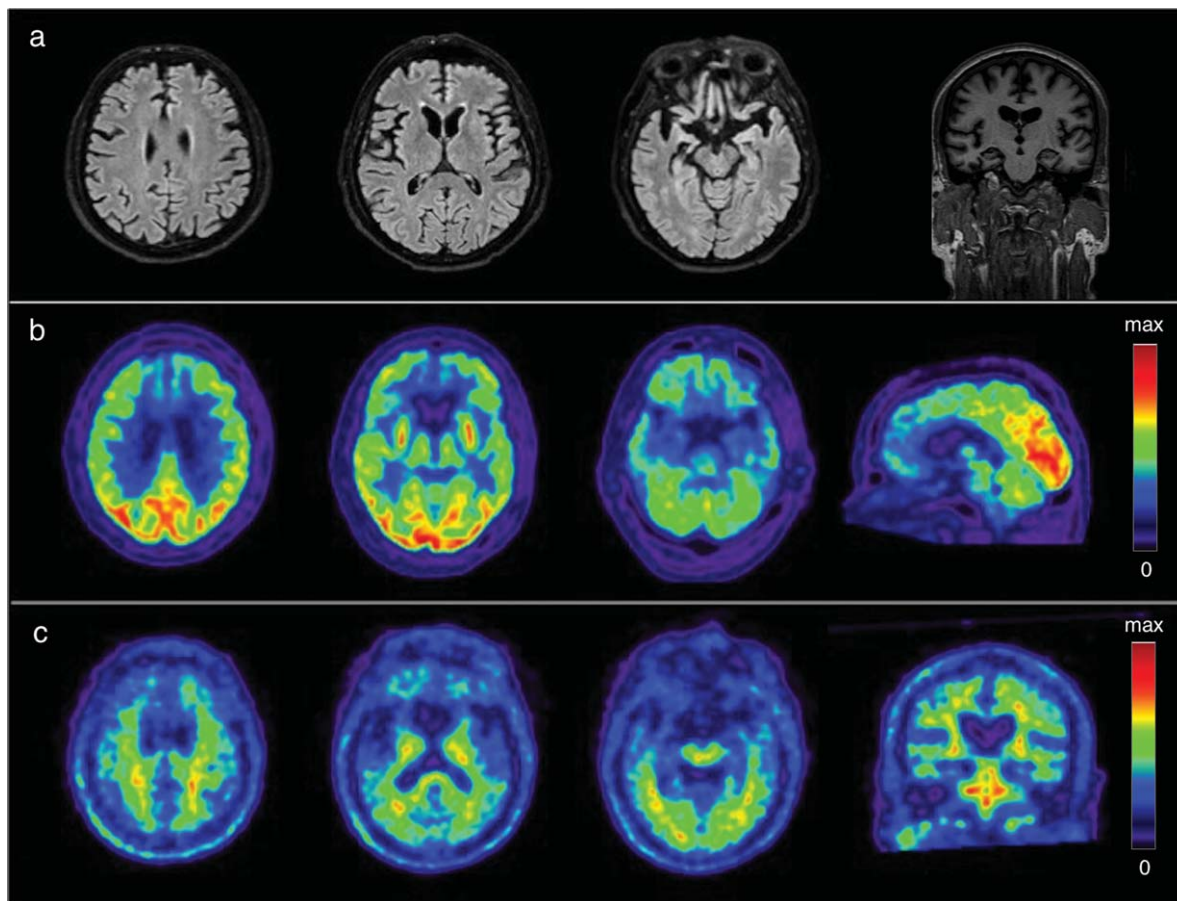


Fig. 1. Neuroimaging data a) MRI, axial T2-weighted fluid-attenuated inversion recovery images and coronal T1-weighted image: no vascular lesions, evidence of cortical and hippocampal atrophy; b) [ $^{18}\text{F}$ ]FDG-PET: severe hypometabolism in frontal lobes, hippocampi and caudate nuclei; c) [ $^{18}\text{F}$ ]Florbetapir PET: no tracer retention in grey matter.

## DISCUSSION

The potential AD pathogenicity of *APP* Ala713Thr (g.275329G>A) variant is confirmed by segregation of the mutation with the disease [8, 9, 28, 29], absence of the mutation in control subjects [8, 9, 28], and results of bioinformatics analysis [30].

This variant is reported in mutation databases as pathogenic (<http://www.molgen.ua.ac.be/ADmutations> [31], <http://www.alzforum.org/mutations> [32], <http://www.hgmd.cf.ac.uk/> [33]); it has been described associated with autosomal dominant FAD, with both early and late onset, and cerebrovascular lesions. Despite these considerations, asymptomatic subjects of heterozygous carriers have been reported [8, 9]; since these cases were mainly younger than 65 years [8] or than the average age at onset of respective affected family members [9], they cannot be considered spared from the disease. Moreover, an

incomplete penetrance of the mutation may be supposed in order to explain this phenomenon, as other genetic or environmental factors could be necessary for the expression/unexpression of AD phenotype [7].

In the present case, the genetic diagnosis was in contrast with the lack of evidence of  $\text{A}\beta$  pathology assessed by both CSF analysis and amyloid imaging. Some cases of negative amyloid PET have been reported in FAD in both Arctic *APP* mutation carriers [34] and *APP* Glu693del mutation carriers [35]; also in rare sporadic cases of disease, [ $^{11}\text{C}$ ]Pittsburgh compound B PET ([ $^{11}\text{C}$ ]PiB PET) failed to show the expected cerebral amyloid burden [36].

PiB binding was found to be associated to certain forms of  $\text{A}\beta$ , such as  $\text{A}\beta\text{N3}$ -pyroglutamate or high-affinity binding sites which might not be present in each amyloid plaque [34]. The absence of [ $^{18}\text{F}$ ]Florbetapir uptake in the present case might

be related to primary structure diversity of A $\beta$  plaque due to a protein-coding mutation.

To support a possible diagnosis of AD, it is assumed that the pathology linked to *APP* mutation starts in the brain first with A $\beta$  accumulation, in a conformation unidentifiable by amyloid PET, and it is later followed by a reduction in CSF A $\beta$ -clearance, presumably not detectable at the time of collection because of not yet started or because of unclassical A $\beta$ -peptides involvement.

Considering previous autoptic findings in *APP* Ala713Thr mutation carriers (relative abundance of A $\beta$ <sub>1-40</sub> deposits compared to A $\beta$ <sub>1-42</sub> [8]) and the supposed pathogenic mechanism of the *APP* Ala713Thr variant (oligomeric toxicity without alteration in A $\beta$  ratio [37]), it is conceivable that CSF A $\beta$ <sub>1-42</sub> value remains in the normal range and that CSF A $\beta$ <sub>1-40</sub> (not evaluated in this case) decreases. This hypothesis is based on the evidence that the reduced A $\beta$ -peptides in CSF match the peptides accumulated in the amyloid plaques [38].

Instead of AD diagnosis, the co-occurrence of an altered A $\beta$  sequence with a FTD phenotype could suggest an association between *APP* Ala713Thr mutation and the FTD pathology. A causative role of *APP* Ala713Thr in pathology different from AD has not been previously supposed, whereas mutation located at the same codon (the *APP* Ala713Val) was found associated to schizophrenia with cognitive deficit [39], suggesting that mutations involving codon 713 can be pleiotropic.

In conclusion, we describe the first case of *APP* Ala713Thr mutation carrier associated to both low [<sup>18</sup>F]Florbetapir PET uptake and normal A $\beta$ <sub>1-42</sub> CSF. It remains to be clarified whether *APP* Ala713Thr mutation is linked to AD without *in vivo* evidence of A $\beta$  biomarkers or more likely to other pathology as FTD, and the debate is unsolvable without histopathological examination. Based on our findings, we suggest that in the occurrence of an AD causative mutation, more than one criterion is necessary for the *in vivo* evidence of AD pathology and that pathophysiological biomarkers should be studied even in carriers of a pathogenic mutation, in order to confirm the genetic diagnosis or, alternatively, to suppose other diagnosis and the relative pathogenic mechanism.

## ACKNOWLEDGMENTS

This study was supported by grants from Italian Ministry of Health RF-2010-2319722 and

Fondazione Cassa di Risparmio di Pistoia e Pescia n. 2014.0365.

Authors' disclosures available online (<http://j-alz.com/manuscript-disclosures/16-1170r1>).

## REFERENCES

- [1] McKhann GM, Knopman DS, Chertkow H, Hyman BT, Jack CR Jr, Kawas CH, Klunk WE, Koroshetz WJ, Manly JJ, Mayeux R, Mohs RC, Morris JC, Rossor MN, Scheltens P, Carrillo MC, Thies B, Weintraub S, Phelps CH (2011) The diagnosis of dementia due to Alzheimer's disease: Recommendations from the National Institute on Aging-Alzheimer's Association workgroups on diagnostic guidelines for Alzheimer's disease. *Alzheimers Dement* **7**, 263-269.
- [2] Dubois B, Feldman HH, Jacova C, Hampel H, Molinuevo JL, Blennow K, DeKosky ST, Gauthier S, Selkoe D, Bateman R, Cappa S, Crutch S, Engelborghs S, Frisoni GB, Fox NC, Galasko D, Habert MO, Jicha GA, Nordberg A, Pasquier F, Rabinovici G, Robert P, Rowe C, Salloway S, Sarazin M, Epelbaum S, de Souza LC, Vellas B, Visser PJ, Schneider L, Stern Y, Scheltens P, Cummings JL (2014) Advancing research diagnostic criteria for Alzheimer's disease: The IWG-2 criteria. *Lancet Neurol* **13**, 614-629.
- [3] Herholz K, Ebmeier K (2011) Clinical amyloid imaging in Alzheimer's disease. *Lancet Neurol* **10**, 667-670.
- [4] Strozzyk D, Blennow K, White LR, Launer LJ (2003) CSF Abeta 42 levels correlate with amyloid-neuropathology in a population-based autopsy study. *Neurology* **60**, 652-656.
- [5] Fagan AM, Mintun MA, Mach RH, Lee SY, Dence CS, Shah AR, LaRossa GN, Spinner ML, Klunk WE, Mathis CA, DeKosky ST, Morris JC, Holtzman DM (2006) Inverse relation between *in vivo* amyloid imaging load and cerebrospinal fluid Abeta42 in humans. *Ann Neurol* **59**, 512-519.
- [6] Dubois B, Feldman HH, Jacova C, Steven T, DeKosky ST, Barberger-Gateau P, Cummings J, Delacourte A, Galasko D, Gauthier S, Jicha G, Meguro K, O'Brien J, Pasquier F, Robert P, Rossor M, Salloway S, Stern Y, Visser PJ, Scheltens P (2007) Research criteria for the diagnosis of Alzheimer's disease: Revising the NINCDS-ADRDA criteria. *Lancet Neurol* **6**, 734-746.
- [7] Carter DA, Desmarais E, Bellis M, Campion D, Clerget-Darpoux F, Brice A, Agid Y, Jaillard-Serradit A, Mallet J (1992) More missense in amyloid gene. *Nat Genet* **2**, 255-256.
- [8] Rossi G, Giaccone G, Maletta R, Morbin M, Capobianco R, Mangieri M, Giovagnoli AR, Bizzi A, Tomaino C, Perri M, Di Natale M, Tagliavini F, Bugiani O, Bruni AC (2004) A family with Alzheimer disease and strokes associated with A713T mutation of the *APP* gene. *Neurology* **63**, 910-912.
- [9] Conidi ME, Bernardi L, Puccio G, Smirne N, Muraca MG, Curcio SA, Colao R, Piscopo P, Gallo M, Anfossi M, Frangipane F, Clodomiro A, Mirabelli M, Vasso F, Cupidi C, Torchia G, Di Lorenzo R, Mandich P, Confaloni A, Maletta RG, Bruni AC (2015) Homozygous carriers of *APP* A713T mutation in an autosomal dominant Alzheimer disease family. *Neurology* **84**, 2266-2273.
- [10] Measso G, Cavarzeran F, Zappalà G, Lebowitz BD, Crook TH, Pirozzolo FJ, Amaducci LA, Massari D, Grigoletto

- F (1993) The Mini-Mental State Examination: Normative study on an Italian Random Sample. *Dev Neuropsychol* **9**, 77-95.
- [11] Carlesimo GA, Caltagirone C, Gainotti G (1996) The Mental Deterioration Battery: Normative data, diagnostic reliability and qualitative analyses of cognitive impairment. The Group for the Standardization of the Mental Deterioration Battery. *Eur Neurol* **36**, 378-384.
- [12] Mondini S, Mapelli D, Vestri A, Arcara G, Bisiacchi PS (2011) Esame neuropsicologico Breve 2, Raffaello Cortina Editore.
- [13] Monaco M, Costa A, Caltagirone C, Carlesimo GA (2013) Forward and backward span for verbal and visuo-spatial data: Standardization and normative data from an Italian adult population. *Neurol Sci* **34**, 749-754.
- [14] Novelli G, Papagno C, Capitani E, Laiacona M, Vallar G, Cappa SF (1986) Tre test clinici di ricerca e produzione lessicale. Taratura su soggetti normali. *Arch Psicol Neurol Psichiatria* **4**, 477-506.
- [15] Appollonio I, Leone M, Isella V, Piamarta F, Consoli T, Villa ML, Forapani E, Russo A, Nichelli P (2005) The Frontal Assessment Battery (FAB): Normative values in an Italian population sample. *Neurol Sci* **26**, 108-116.
- [16] Caffarra P, Vezzadini G, Dieci F, Zonato A, Venneri A (2002) Una versione abbreviata del test di Stroop: Dati normativi nella popolazione italiana. *Nuova Riv Neurol* **12**, 111-115.
- [17] Caffarra P, Vezzadini G, Dieci F, Zonato F, Venneri A (2002) Rey-Osterrieth complex figure: Normative values in an Italian population sample. *Neurol Sci* **22**, 443-447.
- [18] Kaufer DI, Cummings JL, Ketchel P, Smith V, MacMillan A, Shelley T, Lopez OL, DeKosky ST (2000) Validation of the NPI-Q, a brief clinical form of the Neuropsychiatric Inventory. *J Neuropsychiatry Clin Neurosci* **12**, 233-239.
- [19] Katz S, Ford AB, Moskowitz RW, Jackson BA, Jaffe MW (1963) Studies of illness in the aged. The index of ADL: A standardized measure of biological and psychosocial function. *JAMA* **185**, 914-919.
- [20] Scheltens P, Barkhof F, Leys D, Pruvo JP, Nauta JJ, Vermersch P, Steinling M, Valk J (1992) Atrophy of medial temporal lobes on MRI in "probable" Alzheimer's disease and normal ageing: Diagnostic value and neuropsychological correlates. *J Neurol Neurosurg Psychiatry* **55**, 967-972.
- [21] Pasquier F, Leys D, Weerts JGE, Mounier-Vehier F, Barkhof F, Scheltens P (1996) Inter- and intraobserver reproducibility of cerebral atrophy assessment on MRI scans with hemispheric infarcts. *Eur Neurol* **36**, 268-272.
- [22] Fazekas F, Chawluk JB, Alavi A, Hurtung HI, Zimmerman RA (1987) MR signal abnormalities at 1.5 T in Alzheimer's dementia and normal aging. *Am J Roentgenol* **149**, 351-356.
- [23] Nacmias B, Piaceri I, Bagnoli S, Tedde A, Piacentini S, Sorbi S (2014) Genetics of Alzheimer's disease and frontotemporal dementia. *Curr Mol Med* **14**, 993-1000.
- [24] Zhan XH, Zha GC, Jiao JW, Yang LY, Zhan XF, Chen JT, Xie DD, Eyi UM, Matesa RA, Obono MM, Ehapo CS, Wei EJ, Zheng YZ, Yang H, Lin M (2015) Rapid identification of apolipoprotein E genotypes by high-resolution melting analysis in Chinese Han and African Fang populations. *Exp Ther Med* **9**, 469-475.
- [25] Duits FH, Teunissen CE, Bouwman FH, Visser PJ, Mattsson N, Zetterberg H, Blennow K, Hansson O, Minthon L, Andreasen N, Marcusson J, Wallin A, Rikkert MO, Tsolaki M, Parnetti L, Herukka SK, Hampel H, De Leon MJ, Schröder J, Aarsland D, Blankenstein MA, Scheltens P, van der Flier WM (2014) The cerebrospinal fluid "Alzheimer profile": Easily said, but what does it mean? *Alzheimers Dement* **10**, 713-723.
- [26] Tapiola T, Alafuzoff I, Herukka SK, Parkkinen L, Hartikainen P, Soininen H, Pirttilä T (2009) Cerebrospinal fluid  $\beta$ -amyloid 42 and tau proteins as biomarkers of Alzheimer-type pathologic changes in the brain. *Arch Neurol* **66**, 382-389.
- [27] Rascovsky K, Hodges JR, Knopman D, Mendez MF, Kramer JH, Neuhaus J, van Swieten JC, Seelaar H, Dopper EG, Onyike CU, Hillis AE, Josephs KA, Boeve BF, Kertesz A, Seeley WW, Rankin KP, Johnson JK, Gorno-Tempini ML, Rosen H, Prioleau-Latham CE, Lee A, Kipps CM, Lillo P, Piguet O, Rohrer JD, Rossor MN, Warren JD, Fox NC, Galasko D, Salmon DP, Black SE, Mesulam M, Weintraub S, Dickerson BC, Diehl-Schmid J, Pasquier F, Deramecourt V, Lebert F, Pijnenburg Y, Chow TW, Manes F, Grafman J, Cappa SF, Freedman M, Grossman M, Miller BL (2011) Sensitivity of revised diagnostic criteria for the behavioural variant of frontotemporal dementia. *Brain* **134**, 2456-2477.
- [28] Giaccone G, Rossi G, Morbin M, Tagliavini F, Bugiani O, Bruni A (2002) A713T mutation of APP gene in an Italian family with Alzheimer disease and severe congophilic angiopathy. *Neurobiol Aging* **23**(Supp 1), 320.
- [29] Bernardi L, Geracitano S, Colao R, Puccio G, Gallo M, Anfossi M, Frangipane F, Curcio SAM, Mirabelli M, Tomaino C, Vasso F, Smirne N, Maletta R, Bruni AC (2009) A $\beta$ PP A713T mutation in late onset Alzheimer's disease with cerebrovascular lesions. *J Alzheimers Dis* **17**, 383-389.
- [30] Guerreiro RJ, Baquero M, Blesa R, Boada M, Brás JM, Bullido MJ, Calado A, Crook R, Ferreira C, Frank A, Gómez-Isla T, Hernández I, Lleó A, Machado A, Martínez-Lage P, Masdeu J, Molina-Porcel L, Molinuevo JL, Pastor P, Pérez-Tur J, Relvas R, Oliveira CR, Ribeiro MH, Rogaeva E, Sa A, Samaranch L, Sánchez-Valle R, Santana I, Tárrega F, Singleton A, Hardy J, Clarimón J (2010) Genetic screening of Alzheimer's disease genes in Iberian and African samples yields novel mutations in presenilins and APP. *Neurobiol Aging* **31**, 725-731.
- [31] Cruts M, Theuns J, Van Broeckhoven C (2012) Locus-specific mutation databases for neurodegenerative brain diseases. *Hum Mutat* **33**, 1340-1344.
- [32] Kinoshita J, Clark T (2007) Alzforum. *Methods Mol Biol* **401**, 365-381.
- [33] Stenson PD, Mort M, Ball EV, Shaw K, Phillips A, Cooper DN (2014) The Human Gene Mutation Database: Building a comprehensive mutation repository for clinical and molecular genetics, diagnostic testing and personalized genomic medicine. *Hum Genet* **133**, 1-9.
- [34] Schöll M, Wall A, Thordardottir S, Ferreira D, Bogdanovic N, Långström B, Almkvist O, Graff C, Nordberg A (2012) Low PiB PET retention in presence of pathologic CSF biomarkers in Arctic APP mutation carriers. *Neurology* **79**, 229-236.
- [35] Tomiyama T, Nagata T, Shimada H, Teraoka R, Fukushima A, Kanemitsu H, Takuma H, Kuwano R, Imagawa M, Ataka S, Wada Y, Yoshioka E, Nishizaki T, Watanabe Y, Mori H (2008) A new amyloid variant favoring oligomerization in Alzheimer's-type dementia. *Ann Neurol* **63**, 377-387.

- [36] Cairns NJ, Ikonovic MD, Benzinger T, Storandt M, Fagan AM, Shah AR, Reinwald LT, Carter D, Felton A, Holtzman DM, Mintun MA, Klunk WE, Morris JC (2009) Absence of Pittsburgh compound B Detection of cerebral amyloid beta in a patient with clinical, cognitive, and cerebrospinal fluid markers of Alzheimer's disease. *Arch Neurol* **66**, 1557-1562.
- [37] Armstrong J, Boada M, Rey MJ, Vidal N, Ferrer I (2004) Familial Alzheimer disease associated with A713T mutation in APP. *Neurosci Lett* **370**, 241-243.
- [38] Catania M, Di Fede G, Tonoli E, Benussi L, Pasquali C, Giaccone G, Maderna E, Ghidoni R, Tagliavini F (2015) Mirror image of the amyloid- $\beta$  species in cerebrospinal fluid and cerebral amyloid in Alzheimer's disease. *J Alzheimers Dis* **47**, 877-881.
- [39] Jones CT, Morris S, Yates CM, Moffoot A, Sharpe C, Brock DJH, St. Clair D (1992) Mutation in codon 713 of the beta amyloid precursor protein gene presenting with schizophrenia. *Nat Genet* **1**, 306-309.

AUTHOR COPY