



UNIVERSITÀ
DEGLI STUDI
FIRENZE

FLORE

Repository istituzionale dell'Università degli Studi di Firenze

Effects of orbicularis oculi flap anchorage on the lower eyelid position in trans-cutaneous blepharoplasty. Statistical analysis of clinical

Questa è la Versione finale referata (Post print/Accepted manuscript) della seguente pubblicazione:

Original Citation:

Effects of orbicularis oculi flap anchorage on the lower eyelid position in trans-cutaneous blepharoplasty. Statistical analysis of clinical outcome / Innocenti, Alessandro; Mori, Francesco; Melita, Dario; Dreassi, Emanuela; Innocenti, Marco. - In: JOURNAL OF PLASTIC, RECONSTRUCTIVE & AESTHETIC SURGERY. - ISSN 1748-6815. - ELETTRONICO. - 70(2017), pp. 385-391. [10.1016/j.bjps.2016.10.019]

Availability:

This version is available at: 2158/1060394 since: 2017-02-25T10:16:56Z

Published version:

DOI: 10.1016/j.bjps.2016.10.019

Terms of use:

Open Access

La pubblicazione è resa disponibile sotto le norme e i termini della licenza di deposito, secondo quanto stabilito dalla Policy per l'accesso aperto dell'Università degli Studi di Firenze (<https://www.sba.unifi.it/upload/policy-oa-2016-1.pdf>)

Publisher copyright claim:

(Article begins on next page)

Accepted Manuscript

Effects of orbicularis oculi flap anchorage to the periosteum of the upper orbital rim on the lower eyelid position after transcutaneous blepharoplasty. Statistical analysis of clinical outcomes

Alessandro Innocenti, Francesco Mori, Dario Melita, Emanuela Dreassi, Marco Innocenti

PII: S1748-6815(16)30480-6

DOI: [10.1016/j.bjps.2016.10.019](https://doi.org/10.1016/j.bjps.2016.10.019)

Reference: PRAS 5147

To appear in: *Journal of Plastic, Reconstructive & Aesthetic Surgery*


Received Date: 16 July 2016

Revised Date: 27 September 2016

Accepted Date: 27 October 2016

Please cite this article as: Innocenti A, Mori F, Melita D, Dreassi E, Innocenti M, Effects of orbicularis oculi flap anchorage to the periosteum of the upper orbital rim on the lower eyelid position after transcutaneous blepharoplasty. Statistical analysis of clinical outcomes, *British Journal of Plastic Surgery* (2016), doi: 10.1016/j.bjps.2016.10.019.

This is a PDF file of an unedited manuscript that has been accepted for publication. As a service to our customers we are providing this early version of the manuscript. The manuscript will undergo copyediting, typesetting, and review of the resulting proof before it is published in its final form. Please note that during the production process errors may be discovered which could affect the content, and all legal disclaimers that apply to the journal pertain.



Effects of orbicularis oculi flap anchorage to the periosteum of the upper orbital rim on the lower eyelid position after transcutaneous blepharoplasty. Statistical analysis of clinical outcomes.

Alessandro Innocenti*, Francesco Mori*, Dario Melita*, Emanuela Dreassi, Marco Innocenti***

*Plastic and Reconstructive Microsurgery - Careggi Universital Hospital - Florence- Italy

**Dept. Statistica, Informatica, Applicazioni "G.Parenti" DiSIA -University of Florence - Italy

Corresponding author

Alessandro Innocenti

mail innocentialessandro@alice.it

mobile +393356556335

Viale Giacomo Matteotti 42 - 50132 - Firenze Italia

Abstract

Background: The aging process affects skin, muscle, fat of the eyes in a different manner. Their individual rejuvenation would require specific surgical treatment according to their particular demands. The authors analyzed the effect of an orbicularis oculi muscle flap fixed to the superior orbital rim to prevent lower eyelid dislocation during transcutaneous blepharoplasty.

Methods: The study was conducted retrospectively comparing pre and post op images of two different groups of patients: group A (20 patients) treated with orbicularis oculi flap and group B (17 patients) without. Pre and post op distance between the center of the pupil and the upper border of the lower lid at the middle pupil line was measured in each photo and then compared and statistically analyzed.

Results: The mean age of the 37 patients was 57 years old. From the estimated Linear Mixed Model, we observe a significant effect of the presence of the flap (p -value < 0.0001). All the patients treated with the orbicularis oculi flap (group A) showed a cranial movement of the lower eyelid, even though minimally. All patients treated without muscle flap (Group B) showed a caudal movement of the lower eyelid. The 47% of eyes in group B showed a positive variation greater than 10 %.

Conclusion: The study suggests that the anchorage of the orbicularis muscle flap to the upper orbital rim reinforces the lower eyelid's anterior lamellae. It works efficiently to stabilize lower eyelid position after transcutaneous blepharoplasty confirming clinical results, improving surgical outcomes even in patients with minimal or no eyelid laxity .

Introduction

The aging process involves the orbital region affecting skin, muscle, fat and bone in a different manner, giving a tired and sad look.¹⁻³ To optimize their rejuvenation, these different structures would require individual and specific surgical treatment according to their particular demands during blepharoplasty.⁴ This requires the separate management of the skin from the muscle, splitting them in two different flaps. The weakness of the anterior lamellae, resulting from this separation, may produce an unnatural appearance such as round eyes or results in major complications such as ectropion. The aim of this retrospective study is to evaluate the efficacy of the orbicularis oculi muscle flap fixed prophylactically to the periosteum of the superior orbital rim to contrast the natural tendency of the lower eyelid to move downwards after transcutaneous blepharoplasty. This procedure reinforces the lower eyelid's anterior lamellae and stabilizes the lower eyelid position in transcutaneous blepharoplasty, maintaining its original location and improving surgical outcomes even in patients with minimal or no eyelid laxity.

Materials and Methods

This study was conducted retrospectively comparing pre and post operative photos collected from 37 consecutive patients (74 eyes), who underwent primary bilateral lower and upper blepharoplasty between January 2013 and December 2014. The patients were divided in two different groups: A) 20 patients underwent blepharoplasty with orbicularis oculi muscle flap fixation to the upper orbital rim; B) 17 patients without muscular flap anchorage. All the surgical procedures were conducted by a single senior surgeon. Demographic information including age, gender, medical history and surgical information were collected. All the patients underwent local physical examination preoperatively by the senior author. The laxity of the lower eyelid was

evaluated by snap-back and distraction tests. Snap-back test was performed in pulling downward the lower lid. The eyelid which returned to its baseline position quickly and without blinking was considered normal.⁵ Distraction test was performed by pinching forwards the lower eyelid from the anterior surface of the globe. It was considered abnormal when greater than 6 mm.⁶ Both groups A and B enrolled only patients with minimal or no eyelid laxity, without significant differences among the two groups. Patients belonged to the group B underwent surgery without muscular flap anchorage because they required a more conservative approach basing on personal preferences. Since there was no significant differences between the two groups of patients in demographic data, including eyelid laxity, group B was considered as control group.

Exclusion criteria included: history of dry eye, abnormal snap and distraction tests, patients requiring cantopexy or canthoplasty, and previous eyelid or eyebrow surgical procedures. As elucidated by numerous surgeons, cheek-lower lid soft tissue augmentation provides support to the lower eyelid. For this reason, patients who required tear trough correction by fat transplantation or fat bags translocation were also excluded.⁷ Patients with pre or post op images not matching established standards were also excluded.

All the pre and post operative photos were collected in standard condition by the senior author both for head position, primary position gaze, sitting support, digital camera, camera position and light conditions. Post operative follow up included photos collected at 1, 3, 6 and 12 months post operation as is standard in author's practice. However the study focused exclusively on the 12 months post operative comparison, considered the definite result.

Pre and post operative photos of the two groups of patients were used to measure the Marginal Reflex Index 2 (MRD2) namely the distance between the center of the pupil and the upper border of the lower eyelid at the middle pupillary line. The variations of lower eyelid position was

calculated and compared pre and post operatively for every single eye (Fig. 1). The resulting variations for each eye in the two groups of patients were successively compared and the data statistically analyzed.

Analysis of all the collected digital images was performed by three different plastic surgery residents using an agreed standardized technique. Pre operative and post operative photos were organized in two separate grading packets and raters were blinded to pre and post operative status of the subject. At all times the clinicians were unaware of each others' results. Photoshop (Adobe Systems Inc, San Jose, California) was used to measure in pixel the White-to-White Corneal Diameter (white-to-white: WTW) and the distance between the center of the pupil and the upper border of the lower eyelid (MRD2) at the middle pupillary line. WTW was used for standardization of the scale because its value is unchanged by blepharoplasty.³ The ratio (R) of the values of MRD2/WTW was used to compensate for differences in scale inherent in photography; therefore the R reflects a "calculated" MRD2.⁸ R was collected from all 74 eyes. It was averaged between the 3 different values collected by the 3 clinicians and then compared pre (R1) and post (R2) operatively to evaluate the efficacy of the muscular flap in preserving lower eyelid position after transcutaneous blepharoplasty. For an easier interpretation of the results and to compare the two different groups the relative variation of the position of the lower eyelid (RV) in each eye has been adopted. It was calculated as $RV=(R2-R1)/R1$. The analyses of the results in the study was based on this data.

Statistical methods

For the statistical evaluation of the results a Linear Mixed Model⁹ (LMM) was adopted. It summarized the relation between the average of RV and some variables which may influence it. LMM considers both random effects (different patients) and fixed effects: the different

measurement process of the three clinicians, age of patients (divided in three separate classes: less than 50, between 50 and 60, more than 60 years old), gender, left or right eye and the presence/absence of the flap. The presence or absence of the flap represents the main effect we are interested in. The statistical appropriateness of the LMM was verified.

Surgical technique

All the procedures were performed consecutively by the same Senior Author during the indicated period, in a standard way based on the same protocol of anesthesia (Carbocaine 2% + adrenaline 1:200.000), through a standard surgical planning. After upper blepharoplasty, a sub-ciliary transcutaneous incision approached the lower eyelid, harvesting a skin and a muscle flap separately. In the upper lateral part of the orbicularis oculi muscle flap, a triangular flap was cut using a Colorado needle in 20 patients (40 eyes) sec. Reidy Adamson technique.¹⁰ (Fig. 2) Subsequently the flap was passed beneath a para-lateral-canthal tunnel reaching the upper eyelid where it was fixed at the periosteum of the upper lateral orbital rim, immediately above the Whitnall tubercle, using a 5/0 polyglyconate monofilament absorbable suture. No tension was applied. In the remaining 17 cases no muscular flap was performed. After muscle fixation, the skin was gently laid over the repositioned orbicularis muscle and the excess was removed conservatively. The quantity of skin removal ranging from 1.3 mm up to 4.3 mm. The skin was then sutured with separated 5/0 silk stitches. The same medical dressing with 2 patches was applied to support the lower eyelid. No tarsorrhaphy was performed at all.

Results

The mean age of the 37 patients (8 men and 29 women) was 57 years old, ranging from 38 to 67 years old. The presence/absence of the flap seems to be the only factor that explains the

variability on the relative variation (RV). From descriptive statistical analysis, it turns out that the presence of the flap is protective in maintaining lower eyelid position after transcutaneous blepharoplasty. Fig 3 describes the boxplot of the response variable over the four considered fixed factors for the 222 values on 37 patients. The difference between the 3 clinicians measurement (p-value is 0.4005) did not result statistically significant. Patients' gender (p-value is 0.8742) and left/right eye (p-value is 0.0557) did not result statistically significant either. Once all fixed effects are considered, the difference between patients (the inclusion of random effects) explains the 82% of the residual variability.

In each one of the 40 eyes in group A the mean RV of the position of the lower eyelid, considering the average measurements collected by the three different clinicians (120 measurements), ranged from - 32.1% to - 1,7% with an average of - 9.23 % . This negative variation means a decrease of MRD2, namely an upwards movement of the lower eyelid according to the clinical favorable rejuvenation result.⁷ Since the variation was calculated as ratio between MRD2/WTW, and in European population the mean dimension of WTW was reported in 11.71 mm, the MRD2 variation observed in group A can be reported in mm.¹¹ The number of eyes with mean RV less than 5% (< 0,3 mm) are 11 (27.5%); between 5% and 10% (0.3 - 0.6 mm) are 21 (52.5%); greater than 10% (> 0.6mm) are 8 (20%). The results evince that the average variation of lower eyelid upwards position after muscle flap fixation was 0,55 mm and even if minimal, it improves clinical satisfactory rejuvenation results.

In each one of the 34 eyes in group B the mean RV of the position of the lower eyelid, considering the average measurements collected by the three different clinicians (102 measurements), ranged from 0.3 % to 34.1% with an average of 10.79 %. This positive variation means an increase of MRD2 namely a downwards movement of the lower eyelid with an unnatural and unfavorable

clinical appearance. The eyes with mean RV less than 5% (<0.3 mm) are 10 (29.5%); between 5% and 10% (0.3 -0.6 mm) are 8 (23.5%); greater than 10% (>0.6 mm) are 16 (47%). The results indicate that the average variation of lower eyelid position without muscle flap fixation was 0,65 mm. A downward displacement of the lower eyelid after transcutaneous blepharoplasty, even if minimal, results in unsatisfactory outcomes and it appears in the majority of the cases treated without muscular flap fixation.

From the estimated LMM, we observe a significant effect of the presence of the flap (p -value < 0.0001). The majority of eyes (52.5%) treated with orbicularis oculi flap (group A) showed a minimal variation in lower eyelid position ranged between 5-10 % namely 0.3 - 0.6 mm; while 47% of eyes without orbicularis oculi flap (group B) showed a positive variation greater than 10 % namely greater than 0.6 mm. It means that the orbicularis oculi flap works efficiently in conserving lower eyelid position after transcutaneous blepharoplasty.

In group A the main operative time was 53 minutes (ranging 45 - 60 minutes) while in group B it was 42 minutes (ranging 40- 50 minutes).

Discussion

The orbital aging process involves with different modalities the skin of the eyelid, the orbicularis oculi muscle, the orbital fat and the orbital bone. The skin becomes inelastic and wrinkled, the orbicularis muscle loses tone, extends vertically becoming ptotic. The orbital fat herniates, delineating the orbital fat bags. The suspension ligament becomes relaxed and the lower eyelid contour changes in shape. The modifications of the orbital bone has not been focused on in this study.

To optimize their rejuvenation during blepharoplasty, these different structures would require individual and specific surgical treatment according to their particular demands.⁴ The skin must be smoothed and eventually reduced. The muscle must be reinforced, re-tensioned and lifted, the fat must be conservatively removed while the suspension structure must be re-tensioned. This would require the separate management of the skin and the muscle separating them in two different flaps. The weakness of the anterior lamellae, resulting from this method, may produce unnatural round-eye appearance due to lower eyelid dislocation. Skin flaps, especially if very thin, have an increased risk of skin necrosis and may retract dangerously. The setup of a muscle flap further weakens the anterior lamella, increasing the risk of lower lid dislocation, scleral show or ectropion. A muscular - cutaneous flap, not separating the skin from the muscle, does not fully allow to resolve their respective demands. On the other hand, the trans-conjunctival approach to manage the orbital fat respects the muscular structure, resulting more conservative, but does not allow muscle remodeling.¹²⁻¹⁶ Although the merits of transcutaneous versus trans-conjunctival blepharoplasty are widely debated in the literature, we retain that the transcutaneous approach maximizes the cosmetic outcomes even if it may result more aggressive.

All the patients treated with the orbicularis oculi flap reported an upwards elevation of the lower eyelid. The majority of them (52.5%) showed MRD2 reduction ranging between 0.3 and 0.6 mm. These variations can be considered minimal with minor movement of the lower eyelid. It means that the orbicularis oculi flap works efficiently in conserving its original position, producing a natural rejuvenation due to a slight lower eyelid elevation.⁷ According to clinical results, all the patients treated without the anchorage of the flap reported a wider increase of MRD2. As shown in 47% of the cases the variation was greater than 0.6 mm.

According to the literature some sort of canthal support represents a fundamental step in transcutaneous blepharoplasty. Canthopexy and canthoplasty are procedures that involve directly the lateral canthus ligaments or the lateral canthal tendon.¹⁷ Orbicularis oculi flap provides support to the lower eyelid directly, avoiding surgery on the complex anatomy of the lateral canthus itself. During orbicularis oculi flap anchorage, neither the canthal ligament nor the canthal tendon are involved in the fixation. The muscle flap is passed through the para-lateral-canthal tunnel and fixed to the periosteum of the upper orbital rim, supporting directly the anterior lamellae. Although the orbicularis oculi muscle flap fixation avoids surgery around the lateral canthus, may not be suitable for cases without a need for a skin incision or previous history of dry eye. Canthopexy and canthoplasty have both significant effects on eyelid contour, tension and shape, moving upward and laterally the position of the lateral canthus which typically migrates postoperatively toward the preoperative position.¹⁸

As reported by Hidalgo DA, patients in group A, treated with muscle flap, showed prolonged post operative edema than patients in group B.¹⁹ However, in our experience the edema resolved spontaneously within 3 weeks in all patients.

Limitations of this study include its retrospective nature, inherent variability of patients' photos and subsequent measurement of lower eyelid position and inter-rater variability. Unless head posture and camera position are both standardized, photographs do not necessarily give a consistent and reproducible record. Comparatively small variations can have significant implications in their clinical and research value.²⁰ To limit variability all the photos were collected by the same clinicians in a standard way. Although no head positioning support device was used head position was standardized during photos. All the photos were shot in the same room, with the same light condition, in the same position, from the same distance by the same senior author.

The measuring system adopted by the authors kept in mind the value of WTW which is unchanged after blepharoplasty; therefore, the ratio MRD2/WTW reflects a “calculated” MRD2. A calculated ratio for MRD2 has been considered the best way to compensate the differences inherent in scale for patient photographs. Therefore, the digital analysis of the pre and post op photos resulted more accurate than those in mm using a handheld ruler because inter observer variability resulted very low.¹⁹

To evaluate the reliability of the measurement method data collected from the three different clinicians and the differences in mean were statistically compared inseting as fixed effects in LMM.

Given the small sample size and small measurement scale a significant margin of error could occur. To compensate the difference in scale of the photos a calculated ratio MRD2 was used instead of measured values in mm. R was averaged between the 3 different values collected by the 3 different clinicians and then compared pre and post operatively.

Although the study focused on the lower eyelid, all the enrolled patients underwent both upper and lower eyelid procedures to reduce the influence of external bias.

Conclusion

The study reports that the anchorage of the orbicularis muscle flap to the upper orbital rim works efficiently to stabilize the lower eyelid position after transcutaneous blepharoplasty, contrasting competently its downwards dislocation. Furthermore it supports the clinical observation that it cooperates in optimizing orbital rejuvenation, maintaining a natural cosmetic appearance. The reproducibility of the technique is easy to perform, extends slightly surgical timing, does not require additional scars and the post op morbidity remains substantially the same.

Conflict of interest statement

Funding: None

Ethical approval

All the procedures performed in studies involving human participants were in accordance with the ethical standards of the institutional and national research committee and with the 1964 Helsinki declaration and its later amendments or comparable ethical standards.

Bibliography

1. Furnas DW. Festoons of orbicularis muscle as a cause of baggy eyelids. *Plast Reconstr Surg.* 1978;61(4):540-546.
2. Carriquiry CE, Seoane OJ, Londinsky M. Orbicularis transposition flap for muscle suspension in lower blepharoplasty. *Ann Plast Surg.* 2006;57(2):138-141.
3. Zoumalan CI, Lattman J, Zoumalan RA, Rosenberg DB. Orbicularis suspension flap and its effect on lower eyelid position: a digital image analysis. *Arch Facial Plast Surg.* 2010;12(1):24-29.
4. Subramanian N. Blepharoplasty. *Indian J Plast Surg.* 2008;41(Suppl):S88-92.
5. Griffin G, Azizzadeh B, Massry GG. New insights into physical findings associated with post blepharoplasty lower eyelid retraction. *Aesthet Surg J.* 2014;34(7):995-1004.

6. Drolet BC, Sullivan PK. Evidence-based medicine: Blepharoplasty. *Plast Reconstr Surg.* 2014;133(5):1195-205.
7. Rohrich RJ, Ghavami A, Mojallal A. The five-step lower blepharoplasty: blending the eyelid-cheek junction. *Plast Reconstr Surg.* 2011;128(3):775-783.
8. Segal KL, Patel P, Levine B, Lisman RD, Lelli GJ Jr. The Effect of transconjunctival blepharoplasty on margin reflex distance 2. *Aesthetic Plast Surg.* 2016;40(1):13-18
9. McCullagh P, Nelder JA (1989) *Generalized Linear Models, Second Edition*, Chapman and Hall/CRC.
10. Adamson JE, Mc Craw JB, Carraway JH. Use of a muscle flap in lower blepharoplasty. *Plast Reconstr Surg.* 1979;63:359-363.
11. Rüfer F, Schröder A, Erb C. White-to-white corneal diameter: normal values in healthy humans obtained with the Orbscan II topography system. *Cornea.* 2005;24(3):259-261.
12. Seiff SR. Complications of upper and lower blepharoplasty. *Int Ophthalmol Clin.* 1992;32(4):67-77.
13. Smith B. Post surgical complications of cosmetic blepharoplasty. *Trans Am Acad Ophthalmol Otolaryngol.* 1969;73(6):1162-1164.
14. Smith B, Nesi FA. The complications of cosmetic blepharoplasty. *Ophthalmology.* 1978;85(7, pt 1):726-729
15. Lisman RD, Hyde K, Smith B. Complications of blepharoplasty. *Clin Plast Surg.* 1988;15(2):309-335.
16. Kikkawa DO, Kim JW. Lower-eyelid blepharoplasty. *Int Ophthalmol Clin.* 1997;37(3):163-178.

17. De Silva DJ, Prasad A. Aesthetic canthal suspension. *Clin Plast Surg*. 2015 Jan; 42 (1): 79-86
18. Fagien S. Algorithm for canthoplasty. The lateral retinacular suspension: a Simplified suture canthopexy. *Plast Reconstr Surg* 1999 June; 103 (7): 2042-2053.
19. Hidalgo DA. An integrated approach to lower blepharoplasty. *Plast Reconstr Surg* 2011;127(1):386-395.
20. Boboridis K, Assi, A, Indar A, Bunce C, Tyers AG. Repeatability and reproducibility of upper eyelid measurements. *Br. J. Ophthalmol*. 2001;85(1):99-101.
21. Coombes AG, Sethi CS, Kirkpatrick WN, Waterhouse N, Kelly MH, Joshi N. A standardized digital photography system with computerized eyelid measurement analysis. *Plast Reconstr Surg*. 2007;120(3):647-656.

Table 1.

	Eyes (Patients)	Range Relative Variation	Mean Relative Variation	Number of eyes with relative variation less than 5%	Number of eyes with relative variation between 5% and 10%	Number of eyes with relative variation more than 10%
GROUP A*	40 (20)	-32.1% to -1.7%	-9.23%	11 (27.5%)	21 (52.5%)	8 (20%)
GROUP B**	34 (17)	0.3% to 34.1%	10.79%	10 (29.5%)	8 (23.5%)	16 (47%)

Table 1. Showing the results in two different groups of patients.

*Group A: Patient treated with the anchorage of an orbicularis oculi flap to the periosteum of superior orbital rim. **Group B: Patient treated without the anchorage of an orbicularis oculi flap to the periosteum of superior orbital rim.

ACCEPTED MANUSCRIPT

Figure legends

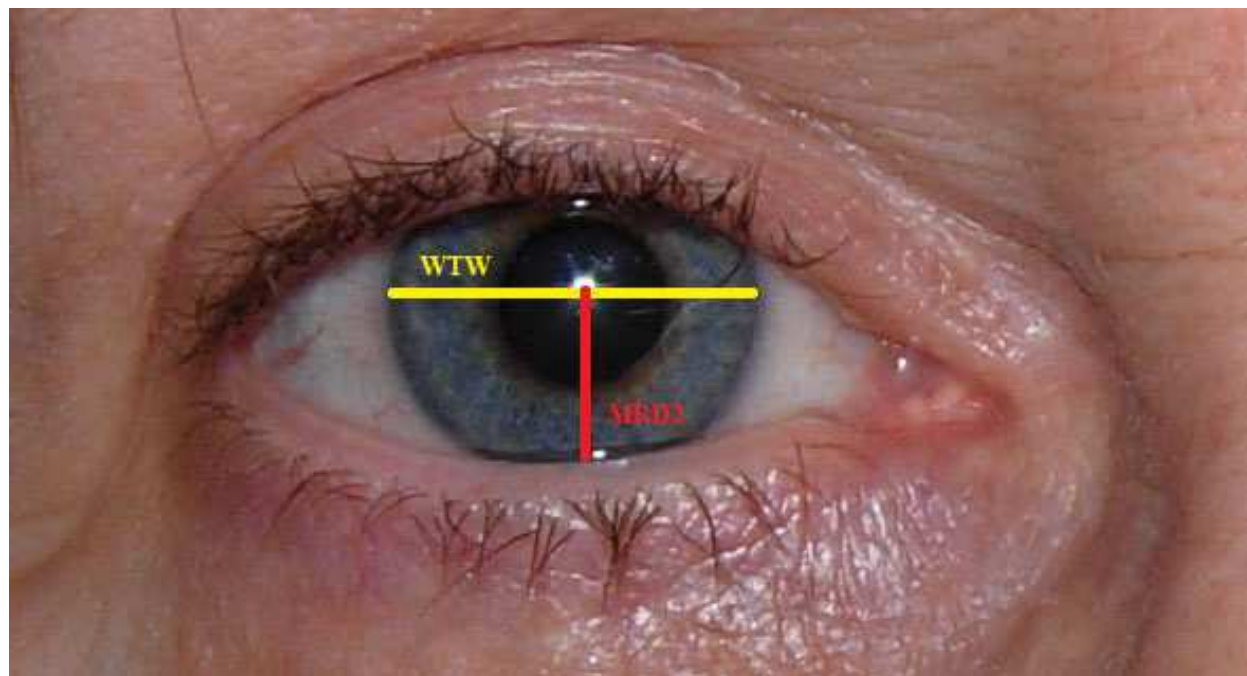
Fig. 1: Digital image analysis was used to standardize preoperative and postoperative photographs. The Margin Reflex Index 2 (MRD2, red line), namely the distance (in pixels) from the centre of the pupil to the lower eyelid margin at the mid pupillary line, and the White-to-White Corneal Diameter (WTW yellow line) were measured. The Ratio (R) $MRD2/WTW$ was used to compensate for differences in scale inherent in photography.

Figure 2 : Box-plot for relative variation distribution over the considered fixed effects.

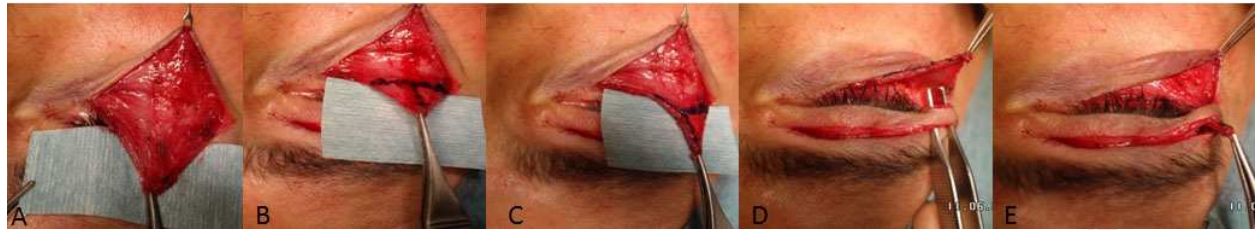Figure 3: showed: A) the orbicularis oculi muscle flap; B) the Reidy Adamson flap is planned; C) the Reidy Adamson flap is harvested; D-E) The flap was passed beneath a para-lateral-canthal tunnel, reaching the upper eyelid and fixed at the periosteum of the upper lateral orbital rim.

Case 1. 44 years old man treated without orbicularis oculi muscle flap anchorage (group B); A pre operative frontal view. B) 12 months post op frontal view. The image shows an improvement of the general appearance with a more youthful look but with an overoperated appearance due to a increase of MRD2: 19.3 % (approximately 1,2 mm) on the right eye, 16.2 % (approximately 0,9 mm) on the left.

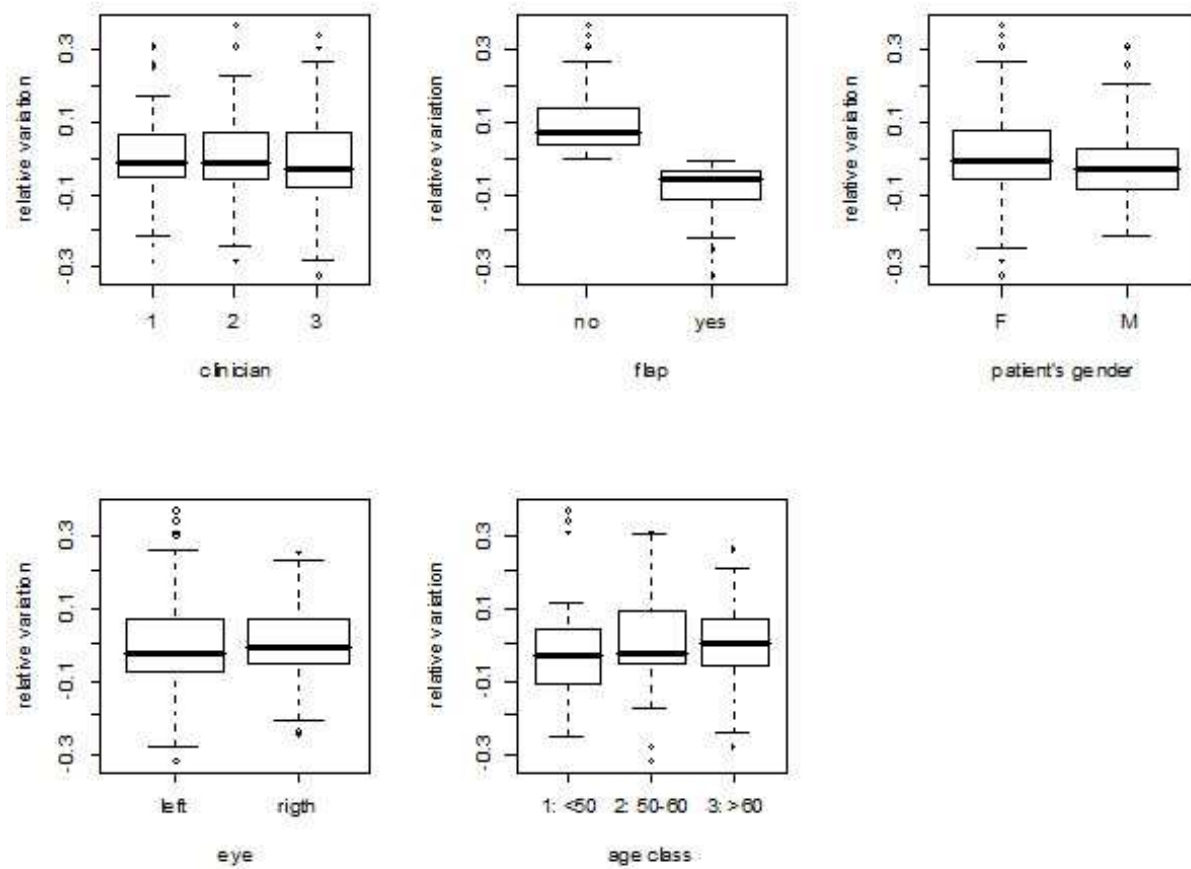
Case 2. 53 years old woman treated with anchorage of orbicularis oculi muscle flap to the periosteum or the upper orbital rim. (group A); A) pre operative frontal view; B) 12 months post op frontal view. The image shows a decrease of MRD2 in the right eye about 7.1% (approximately 0,4 mm) and in the left eye about 7,6% (approximately 0,5mm). She appears more youthful and balanced without lower lid malposition and overoperated appearance. Harvesting separately a wide skin flap, the lower eyelid festoons were corrected. The tone of the orbicularis oculi muscle is improved also by harvesting a muscle flap, taking up redundant muscle and anchoring it to the orbital rim.



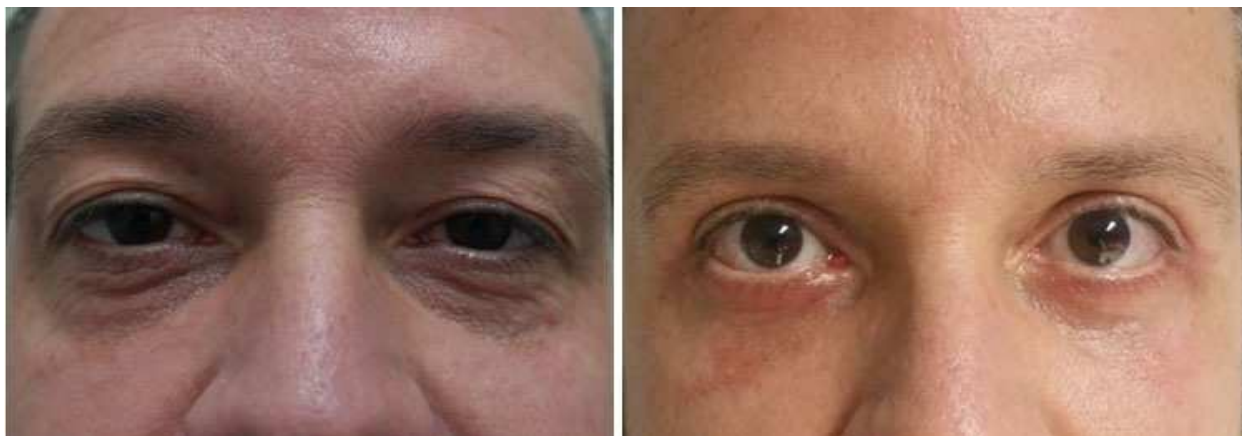ACCEPTED MANUSCRIPT



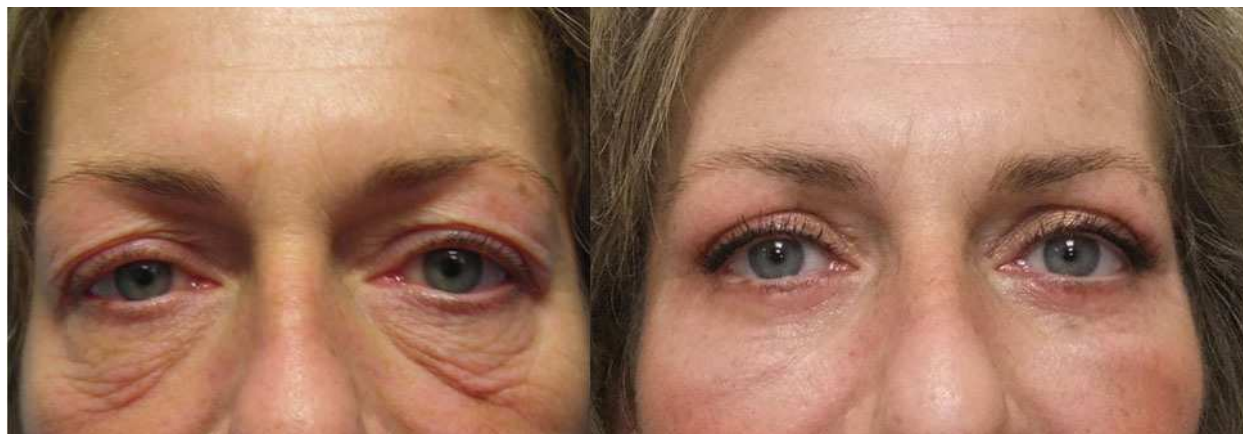ACCEPTED MANUSCRIPT



ACCEPTED



ACCEPTED MANUSCRIPT



ACCEPTED MANUSCRIPT